

## ASSESSMENT OF THORACIC ABNORMALITIES IN PREMATURE INFANTS

**Background:** There is a large incidence of congenital thoracic abnormalities that manifest as deformities and or defects of anterior chest walls. Thoracic abnormalities in preterm infants may also be associated with malpositioning in the incubator in the presence of respiratory disease and prolonged mechanical ventilation. Immaturity of respiratory and musculoskeletal system need to compromise biomechanical function of thorax. Thus, the purpose of the study is to assess the thoracic alteration and the factors associated with its abnormalities in the infants born prematurely.

**Objective:** Assess thoracic alteration in premature infants.

**Method:** This was an observational study with infants in first year of age, born prematurely with birth weight < 2000g. Exclusion criteria were: major congenital malformations as defined by the CENTERS FOR DISEASE CONTROL AND PREVENTION, grade III/IV intraventricular hemorrhage or periventricular leucomalacia. Physical examinations were performed independently to assess shoulder elevation and thoracic alterations.

**Result:** 34 infants born prematurely were included for the study according to the inclusion criteria from which 20 infants (58.8%) showed thoracic abnormalities and remaining 14 infants (41.1%) were without abnormalities.

**Conclusion:** The prevalence of thoracic abnormalities was high in infants born prematurely, and was associated with pulmonary disease, and may also have compromised the growth rate of these infants during the first year of life.

**Keywords:** infants, premature, deformities, thoracic abnormalities.

### INTRODUCTION:

There is a large incidence of congenital thoracic abnormalities that manifests as deformity and or defects of the anterior chest wall, which may also have cardiopulmonary and vascular implications. As there is immaturity of the lungs, ribcage and central nervous system, which frequently needs prolonged mechanical ventilation and oxygen therapy in preterm infants. The therapy may be associated with lung injuries such as, bronchopulmonary dysplasia, which increases the morbidity and prolonged stay in hospital.<sup>1</sup>

The thoracic abnormalities in preterm infants may also be associated with malpositioning in the incubator in the presence of respiratory disease and prolonged mechanical ventilation. In the premature infants, some factors could explain the high prevalence of musculoskeletal alterations. The immaturity of the lungs and the ribcage favors and increase the effort required for breathing, in case of acute respiratory illnesses. Under these conditions, accessory respiratory muscles, such as trapezius and sternocleidomastoid, are recruited, thus increasing thoraco-abdominal asynchronism<sup>1</sup>. In patients with chronic obstructive pulmonary disease, the hyperinflation caused by parenchyma destruction could increase the ribcage diameter<sup>1</sup>. The resulting altered diaphragm position and reduced muscle contraction and tidal volume, cause the recruitment of accessory

muscles of the neck and upper ribcage to maintain ventilatory demand, thereby causing typical postural abnormalities.

Respiratory distress syndrome, patent ductus arteriosus and bronchopulmonary dysplasia are inter-related and significantly contribute to the occurrence of thoracic musculoskeletal alterations<sup>1</sup>. The presence of patent ductus arteriosus is known to contribute to the development of bronchopulmonary dysplasia, whose clinical consequences may persist into adolescence, which increases the stay in the NICU.

Bronchopulmonary dysplasia may be followed by obstructive impaired lung function in the first year of life and may cause biomechanical alterations and recruitment of all the respiratory muscles including the accessory respiratory muscles, over a long period leading to thoracic alterations<sup>1</sup>. In preterm infants tidal breathing components that identify the asynchrony and paradoxical motions between the ribcage and abdominal compartments may be different from those of the healthy full-term infants because of their shape, deformity and high compliance of the premature thorax. The infants born prematurely, at one year of age, with low gestational age, birth weight, respiratory distress syndrome are in need of mechanical ventilation or prolonged oxygen therapy.

The high rate of musculoskeletal alteration are observed in specific anatomical and physiological characteristics of preterm infants: less ribcage ossification, resulting in increased flexibility, immature contractile activity of the intercostal and accessory respiratory muscles, reduce efficiency of diaphragmatic contraction due to limited excursion and limited strength of inspiratory and expiratory muscles. These factors lead to increased work of breathing, resulting in thoracic abnormalities in the long term<sup>5</sup>. These alterations can appear as a consequence of cardiopulmonary diseases during the neonatal period and may persist long term.

The chronic respiratory morbidity can be observed in premature infants, particularly in those having bronchopulmonary dysplasia and may cause musculoskeletal abnormalities in childhood as a consequence of increased work of breathing. Thus, the purpose of this study is to assess the thoracic alterations and the factors associated with its abnormalities in infants born prematurely.

## **METHOD:**

It was a cross-sectional study in which 34 of infants of age between 1 to 12 months prematurely born. The parents/guardians signed the informed consent forms.

The infants were selected according to the inclusion and exclusion criteria, with gestational age <37 weeks and birth weight <2000g. Exclusion criteria were infants with congenital malformation, Grade iii/iv intraventricular hemorrhages, pre-ventricular leucomalacia diagnosed by cranial ultrasound and/ or magnetic resonance.

Infants who met the inclusion criteria were subjected to physical examination and a photographic session. The photographs were analyzed using a software SAPO.

## **PHYSICAL EXAMINATION<sup>5</sup>**

For physical examination the infants were positioned on their back with their thorax visible. As the frequency of clinical alteration observed in adults and children with chronic pulmonary disease two abnormalities were noted specifically.

- Shoulder elevation
- Retraction in the rib cage

## **PHOTOGRAPHY**

Two photographs were taken of every infant in supine position with different angles and varying distance.

Photograph 1: Prior taking the first photograph an adhesive was attached to the manubrium, acromion and trapezius muscle (lateral third of the clavicle). It was taken in frontal plane and was used to assess shoulder elevation. A digital camera was placed at the end of 30-cm rod that was attached to a tripod 150 cm high, parallel to infant and at distance of 70 cm perpendicular to thorax.

Photograph 2: Prior taking the second photograph an adhesive tape was attached longitudinally to the skin between the left nipple and last rib following the curvature of the thorax. A straight rod marked every point 0.5 cm was placed above the tape and fixed with adhesive tape at each end. It was taken on the sagittal plane with a digital camera attached to a tripod, 20cm from the side of the bed and from a height of 95 cm.

## **PHOTOGRAPH ANALYSIS**

All photographs were analyzed using SAPO. The steps of analysis were: open the photograph, zoom to 100% and calibrate the image based on the plumb line and the mark the anatomical points on the photographs.

The detection of borders function was used for photograph 1 in order to facilitate observation of the marks on the acromion and trapezius muscles. Due to normal asymmetry of body, only one side (right side) was chosen to the fixed elevation of the shoulders.

The distance measurement function was used for photograph 2. Before analysis, the photograph was calibrated on known measurements of the rod. A perpendicular distance between the rod and the edge of the adhesive tape determine the retraction depth. The greatest thoracic retraction depth (GTD) was used for the analysis.

## **STATISTICAL ANALYSIS**

The analysis for the study was done with the of qualitative data measure the graphs were presented by Graph Pad Instat 3.1 version.

## **RESULTS**

During the study period, 34 infants with age between 1 to 12 months and weight of > 2000g were examined. Among which 25 (73.5%) male and 9 (26.4%) female, with weight ( $1389.1 \pm 343.91$ ) range 885 to 1893g, age

ranging between 20 to 27 were 8 (23.5%) and infants more than 27 weeks were 26 (76.5%). On analysis of the photograph infants with abnormalities were 20 (58.8%) and infants without abnormalities were 14 (41.1%).

For analysis of the demographic and clinical characteristics of the studied infants' physical examination were performed. Infants with shoulder elevation presented with smaller manubrium/ acromion/ trapezius angle [ $139.6^\circ$  to  $152.7^\circ$  ( $145.91 \pm 4.213$ )] and the greatest thoracic depth [0.3 to 0.9 cm ( $0.5824 \pm 0.1977$ )].

Regardless of the presence of thoracic alterations, infants in the study exhibited similar nutritional status. The following statistically significant variables derived from the univariate analysis were included in the multivariate model: type of delivery, gestational age and birth weight.

Table 1 : Distribution of study variables among thoracic abnormalities in premature infants

<b>VARIABLES FOR THORACIC ABNORMALITIES</b>	<b>FREQUENCY</b>	<b>PERCENTAGE (%)</b>
<b>TYPE OF DELIVERY</b>		
NORMAL	7	20
LSCS	27	79.4
<b>AGE OF BABY (YEARS)</b>		
20-27	8	23.5
MORE THAN 27	26	76.5
<b>GENDER OF THE BABY</b>		
MALE	25	73.5
FEMALE	9	26.4

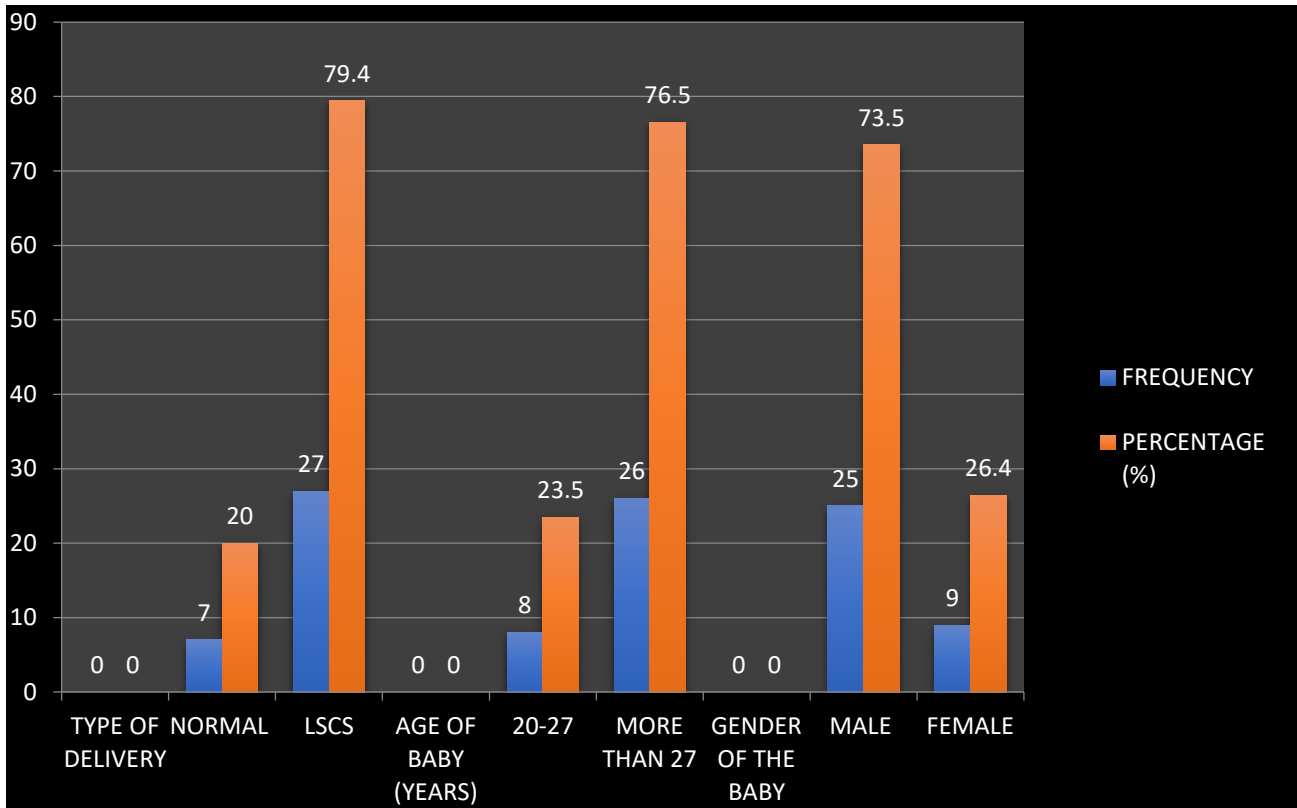


Fig 1 Graphical representation distribution of study variables among thoracic abnormalities in premature infants

Table 2: Percentage and Frequency found in premature infants

	<b>FREQUENCY</b>	<b>PERCENTAGE (%)</b>
<b>ABNORMALITIES</b>	20	58.8
<b>NORMAL</b>	14	41.1

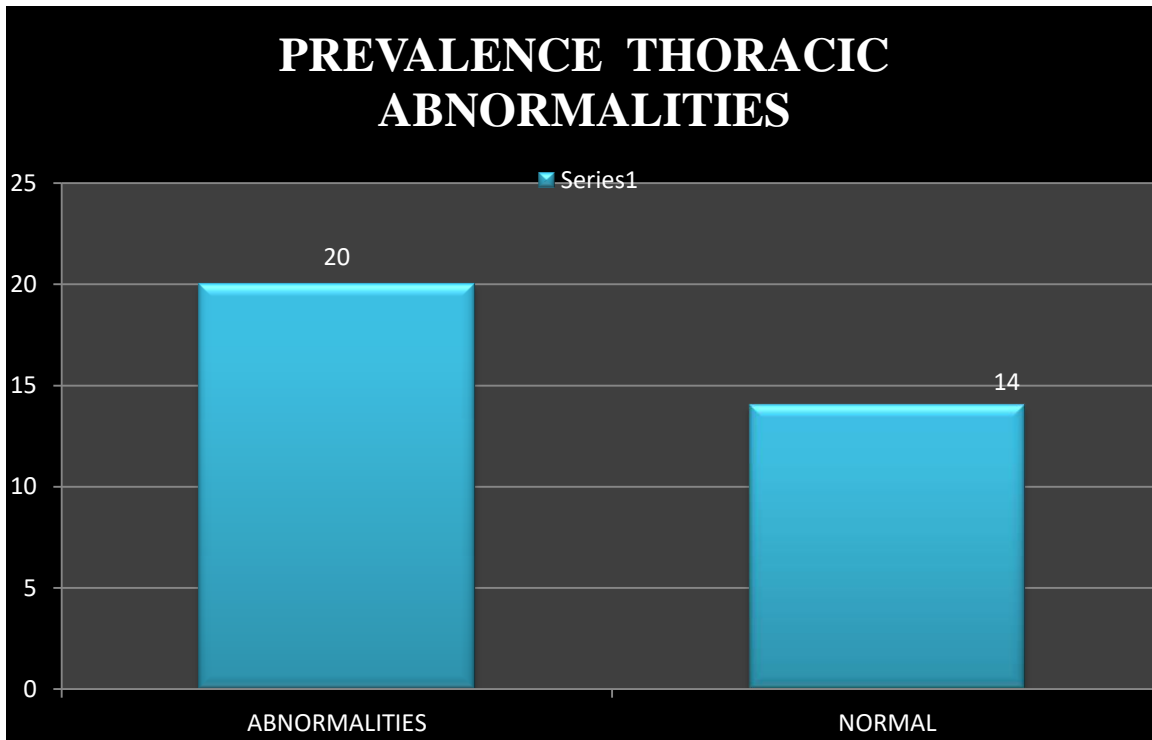


Fig 2 PREVALENCE THORACIC ABNORMALITIES

Table 3: Weight of infant, manubrium - acromion – trapezius angle, greatest thoracic retraction depth.

<b>WEIGHT OF BABY (gm.)</b>	
MEAN±SD	1389.1 ± 343.91
<b>MAT</b>	
MEAN±SD	145.91 ± 4.213
<b>GTD</b>	
MEAN±SD	0.5824 ± 0.1977

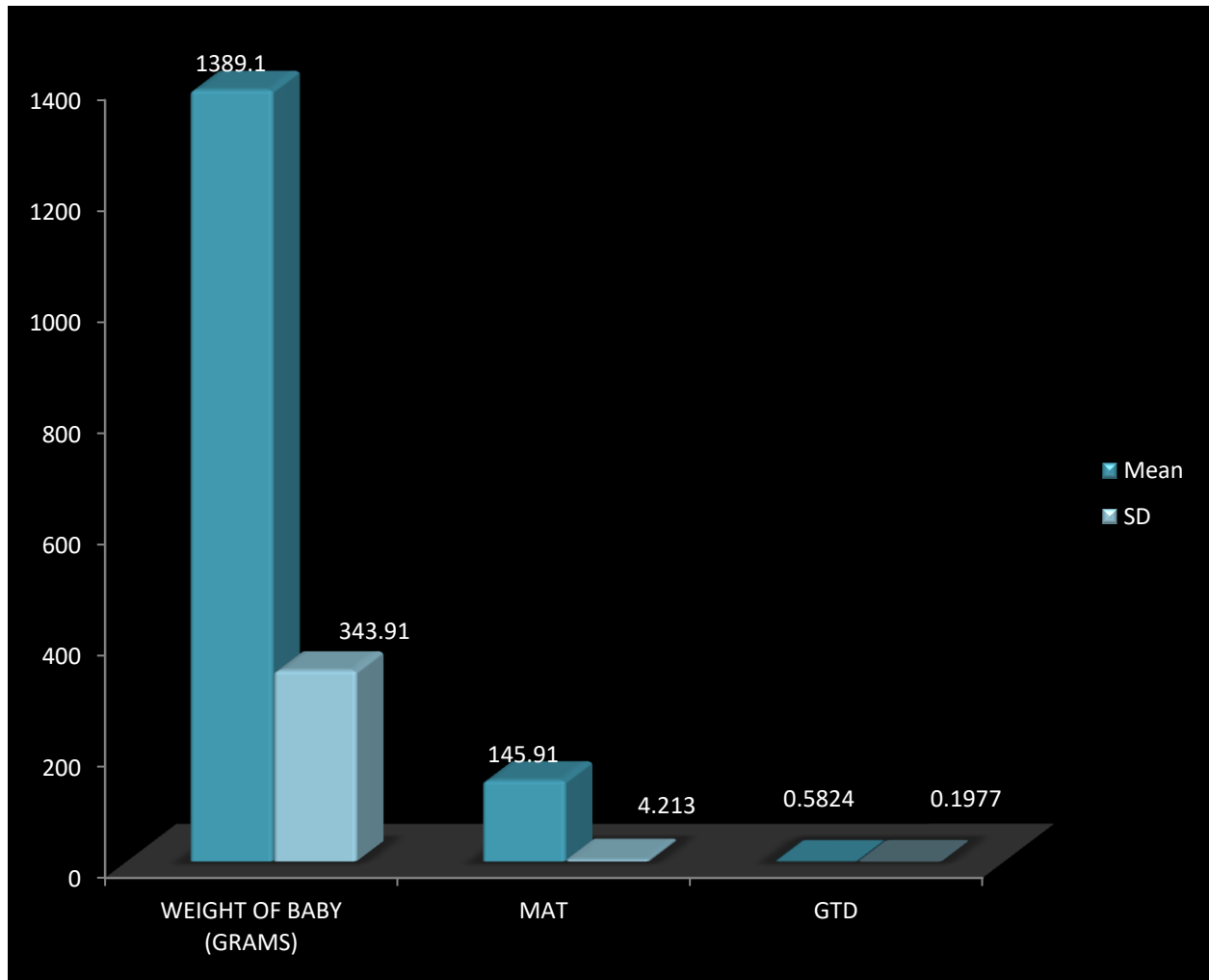


Fig 3 Graphical representation of weight of infant, manubrium - acromion – trapezius angle, greatest thoracic retraction depth

## DISCUSSION

To the author's knowledge, there are a few studies done on assessing thoracic abnormalities in infants born prematurely. Although there are no data for comparison, the prevalence of thoracic abnormalities found in this study are high. In premature infants, some factors could explain the high prevalence of musculoskeletal alterations found in this study there is large group of congenital abnormalities of thoracic cage that manifest as deformities and defects of the anterior chest wall, which also may have cardiopulmonary and vascular implications. This diverse group includes pectus excavatum, pectus carinatum, pouter pigeon breasts, Poland syndrome and cleft sternum.

The immaturity of the lungs and rib cage favors an increase in effort required to breathe, in case of acute respiratory illness. Under these conditions, accessory respiratory muscles, such as trapezius and

sternocleidomastoid are recruited, thus increasing thoracoabdominal asynchronism<sup>1</sup>. Successive increase in respiratory work during the neonatal period can alter respiratory work during neonatal period can alter respiratory muscles and, in the long term, rib cage configuration.

In patients with chronic obstructive pulmonary disease, the hyperinflation caused by parenchyma destruction could increase the rib cage diameter. The resulting altered diaphragm position, and reduced muscle contraction and tidal volume, cause the recruitment of accessory muscle of the neck and upper rib cage in order to maintain ventilator demand, thereby causing typical postural abnormalities in the long term.

The development of shoulder elevation reflects the use of neck and upper thorax muscles, such as the trapezius, sternocleidomastoid, and pectoral muscles, as imposed by increased respiratory effort. Thoracic retraction occurs due to thoracoabdominal asynchronism, causing depression of the rib and sternum.

According to univariate analysis, every 10g decrease on birth weight increased the probability of having such abnormalities by 10-fold. This suggests that lower birth weight represent a greater probability of morbidity and need for life support, particularly, mechanical ventilation and oxygen therapy. Further, the univariate analysis demonstrated that all variables related to respiratory illness increased probability of thoracic abnormalities in first year of life.

A physical examination is a qualitative and subjective tool, and is dependent upon examiners experience; this could also mention as a limitation of this study. However present study, physical examinations were performed by professionals, thereby justifying its use as a reference standard for the assessment of musculoskeletal alterations.

The presence of thoracic alterations was found to be associated with neonatal prematurity and pulmonary diseases.

## **CONCLUSION**

The prevalence of thoracic abnormalities was high in infants born prematurely, and may also have compromised the growth rate of these infants during the first year of life. This study could be useful for early diagnosis of thoracic abnormalities in premature infants; and may contribute to follow up programme for preterm infants and the development of further related studies.

## **REFERENCES**

1. Josy Davidson, Kessey Maria B. Gracia, Liu C. Yi, Ana Lucia Goulart, Amelia Miyashiro N Dos Santos. Prevalence and factors associated with thoracic alterations in infants born prematurely.

2. Hennessey EM, Bracewell MA, Wood N, et al. EPICure study group. Respiratory health in pre school and school age children following extremely preterm birth. *Arch Dis Child*. 2008;93:1037-43.
3. Broughton S, Robert A Fox G, Pollina E, Zuckerman M, Chaudhry S, et al. prospective study of health care utilization and respiratory morbidity due to RSV infection in prematurely born infants. *Thorax* 2005;60:1039-44.
4. Greenough A. Long term pulmonary outcome in the preterm infant. *Neonatology*, 2008;93:324-7.
5. Davidson J, dos santos AM, Gracia KM, Yi LCJoao PC, Miyoshi MM, et al. Photogrammetry: an accurate and reliable tool to detect thoracic musculoskeletal abnormalities in preterm infants. *Physiotherapy*. 2012;98:243-9.
6. Greenough A. Late respiratory outcome after preterm birth. *Early Hum Dev* 2007;83:785-8.
7. Gappa M, Pillow JJ, Allen J, Mayer O, Stocks J. Lung function test in neonates and infants with chronic lung disease: lung and chest wall mechanics. *Pediatr pulmonol* 2006;41:291-317.
8. Sweeney JK, Gutierrez T. Musculoskeletal implications of preterm infant positioning in the NICU. *J Perinat Neonatal Nurs* 2002;46:369-75.
9. Belli JF, Chaves TC, de oliveira AS, Grossi DB, Analysis of body posture in children with mild to moderate asthma. *Eur J Pediatr* 2009;168:1207-16.
10. Dimitriou G, Greenough A, Dyke H, Rafferty GF. Maximal airway pressure during cryig in health pretem and term neonates. *Early Hum Dev* 200;57:149-56.
11. Gracia KM. The impact of prematurity on thocic musculoskeletal structure in adolescence. Sao Paulo: universidade federal de Sao Paulo- Escola Paulista de Medicina;2011.
12. Gross SJ, Iannuzzi DM, Kveselis DA, Anbar RD. Effect of preterm birth on pulmonary function at school age: a prospective controlled study. *J Pediatr* 1998;133:188-92.
13. Warren RH, Horan SM, Robertson PK. Chest wall motion in preterm infants using respiratory inductive plethysmography. *Eur Respir J*. 1997;10:2295-300.
14. Gerhardt T, Bancalari E. Chest wall compliance in full term in premature infants. *Acta*
15. *Pediatr Scand* 1980;69:359-364.
16. Brooks LJ, DiFiore JM, Martin RJ. CHIME study group. Assessment of tidal volume over time in preterm infants using respiratory inductive plethysmography. *Am Rev Respir Dis* 1994;149(4): A694.