

## **Staphylococcal Epidermolysis: a Case Report**

### **ABSTRACT**

Acute staphylococcal epidermolysis, also known as staphylococcal scalded skin syndrome (SSSS), in young children is caused by the release of exfoliative toxins A and B (ETA and/or ETB) from an initial outbreak which can be ear-nose-throat, conjunctival or cutaneous.

Staphylococcal scalded skin syndrome is characterized by painful erythroderma, quickly followed by generalized detachment with respect to mucous surfaces, regressing in 2 to 4 days on antibiotics. The positive diagnosis is mainly based on clinical examination and sometimes on skin biopsy.

The course of the disease is benign, favored by anti-staphylococcal treatment combined with local care. However, the risk of fatal course is estimated at around 4% in the event of delay in antibiotic treatment. We report the case of an infant with SSSS, diagnosed and treated early with good evolution.

**Keywords:** Staphylococcus Aureus- skin, epidermolysis-1, antibiotics

### **INTRODUCTION**

Staphylococcal scalded skin syndrome (SSSS) is a bacterial toxin-mediated skin disorder which occurs when exotoxins produced by Staphylococcus Aureus undergo hematogenous dissemination to the skin. Staphylococcus aureus causes exfoliative dermatitis by secretion of exfoliative toxin A and B with proteolytic activity responsible for the cleavage of desmoglein 1 [1]. Desmoglein-1 is a desmosomal cadherin found in the upper epidermis but not in the mucous membrane.

Staphylococcal scalded skin syndrome is a rare disease with an incidence of 0.09 to 0.56 cases per million inhabitants [5]. It mainly affects infants and young children before the age of six [2]. The susceptibility of young children to SSSS is postulated to result from a lack of protective antibodies against staphylococcal toxins and/or insufficient ability of young children's kidneys to excrete the exotoxins [3]. The diagnosis of SSSS is essentially clinical [4], The management is based on the treatment of the infectious focus. Intravenous anti-staphylococcal antibiotic treatment combined with good hydration, painkillers and local treatments, quickly leads to recovery without sequelae.

## CASE REPORT

A nine-month-old infant was referred to our unit for a generalized rash characterized by erythema, associated with superficial peeling of the skin with scaling lesions, and oozing (Figure 3). The infant, with no particular medical history, had not taken any drugs or toxic substances in the previous days. He had no history of allergies and was up to date on vaccinations. The rash had started four days earlier in the perioral region and neck, then spread over to 70% of the body surface. Everything evolved in a context of pyrexia at 38.7°C. On admission, the infant was conscious, feverish at 39°C, irritable and crying; he refused to feed, his blood pressure was 110 mmHg for systole and 50 mmhg for diastole; the time to re-color was normal, signs of skin dehydration in the form of skin folds, the heart rate was 130 beats per minute. The diuresis was reduced. The clinical examination revealed erythroderma with yellowish oozes (face, neck, nostrils and external auditory canals), desquamative lesions on the back (Figure 4) chest, limbs and external genitalia, (Figure 5) mucous membranes were healthy. The diagnosis of SSSS was made clinically. The infant was conditioned with hydration measures and local care. Antipyretic was administered. The patient was started on intravenous Oxacillin at a rate of 100 mg / kg per day in divided doses every six hours.

A biological assessment demonstrated an increase in CRP to 88 mg/l (standard: 0-10 mg/l) associated with hyperleukocytosis at 28.95 10<sup>3</sup>/mm<sup>3</sup>, predominantly neutrophilic at 14.23 10<sup>3</sup>/mm<sup>3</sup> (standard: 2.0-7.7 10<sup>3</sup>/mm<sup>3</sup>). A sample for bacteriological study of the lesions revealed a staphylococcus aureus sensitive to oxacillin, our patient improved on day 4 of treatment (Figure 6) and the follow-up treatment consistent of oral doses, for six days. The evolution was favorable (Figure 7).

## DISCUSSION

It is characterized by progressive, cutaneous erythema and desquamation and constitutional symptoms (Figure 1). Mucous membrane involvement is absent. The earliest cutaneous signs of SSSS are macular erythema and skin pain. Initially, erythema is accentuated in the skin folds, such as the neck, axillae, inguinal folds, and gluteal cleft. Generalized erythema usually develops within 48 hours. As the disease progresses, flaccid bullae begin to appear in areas of skin erythema, resulting in a wrinkled appearance. Sheet-like, superficial desquamation can develop, leaving large patches of moist, erythematous, shiny skin. Thick crusting and radial fissuring often develop around the mouth, nose, and eyes (Figure 2).

Faced with this clinical picture, the differential diagnosis arises mainly with toxic epidermal necrolysis composed of Lyell and Stevens-Johnson syndrome. The name Lyell syndrome is used for the most extensive forms (> 30% of the body surface) and that of Steven-Johnson syndrome for the limited forms of epidermal necrolysis (<10% of the body surface) [5]. This distinction is however very theoretical, a Stevens-Johnson syndrome being able, in a few hours, to progress to a Lyell syndrome. These differ from the SSSS by several characteristics.

- Involvement of the mucous membranes is usual [5]. Histopathology shows epidermal necrosis of the entire thickness of the keratinocytes [6] and not only at the level of the stratum granulosum. The

cleavage occurs in fact at the dermal-epidermal junction [1].

- A history of drug use is demonstrated during the history (immunological reaction to a drug) [7].
- The disease occurs at any age. It is a life-threatening emergency, the prognosis is severe: 20-25% mortality [5].

If the diagnosis is not clinically obvious, a skin biopsy can differentiate these two pathologies [7]. PCR detecting staphylococcal toxins can also aid in the diagnosis [8].

Among other differential diagnoses, generalized bullous impetigo is also caused by exfoliative staph toxins. Unlike SSSS where the bullous content is sterile because the toxins are spread hematogenously [9], in bullous impetigo, these toxins diffuse locally and *S. aureus* can be identified by swabbing a bubble. Clinically, the bubble is clearly demarcated with no surrounding or generalized erythema and Nikolski's sign is typically negative [10].

Intravenous treatment with an antistaphylococcal antibiotic should begin promptly. Patients are typically initially treated with a penicillinase-resistant penicillin, methicillin, such as oxacillin or nafcillin. Alternatives include a first- or second-generation cephalosporin or vancomycin.

Clindamycin has antistaphylococcal activity but is not recommended as a primary treatment because of high rates of clindamycin resistance in SSSS [11].

Most SSSS isolates in children are susceptible to oxacillin or nafcillin:

- Intravenous nafcillin or oxacillin: 100 to 150 mg/kg per day in divided doses every six hours; maximum daily dose of 12 g per day. Weight-based dosing for neonates differs and is reviewed separately.
- Intravenous cefazolin: 50 to 100 mg/kg per day in divided doses every eight hours; usual maximum daily dose of 6 g.
- Intravenous vancomycin: 45 mg/kg per day in divided doses every eight hours; usual maximum daily dose of 2 g. Initial antibiotic selection should be adjusted based upon antimicrobial susceptibility of isolates. In addition, antibiotic selection and dosing should be appropriately adjusted based upon the underlying infection.

Supportive care is a critical component of management. Adequate hydration should be ensured, and trauma to the skin should be minimized:

Then, depending on the response to treatment, antibiotic therapy may be substituted by the oral route [10]. In our patient's case, the antibiogram showed sensitivity of *Staphylococcus aureus* to oxacillin.

Finally, if no improvement is observed with the antibiotics, the intravenous injection of immunoglobulins for five days (0.4 g/kg/day) or of fresh frozen plasma from an adult (10 ml/kg) had been shown to be effective in children with SSSS.

## CONCLUSION

The initial management of SSSS typically involves hospitalization of the patient, intravenous antibiotic therapy, and supportive measures. We suggest intravenous, rather than oral, administration of an antistaphylococcal antibiotic for initial therapy. A penicillinase-resistant penicillin, such as nafcillin or oxacillin, is usually given as initial therapy. Cephalosporins and vancomycin are alternative treatments. Culture and antibiotic susceptibility testing should be followed to detect the presence of *S. aureus* strains resistant to the selected therapy. Once clinical improvement occurs, patients may be transitioned to oral antibiotic therapy.

### **Consent Disclaimer:**

As per international standard or university standard, parent's consent has been collected and preserved by the authors.

UNDER PEER REVIEW

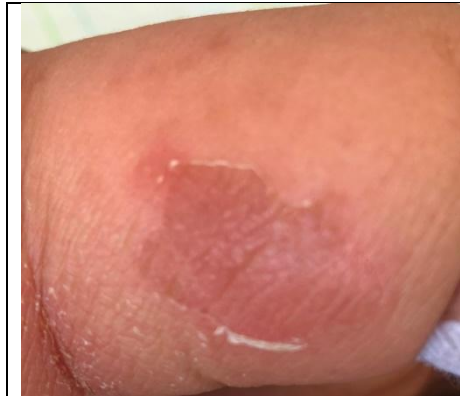

Figure 1

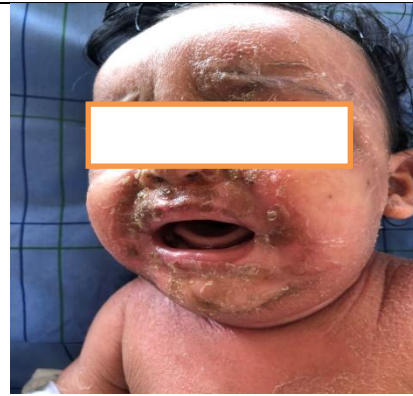

Figure 2

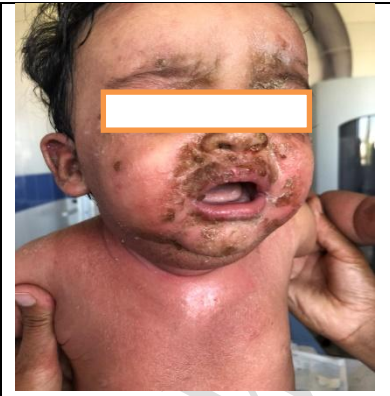

Figure3

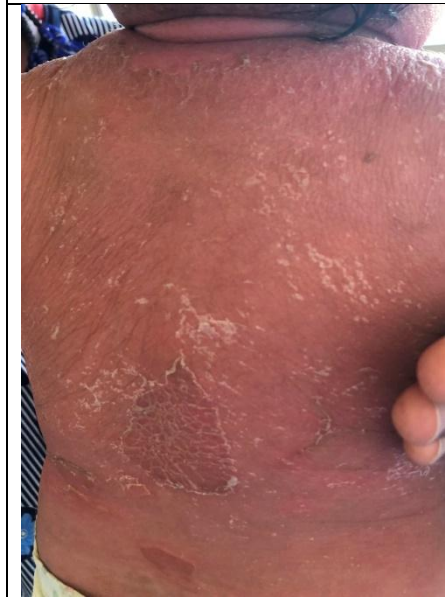

Figure 4

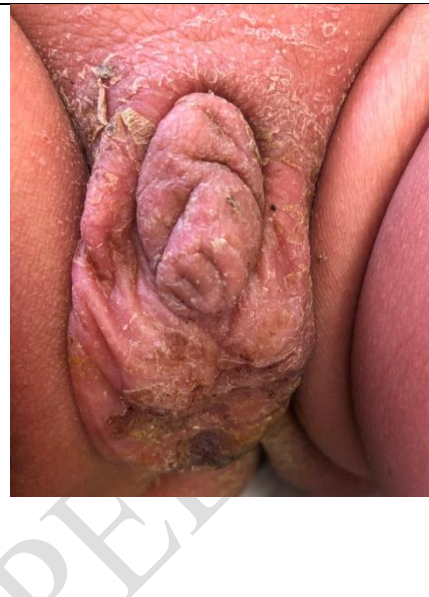


Figure 5

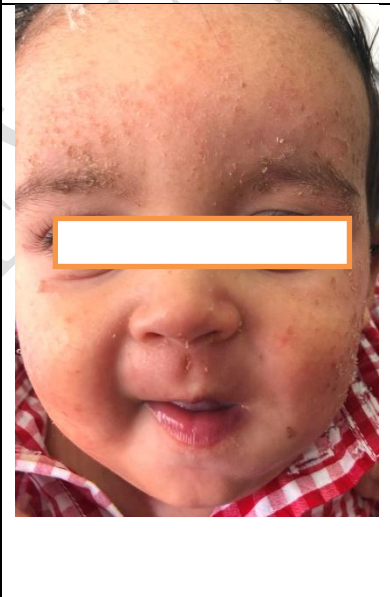

Figure 6

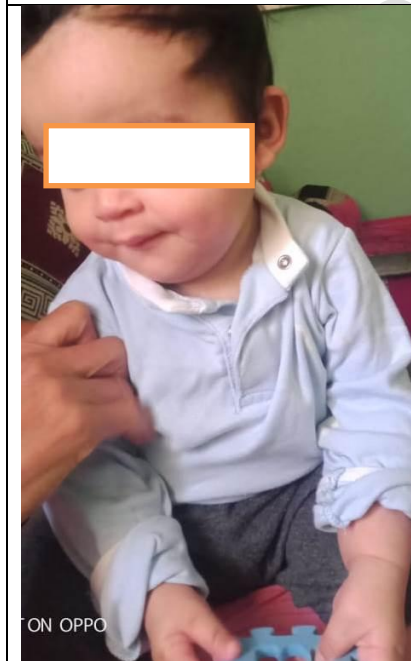

Figure 7

## REFERENCES

- 1 Saurat JH, Lipsker D, Thomas L, Borradori L, Lachapelle JM. Dermatologie et infections sexuellement transmissibles. Elsevier Masson, Paris, 2017, 6ème Edition.
- 2 Haliou A, Malkin JE, Feuillhade de Chauvin M, Patey O, Picard-Dahan C. Dermatologie infectieuse. Elsevier Masson, Paris, 1997.
- 3 Handler MZ, Schwartz RA. Staphylococcal scalded skin syndrome: diagnosis and management in children and adults. *J Eur Acad Dermatol Venereol*. 2014;28(11):1418-23.
- 4 Mourad M, Dupin N, del Giudice P. Dermatologie infectieuse. Elsevier Masson, Paris, 2014.
- 5 Roujeau JC. Syndromes de Lyell et de Stevens-Johnson. *Rev Praticien*. 2007;57:1165-70.
- 6 Hubiche T. Epidermolyse aigüe staphylococcique. *Thérapeutique dermatologique*. <http://www.therapeutique-dermatologique.org>
- 7 Libby E. *Dermatology in emergency care*. Elsevier Health Sciences, Londres 1997.
- 8 Aydin D, Alsbjorn B. Severe case of staphylococcal scalded skin syndrome in a 5-year-old child - case report. *Clin Case Rep*. 2016;4(4):416-9.
- 9 Grama A, Marginean OC, Melit LE, Georgescu AM. Staphylococcal scalded skin syndrome in child. A case report and a review from literature. *J Crit Care Med*. 2016;2(4):192-197.
- 10 Leung AKC, Barankin B, Leong KF. Staphylococcal-scalded skin syndrome: evaluation, diagnosis, and management. *World J Pediatr* 2018; 14:116.
- 11 Braunstein I, Wanat KA, Abuabara K, et al. Antibiotic sensitivity and resistance patterns in pediatric staphylococcal scalded skin syndrome. *Pediatr Dermatol* 2014; 31:305.