

A prospective study of four-part intertrochanteric femur fractures treated with cemented bipolar prostheses in elderly patients.

## Original Research Article

### Abstract

**Introduction:** - The care of comminuted inter trochanteric femur fractures in the elderly is complicated because to the difficulty of anatomical reduction in osteoporotic bones, the requirement for prolonged immobilization following surgery, and the increased risk of screw cut out in poor quality bone. Prolonged Bed sores, chest infections, and deep vein thrombosis are among problems of immobility. Both morbidity and mortality are increased as a result of reliance and psychosocial side effects.

**The purpose of this study:** - "To assess the functional outcome of cemented bipolar hemiarthroplasty in patients over 60 years old with comminuted intertrochanteric femur fractures".

**Material& method:** - This study was conducted in the Department of Orthopedics, Govt. Medical College, and affiliated groups of hospitals in Kota between 2017 and 2019. The patients were all over 60 years old and had an intertrochanteric fracture that was unstable. Exclusion criteria: Patient is unwilling to undergo surgery and is medically unfit.

**Result:** - The average age in our research was 77.3 years. Hypertension was the most prevalent linked medical issue, accounting for 33% of the total. Cerclage wire was used to keep the pieces of the Greater trochanter together (46.66%). In seven cases, calcar reconstruction was performed (23.33%). The patients were followed up on at six weeks, three months, six months, nine months, and one year after surgery. After 6 weeks, 12 patients were able to walk without assistance, 10 with a cane, and 8 with a walker. Squatting and sitting cross-legged were not recommended for any of the patients.

**Conclusion:** For older patients with comminuted inter trochanteric femur fractures, the surgery allowed for quick mobilization, early recovery to pre-injury levels, and provided a long-term solution.

**Keywords:** Cemented hemiarthroplasty, Harris hip score, comminuted intertrochanteric fracture Unstable, Prosthesis

### INTRODUCTION

"Among the most common health issues among the elderly is an intertrochanteric femoral fracture. Nearly half of all hip fractures are intertrochanteric. Osteosynthesis is a simple technique that provides reliable outcomes for stable fractures. However, owing to the difficulties in getting anatomical reduction, managing unstable intertrochanteric (Evans type III or IV and AO/OTA type 31-A2.2 and 2.3) fractures is problematic".<sup>1</sup> "The use of fixed nail plate devices to treat these fractures has historically had a significant risk of fracture displacement and cut-out"<sup>2</sup>. "After that, a sliding hip screw was effectively employed and became the standard way of treating these fractures"<sup>3</sup>. "Head perforations, excessive sliding resulting in shortening, excessive collapse, loss of fixation, cut through and plate withdrawal, and plate breakage continued, particularly in unstable fractures"<sup>4</sup>, "two of the most prevalent causes of poor outcomes are osteoporosis and instability"<sup>5,6</sup>. "A period of reduced mobility is also recommended in these older patients with unstable osteoporotic fractures, which can lead to comorbidities such as atelectasis, bedsores, pneumonia, and deep vein thrombosis"<sup>7</sup>. In the instance of an unstable-intertrochanteric fracture, the end results were defined by fracture stability, bone strength, and early rehabilitation. These individuals have inadequate bone quality and are not candidates for traditional osteosynthesis. Non-union and metal failure are common outcomes of

operations. The main aims of therapy are to achieve a stable fixation and to begin rehabilitation as soon as possible. Some surgeons have advocated prosthetic replacements for unstable intertrochanteric fractures to allow early post-operative weight bearing and quick rehabilitation.

### **The purpose of this study**

evaluating the practical and clinical effect of cemented bipolar arthroplasty as a major treatment for unstable intertrochanteric fractures in an elderly patient with full weight post-surgery stress and return to normal living and reduced rate of revision and learning the final outcome of bipolar prosthesis regarding pain, mobility, stability.

### **MATERIAL & METHODS**

This study was conducted in the Department of Orthopedics, Govt. Medical College, and affiliated groups of hospitals in Kota between 2017 and 2019. After getting clearance from Ethical committee approval This study was followed up on 30 cases of unstable inter-trochanter fracture that match the inclusion criteria in a prospective manner. These patients were all over 60 years old and had an intertrochanteric fracture that was unstable [three or four sections intertrochanteric fracture with loss of the posteromedial cortical buttress and reversed obliquity fracture.

**Exclusion criteria** patient under the age of 60, Polytrauma patient with an open fracture No ambulatory status prior to injury Any signs of illness in the past, Patient is unwilling to undergo surgery and is medically unfit. All patients will undergo a thorough history and clinical examination, with special attention paid to age, gender, mechanism of injury, fracture pattern, medical comorbidities, other related bone damage, reporting time after injury, and time between injury and treatment. Radiographs of the hip will be obtained in the appropriate perspectives, and a clinical and radiological diagnosis will be made. Preoperative buck's skin traction with adequate weight will be applied to the patient. After the appropriate blood, urine, and radiographic preoperative work-up, all patients will be scheduled for elective surgery as soon as feasible.

Preoperative intravenous cephalosporin antibiotics were administered and maintained at a 12-hourly interval for five days after surgery, before switching to oral antibiotics until sutures were removed. The hip joint was exposed via the posterior-lateral technique (Gibson posterolateral hip approach). The underlying fascia, and also the fascia over the gluteus maximus, were exposed and separated in line with the skin incision, and then split in the direction of its fibers using blunt dissection. The greater trochanter is revealed by withdrawing the proximal fibers of the muscle proximally. The greater trochanter is broken in circumstances where it is fractured. anteriorly reflected. The sciatic nerve was rarely exposed, and if it was, it was retracted gently out of the way. After labeling the gemelli, obturator internus, and piriformis tendons, they were split at their insertions for better identification and reattachment. The posterior portion of the capsule is then incised from distal to proximal along the line of the femur's neck and at a right angle to it, forming a 'T' shaped aperture. The leg is rotated internally and the thigh and knee are flexed to 90 degrees to expose the femoral neck. At the neck level, an osteotomy is done, and the hip is displaced posteriorly. The femoral head was levered out of the acetabulum, and the head size was measured using a template; the size was then confirmed with a trial prosthesis. The acetabulum was prepared, the ligamentum teres was completely excised, and the soft tissue in the pulvinar region was curetted. To prepare the femoral shaft for prosthesis insertion, it was rasped using a broach (rasp). To fix the bipolar stem in 10-15 of anteversion, standard cementing processes were employed – washing, cleaning, drying, then canal blocking. Calcar repair utilizing

bone from the removed head is sometimes done before cementing. The larger trochanter and the fractured lesser trochanter were reattached with an SS wire in the instance of comminution. Joint reduction was completed. On the table, the joint was moved to assess the stability of the prosthesis. Flexing and adducting the hip checks the prosthesis' stability and inclination to dislocate. The incision was closed in layers over a suction drain implanted behind the gluteus maximus, which was removed during the first change of dressing after 48 hours after suturing the capsule and external rotators. Foot end elevation was administered postoperatively if spinal anesthesia was used. Pillows were used to keep the lower limbs in abduction [20-30°]. For the first 24 hours, blood pressure, pulse rate, temperature, and respiration rate were measured every half-hour. A postoperative blood transfusion was provided whenever it was necessary. Intramuscular analgesics were provided in accordance with the patient's wishes, and IV antibiotics were maintained for another five days. After 48 hours, the drain was removed. After 48 hours, a follow-up radiograph was taken. Participants were forced to sit up on the second postoperative day, stand up with assistance (walker) on the third day, and then allowed to fully weight bear and walk with assistance (walker) on the fourth postoperative day, depending on pain tolerance, and were urged to walk thereafter. It was forbidden to squat or sit cross-legged. 12 to 15 days following surgery, the sutures were removed. The patients in the study were released on the fifth day or after the stitches were removed. Any shortening or abnormalities in the individuals were examined. Before the patients are discharged, any problems such as infections and bed sores are addressed. Patients were followed up on every six weeks, three months, six months, and twelve months. The Harris Hip Score was used to guide clinical follow-up. A radiological follow-up was performed to look for symptoms of implant loosening, protrusion, dislocation.

## RESULTS

The average age in our research was 77.3 years. There were 35 patients in study, we lost follow-up of 5 patients after discharge, so 30 patients (18 female patients and 12 with 14 right-sided fractures and 16 left-sided fractures. There were 19 patients with minor injuries and 6 patients with RTAs. Intertrochanteric fractures were classified using the AO/OTA classification system. 16 patients had AOType31A2.2 fractures, while 8 had AO/OTA Type31A2 fractures. Six patients reported with AO/OTA Type31A2.1 fractures, three of which were AO/OTA Type31A2.1 fractures. Hypertension was the most prevalent linked medical issue, accounting for 33% of the total. 20% of patients have cardiac disease. 16.66 percent of people had diabetes, 16.66 percent of people had COPD, and 13.33 percent of people had ipsilateral knee osteoarthritis. Pre-operatively, 7 patients (23.33%) required blood transfusion, and post-operatively, 5 patients (16.66%) required blood transfusion, both of which went smoothly. Cerclage wire was used to keep the pieces of the Greater trochanter together in 14 instances (46.66 percent). In seven cases, calcar reconstruction was performed (23.33 percent) One patient with a serous discharge developed a postoperative superficial infection. Without the use of antibiotics, they responded to conservative care alone. 2 patients had superficial bedsores, which were treated with daily dressings and wounds that healed before they were released from the hospital. One

patient had a shortening of less than 2 cm of the operated limb and needed to walk with a cane after surgery. One patient had a two-centimeter shortening, a mild limp, and walked with the assistance of a triple walker. Two of the patients got a 2cm lengthening. On the 3 postoperative day, full weight bearing was allowed. In this Study, mean duration of hospital stay was 8.5 days. Squatting and sitting cross-legged were not recommended for any of the patients. The patients were followed up on at six weeks, three months, six months, nine months, and one year after surgery. On a one-year follow-up, there was no evidence of acetabular erosion, loosening, or dislocation of the prosthesis in this series. After 6 weeks, 12 patients were able to walk without assistance, 10 with a cane, and 8 with a walker. The Harris Hip Scoring System was used to score the functional outcomes, with a score of more than 90 suggesting an exceptional result, a score of 80-90 indicating acceptable results, a score of 70-80 indicating good results, and a score of less than 70 indicating poor results. In our study, 11 patients had excellent results, 14 patients had acceptable results, three patients had medium results, and two patients had poor results.

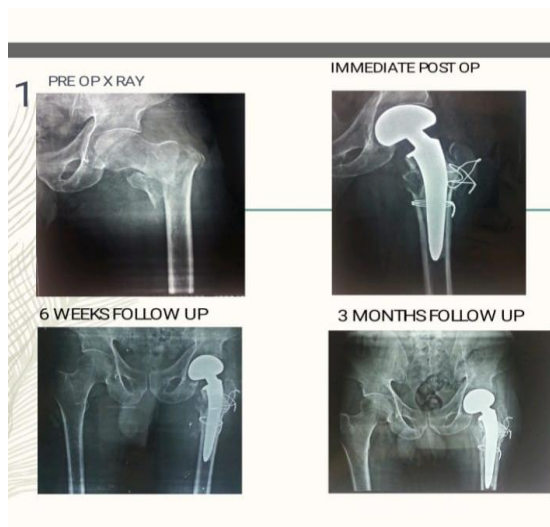


Figure 1 case 1, 2 pre-operative X ray and post-operative x-ray, 3- & 6-month follow-up x ray

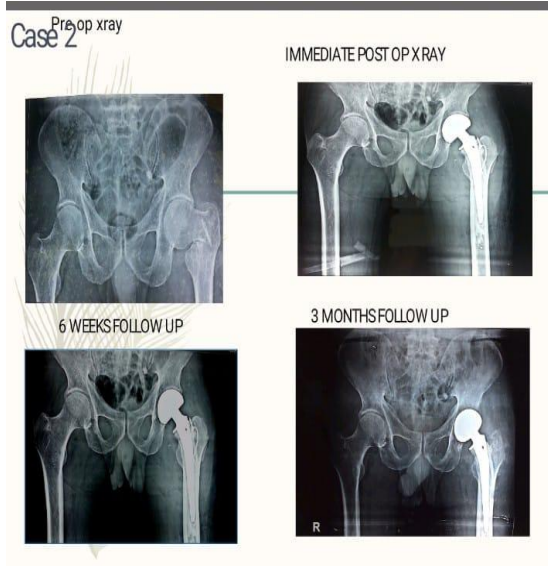


Figure 2 Case 2 pre-operative X ray and post-operative x-ray, 3- & 6-month follow-up x ray

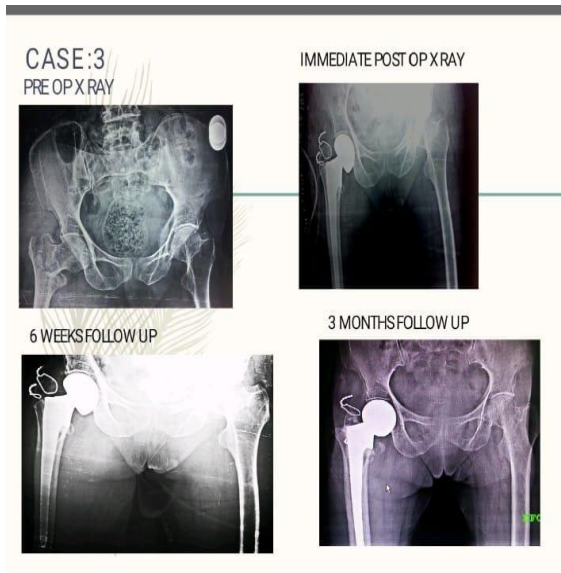


Figure 3 Case 3 pre-operative X ray and post-operative x-ray, 3- & 6-month follow-up x ray



*Figure 4 Clinical Photograph at 6 month follow-up*

UNDER PEER REVIEW

## DISCUSSION

“Displaced, unstable, and substantially comminuted intertrochanteric injuries were linked to considerable morbidity, including death, in elderly people. Despite the fact that internal fixation has greatly reduced mortality associated with intertrochanteric fractures, early mobilization is nevertheless avoided in situations of comminution, osteoporosis, and notably poor screw stability”.<sup>8, 9, 10</sup> “Primary hemiarthroplasty provides for proper fixation and early mobilization in these patients, reducing surgical complications such as bed sores, upper respiratory infections, bronchiectasis, and pseudoarthrosis”.<sup>11</sup> The surgeon has little influence over the quality of the bone or the shape of the fracture. Age, sex, race, general health, muscle mass, and exercise level all have an impact on bone quality (hardness, flexibility, and strength). No one can guarantee 100% fracture stability and complete bone union in the elderly, despite the availability of several fixation techniques such as a fixed nail plate, a sliding hip screw, or intramedullary interlocking devices. In such an aged patient, a hip prosthesis is a successful restoration technique following unsuccessful therapy of an intertrochanteric fracture. As a result of this therapy, the vast majority of people reported significant pain alleviation and improved function. Treatment of comminuted and unstable intertrochanteric fractures in the elderly using a Leinbach bipolar prosthesis, a calcar-replacing prosthesis, is an excellent technique to get the patient up and walking quickly. Treatment with an endoprosthesis is regarded to be beneficial in older patients with intertrochanteric fractures and accompanying comorbidities, since it allows for early mobility. Primary hemiarthroplasty is just a surgical option for these participants that provides sufficient fixation and early mobilization, avoiding postoperative sequelae such as bed sores, pneumonia, bronchiectasis, as well as pseudoarthrosis. As of 1971, hemiarthroplasty has been utilized to treat unstable intertrochanteric fractures. Nevertheless, compared to femoral neck fractures, these occur less often.<sup>12</sup> It was initially designed to be used as a last resort in the event of failed pinning or other difficulties. Rosenfeld, Schwartz, and Alter<sup>14</sup> demonstrated the efficacy of the Leinbach prosthesis. This method has been proved to yield favorable effects in several studies. Stern and Goldstein reported an 88 percent success rate in patients diagnosed with an unstable intertrochanteric fracture who have been addressed the with Leinbach prosthesis. “After treating 105 cases of unstable intertrochanter fractures with the Leinbach prosthesis, Stern and Angerman”<sup>15</sup> documented a 94 percent success rate in returning patients to their refracture ambulatory status. Stern M B et al<sup>13</sup>, “in a series of 105 cases of type III and type IV intertrochanteric comminuted intertrochanteric fractures treated using the Leinbach Bipolar prosthesis, concluded that operations were restored within a short period of time and allowed to carry unrestricted weight almost immediately. The hospital stay was shorter and the incidence of secondary surgery, thrombophlebitis, pulmonary embolism, decubitus ulcers and pneumonia were significantly lower”. Broos PL et al<sup>16</sup>, “in a series of 565 patients, who experienced new trochanteric fractures, were treated with hip replacement, angled blade plate, enders, and Bipolar Hemiarthroplasty. They concluded that repairs

with angled blade plate and enders' pins should be omitted, patients treated with screw hip screw had positive results but, in this treatment, there was a risk of severe falls and pain in 80% of cases, he suggested multifragmentary intertrochanteric fractures. can be treated with endoprosthesis as it can no longer be considered a serious intervention with a risk of less than 1% of mechanical problems". Rodop et al.<sup>17</sup>, "in a series of 54 adult patients, with an average age of 75.6 years, who had unstable intertrochanteric fractures were treated primarily with Bipolar hemiarthroplasties. The series showed excellent results in 17 cases, positive results in 14 cases, positive results in 3 cases, negative results in 13 cases and reported death in 7 cases. They concluded that Bipolar Hemiarthroplasty for unstable intertrochanteric fractures in the elderly was an effective way to provide rapid weight loss and rehabilitation to patients". George et al.<sup>18</sup>, "in a series of 60 patients aged 78 of whom 24 patients were treated for total hip arthroplasty, 27 patients were treated with Bipolar arthroplasty, and 9 patients were treated with unipolar arthroplasty, second failed. internal correction of intertrochanteric fractures. The series showed excellent results in 26 cases, positive results in 20 cases, positive results in 10 cases and negative effects in 4 cases. None of the patients had a revised arthroplasty of acetabular erosion. They did not see any correlation between quality pain relief and treatment with Bipolar Hemiarthroplasty as opposed to total hip arthroplasty. They concluded that hip arthroplasty was an effective way to maintain postoperative treatment of intertrochanteric fracture in older patients. Most patients had good pain relief and functional improvement". Harish, Chokka Ramesh. et al<sup>19</sup>; The average age of the patients receiving cemented bipolar hemiarthroplasty treatment was 68.82 years (60-82) years. There were 12 female and 8 male patients. Patients were checked in on after six weeks, three months, six months, and a year. Using patients with a Harris Hip Score of 8 at the one-year follow-up (40 percent) Ajay Kumar et al<sup>20</sup>. Nine male and eleven female patients with a mean age of 77.3 years participated in this research of 20 cases. 25% of the admitted patients were due to RTA, with the left side being the most often injured side, and 75% of the cases were due to minor trauma. 75 percent of cases were Type II fractures according to Boyd & Griffin. Average time of in our patients, the mean time before complete weight bearing was 3.9 days throughout their 12.6-day hospital stay. lone patient died on postoperative day 5, with 25% excellent, 30% good, and 30% fair outcomes according to study. Harris Hip Score were rated as outstanding, ten patients (50%) as good, and two (10%) as fair. As per Sinno K, Sakr M, Girard J<sup>21</sup> findings suggest that cemented bipolar arthroplasty is the preferred procedure for older patients who are ambulatory and above the age of 70 and have an intertrochanteric fracture. A fractured femur. following surgery, after full weight bearing the postoperative complications of hemiarthroplasty not holding weight following internal fixing. Liu D et al <sup>22</sup> found total of 77 patients with intertrochanteric fracture who received treatment for cemented hemiarthroplasty were repeatedly followed. The statistical analysis was done with a variety of hospital data, Harris school, complications, and mortality rates. Total of 18 models of lateral femoral arising from the ventricles of nine people were used to mimic comminuted intertrochanteric to break. After repairing a small trochanter with a wire to cut and reconstruct the calcar femoral with bone cement, the implant stem was repaired with bone cement, and the mechanical stability of the femoral prosthesis. the stem was tested with a universal test machine. Typical changes are made simultaneously to act as a control. The median follow-up period was approximately 39.2 months, and the mean age of the

patients was  $80.6 \pm 6.0$  years. 1 week after surgery, 89.6% of patients were able to run, with Harris points of  $75.6 \pm 12.0$  points, an incidence of complications. it was 6.4%, and the one-year mortality rate was 20.8%. After the three test groups completed the cycle test, no significant difference was observed in axial displacement data between the three groups. Cemented hemiarthroplasty can effectively treat intertrochanteric fractures in the elderly, and a semi-hip replacement implanted cement can provide sufficient initial stability of the implant stem.

Gashi YN, Elhadi AS, Elbushra IM.<sup>23</sup> concluded that Age, sex, comorbidities, mechanism of trauma, and fracture categorization were equivalent across the two groups. Early mobilization was much superior in the hemiarthroplasty group ( $p < 0.001$ ), where 93.3 percent of patients began light weight bearing on the first postoperative day, as opposed to 73.7 percent of patients in the DHS group who began light weight bearing two weeks following surgery. The mortality rate was the same in both groups at the time of the last follow-up, although the DHS group experienced greater general and mechanical problems. The group that had hemiarthroplasty had a higher mean Harris Hip score (91.14 vs 74.11). The two groups' death rates were similar, although General and mechanical issues predominated. inside the DHS team. The average Harris Hip score improved in the group for hemiarthroplasty (91.14 vs 74.11).

In the short term, bipolar hemiarthroplasty appears to provide a better effect than open reduction and internal correction in the treatment of unstable intertrochanteric fractures in terms of mortality and morbidity, complications, early recovery and return to daily living activities. long-term problems such as relapse, protrusio, stem failure, late infection and late removal have not been identified in this series.

#### **LIMITATION**

The current study was unable to remark on mortality due to the small sample size and short follow-up period. In addition, there were insufficient patients in this trial to do analyses on uncommon adverse effects such as infections, dislocations, and implant loosening. To investigate these problems, a large prospective randomized trial comparing the use of intramedullary implants vs primary hemiarthroplasty for unstable osteoporotic fractures is required.

#### **CONCLUSION**

Based on our findings, **we concluded** that cemented bipolar hemiarthroplasty is **the better** option for freely mobile senior patients over the age of seventy who have an intertrochanteric femoral fracture. In older patients with femur intertrochanteric fractures, the operation provided speedier mobility, a speedy return to pre-injury levels, increased quality of life, and a long-term solution. In these instances, hemiarthroplasty is a difficult surgical procedure. Poor surgical technique can result in increased operational time, a higher risk of deep infection, dislocation, and a poor radiological and functional outcome. Neck length, offset, and version are all carefully restored to enhance hip joint stability and prosthesis lifetime. Extended immobilization, prolonged rehabilitation, significant residual abnormalities, and the need for revision procedures were all minimized with bipolar hemiarthroplasty.

#### **Ethical Approval:**

As per international standard or university standard written ethical approval has been collected and preserved by the author(s).

### **Consent**

As per international standard or university standard, patients' written consent has been collected and preserved by the author(s).

### **REFERENCES**

1. Evans EM. The treatment of trochanteric fractures of the femur. *J Bone Joint Surg Am.* 1949; 31:190–203. Marsh JL, Slongo TF, Agel J, Broderick JS, Creevey W, DeCoster TA, et al. Fracture and dislocation classification compendium: Orthopaedic Trauma Association classification, database and outcomes committee. *J Orthop Trauma.* 2007;21: S1–133.
2. Bannister GC, Gibson AG, Ackroyd CE, Newman JH. The fixation and prognosis of trochanteric fractures: A randomized prospective controlled trial. *Clin Orthop Relat Res.* 1990; 254:242–6. Chinoy MA, Parker MJ. Fixed nail plates versus sliding hip systems for the treatment of trochanteric femoral fractures: A meta-analysis of 14 studies. *Injury.* 1999; 30:157–63. Moller BN, Lucht U, Grymer F, Bartholdy NJ. Instability of trochanteric hip fractures following internal fixation: A radiographic comparison of the Richards sliding screw-plate and the McLaughlin nail-plate. *Acta Orthop Scand.* 1984; 55:517–20.
3. Flores LA, Harrington IJ, Martin H. The stability of intertrochanteric fractures treated with a sliding screw plate. *J Bone Joint Surg Br.* 1990; 72:37–40. Hall G, Ainscow DA. Comparison of nail-plate fixation and Ender's nailing for intertrochanteric fractures. *J Bone Joint Surg Br.* 1981; 63:24–8. Sernbo I, Fredin H. Changing methods of hip fracture osteosynthesis in Sweden: An epidemiological enquiry covering 46,900 cases. *Acta Orthop Scand.* 1993; 64:173–4. Larsson S, Friberg S, Hansson LI. Trochanteric fractures: Mobility, complications, and mortality in 607 cases treated with the sliding-screw plate. *Clin Orthop Relat Res.* 1990; 260:232–41.
4. Davis TR, Sher JL, Horsman A, Simpson M, Porter BB, Cheketts RG. Intertrochanteric femoral fractures: Mechanical failure after internal fixation. *J Bone Joint Surg Br.* 1990; 72:26–31. Kaufer H, Matthews LS, Sonstegard D. Stable fixation of intertrochanteric fractures: A biomechanical evaluation. *J Bone Joint Surg Am.* 1974; 56:899–90. Thomas AP. Dynamic hip screws that fail. *Injury.* 1991; 22:45–46. Simpson AH, Varty K, Dodd CA. Sliding hip screws: Modes of failure. *Injury.* 1989; 20:227–31
5. Kim WY, Han CH, Park JI, Kim JY. Failure of intertrochanteric fracture fixation with a dynamic hip screw in relation to pre-operative fracture stability and osteoporosis. *Int Orthop.* 2001; 25:360–2. Larsson S. Treatment of osteoporotic fractures. *Scand J Surg.* 2002; 91:140–6.

- Jensen JS, Tondevold E, Mossing N. Unstable trochanteric fractures treated with the sliding screw-plate system: A biomechanical study of unstable trochanteric fractures. III, Acta Orthop Scand. 1978;49:392-7.
6. Suriyajakyuthana W. Intertrochanteric fractures of the femur: results of treatment with 95 degrees Condylar Blade Plate. J Med Assoc Thai. 2004.  
Kyle RF, Gustilo RB, Premer RF. Analysis of six hundred and twenty-two intertrochanteric hip fractures. J Bone Joint Surg Am. 1979; 61:216-21.
  7. Stern MB, Angerman A. Comminuted intertrochanteric fractures treated with a Leinbach prosthesis. Clin Orthop Relat Res. 1987; 218:75-80
  8. stern MB, angerman A. comminuted intertrochanteric fracture treated with leinbach prosthesis. clin orthop relat res. 1987; 218:75-80.
  9. Wolfgang GL, Bryant MH, O'Neill JP. Treatment of intertrochanteric fracture of the femur using sliding screw plate fixation. Clin Orthop Relat Res. 1982; 163:148-58.
  10. Sernbo I, Johnell O, Gentz CF, Nilsson JA. Unstable intertrochanteric fractures of the hip: Treatment with Ender pins compared with a compression hip-screw. J Bone Joint Surg Am. 1988; 70:1297-30.
  11. Haentjens P, Casteleyn PP, Opdecam P. The VidalGoalard mega prosthesis: An alternative to conventional techniques in selected cases? Acta Orthop Belg. 1985; 51:221-34.
  12. Parker MJ, Handoll HH. Replacement arthroplasty versus internal fixation for extracapsular hip fractures. Cochrane Database Syst Rev. 2006; 2:CD000086.
  13. Stern MB, Goldstein TB. The use of the Leinbach prosthesis in intertrochanteric fractures of the hip. Clin Orthop Relat Res. 1977; 128:325-31.15.
  14. Rosenfeld RT, Schwartz DR, Alter AH. Prosthetic replacements for trochanteric fractures of the femur. J Bone Joint Surg Am. 1973; 55:420.
  15. Stern MB, Angerman A. Comminuted intertrochanteric fractures treated with a Leinbach prosthesis. Clin Orthop Relat Res. 1987; 218:75-80

16. Broos PL, Rommens PM, Deleyn PR, Greens VR, Stappaerts KH. Petrochanteric fractures in the elderly are they indications for primary prosthetic replacement. *J Orthop Trauma*. 1991; 5(4):446-51.
17. Rodop O, Kiral Kaplan H, Akmaz I. Primary Bipolar hemiprosthesis for unstable Intertrochanteric fractures. *Int Orthop*. 2002; 26(4):233-7
18. George J, Haidukewych, Daniel Berry J. Hip Arthroplasty for salvage of failed treatment of Inter trochanteric hip fractures. *J Bone Joint Surg*. 2003; 85(A):899-904.
- 19 Harish, Chokka Ramesh. "A Prospective Study of Surgical Management of Comminuted Intertrochanteric Fractures of Femur by using Cemented Bipolar Prosthesis in Elderly Patients." *European Journal of Molecular and Clinical Medicine*, vol. 8, no. 4, summer 2021, pp. 1932+.
- 20 Ajay Kumar et al. Study of unstable intertrochanteric fractures treated by cemented bipolar hemiarthroplasty in elderly patients. *International Journal of Orthopaedics Sciences* 2017; 3(3): 241-246. DOI: <http://dx.doi.org/10.22271/ortho.2017.v3.i3d.48>
- 21 Sinno K, Sakr M, Girard J, Khatib H. The effectiveness of primary bipolar arthroplasty in treatment of unstable intertrochanteric fractures in elderly patients. *North American Journal of Medical Sciences* 2010 December, Volume 2. No. 12
- 22 Liu D et al. Clinical and biomechanical studies on cemented hemiarthroplasty treatment of advanced-age comminuted intertrochanteric fractures. *Int J Clin Exp Med* 2016;9(7):13433-13444
- 23 Gashi YN, Elhadi AS, Elbushra IM. Outcome of Primary Cemented Bipolar Hemiarthroplasty compared with Dynamic Hip Screw in Elderly Patients with Unstable Intertrochanteric Fracture. *Malaysian Orthopaedic Journal* 2018 Vol 12 No 1.