

## **Tuberculous Dactylitis-A Case Report**

### **ABSTRACT**

Tuberculous dactylitis is an unusual form of osteoarticular tuberculosis involving the short tubular bones of hands and feet. We report the case of a three-year-old female child who was diagnosed with tuberculous dactylitis, involving metacarpal of hand. Her diagnosis was delayed due to lack of suspicion of this rare entity. The report also examines the diagnostic difficulties faced by clinicians in arriving at an accurate diagnosis.

**Key words:** Dactylitis, Spina Ventosa, Tuberculous Osteomyelitis

### **INTRODUCTION**

Osteoarticular tuberculosis (TB) is a relatively rare presentation of TB, constituting around 10%–15% of all cases of extrapulmonary TB [1]. Tuberculous infection of metacarpals, metatarsals, and phalanges of hands and feet is known as tuberculous dactylitis. Eighty-five percent of the patients are younger than six years of age [2]. Tuberculosis at this site is quite unusual leading to confusion in diagnosis and delays in proper treatment. Since tuberculous dactylitis mimics conditions like chronic pyogenic osteomyelitis and malignancy, hence proper assessment of patient with establishment of definitive diagnosis is absolutely essential before embarking upon a definitive treatment option.

### **CASE REPORT**

A 3-year-old female child of migrant labourer presented to us with swelling on dorsum of right hand for last 6 months. Initially swelling was insidious in onset but showed rapid growth in last 3 weeks (Fig. 1). There was no history suggestive of antecedent trauma. Patient was febrile for last 7 days with functional impairment in the form of inability to grasp objects. Taking into account long history a possibility of tuberculosis was kept at this stage, however other supporting features i.e. loss of weight and appetite, history of antitubercular drug intake, and history of contact with tubercular patient were found absent. Lab investigations revealed Anaemia (Hb=7.2 mg/dl, Haematocrit 24.2%) while Total and Differential leucocyte count were in normal range.

Digital radiography of right hand revealed scalloping of the third metacarpal with underlying subtle cortical irregularities and osteopenia (Fig. 2 ). At this stage possibilities of neoplasia and an infective aetiology were entertained . Computerised tomography revealed lytic destructive area involving third metacarpal bone with flaring of medullary cavity with destruction along lateral aspect with significant soft tissue content along fascial planes with extension and fullness in the carpal tunnel (Fig.3). Since clinically there was a fluctuant swelling on dorsum of hand , ultrasonography was done which revealed dorsal hypoechoic collection 1.6x1.8 cm indicative of soft tissue collection over right hand and underlying cortical irregularity of right metacarpals were noted . Aspiration of the swelling revealed purulent material. No microorganisms were detected from the aspirate, while cartridge-based nucleic acid amplification test (CBNATT) detected Mycobacterium Tuberculosis. Patient was initiated on Antitubercular therapy as per INDEX tuberculosis guidelines and showed full resolution of symptoms and signs, with functional improvement at one year follow up (Fig.4).

## DISCUSSION

Diagnosis of skeletal tuberculosis in children is based more on suspicion as classical features on history, clinical examination and investigations may be absent. This could be due to various factors like absent high index of suspicion and poor awareness among the clinicians regarding this condition in children, atypical presentation, uncommon beyond 6 years of age ,absence of concomitant pulmonary involvement and paucibacillary nature of lesion [3,4]. Still differential diagnosis of dactylitis including pyogenic osteomyelitis, sarcoidosis and enchondroma need to be excluded considering their features on X Ray and histopathology. While osteomyelitis and enchondroma present as a skeletal lytic lesion, skeletal sarcoidosis has a lacy pattern of lytic lesion with periosteal reaction akin to Tuberculosis [5]. However careful consideration of history, clinicoradiological correlation and histopathology together can help arrive at diagnosis of skeletal tuberculosis. In the present case the diagnosis of tuberculous dactylitis was established on basis of long history, cortical destruction on X Ray, and positive CBNAAT for Tuberculosis from aspirate.

Some studies have suggested to start Antitubercular therapy(ATT) without delay even in a suspicion of tuberculosis on clinic-radiological presentation [6]. In the present case there was no classical presentation of skeletal tuberculosis . Long disease history (6 months) and a poor socioeconomic status were the only supporting observation. Although Anaemia

was noted on initial investigation, DLC was found to be in normal range. Aspiration revealed purulent material but detection of tuberculosis on CBNAAT along with cortical destruction of third metacarpal clinched the diagnosis of tubercular dactylitis. **Therefore, tuberculous dactylitis, although representing a rare manifestation of skeletal tuberculosis, should be taken into consideration in case of children with swelling hands**. The diagnosis can be established after meticulous exclusion of other pathologies with identical presentation.

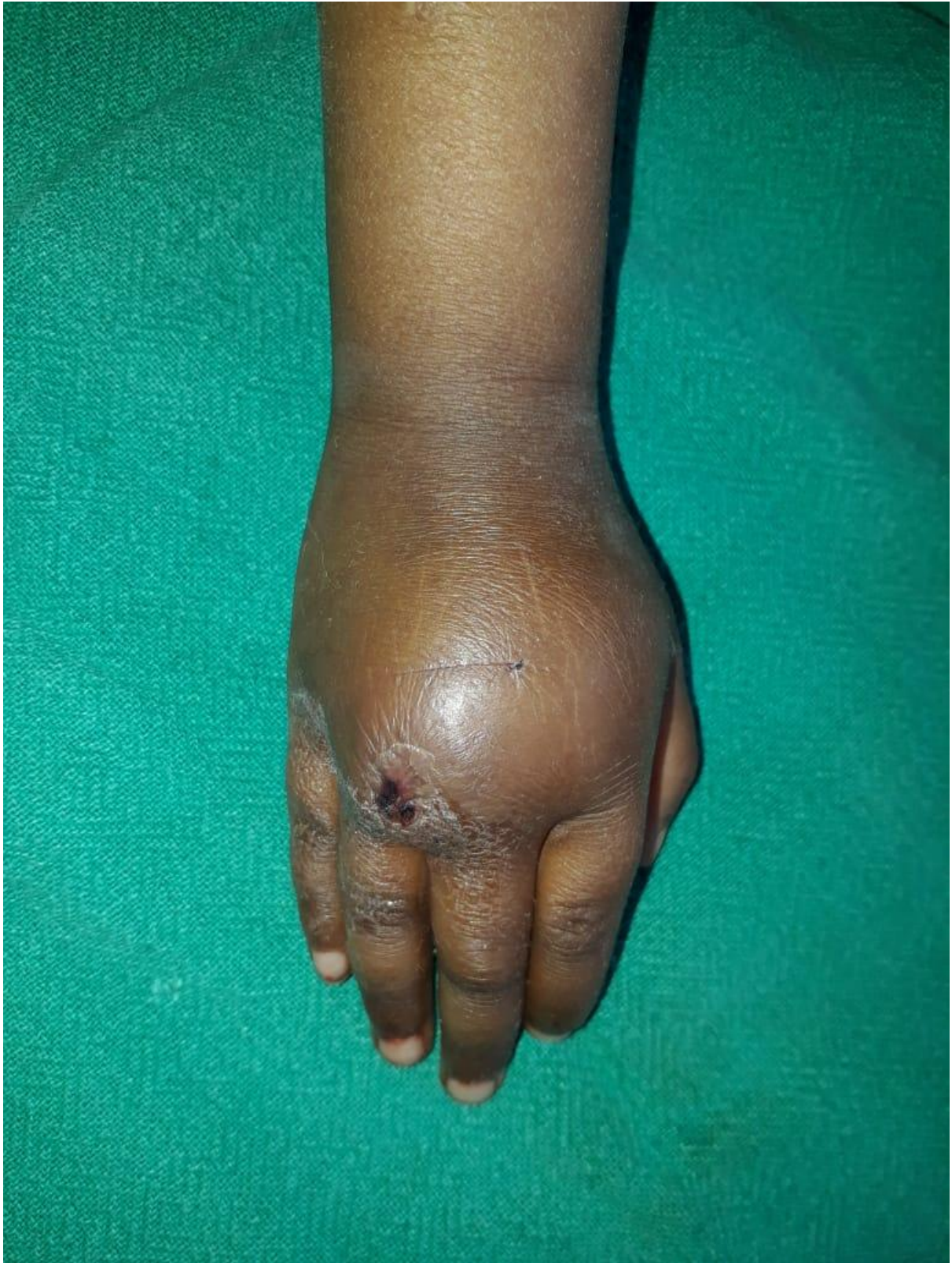## **CONCLUSION**

Skeletal Tuberculosis has very low incidence **and tuberculous** dactylitis is a rare entity. The patients presenting with swelling hand may be misdiagnosed as pyogenic osteomyelitis, malignancy or other granulomatous conditions. **As no single feature is** **resolutive for the tubercular aetiology**, a collective approach involving **anamnesis**, clinicoradiology along with histopathological diagnosis are mandatory to establish diagnosis of tubercular osteomyelitis and initiate appropriate treatment.

**CONSENT** As per international standard informed and written participant consent has been collected and preserved by the authors.

**ETHICAL APPROVAL** No ethical issues are involved in this manuscript.

## **Figure Legends**



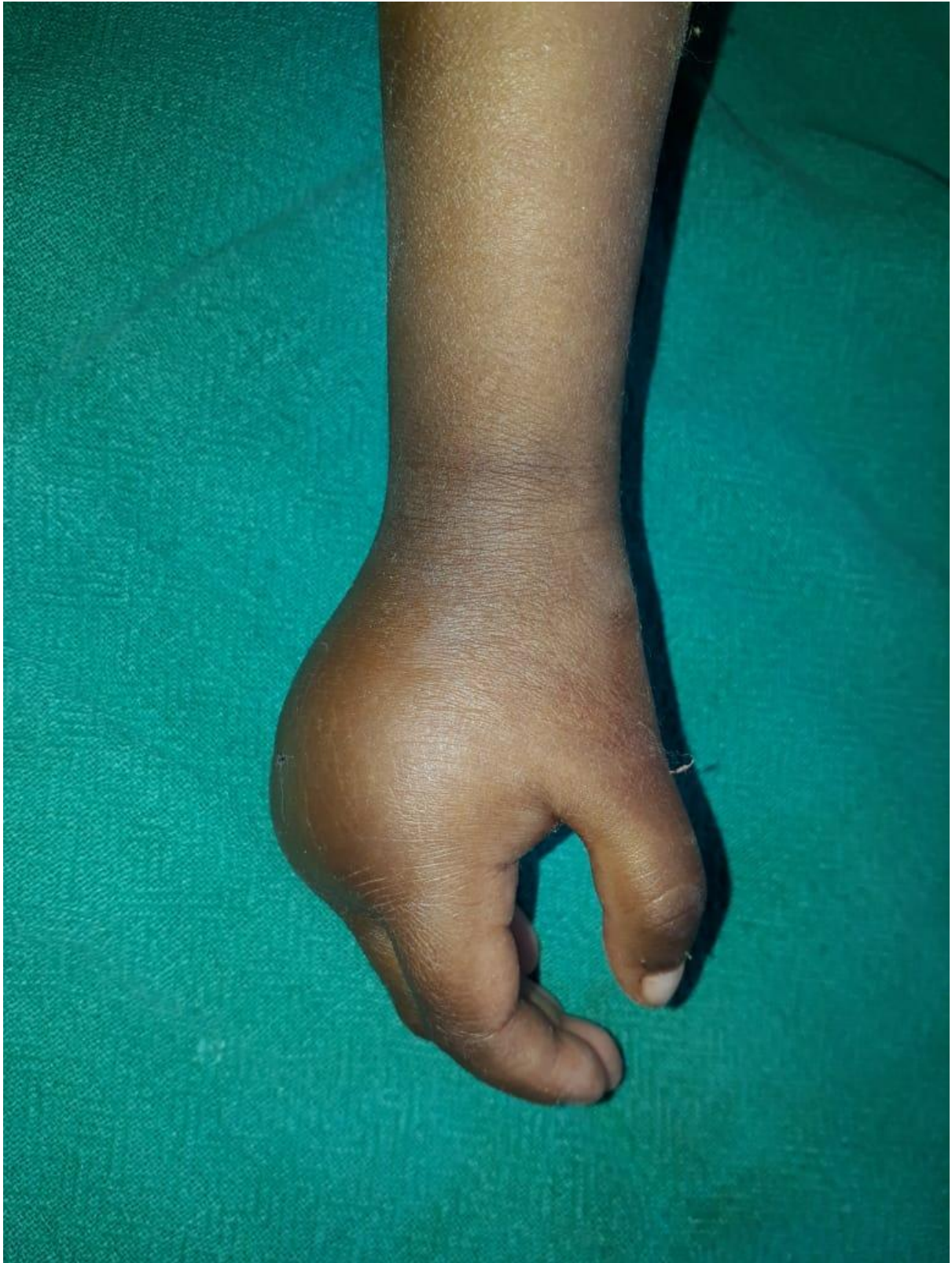

Fig.1 Clinical pic Right Hand at the time of presentation

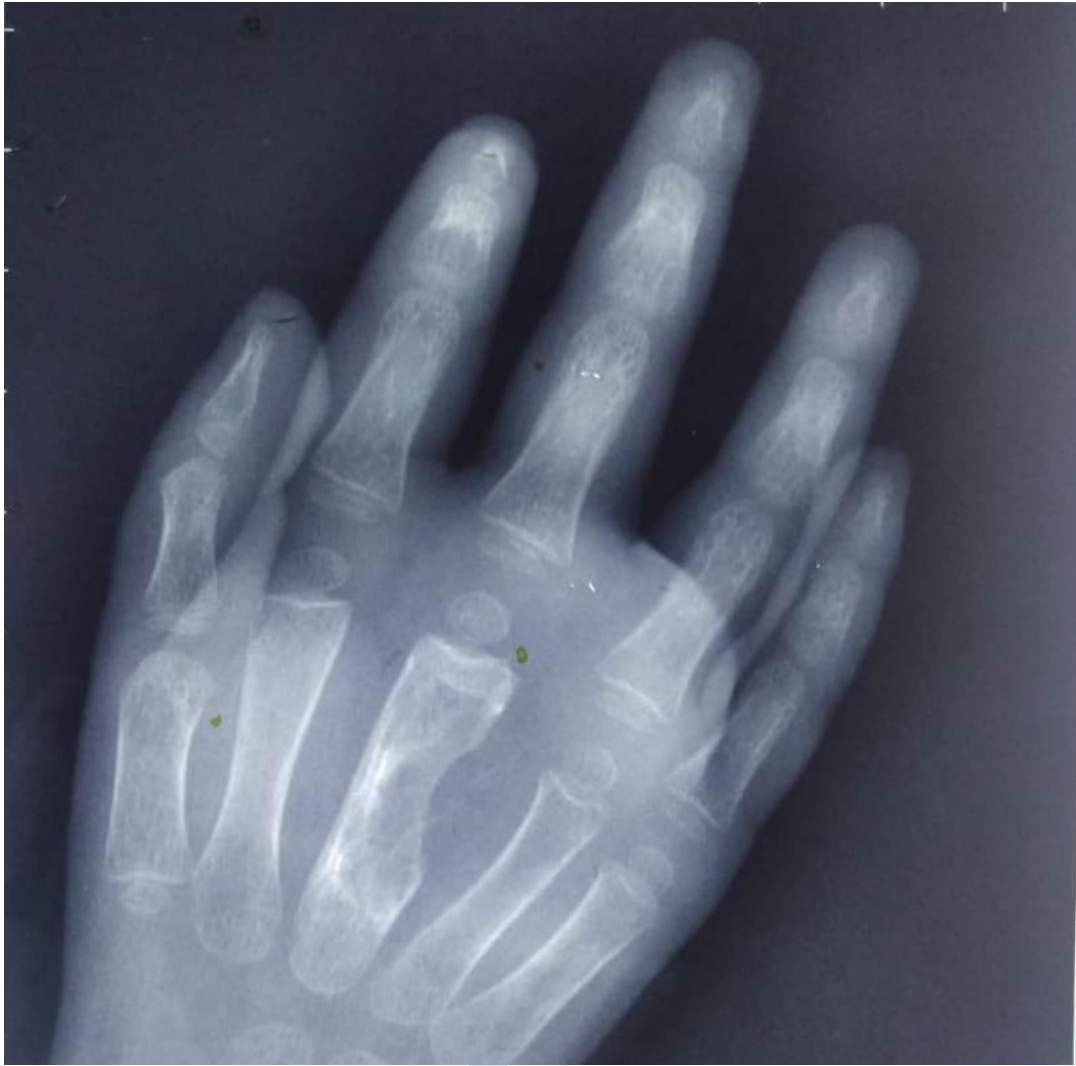

Fig.2 Radiograph showing scalloping of the 3rd metacarpal , subtle cortical irregularities and Osteopenia

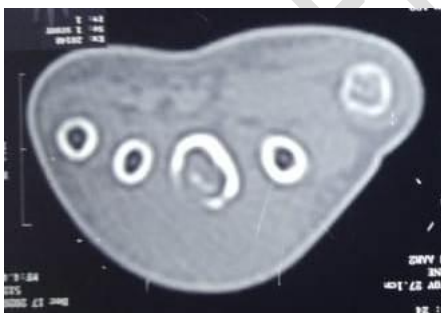
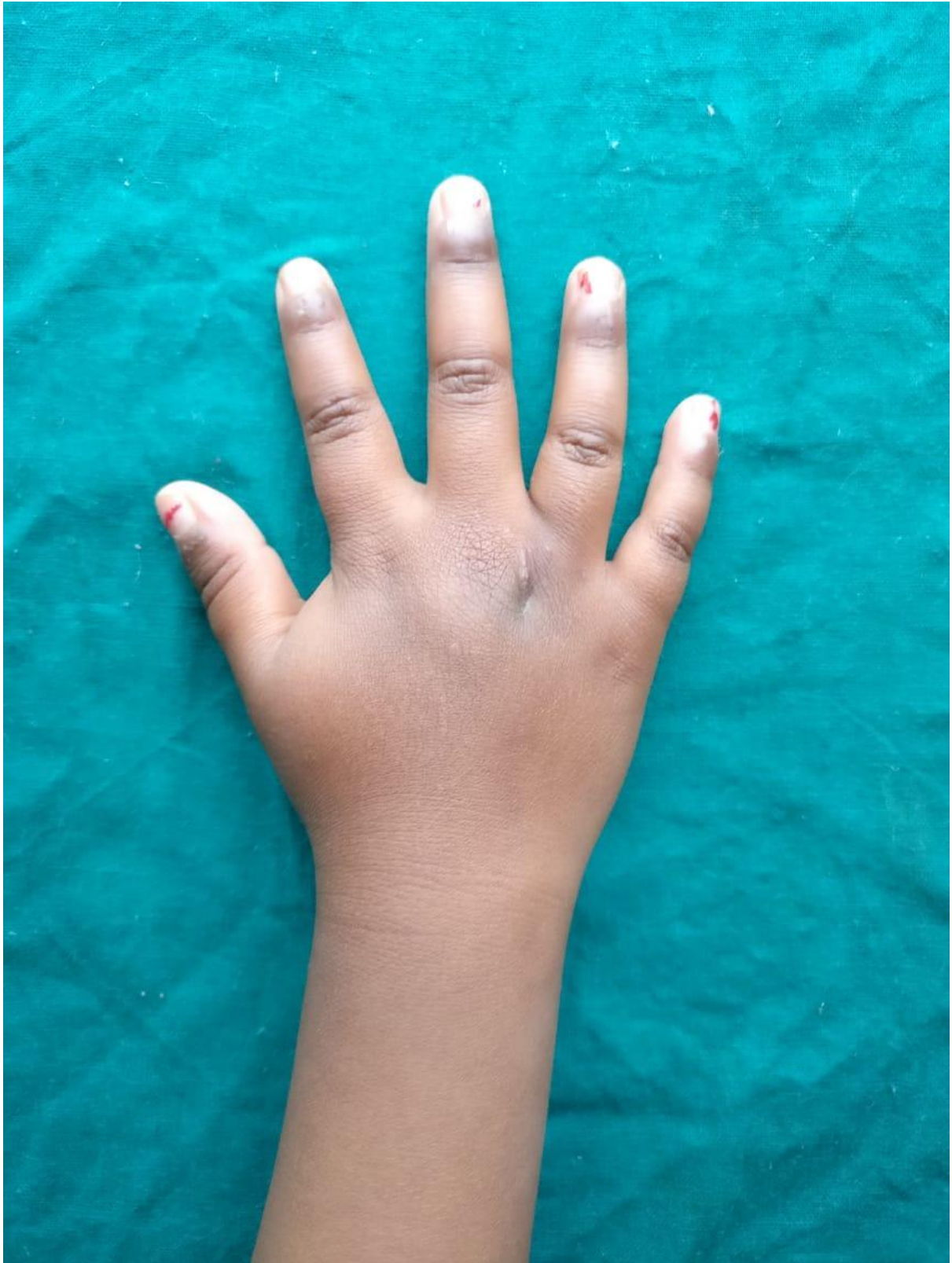
Fig.3 CT Scan showing lytic destructive area 3<sup>rd</sup> metacarpal bone, flaring of medullary cavity with destruction



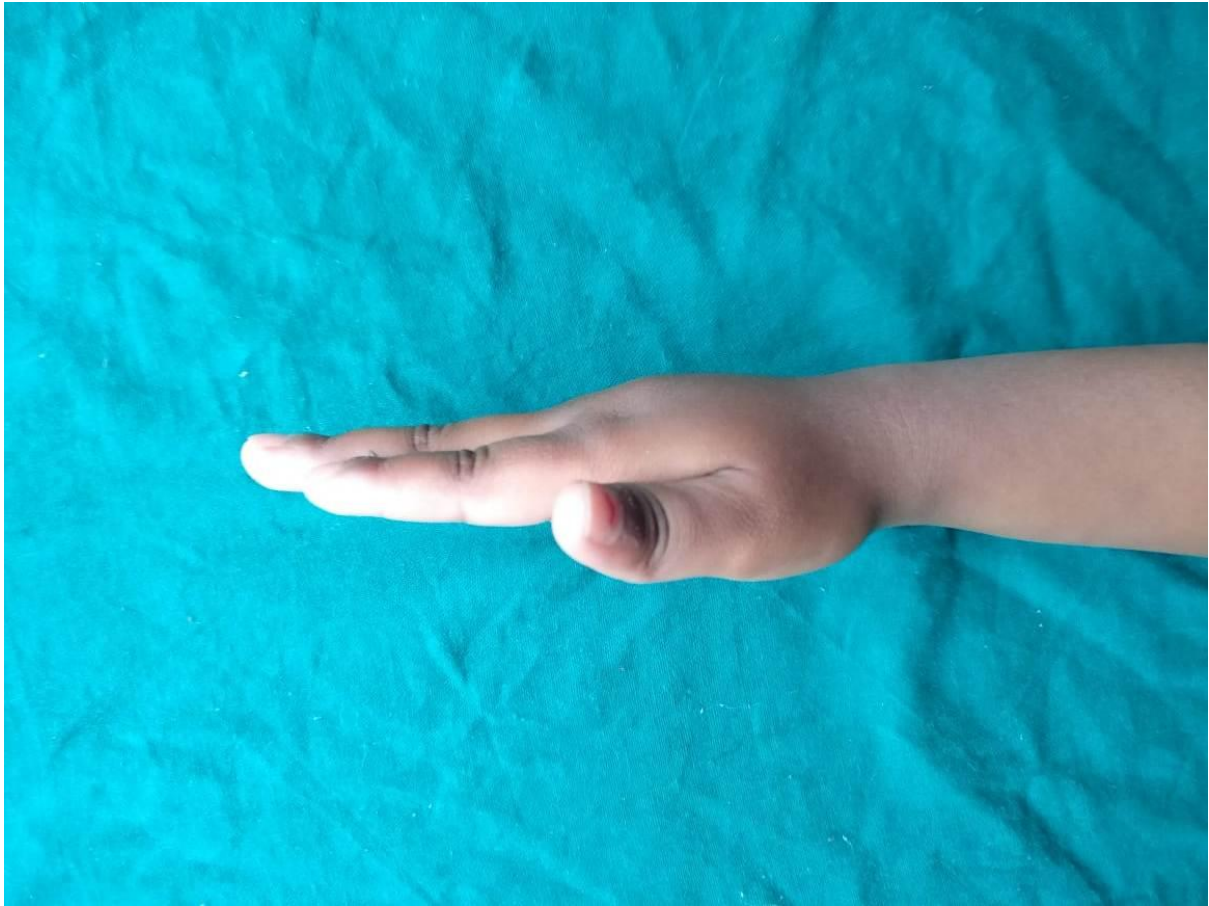


Fig.4 Clinical pics post ATT at one year

### References

1. Ahammadunny R, Rathish B, Wilson A, Warriar A. Pubic symphysis tuberculosis: A diagnostic dilemma. *Int J Mycobacteriol* 2021;10:98-100.
2. Salimpour R, Salimpour P. Picture of the Month. *Arch Pediatr Adolesc Med.* 1997;151(8): 851–852.
3. Sunderamoorthy D, Gupta V, Bleetman A. TB or not TB : an unusual sore finger. *Emergency Medicine Journal.* 2001;18:490–491.
4. Panchonia, Kulkarni CV, Meher R, Mandwariya S. Isolated tuberculous dactylitis [Spina

ventosa] in a 9 year old boy-a rare entity. International Journal of Basic and Applied Medical Sciences. 2012;2:55.

5. Jha S, Dhooria A, Jain S. Tuberculous Dactylitis: A Rare Form of Skeletal Tuberculosis. J Clin Rheumatol. 2020 Aug;26(5):e93.

6. Index TB Guidelines. Available from : [http://www.tbonline.info/media/uploads/documents/index-tb\\_guidelines\\_-\\_green\\_colour\\_2594164.pdf](http://www.tbonline.info/media/uploads/documents/index-tb_guidelines_-_green_colour_2594164.pdf). [Last accessed 2020 Dec 15].

UNDER PEER REVIEW