

EXPERIENCE OF DUAL PLATING IN DISTAL FEMUR FRACTURES

ABSTRACT

Aim of the study: Considering above pitfalls of single lateral plating we conducted a study to assess the role of dual plating.

Study Design: The study conducted is prospective in nature.

Place of Study: Department of Orthopedics, Jawaharlal Nehru Medical College and Hospital (JNMCH), Aligarh Muslim University (AMU), Aligarh.

Methodology: We conducted a prospective study from November 2018 to November 2020 on 32 patients. We included the complex extra and intraarticular fractures (A3, C2 and C3 according to the OTA classification) in our study. Standard Antero-Posterior and lateral radiographs of injured distal femur and knee joint were used. We used anterior midline in 19 and dual incision approach in 13 patients. We followed the patients clinically and radiologically for union and knee function by knee society score.

Results: Mean age of patients was 46 years (20-65 years). 21 were male and 11 were females. Mean follow up of our patient was 18 months (6-29 months). Fracture union was achieved in 29 out of 32 patients. Average time to achieve union was 9 months (6-14 months). Most of the patient's range of Motion (ROM) was 90°-135°. 24 patients obtained good to excellent results. None of them developed varus or valgus deformity.

Conclusion: Considering these covenant results we propose that dual plating is the most appropriate modus operandi for the treatment of the distal femur fractures.

Key words- dual plating, distal femoral fracture, intraarticular, varus collapse.

*Abbreviations

- 1- DFLCP- Distal Femoral Locking Compression Plate
- 2- AO/OA- Arbeitsgemeinschaft fur Osteosynthesfragen
- 3- ROM- Range of Motion
- 4- AP- Antero-Posterior
- 5- KSS- Knee Society Score
- 6- DCU- Dynamic Compression Unit
- 7- RTA- Road Traffic Accident
- 8- FFH- Fall from Height
- 9- FOG- Fall on Ground
- 10- GA- Gustilo Anderson
- 11- ITBS- Iliotibial Band Syndrome
- 12- DVT- Deep Vein Thrombosis
- 13- UTI- Urinary Tract Infection
- 14- ABP- Angled Blade Plate
- 15- DCS- Dynamic Condylar Screw
- 16- PCL- Posterior Cruciate Ligament
- 17- CPM- Continuous Passive Motion

INTRODUCTION

The world is progressing over a rapid speed leading to a massive development in the field of automobiles and land and buildings. But every facet has its own pros and cons.

Although these advancements have made our life easier, but it has led to higher cases of road traffic accidents and construction sites accidents devastating many lives. Most of these patients are young individuals. The older patients sustaining these types of injuries are osteoporotic that too mostly of the female gender. There is a bimodal¹ distribution of the fracture of the distal femur.

The distal femoral fractures pose considerable challenge to the orthopedic surgeon. These injuries particularly those extending into the knee joint lead to considerable functional impairment. They account for 6%² of all femur fractures.

Despite the recent advancements in techniques and implants, the treatment of intra-articular multi-fragmentary distal femoral fractures remains a tedious task. The management of these fractures present many difficulties due to the factors like, severe soft tissue damage, fracture extending into the knee joint, marked comminution at the fracture site and injury to the quadriceps mechanism³.

Long-term disability can occur in patients with extensive articular cartilage damage and marked comminution. Fracture shortening with extension and varus deformities of the distal articular surface is a typical presentation⁴.

A variety of nails and plates have been recommended in the past for the fracture of the distal femur. Although intramedullary devices, blade plates and dynamic condylar screws with side plates were commonly used, condylar buttress plates are more useful for very distal fractures and those with intraarticular comminution^(5,6,7).

At present the fractures of the distal femur are treated using Distal Femur Locking Compression Plate (DFLCP). It has the advantage of combination of compression plating, locked plating and bridge plating. It results in reduction in soft tissue damage and preserves the periosteal vessels⁸.

Single lateral plating of the distal femur fractures high failure rates⁹. A medial plate in conjunction with the lateral plating reduces the chances of failure of fixation⁹. This article focuses on the advantages of dual plating of the distal femur fractures.

MATERIALS AND METHOD

The study was a prospective one. 32 patients of the fracture of the distal femur were taken in our study from August 2016 to September 2019. They were all managed by dual plating of the distal femur. The study was permitted by the ethical committee of our institution.

The inclusion criteria were patients having A3, C2 or C3 fracture of the distal femur according to the OA classification, closed or compound grade I or II according to the Gustilo Anderson classification, low condylar fractures and fractures less than 3 weeks old. The exclusion criteria were compound grade III(B&C), other ipsilateral fractures and pathological fractures.

There were no intermediate procedures. Dual plating was the only procedure done both in the closed and open injuries be it Grade I or Grade II.

Standard Antero-Posterior and Lateral radiographs of the injured distal femur with the knee joint was taken. Oblique and tractional radiographs were taken, if needed for better understanding of the fracture geometry. CT scan with 3D-reconstruction was done if needed.

SURGICAL TECHNIQUE

After obtaining informed consent and anesthetic fitness the patient was taken up for the procedure. All the procedures were taken under spinal anesthesia.

The surgery was performed in supine position with the knee in 30° flexion and further flexion was done as per the surgical need. The use of tourniquet was entirely surgeon dependent.

APPROACH

There were two approaches, the dual incision approach and a single incision approach.

ANTERIOR APPROACH

The single incision approach utilized anterior medial or lateral parapatellar approach depending upon the surgeon's choice and the type of fracture. A single midline incision and extended medial or lateral parapatellar approach was used by Imam et al. for the fixation of the C3 type of distal femur fractures³.

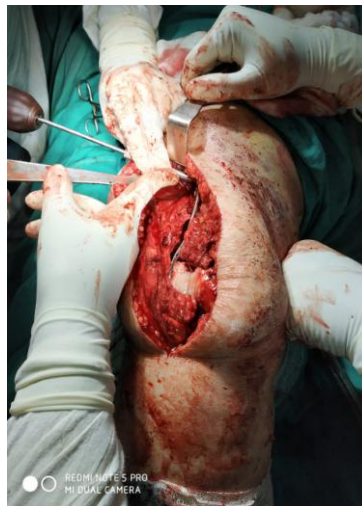

FIG 1: Anterior parapatellar approach

DUAL INCISION APPROACH

A direct lateral approach (Fig 2) was made with the skin incision longitudinal and distally centered over the lateral epicondyle. The length of the incision was determined based upon the extent of the fracture.

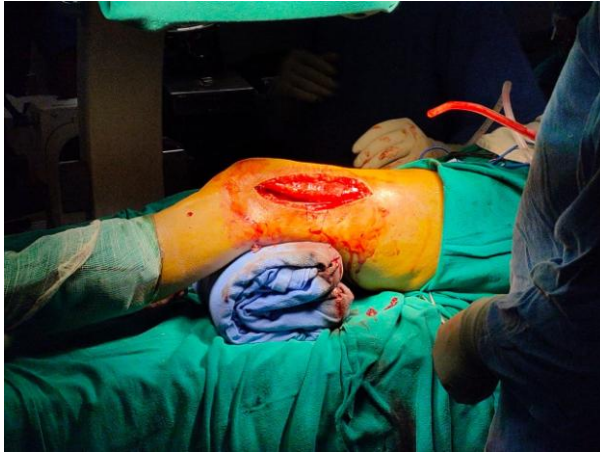

FIG 2: Lateral incision

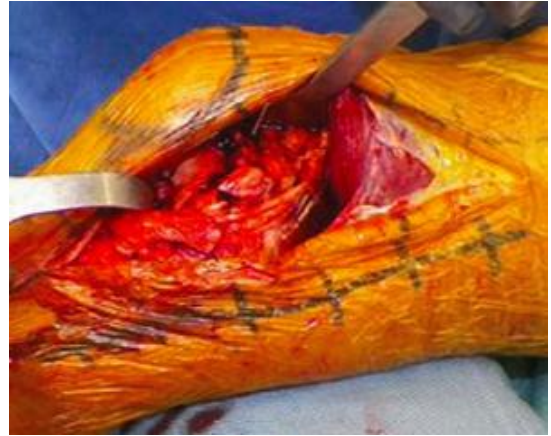

FIG 3: Medial incision

For the medial approach (Fig 3) a straight medial skin incision was made over the adductor tubercle and extended proximally into the distal thigh.

Steinberg et al. utilized dual incision for the double plating approach in the fracture of the distal femur⁹.

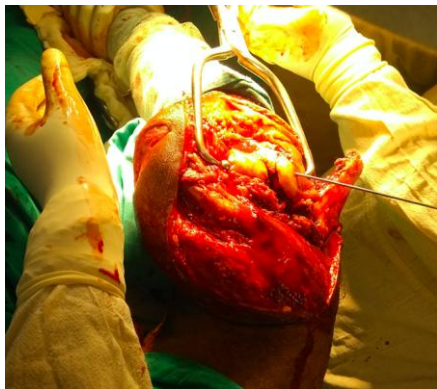

FIG 4: Use of pointed clamp

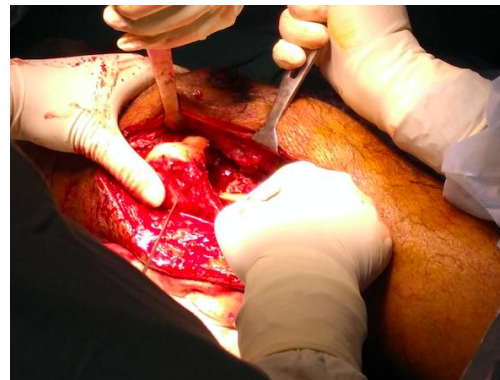

FIG 5: Use of K-wire

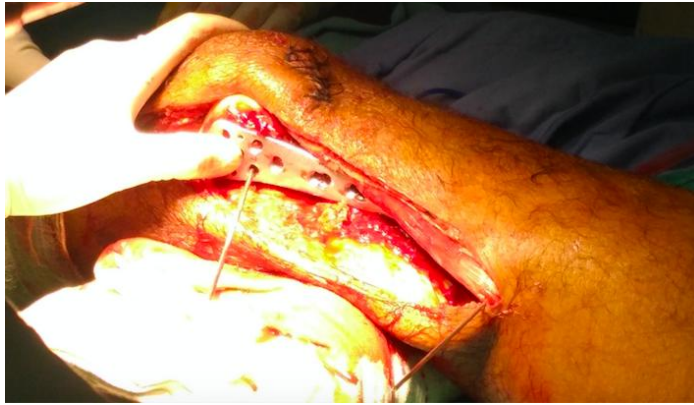

FIG 6: Lateral plate application

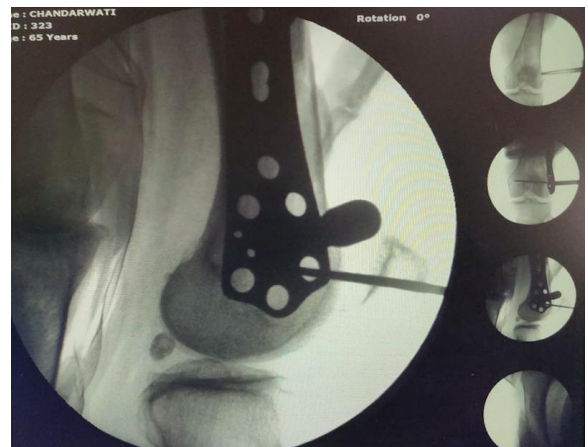
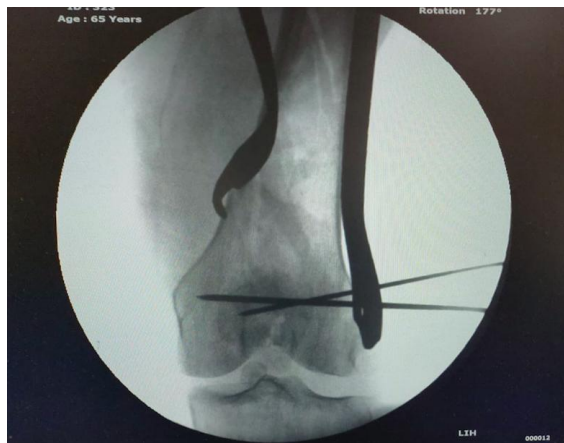

FIG 7: Intraoperative AP and Lateral fluoroscopy

Intraoperative fluoroscopy (Fig 7) was checked to insure adequate reduction of the fracture fragments and congruency of the articular margin.

After the placement of the screws when the adequate reduction was achieved locking screws were inserted.

Finally, the medial plating (Fig 8) was done by the plane as described above.

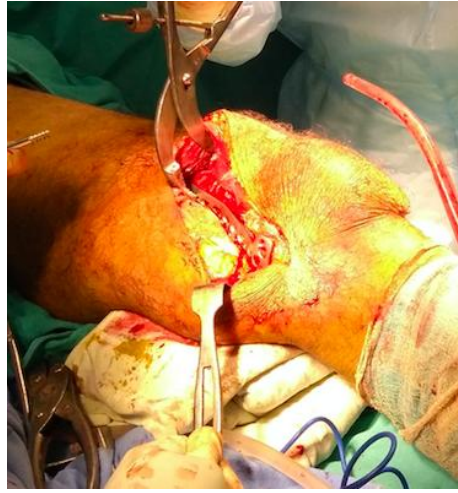

FIG 8: Medial plate application

Final reduction was achieved and confirmed under fluoroscopy (Fig 9).

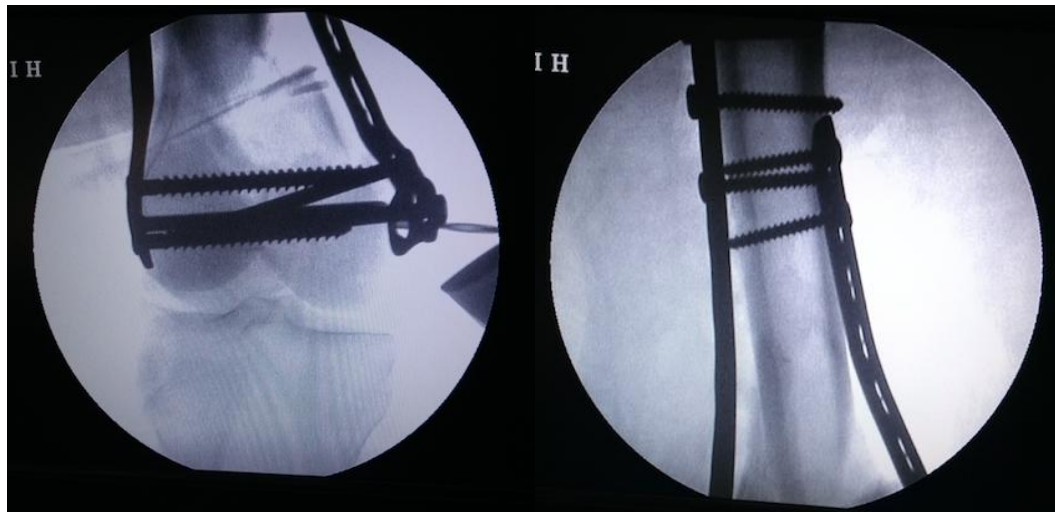


FIG 9

POST OPERATIVE CARE

All the patients were either given a posterior long leg slab or knee brace for at least two days for adequate soft tissue healing and to alleviate the pain. Early knee physiotherapy was initiated and full range of motion was tried to achieve as much as the patient could tolerate. Weight bearing was allowed according to the clinical and radiological findings on subsequent follow up visits. The patients were followed at 4 weeks interval for the first 3 months, at 6 weeks for the next three months and then at three months intervals till the final follow up. Radiographic healing was confirmed by the union of the three cortices of the bone on the antero-posterior (AP) and lateral radiographs. Clinical healing was confirmed by the absence of pain on weight bearing or application of stress over the injured site on examination and grading was done according to the **Knee Society Score** (Table IV). Rotation was checked by comparing with the opposite normal limb.

CHOICE OF IMPLANTS

For the lateral condylar fragment, a distal femoral locking plate (DFLP) is used (Fig 10). These are anatomically contoured locking plates creating a fixed angle construct that improves fixation. There is multiple screw fixation in the femoral condyle. Threaded holes in the plate head accepts 6.5mm of cancellous locking screws. Combi holes combine a Dynamic Compression unit (DCU) with a locking screw hole, which allows flexibility of axial compression and locking capability throughout the plate length. The plate shaft accepts 4.5mm simple cortical and 5.0 mm locking cortical screws.

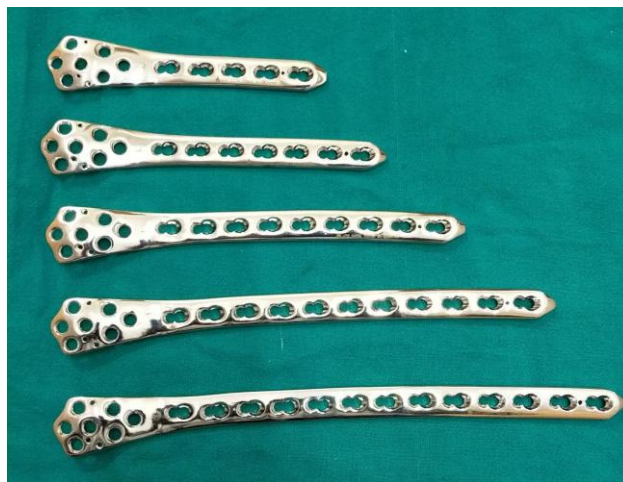

FIG 10: DFLP



FIG 11: T-plate




FIG 12: Recon plate

For the medial buttressing either T-plate or recon plate was used. The plate was bended intraoperatively using a plate bender to prepare a contour best fitting the geometry of the fracture and also maintaining the joint congruency. Till now there is no consensus drawn as to which plate to be used for the medial condyle fragment nor are there any specially designed

plates for the same. Imam et al.³ used proximal tibial plate in ten cases and distal tibia plate in six cases in their study of double plating of intra-articular multi-fragmentary C-3 type of distal femoral fractures through the anterior approach.

RESULTS AND OBSERVATIONS

This was a study utilizing 32 patients (21 M and 11 F), with a mean age of 46 years ranging from 20 to 65. Some of the patients' particulars are summarized in table I.

	OA Classification			GA Classification			Limb		Mode of Injury		
	A3	C2	C3	closed	Gr I	Gr II	R	L	RTA	FFH	FOG
No of Patients	9	7	16	21	4	7	18	14	29	1	2

Table I (GA- Gustilo Anderson; R= right, L= left; RTA= road traffic accident, FFH= fall from height, FOG= fall on ground)

APPROACH	NUMBER
Anterior midline	19
Dual incision	13
IMPLANT	
Lateral - DFLCP	32
Medial	
T-plate	29
Recon plate	03

Table II

Amongst the 32 patients; 9 were of type A3, 7 of C2 and 16 of C3 according to the OA classification. 21 were closed, 4 of Grade I and 7 of Grade II according to the GA classification. Most common mode of injury was RTA. 29 patients fell in this group. 1 sustained injury due to fall from height and 2 due to fall on ground. Talking about the surgical approaches; anterior midline approach was used in 19 patients and dual incision approach in the rest 13 patients.

We had a total of 11 open injury comprising (34.4%) of the total cases. 4 were of GA I and 7 were GA II. All the grade I and grade II open injuries were operated the same day under the intravenous antibiotic coverage. Amongst the open injuries there were none of grade III nor were any injuries with gross contamination. Dual plating was used in all these fractures from the very beginning. The risk of infection was evaluated by the presence of wound dehiscence around the incision margin, any discharge from the wound, soaking of the dressings and fever. There was a total of 5 patients who had such episodes, 2 were of Grade I and the other 3 of Grade II open injuries. Fortunately, only one of our patients had deep infection. None of the closed fracture patients showed such episodes.

Mean duration between injury and fixation was 7 days ranging (1-15) days. Mean duration of surgery was 110 minutes ranging (90-150) mins. Mean amount of blood loss was 500ml ranging (350-800) ml.

The follow up time of our cohort ranged from 6 to 29 months with a mean of 18 months. Union was achieved in 29 patients, 2 patients required autologous bone grafting in later surgery and 1 had non-union due to deep infection. Mean duration of union was 6 months.

Range of motion exercises were started after 2 days post op. Our aim was to attain 90° of flexion by stitch removal averaging 14 days post op. After 14 days the wound was examined and when there were no chances of wound dehiscence further Range of Motion (ROM) exercises were started. 9 patients attained the ROM beyond 135°. Most of the patients numbering 22 fell in the ROM of (90-135°). 1 patient had a ROM less than 45° as he presented late to our side because he had head injury and couldn't strictly follow the commands. He subsequently developed stiff knee with just a jog of movement. There was no extension lag seen in our cohort. Mean ROM was 120 degrees.

Variables	Studied cohort (n=32)
Operative time (min)	
Mean	110
Range	(90-150)
Blood loss	
Mean	550ml
Range	350-800
Complications	
None	26(81.25%)
Superficial infection	3(9.3%)
Deep infection	1(3.1%)
Stiff knee	1(3.1%)
ITB syndrome	1(3.1%)
Follow up (months)	
Mean	18
Range	6-29

Table III

Functional assessment was done according to the knee society score (KSS). Score in the range of (80-100) was considered Excellent, in the range of (70-79) as Good, in the range of (60-69) as Fair and that below 60 as Poor.

7 patients showed excellent result (21.8%), 17 showed good result (53.2%), 5 showed fair (15.6%) and 3 (9.4%) showed poor result.

PAIN	
None	50
Mild or occasional	45
Stairs only	40
Walking and stairs	30
Moderate	
Occasional	20
Continual	10
Severe	0
RANGE OF MOTION	
5°=1 Point	25
STABILITY	
Antero-posterior	
< 5 mm	10
5-10 mm	5
10 mm	0
Medio-lateral	
< 5°	15
6-9°	10
10-14°	5
> 15°	0
Total positive points	[+]
DEDUCTION POINTS	[-]
Flexion Contracture	
5-10°	2
11-15°	5
16-20°	10
> 20°	15
Extension lag	
< 10°	5
10-20°	10
>20°	15
Alignment	
5-10°	0
0-4°	3 points each degree
11-15°	3 points each degree
Other	20
Total negative points	[]
TOTAL KNEE SCORE	[]

Table IV: KNEE SOCIETY SCORE (KSS)

There were no varus or valgus deformity seen in our study. This evaluation was done using scanogram of the bilateral lower limbs and comparing the mechanical and anatomical axes of both the sides. Nor were there any hardware failure or intra-articular penetration. There were 4 superficial infections which were managed by simple iv antibiotics and dressings. There was

1 deep infection which was initially managed by debridement and iv antibiotics but later turned into nonunion. There was 1 Iliotibial Band Syndrome (ITBS).

CASE

This figure is showing the x-rays and clinical pics of a male of age 20yrs who had a 33C2 type of fracture of the distal femur according to the OA classification. The patient was operated in the emergency on the very same day he sustained injury. Dual plating was done by the anterior incision approach. The patient achieved full ROM by 6 weeks post op and complete radiological union by 20 weeks. There was no shortening or any limp.

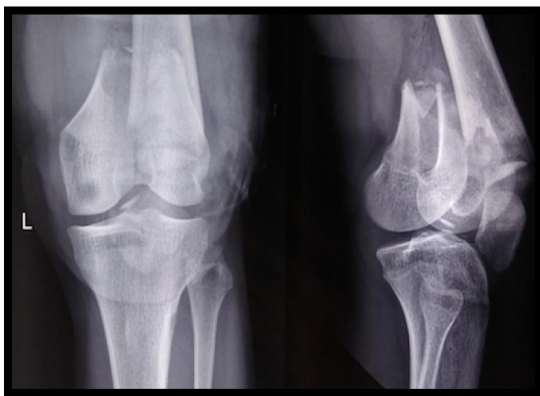


FIG 13: PRE-OPERATIVE

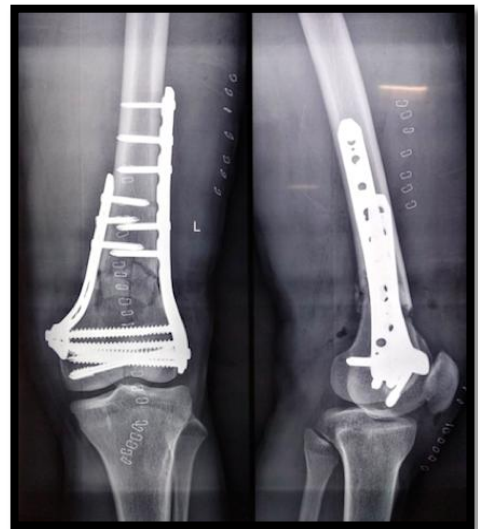

FIG 14: POST-OPERATIVE

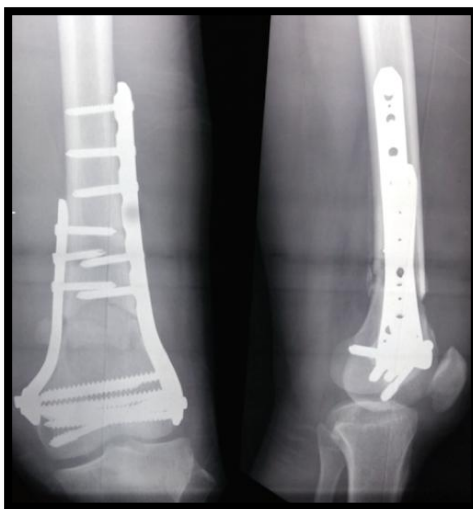

FIG 15: 6 WEEKS POST OP

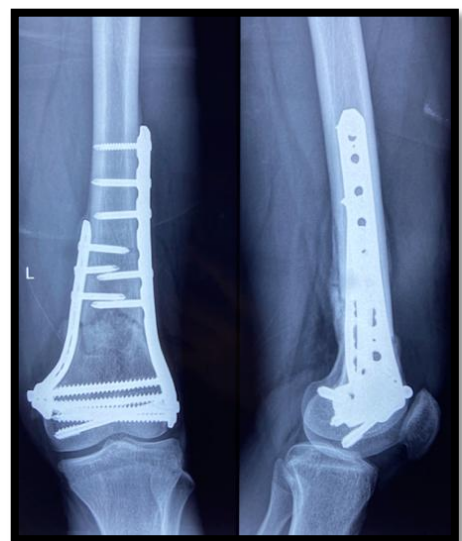

FIG 16: 20 WEEKS POST OP

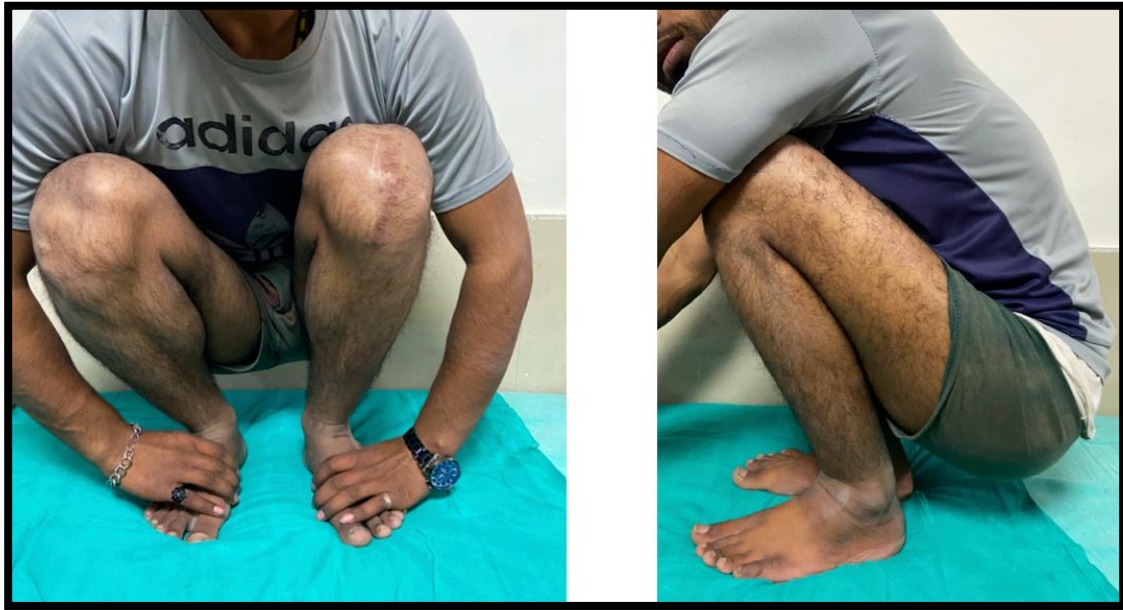

FIG 17 & 18

DISCUSSION

Fracture of the distal femur pose a considerable challenge for the orthopedic surgeon. Till date there hasn't been a single surgical technique or a single type of implant which could address all the needs. There are many factors which come into play while considering these types of fractures. These include patient's age, the bone quality, the extent of soft tissue injury, the amount of comminution, the type of instrument to be used and the most importantly the articular involvement⁹.

Although nonoperative treatment was the treatment of choice prior to 1970, its use now is reserved for a few situations: reliable patients with minimally displaced fracture, in non-ambulatory patients (e.g., paraplegia), in patients with significant underlying medical diseases. Nonoperative treatment of a displaced distal femur fracture includes closed reduction with skeletal traction with or without subsequent cast bracing¹⁰.

Early attempts at internal fixation of distal femur fractures were associated with a high incidence of malunion, nonunion, and infection. Because of these poor early operative results, numerous authors concluded that nonoperative methods were preferable. For example, Neer et al. reviewed a large series of supracondylar fractures and reported in 1967 good results in 84% of patients treated nonoperatively, but only 54% good results in surgically treated patients¹⁰.

Only one study, published by Butt et al. in 1996, has assessed nonoperative versus operative treatment for distal femur fractures. The results overwhelmingly favored operative treatment with a threefold decreased risk for complications of immobilization (DVT, UTI, pressure sores, and pneumonia) and a 33% risk reduction for poor results¹⁰.

In the 1970s and early 1980s, distal femur fractures were most commonly treated with an anatomically contoured, but angularly unstable (non-locking) distal femur plate (e.g., condylar buttress plate). Relatively high complication rates were reported, which adversely affected clinical results, including infection, nonunion or delayed union, malunion (especially varus collapse), the need for bone graft, and knee stiffness owing to delayed mobility¹¹.

Later there were also advances in plate-screw design. Fixed angle implants such as the 95-degree angled blade plate (ABP) and dynamic condylar screw (DCS) provided drastically improved stability compared to prior implants. When these two methods were combined, they dramatically improved the rates of bone healing with fewer complications. However, insertion of these implants was technically demanding limiting their widespread use¹².

More recently, “locked plating” systems have been developed in which screws are inserted that lock into the plate, forming a fixed angle construct. Condylar fixation with locking screws is mechanically superior to earlier implants (e.g., blade plate or DCS) by spreading out fixation points among a number of screws. A variety of other plating systems have since been developed that offer additional advantages including better anatomic contouring, improved fixation in the condylar segment, and options for conventional screws, bi-cortical or uni-cortical solid locking screws, and cannulated nonlocking or locking screws. The mechanics of fracture healing using these implants are better but still incompletely understood and surgeons are investigating novel ideas for optimizing this mechanical environment by modulating the degree of stiffness and mobility in the fixation construct¹².

Most of the published studies on lateral locking plate have reported a union rate ranging from 81%-95%^{21,22,23,24,25}. The complications related to implants including loosening, breakage and rotational malposition, were reported as being between 5% to 7% with a revision rate between 19% to 23%^{24,25}. Some other potential problems were regarding the plate positioning, like the plate placed too ventral, too proximal or too short²⁴ which may weaken the mechanical stability leading to early implant loosening and failure.

Comparing the two approaches of dual plating intra-op, it was the anterior approach which had a better visualization of the fracture geometry, less tiring for fracture reduction, had less amount of blood loss. It allows better visualization of the anterior and lateral walls of the femur and prevents medial dissection. Additional two plates can be placed by a single incision in a 90° angle to each other. The concept is somewhat similar to the distal humerus plating.

It is essential to orient the plate properly to the joint on the anteroposterior projection. The plate sits at an inclined angle on the lateral femoral cortex matching the shape of the femur. If this is not recognised the distal screws will aim anteriorly and penetrate the patellofemoral

joint. Proximally, it is essential that the plate sits along the mid-axis of the shaft and not too anterior or posterior, which is a common error in percutaneous plating. The number of screws and their configuration are controversial³. Distally we preferred to use as many locked screws as possible in our construct. Proximally, we preferred a near–far pattern of locked screws, with a total of at least five or six screws.

Double plating utilizing the anterior medial parapatellar approach delivers superb visualization and permits controlled access to the distal femur while minimizing inadvertent stripping of the medial side³.

The only difficulty that we encountered was the decreased ROM at knee. These types of fractures are caused by high velocity trauma with resultant muscular and capsular injury causing extensive adhesions of the quadriceps mechanism^{13,14,15,16}. These results are probably attributed to the high energy nature of these injuries and resultant soft tissue damage. The application of medial plate which necessitated additional dissection of soft tissues also contributed to the contractures at knee.

The double-plating technique may overcome the complications encountered in single lateral plating by its properties that provide increased stability by compensating for some of the intraoperative technical errors to permit complete healing⁹.

Study	Year	No of patients	Type (Fracture)	Approach	Implant	Union	Result
Sanders et al	1991	9	C2, C3	Dual incision	Condylar buttress plate	100%	55.56% Good
Ziran et al	2002	36	C2, C3	Anterior lateral parapatellar	Condylar/blade plate & Dynamic comp/Recon plate	73%	–
Ayman et al	2012	12	C3	Modified Olerud Extensile	DFLP & Recon/Semi-tubular plate	100%	58.4% Excellent-Good
Steinberg et al	2017	32	A3, C1, C2, C3	Dual incision	DFLP & T-plate/Recon plate	93.7%	-
Imam et al	2017	17	C3	Ext Medial parapatellar	DFLP & T-plate	93.8%	68.8% Excellent-Good
Metwaly et al	2018	23	A3, C1, C2, C3	Anterior midline	DFLP	100%	-
My Study	2021	32	A3, C2, C3	Anterior midline and dual incision	DFLP & Recon/T plate	90.6%	75% Excellent-Good

Table V

Various studies have shown that dual plating of the distal femur has given promising results. Sanders et al¹⁷ studies the cases of nine patients who had a complex fracture of the distal femur and a deficient medial-cortical buttress. Stable fixation was not achieved by the single lateral condylar buttress alone. Collapse of the distal fragment into varus angulation was noted intra-operatively. Additional stabilization with a medial plate and a bone graft from the iliac crest was applied in all nine patients. At an average duration of twenty-six months of follow-up all the fractures healed. Most of the patients had the arc of motion at knee from 90° to 100°.

Thirty-two patients (26 females and 6 males, mean age 76 years, range 44–101) were included in the study by Steinberg et al⁹. Eight of them had a periprosthetic stable implant fracture and two patients were treated for nonunion. All fractures, excluding one that needed bone grafting and one refracture, healed within 12 weeks. One patient needed bone grafting for delayed union and one patient needed fixation exchange due to femur re-fracture at the site of the most proximal screw. Two patients developed superficial wound infection and one patient required medial plate removal after union due to deep infection.

In a prospective study done by Imam et al³ sixteen patients were reviewed with supracondylar femoral fracture type C3, according to Müller long-bone classification system and its revision OA/OTA classification. These were treated using dual plating through extended anterior approach and bone grafting. The mean time of complete radiological union in the studied population was 6.0 ± 3.5 months with a range of 3–14 months. They have not observed postoperative varus or valgus deformity in our cohort. The majority (68.75%) of the studied patients showed significant improvement in range of motion (90°–120°) during follow-up. Eleven out of sixteen patients (68.75%) had well-to-excellent functional outcome. Poor outcome was reported in only two patients (12.50%).

Ziran et al¹⁸ gave a study about thirty-five patients with 36 displaced distal femoral fractures (16 AO-type C2 and 19 AO-type C3). They were treated with an anterior approach and double plating and followed for an average of 7 (3–44) months. They used a longitudinal anterior incision to minimize stripping of the medial femur side, and two plates were placed orthogonally oriented. They also used a lateral condylar or a buttress plate and an anterior reconstruction or dynamic compression plate and reported uneventful healing within 16 weeks in 24 out of 36 reported patients.

Khalil and Ayoub¹⁹ reviewed about twelve patients with closed C3-type injuries. Mechanism of injury was road traffic accident (RTA) in nine patients and fall from height in the other three cases. Eight cases were operated during the first week and four cases during the second week after injury. Mean follow-up was 13.7 months (range 11–18 months). Mean radiological

healing time was 18.3 weeks (range 12-28 weeks), and all cases had good radiological healing without recorded non-union or malunion. Clinically, two cases (16.7 %) had excellent results, five cases (41.7 %) had good results, three cases (25 %) had fair results, and two cases (16.7 %) had poor results. No cases developed skin necrosis, deep infection, bone collapse, or implant failure. However, two cases (16.7 %) had limited knee flexion to 90° and required subsequent quadricepsplasty.

In a biomechanical study on synthetic bone that was done by Prayson et al²⁰ they reported that supplementation of the medial column by medial plate must be considered to prevent varus collapse, especially in highly comminuted metaphyseal fractures with bone loss.

There were some hurdles in our surgical procedure. We found it difficult to reduce the comminuted intra-articular C3 types of fractures. We often found difficulty for the placement of medial plate in C3 types of fractures, so had to adjust the plate accordingly. The placement of screw for the medial Hoffa's along with the C3 fracture was a cumbersome task.

CONCLUSION

Dual plating is an efficient method for the stabilization of the distal femur fractures. The addition of a medial buttressing plate, besides providing with a rigid fixation also maintains the bone alignment and prevents any varus or valgus deformities. Especial emphasis should be given to active knee physiotherapy in post op. The patient should be switched to Continuous Passive Motion (CPM) machine as soon as it is realized that no further flexion is being carried out by the patient.

ACKNOWLEDGEMENTS

It is a genuine pleasure to express my deep sense of thanks and gratitude to my mentor **Prof. Aamir bin Sabir**. His dedication and keen interest, above all, his overwhelming attitude towards me had been solely and mainly responsible for completing my work. His timely advice, meticulous scrutiny, scholarly suggestions and scientific approach have helped me to a very great extent to accomplish this task.

I owe a deep sense of gratitude to **Dr. Mohd Faizan** for his keen interest on me at every stage of my research. His prompt inspirations, timely suggestions with kindness, enthusiasm and dynamism have enabled me to complete my thesis.

COMPETING INTERESTS

Authors have declared that no competing interests exist.

AUTHOR'S CONTRIBUTIONS

Prof. Aamir and Dr. Faizan operated on the patients. Dr. Sohaib collected and analyzed the data of the patients prior to the surgery as well as after it and drafted the manuscript. All authors contributed to manuscript revisions. All authors read and approved the final manuscript and agree to be held accountable for the contents therein.

CONSENT

SDI Patient Consent Form 1.0					
Date: <u>20/06/2021</u>					
Place: <u>Aligarh, UP, India</u>					
+					
Name of the Journal	Asian Journal of <u>Orthopaedic</u> Research				
Title of the article	Experience of Dual Plating in Distal Femur Fractures				
Name of the Authors	Dr Mohammad <u>Sohaib</u> , Haider (corresponding author), Prof Aamir bin Sabir Dr <u>Mohd faizan</u>				
Patient's name:	<u>Arif</u>				
□					
<p>I give my consent for this material to be published in the <u>above mentioned</u> journal and associated publications without limit on the duration of publication.</p> <p>I understand that the material will be published in the <u>above mentioned</u> journal will be included in any reprints of the published article. I understand that my name will not be included in the published article, and that every effort will be made to keep my identity anonymous in the text and in any images. However, I understand that complete anonymity and control of all uses cannot be guaranteed.</p> <p>I have been offered the opportunity to preview the material in the format it will eventually appear and I am satisfied with it.</p> <p>Signed: <u>Arif</u>.....</p> <p>Full Name of the <u>Patient</u>: <u>Arif</u> Khan.....</p> <p>Alternative:</p> <p>Signed:.....</p> <p>Full name of the relative:</p> <p>Relation:.....</p> <table border="1"><tbody><tr><td>Patient's Name and contact address</td><td><u>Arif</u> Khan, house no: 345, patwari ka <u>bagla</u>, <u>Aligarh</u>, UP, India</td></tr><tr><td>Corresponding author's name and contact address</td><td>Mohammad <u>Sohaib</u>, Haider Flat A2, first floor, Green view apartment, <u>Dhorra</u>, Aligarh, UP</td></tr></tbody></table>		Patient's Name and contact address	<u>Arif</u> Khan, house no: 345, patwari ka <u>bagla</u> , <u>Aligarh</u> , UP, India	Corresponding author's name and contact address	Mohammad <u>Sohaib</u> , Haider Flat A2, first floor, Green view apartment, <u>Dhorra</u> , Aligarh, UP
Patient's Name and contact address	<u>Arif</u> Khan, house no: 345, patwari ka <u>bagla</u> , <u>Aligarh</u> , UP, India				
Corresponding author's name and contact address	Mohammad <u>Sohaib</u> , Haider Flat A2, first floor, Green view apartment, <u>Dhorra</u> , Aligarh, UP				

ETHICS APPROVAL

D.No. 242 /FM

D/O Orthopaedic Surgery

Dated: 11-12-2019

R. No. 889

Dated: 27/2/2021

INSTITUTIONAL ETHICS COMMITTEE


CERTIFICATE

Faculty of Medicine, AMU, Aligarh


ROLE OF DUAL AND SINGLE PLATING IN DISTAL FEMUR FRACTURES : A COMPARATIVE STUDY

Members of Institutional Ethics Committee examined & approved the Thesis Protocol submitted by Dr. Mohammad Sohaib Haider, MS (Orthopaedic Surgery) admitted batch 2018 under the supervision of Prof. Aamir Bin Sabir, Dept. of Orthopaedic Surgery, J.N. Medical College, AMU in the meeting held on 22.12.2018.

APPROVED



(Prof. Mohd. Shahid)
Member Secretary, IEC
MEMBER SECRETARY
Institutional Ethics Committee
Faculty of Medicine
A.M.U., Aligarh



(Prof. Rana Sherwani)
Chairperson, IEC
CHAIRPERSON
Institutional Ethics Committee
Faculty of Medicine
A.M.U., Aligarh

BIBLIOGRAPHY

1. Martinet, J Cordey, Y Harder, A Maier, M Buhler, GE Barraud. Epidemiology of fracture of distal femur. *Injury* 2000; 31: 62-63.
2. Thomas P Reudi, Richard E Buckley, Christopher G Moran. *A O Principles of Fracture Management*. 2nd edition. Switzerland: AO Publishing; 2007.
3. Imam MA, Torieh A, Matthana A. Double plating of intra-articular multi-fragmentary C3-type distal femoral fractures through the anterior approach. *European Journal of Orthopedic Surgery & Traumatology*. 2018 Jan 1;28(1):121-30.
4. Gangavalli AK, Nwachuku CO. Management of distal femur fractures in adults: an overview of options. *Orthopedic Clinics*. 2016 Jan 1;47(1):85-96.
5. Helfet DL, Lorich DG. Retrograde intramedullary nailing of supracondylar femoral fractures. *Clinical orthopedics and related research*. 1998 May 1(350):80-4.
6. Johnson KD, Hicken G. Distal femoral fractures. *The Orthopedic Clinics of North America*. 1987 Jan;18(1):115.
7. Mize RD. Surgical management of complex fractures of the distal femur. *Clinical orthopedics and related research*. 1989 March (240):77-86.
8. Egol KA, Kubiak EN, Fulkerson E, Kummer FJ, Koval KJ. Biomechanics of locked plates and screws. *Journal of orthopedic trauma*. 2004 Sep 1;18(8):488-93.
9. Steinberg EL, Elis J, Steinberg Y, Salai M, Ben-Tov T. A double-plating approach to distal femur fracture: a clinical study. *Injury*. 2017 Oct 1;48(10):2260-5.
10. Rockwood and Green's fractures in Adults - 8E (2 Volume Set) (2015) page 2236.
11. Rockwood and Green's fractures in Adults - 8E (2 Volume Set) (2015) page 2237.
12. Rockwood and Green's fractures in Adults - 8E (2 Volume Set) (2015) page 2238.
13. Chiron HS, Trémoulet J, Casey P, Müller M. Fractures of the distal third of the femur treated by internal fixation. *Clinical Orthopedics and Related Research (1976-2007)*. 1974 May 1 100:160-70.
14. CONNOLLY JF, DEHNE E, LAFOLLETTE B. Closed Reduction and Early Cast-Brace Ambulation in the Treatment of Femoral Fractures: PART II: RESULTS IN ONE HUNDRED AND FORTY-THREE FRACTURES. *JBJS*. 1973 Dec 1;55(8):1581-99.
15. Sanders R, Regazzoni P, Ruedi TP. Treatment of supracondylar-intercondylar fractures of the femur using the dynamic condylar screw. *Journal of Orthopedic trauma*. 1989 Sep 1;3(3):214-22.
16. SCHATZKER J, LAMBERT DC. Supracondylar fractures of the femur. *Clinical Orthopedics and Related Research*®. 1979 Jan 1(138):77-83

17. Sanders R, Swiontkowski M, Rosen H, Helfet D. Double-plating of comminuted, unstable fracture of the distal part of the femur. *J Bone Joint Surg* 1991 73:341–_6.
18. Ziran BH, Rohde RH, Wharton AR. Lateral and anterior plating of intra-articular distal femoral fractures treated via an anterior approach. *Int Ortho* 2002 26:370–3.
19. Khalil Ael S, Ayoub MA. Highly unstable complex C3-type distal femur fracture: can double plating via a modified Olerud extensile approach be a standby solution. *J Orthop Traumatol* 2012 13:179–88.
20. Prayson MJ, Datta DK, Marshall MP. Mechanical comparison of endosteal substitution and lateral plate fixation in supracondylar fractures of the femur. *J Orthop Trauma*. 2001;15(2):96-100.
21. Meneghini RM, Keyes BJ, Reddy KK, Maar DC. Modern retrograde intramedullary nails versus periarticular locked plates for supracondylar femur fractures after total knee arthroplasty. *J Arthroplasty* 2014;29:1503–6.
22. Kregor PJ, Stannard J, Zlowodzki M, Cole PA, Alonso J. Distal femoral fracture fixation utilizing the Less Invasive Stabilization System (L.I.S.S.): the technique and early results. *Injury* 2001;32: S-C32-41.
23. Large TM, Kellam JF, Bosse MJ, Sims SH, Althausen P, Masonis JL. Locked plating of supracondylar periprosthetic femur fractures. *J Arthroplasty* 2008;23(6 Suppl 1):115–20.
24. Schütz M, Müller M, Krettek C, Höntzsch D, Ragazzoni P, Ganz R, et al. Minimally invasive fracture stabilization of distal femoral fractures with the LISS: a prospective multicenter study. Results of a clinical study with special emphasis on difficult cases. *Injury* 2001;32:SC48–52.
25. Rodriguez EK, Boulton C, Weaver MJ, Herder LM, Morgan JH, Chacko AT, et al. Predictive factors of distal femoral fracture nonunion after lateral locked plating: a retrospective multicenter case-control study of 283 fractures. *Injury* 2014;45:554–9.