

# STUDIES ON THE **USE OF ROOT EXTRACTS OF *Triclisia subcordata* and *Hippocratea africana*** ON THE NEUROHISTOLOGY OF THE CEREBELLUM OF ADULT WISTAR RATS

---

## ABSTRACT:

**Aims:** This study was conducted to investigate the effects of *Triclisia subcordata* and *Hippocratea africana* on the histological features of the cerebellum of adult Wistar rat. **Methodology:** Twenty adults male Wistar rat with an average weight of 200 g were divided into 4 groups. Group 1 served as the control and received 5 ml kg<sup>-1</sup> of water. Group 2 animals received 150 mg kg<sup>-1</sup> body weight of ethanolic root extract of *T. subcordata*, group 3 animals received 200 mg kg<sup>-1</sup> body weight of ethanolic root extract of *H. africana*, while group 4 animals received combined ethanolic root extracts of 150/200 mg kg<sup>-1</sup> body weight of *T. subcordata* and *H. africana* orally for 7 days. The weight of the animals were confirmed prior, during and after the administration of the extracts. The brains were processed for routine histological study using haematoxylin and eosin. Representative sections were used for silver impregnation method for neuronal morphology. **Results:** There was a high significant difference ( $P = .05$ ) in the final body weights of the control group 1 and that of the test group 2 animals given 150 mg kg<sup>-1</sup> *T. subcordata* when compared to their initial weights. The body weight of group 4 animals given combined 150/200 mg kg<sup>-1</sup> *T. subcordata* and *H. africana* was however significantly ( $P = .05$ ) lower than the control after administration of the extract. There was no significant difference in body weight in group 3 which received 200 mg kg<sup>-1</sup> of *H. africana* throughout the duration of the administration. The cerebellum of all the test groups showed histopathological features including cell atrophy, pyknosis, vacuolation of oligodendrocyte with loss of Purkinje cell neurons. **Conclusion:** In conclusion, this result shows that the extract may individually and in combination cause neurodegenerative alterations in the cerebellar cytoarchitecture hence must be taken in moderation

**Keywords:** Cerebellum, *Triclisia subcordata*, *Hippocratea africana*, Wistar rats. histopathology

---

## 1. INTRODUCTION

The use of plants parts as a form of medication is an act as old as mankind. Herbs are usually used in the treatment of some common health challenges in Africa particularly in Nigeria [10]. This treatment usually involves the use of certain plant parts such as, roots, leaves, stems, flowers and rhizomes as decoctions, infusions and steam baths as a means of traditional treatment of various illnesses by both urban and rural dwellers. This is because plants are used as valued sources of food and medicine for the prevention of illnesses and maintenance of health of humans [1]. In Nigeria, interest in medicinal plants as a re-emerging health aid is fueled by the rise in cost and widespread counterfeiting of drugs used in orthodox medicine. Moreover, due to consistent scientific verification of safety and efficacy, herbal products are more acceptable than ever before [19].

*Triclisia subcordata* and *Hippocratea africana* are examples of herbs with various applications, especially in medicine, agriculture, cosmetic and chemical industries [12]. Evidenced-based studies revealed that *T. subcordata* has antiulcer, antihistamine, antimicrobial, anticancer, antioxidant and antidiabetic activities [2]. *Hippocratea africana* plant root has been reported to be effective in the treatment of malaria, convulsion, body pains and diabetes [16]. The relationship between these two plants is that they grow naturally in tropical region, hence, their availability makes them a reliable cost-effective herbal regimen, fast to access and available almost all year round. However, various adverse effects including reduction of body weight, mild distortions of the cerebellum, and reduction in locomotion and exploratory behaviours have been attributed to administration of herbs in animals [5]. Therefore, given the widespread use of *T. subcordata* and *H. africana* plant parts in the management of many ailments, it is therefore necessary to investigate the possible detrimental effects of these plant extracts on the microstructure of the cerebellum of adult Wistar rats.

The cerebellum is the largest portion of the hindbrain. Its principal function is to regulate and maintain balance and to coordinate timing and precision of body movement [9,25]. It also plays an important role in cognition [25]. The cerebellum has multiple connections with other parts of the brain such as the brain stem, thalamus, vestibular nuclei and the hippocampus [9, 26]. This enables it to constantly monitor sensory inputs from effector organs and then refine and coordinate their responses [9]. Since there is no sufficient information on the effects of both plants on the cerebellum, even though these plants have been used for years in the management of various ailments by the rural dwellers, this present study investigated the histopathological presentations of the cerebellum of adult Wistar rats following *T. subcordata* and *H. africana* administration.

## 2. MATERIAL AND METHODS

### Preparation of *T. subcordata* and *H. africana* Extracts

*T. subcordata* and *H. africana* plant material (roots) were collected from Akwa Ibom State University Commercial Farms, Nigeria. They were identified and authenticated by the Curator at the Herbarium of Akwa Ibom State University with specimen and voucher deposited. The preparation of the root extracts was modified according to the methods described by [18]. The roots were washed to remove debris, cut into tiny pieces and air dried for one week. After drying, the dry plant sample were grounded with the aid of a manual grinding machine to powdered form out of which 240g dried powder were stirred in 1400ml of 70% ethanol topped up to 2000ml ethanolic solution by 600ml of distilled water using bell jar and allowed to stand for 72hours. The solution was filtered using a glass funnel packed with cotton wool. The filtrate was evaporated to dryness by heating in a water-bath at 40C to yield a semi-dry extract with brown colour. The semi-dry extract was re-suspended in 50ml beaker in refrigerator until ready for use and phytochemical screening [18]

### Phytochemical Screening

Phytochemical Screening of the extracts was carried out according to standard procedures and methodologies modified after [23].

### Care and Grouping of the Experimental Animals

“Twenty inbred adults male Wistar rats of average weight 200 g, were obtained and housed in the animal House of the Faculty of Biological Sciences, Akwa Ibom State University, Nigeria. The animals were housed in 14 standard home cages (40 cm × 35 cm) with wire gauze roof and wood shavings as beddings. The room temperature was between 27°C – 30°C, and the animals were exposed to 12:12 hours light/dark cycles and fed with normal commercial pelletized growers mash (Vital Feed Grand Cereal Ltd, Jos, Nigeria) and clean water *ad-libitum*. The animals were allowed to acclimatize for fourteen days before commencement of the experiment. Ethical approval was obtained from the Ethics Committee of Akwa Ibom State University, Nigeria and the animals were handled according to international guidelines as laid down by the National Institute of Health (NIH) of the United States of America for the regulation of laboratory animals” [13].

### Administration of *T. subcordata* and *H. africana* Extract

The Wistar rats were divided into four groups of five animals each. Group 1 was the control group and received 5 ml kg<sup>-1</sup> of water. Groups 2, 3 and 4 were the treatment groups and received respectively 150 mg kg<sup>-1</sup> body weight of *T. subcordata*, 200 mg kg<sup>-1</sup> body weight of *H. africana*, and a combination of 150 mg kg<sup>-1</sup> and 200 mg kg<sup>-1</sup> body weight of *T. subcordata* and *H. africana*. The administration which lasted for 7 days was orally with the aid of orogastric tubes according to their body weights (Table 1). The extracts and water were administered once daily in the morning (7 - 9am). The body weights of the animals were taken prior and every day till the end of the experiment.

**Table 1. Dosages of Extract Administered to the Rats For 7 Days**

Groups (1-4)	Treatment	Duration
1(Control)	5 ml kg <sup>-1</sup> of Water	7
2	150 mg kg <sup>-1</sup> of <i>T. subcordata</i>	7
3	200 mg kg <sup>-1</sup> of <i>H. Africana</i>	7
4	150 mg kg <sup>-1</sup> of <i>H. africana</i> and 200 mg kg <sup>-1</sup> of <i>T. subcordata</i>	7

### Termination of the Experiment

After the last day of the administration, the weights of the animals were confirmed before they were allowed to fast for few hours before commencement of the sacrifice by withdrawing their food and water. The animals were sacrificed after they were deeply anesthetized with 60 mg kg<sup>-1</sup> ketamine–hydrochloride (#50155, Rotex Medica, Trittau, Germany). Intra - cardiac perfusion with phosphate-buffered saline (PBS, 2M, pH 6.4) were carried out by means of a cannula and then perfusion-fixed with 10% buffered formalin. On complete perfusion, the skull was opened and the brain of the animal removed and post fixed in 10% buffered formalin for 48 hours. The whole cerebellum was further routinely processed for histological studies using haematoxylin and eosin [6] and Bielschowsky silver impregnation [14]. methods respectively. Sections were viewed under the light microscope and photomicrographs were obtained using the microscope camera linked to a computer.

### Statistical Analysis

One-way analysis of variance was used to analyse all the data, followed by a *post hoc* Tukey's test. All analysis was done using GraphPad Prism for Windows (version 5.01, San Diego California, USA). Data at probability level ( $P = .05$ ) was regarded as significant and are presented as Mean  $\pm$  Standard error of mean

## 3. RESULTS AND DISCUSSION

### Phytochemical Analysis

The phytochemical analysis of the root extract of *H. africana* showed that it contained moderate amount of alkaloid and phlobatannins, abundant quantity of saponin and flavonoids with traces of tannins. Anthraquinones, cardiac glycosides and terpenes were not detected. The results for the phytochemical analysis of the root extracts of *T. subcordata* showed that it contained abundant alkaloid, anthraquinones, cardiac glycosides and terpenes, with moderate quantities of flavonoids and tannins with traces of saponins. Phlobatannins was not detected (Table 2).

**Table 2: Phytochemical Analysis for *H. africana* and *T. subcordata***

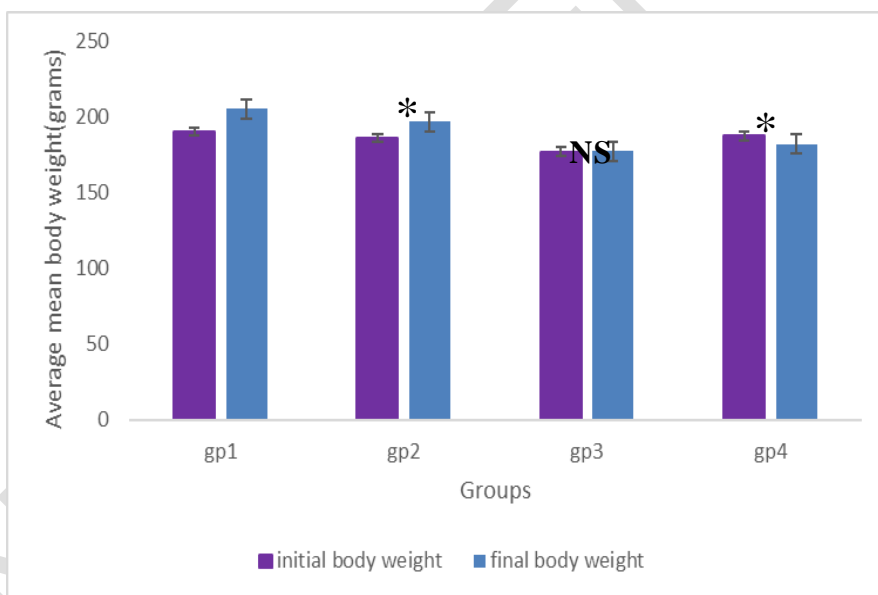
Parameters	<i>H. africana</i>	<i>T. subcordata</i>
------------	--------------------	----------------------

Alkaloids	++	+++
Saponin	+++	+
Flavonoid	++	++
Phlobotannins	++	ND
Anthraquinones	ND	+++
Cardiac glycosides	ND	+++
Terpenes	ND	+++
Tannins	+	++

\* +++ = Abundant, ++ = Moderate, + = Trace, ND = Not Detected

### Body weight changes

After the administration of *T. subcordata* and *H. africana* extracts, the final body weights of the control group 1 and that of the test group 2 animals given 150 mg kg<sup>-1</sup> *T. subcordata* were significantly ( $P = .05$ ) higher when compared to their initial weights. The body weight of group 4 animals given 150 mg kg<sup>-1</sup> *T. subcordata* and 200 mg kg<sup>-1</sup> body weight of *H. africana* was however significantly ( $P = .05$ ) lower than the control after administration of the extract. There was no significant difference in body weight in group 3 which received 200mg/kg of *H. africana* throughout the duration of the administration (Figure 1)



**Figure 1: Bar Chart Showing the Effect of Extract on the Body Weight**

Mean  $\pm$  Standard Error of Mean

\* = Significantly different from the control group at ( $P = .05$ )

NS = Not significantly different from the control group at ( $P = .05$ )

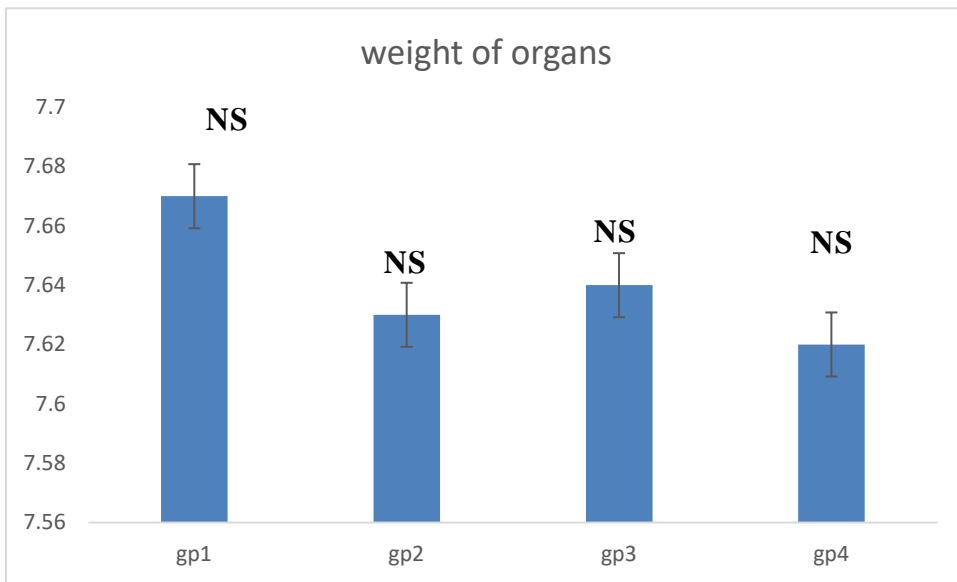
IBW = Initial Body Weight

FBW = Final Body Weight

F = F – ratio, P= Probability level,

## Organ Weight Changes

After the administration of *T. subcordata* and *H. africana* extracts, there was no significant difference in the organ weights of both test and control group throughout the duration of the experiment (Figure 2)



**Figure 2: Bar Chart Showing the Effect of Extract on Weight of brain**

Mean  $\pm$  Standard Error

NS = Not significantly different from the control group at  $p < 0.05$

F = F - ratio, P = Probability level

## Organosomatic Index

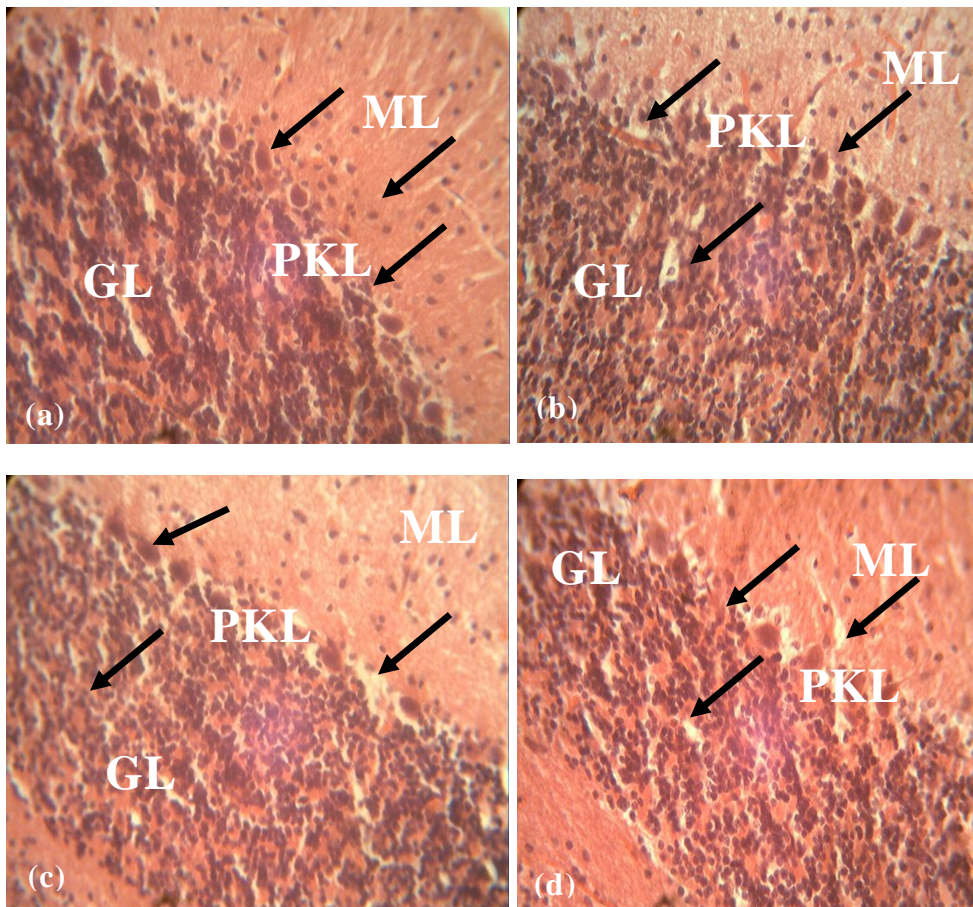
There was significant difference in the organosomatic index of the animals exposed to *T. subcordata* and co-administered *H. africana* (group 4) when compared to the control. The value of the organosomatic index of the rat in the test group was significantly higher than the control at ( $P = .05$ ) (Table 3).

Groups (1 - 4)	Treatment	Brain Weight	Body Weight	Organosomatic Index
1 (Control)	5 ml kg <sup>-1</sup> of Water	7.67±0.074	205.6±7.94	3.74
2	150 mg kg <sup>-1</sup> of <i>H. africana</i>	7.63±0.052	197±7.56	3.87
3	200 mg kg <sup>-1</sup> of <i>T. subcordata</i>	7.64±0.09	177.6±7.33	4.18
4	150 mg kg <sup>-1</sup> of <i>H. africana</i> and 200 mg kg <sup>-1</sup> of <i>T. subcordata</i>	7.62±0.06	182.4±10.21	4.31

**Table 3: Showing, Organosomatic Index**

#### Histomorphological Observations

**Haematoxylin and Eosin (H & E):** Sections of the cerebellum of the control rat given water showed spherical shaped Purkinje cell bodies in the Purkinje cell layer with densely packed cells in the granular layer (Figure 3a). Group 2 animals given 150 mg kg<sup>-1</sup> *T. Subcordata*, showed atrophied Purkinje cell neuron, with vacuolated neuronal cell bodies in the granular cell layer, while the cells in the molecular layers appear unaffected (Figure 3b). Sections of the cerebellum of group 3 animals given 200 mg kg<sup>-1</sup> *H. africana* showed markedly hypertrophied Purkinje and granular cell neurons with pyknotic nuclei in the Purkinje cell layer. the cells in the molecular layer appear unaffected (Figure 3c). The sections of the cerebellum of group 4 animals given 150/200 mg kg<sup>-1</sup> combined dosages of *T.subcordata* and *H. africana* showed hypertrophied Purkinje cells with pyknotic nuclei in the Purkinje cell layer with the granular cells appearing vacuolated when compared to the control group. The molecular layer appears unaffected (Figure 3d).

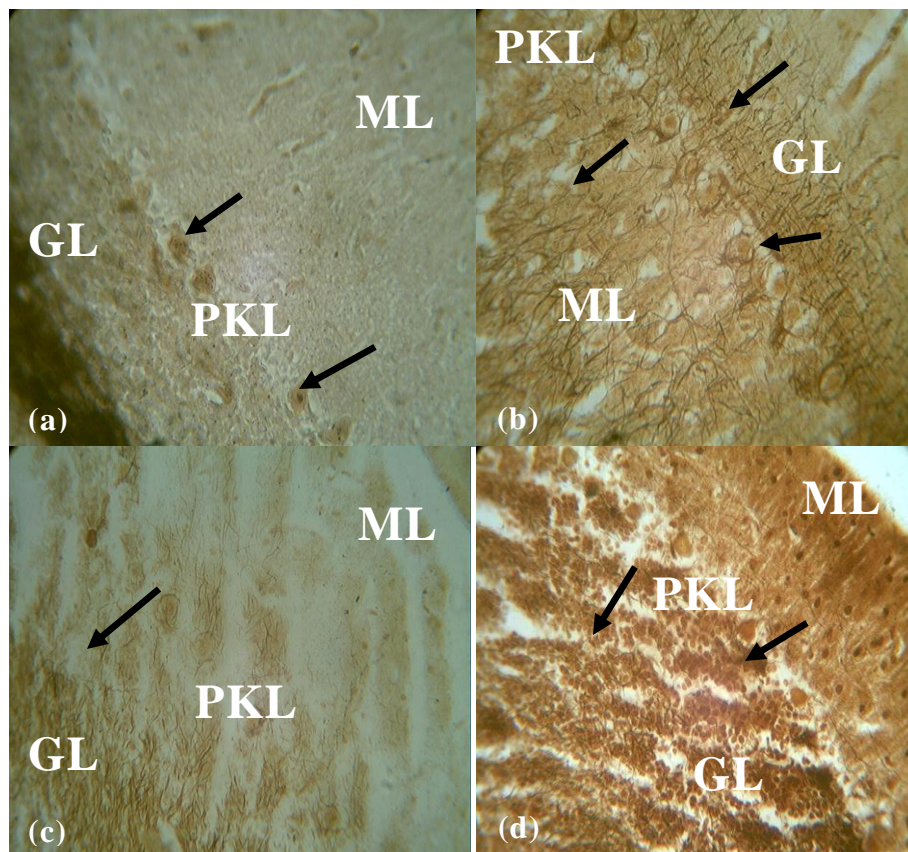


**Figure 3: Photomicrographs of the sections of the cerebellum of the control and test groups: H & E X400:**

Sections of the cerebellum of control rat given distilled water, shows normal histological appearance of neurons and glia in the three cortical layers (a), the cerebellum section of the  $150 \text{ mg kg}^{-1}$  *T. subcordata* group shows loss of a few Purkinje nuclei in the Purkinje cell layer (PKL) with hypertrophied Purkinje cell neuron (b). In the groups given  $200 \text{ mg kg}^{-1}$  *H. africana*, and combined ethanolic root extracts of  $150/200 \text{ mg kg}^{-1}$  body weight of *T. subcordata* and *H. africana* respectively, the cerebellum sections show pyknotic and hypertrophied Purkinje nuclei in the Purkinje cell layer, with vacuolated oligodendrocytes in the molecular layer in group 4 (c, d)

**Silver Impregnation:** Sections of the cerebellum of the control animals showed spherical shaped Purkinje cell bodies in the Purkinje cell layer with densely packed cells in the granular layer cells (Figure a). Sections of the cerebellum of groups 2 rat given  $150 \text{ mg kg}^{-1}$  *T. subcordata* shows degenerating and hypertrophied Purkinje cell neurons in the Purkinje cell layer (PKL) with argyrophilic nuclei; there is also an increased proliferation of silver grain-stained reactive astrocytic

processes across the three cortical layers (Figure 4b). The cerebellar section of group 3 animals given  $200 \text{ mg kg}^{-1}$  *H. africana*, shows marked loss of neuronal cells in the Purkinje and molecular layer cell layers with silver grain-stained astrocyte processes in the granular cell layer (4c), while the section of the cerebellum of rat given combined  $150/200 \text{ mg kg}^{-1}$  *H. africana* and *T. subcordata* (group 4) shows marked argyrophilic nuclei throughout the three cortical layers with vacuolations in the granular cell layer (4d)



**Figure 4:**The sections of the cerebellum of control and test group: Silver impregnation X400:

Section of the cerebellum of control rat showing normal appearance of neurons and glia in the three cortical layers (a). Section of the cerebellum of rat given  $150 \text{ mg kg}^{-1}$  *T. subcordata* shows hypertrophied Purkinje cell neurons in the Purkinje cell layer (PKL) with increased argyrophilic reactive astrocytic processes (b). the cerebellar section of group 3 and 4 animals given  $200 \text{ mg kg}^{-1}$  *H. africana* and combined  $150/200 \text{ mg kg}^{-1}$  *H. africana* and *T. subcordata* respectively, shows marked loss of neuronal cells in the Purkinje and molecular layers with silver grain-stained astrocyte processes in the granular cell layer (c), argyrophilic nuclei throughout the three cortical layers with

## DISCUSSION

In tradi-medical practice, extracts of *H. africana* and *T. subcordata* have been implicated in the treatment and management of many illnesses such as malaria infection in some part of Africa [16]. However, there are no reports on the possible adverse effects of these plant extracts on certain areas of the brain such as the cerebellum.

“The cerebellum is that part of the brain that plays an important role in motor control, cognitive functions and fine movement-related functions” [26]. “Its primary cell called the Purkinje form the heart of the cerebellar circuit” [21]. “The Purkinje cells also receives more synaptic inputs than any other type of cell in the brain with estimates of the number of spines on a single human Purkinje cell running as high as 200,000, coupled with their large size and distinctive activity pattern” [26]. However, damages to the cerebellum upon the administration of *H. africana* and *T. subcordata* as seen in this present study can impair these functions of the cerebellum.

Body weight is an important determinant of the wellbeing of an individual. Reductions in weight has been reported to be as a result of the bioactive effects of certain alkaloids on weight loss [3]. The results for the phytochemical analysis of the root extracts of *T. subcordata* in this present study showed that it contained abundant alkaloid when compared to the other extract (Tables 2). “Alkaloids are important class of phytochemicals having nitrogen atom in their heterocyclic ring and are derivative of amino acids” [22]. “These compounds are produced by large numbers of organisms, including plants,

animals, bacteria and fungi" [4, 22]. "Some alkaloids also act as poisons, neurotoxins and traditional psychedelics" [22]. Also, some potent alkaloids such as reserpine has been reported to have anti depressive effects even at low dose [5]. The implication of this is seen in the reduction in the body weights of group 4 animals given combined 150/200 mg kg<sup>-1</sup> *T. subcordata* and *H. africana*, probably due to the presence high amount of alkaloid in *T. subcordata*. A similar report of reduction in the body weights of mice administered root extract of *N. latifolia* compared with the control group was reported by [3]. The weight loss observed in the combined treatment group may be as a result of gastric intolerance as well as drowsy, hypnotic and sedative tendencies caused by the compounds. In this study, no difference existed in the brain weights of the animals in all the treatment groups. This account may indicate that the size of the body and brain of the animals were not affected by the treatment regimes, though differences in the sex of the animals, pharmacokinetics and pharmacodynamics of the drugs, as well as the species of the animal may influence alternative reports. According to [5]. "test materials that alter body weight generally do not alter brain weight". "Brain weight is less prone to be affected by changes in body weight and can be closely correlated with food consumption" [8].

Since some histopathological effects in animals have been linked to administration of the root bark extract of plants [23], in this study, histological investigation of the cerebellum of adult male Wistar rats administered with ethanolic root extracts of *T. subcordata* and *H. africana* showed alterations including cell atrophy, hypertrophy, and pyknosis in the treatment groups compared to the control group. The results for the phytochemical analysis of the root extracts of *H. africana* in this present study shows that it has abundant saponin when compared to the other plant. Saponins are secondary metabolites which are glycosidic in nature [4, 22]. "Studies on two smilagenin diglycosides and one trisaccharide steroidal saponin revealed that they both have cytotoxic potentials. The lysis of erythrocyte is one of the characteristics of saponin. It is believed to result from the ability of these compounds to interact with membrane cholesterol leading to membrane destabilization" [4, 22]. The same mechanism is also involved in the cytotoxicity of saponin as seen in this present study.

"Cerebellar granule cells are among the smallest neurons in the brain. They are also easily the most numerous neurons in the brain: In humans, estimates of their total number average around 50 billion, which means that about 3/4 of the brain's neurons are cerebellar granule cells" [21]. "Their cell bodies are packed into a thick layer which is the innermost part of the cerebellar cortex. A granule cell emits only four to five dendrites, each of which ends in an enlargement called a dendritic claw. These enlargements are sites of excitatory input from mossy fibres and inhibitory input from Golgi cells" [21]. "The most salient symptoms of cerebellar dysfunction are motor-related. The specific symptoms depend on which part of the cerebellum is involved and how it is disrupted. Damage to the flocculonodular lobe may show up as a loss of equilibrium and, in particular, an altered walking gait, with a wide stance that indicates difficulty in balancing. Damage to the lateral zone or the cerebrocerebellum results in problems with skilled voluntary and planned movements, dysdiadochokinesia, impaired check reflex or rebound phenomenon and intention tremor" [26]. "Damage to the midline portion may disrupt whole-body movements, whereas damage localized more laterally is more likely to disrupt fine movements of the hands or limbs" [21]. Damage to the upper part of the cerebellum tends to cause gait impairments and other problems with leg coordination. Damage to the lower part is more likely to cause uncoordinated or poorly aimed movements of the arms and hands, as well as difficulties in speed. In this present study, the histological sections of the cerebellum of the animals in groups 3 and 4 which were given *H. africana* singly and in combination showed varying degrees of neuronal degeneration including pyknotic and hypertrophied Purkinje nuclei in the Purkinje cell layer, with vacuolated oligodendrocytes in the molecular layer.

The presence of pyknotic nuclei in a brain area as well as vacuolation of the surrounding glia such as the oligodendrocyte are features of neuronal deaths [17]. Neuronal changes and evidence of neuronal damage are reportedly manifested in the form of discontinuation of the nuclear membrane, pyknosis of nuclei and vacuolation of neuropil around the damaged neurons [11, 15]. as seen in the present study. These degenerative features are seen in this present study especially in the Purkinje neurons in the test groups. The result of this present study agrees with the earlier report by [5], who reported on the cerebellar neurohistology and behavioral effects of *Gongronema latifolium* and *Ruwolfia vomitoria*. Saponins are reported to limit cell division and growth [22]. "the implication can be seen in the altered Purkinje neurons as seen in the histological sections of the cerebellum of the animals in the test group in the present study. This may hinder the participatory role of the Purkinje cells as the primary excitation unit in cerebellar function" [15, 17].

The principle of silver impregnation technique is based on the findings that certain component of degenerative neuronal components become argyrophilic [11, 14]. In this present study, silver impregnation sections of the cerebellum of the animals in all the treatment groups showed alterations in their cytoarchitecture with strong affinity for the silver ions in the degenerating neurons and axonal terminals forming metallic grains that are visible under light upon reduction as seen in this present study. The Purkinje cells showed disorganization and proliferation of synaptic terminals surrounding soma. According to [7], this occasional loss of Purkinje cells may have resulted in the presence of degeneration of axon terminals of basket cells that typically enwrap the perikaryon appearing to surround an empty space in the cerebellum in this present study. It is thought in disease states that abnormal accumulation of the axonal structural components leads to morphological changes within the axon and depending on the underlying disease mechanism, the accumulated material can differ [15, 17]. This may have been the case in the present study upon *T. subcordata* and *H. africana* administration.

#### 4. Conclusion

The ethanolic root bark extract of *T. subcordata* and *H. africana* induced neurodegenerative potentials in the cerebellum of adult Wistar rats as evidenced by loss of Purkinje cells, pyknosis, hypertrophy and atrophy of neuronal cells. It also causes a loss in body weight but does not have an effect on brain weight. Hence, they must be taken under strict supervision

#### Ethical Approval:

As per international standard or university standard written ethical approval has been collected and preserved by the author(s).

#### Recommendations

It is recommended that further studies be carried out on specific parameters of the neurodegeneration, as well as real-time activity of the brain regions using imaging and computer-based programs.

#### REFERENCES

1. Allam EA, Alaa, MN, Amgad, IMK, Toshinori, N, Kuniyoshi, D. Potential Activities for Constituents from *Vicia Faba* L. Trends. *Phytochem. Res.* 2018; s2(1), 21-26
2. Ayoola MD, Akinwunmi KF, Agboola OB. Antidiabetic and antioxidant activities of *Entandrophragma cylindricum* and *Trichlisia subcordata*. *Nigerian Journal of Natural Products and Medicine.* 2017;21(1):24-31.
3. Edagha, I., Peter, I and Aquaisua, A. Histopathological Effect of *Nauclea Latifolia* Ethanolic Leaf Extract and Artemether/Lumefantrine on The Hippocampus of *P. Berghei*-Infected Mice. *International Journal of Brain and Cognitive Sciences.* 2017; 6(1): 9 - 16
4. Edeoga, HO. and Eriata, DO. Alkaloid, Tannin and Saponin Contents of Some Nigeria Medicinal Plants. *J. Med. Aromatic Plant Sci,* 2001; 23, pp.344-349.
5. Ekong, M., Peter, M., Peter, A., Eluwa, M., Umoh, I., Igiri, A. and Ekanem, T. Cerebellar Neurohistology and Behavioural Effects of *Gongronema Latifolium* and *Rauwolfia Vomitoria* in Mice. *Metabolic Brain Disease,* 2015; 29(2): 521 - 527.
6. Ellis, R. Hematoxylin and Eosin (Hand E) Staining Protocol, IMS's Division of Pathology. The Queen Elizabeth Hospital, Woodville Road, Woodville, South Australia, Accepted 5/11/2019. Available; [http://www.ihcworld.com/protocol/special\\_stain/h\\_and\\_e\\_ellis.htm](http://www.ihcworld.com/protocol/special_stain/h_and_e_ellis.htm).
7. Ferrer IG., Santpere GW., and Van Leeuwen FW. Argyrophilic grain Disease. *Brain,* 2008: 131;1416-1432
8. Gill LS. Ethnomedical Uses of Plant in Nigeria. Uniben Press, Benin 1992.
9. Harold. E., and Vishy M. Clinical Anatomy: Applied Anatomy for Students and Junior Doctors, 12<sup>th</sup> Edition, 2010; pp362 -363
10. Madara, AA; Abah, RO; Elkanah, OS. Ethnobotanical Survey of Medicinal Plants Used in The Treatment of Malaria by The Idoma Speaking People of Ogbadibo Local Government Area of Benue State, Nigeria. *FUDMA Journal of Sciences (FJS),* 2018; 2(2):48 – 54
11. Mitra, NK., Nadarajah, VD. and Siong, HH. Effect of concurrent application of heat, swim stress and repeated dermal application of chlorpyrifos on the hippocampal neurons in mice. *Folia Neuropathologica,* 2009; 47(1): 60 - 68.
12. Mohammadhosseini, M. The ethnobotanical, phytochemical and pharmacological properties and medicinal applications of essential oils and extracts of different *Ziziphora* species. *Ind. Crop Prod.* 2017; 105, 164-192.
13. National Institute of Health. Guide for the Care and Use of Laboratory Animals, 8<sup>th</sup> ed., Washington: National Academies Press, pp. 1 – 2, 2011
14. Neurotech. Neurosilver™ Kit II: A Rapid Silver Staining Kit for the Microscopic Detection of Neuronal Damage. FD NeuroTechnologies Consulting and Services, Inc., Columbia, 2012; pp:45.
15. Nsikan-Abasi B. Udoh, Theresa B. Ekanem and Moses B. Ekong Behavioural and Microstructural Evaluation of the Hippocampus of Adult Wistar Rats Following Artequin Administration *Current Research in Neuroscience* 2020; 10 (1): 1-10,2020
16. Okokon JE; Okokon PJ; Sahal D. In-Vitro Antiplasmodial Activity of Some Medicinal Plants from Nigeria. *International Journal of Herbal Medicine.* 2017; 5(5):102-109. 7.

17. Pagnussat, A. S., Faccioni-Heuser, M. C., Netto, C. A. and Achaval, M. An Ultrastructural Study of Cell Death in the CA1 Pyramidal Field of the Hippocampus in Rats Submitted to Transient Global Ischemia Followed by Reperfusion. *Journal of Anatomy*, 2007; 211 (5): 589 - 599.
18. Pekny, M. and Nilsson, M. Astrocyte Activation and Reactive Gliosis. *Glia* 2005; 50 (8): 427–434.
19. Sonibarea MA and Adeboduna DF. Macroscopic And Microscopic Evaluation of *Triclisia Subcordata* Oliv. (Menispermaceae) Towards Its Standardization. *Nig. J. Pharm. Res.* 2018; 14 (2) Pp 189-196 Issn 0189-8434, E-Issn 2635-3555
20. Sarker, SD and Nahar, L. Evidence-Based Phytotherapy: What, Why and How? *Trends Phytochem. Res.* (2018) 2(3), 125-126.
21. Shi, Z., Zhang, Y., Meek, J., Qiao, J. and Han, VZ. The Neuronal Organization of a Unique Cerebellar Specialization: The Valvula Cerebelli of a Mormyrid Fish. *Neurology*. 2008; 509 (5): 449–473
22. Sibi, G., Venkategowda, A. And Gowda, L. Isolation and Characterization, of Antimicrobial Alkaloids from *Plumeria alba* Flowers Against Foodborne Pathogens. 2014; *Am. J. Life Sci*, 2, Pp.1-6.
23. Simran Arora and Suvartan Ranvir. *Phytochemicals: Benefits, Concerns and Challenges Book on Advancement in Functional Food Ingredients: 205–227 Edited By: Harish Kumar copyright © 2019, Jaya Publishing House, Delhi, India*
24. Thusa, R., and Mulmi, S. Analysis of Phytoconstituents and Biological Activities of Different Parts of *Mahonia Nepalensis* and *Berberis Aristata*, *Nepal Journal* <https://doi.org/10.3126/Njb.V5i1.18864>, Accessed: 2017; 05.02.2018.
25. Udoh, N. B., Ekanem, T. B., Ekong, M. B., Peter, A. I. and Akpantah, A. O. (2014). Hippocampal Glial Degenerative Potentials of Mefloquine and Artequin in Adult Wistar Rats. *International Journal of Brain Science*, 2014; (104785):5.
26. Wolf, U., Rapoport, M. J. And Schweizer, T. A. Evaluating The Affective Component of The Cerebellar Cognitive Affective Syndrome. *Neuropsychiatry And Clinical Neuroscience*, 2009; 21 (3): 245–453.
27. Yu, W. And Magnuson K, E. Cognitive Collaborations: Bidirectional Functional Connectivity Between the Cerebellum and The Hippocampus. *Neuroscience*, 2015; 9(5): 177-187.