

COMPARATIVE EVALUATION OF DIFFERENT LOCAL SPICES ON HEPATIC FUNCTIONS IN MALE MICE EXPOSED TO LAMBDA-CYHALOTHRIN

Abstract

Aim: This study was aimed at evaluating the effect of different spices on hepatic function in male mice exposed to lambda-cyhalothrin (LCT).

Experimental design: A completely randomized experimental design using standard methods for analysis.

Place and duration of Study: This study was carried out in the Animal house, Department of Animal and Environmental Biology of Rivers State University, Nkpolu-Oroworukwo Port Harcourt, Nigeria. GPS 4°47'50"N 6°58'49"E. This study lasted for 35days.

Methodology: Forty-two male mice were randomly selected into six (6) groups A-F (n=7/group). Group B were gavage Cyhalothrin (LCT) alone. Group C, D, and E were gavaged 10mg/kg/bw of LCT and 20mg/kg/bw/day of aqueous extract of Tetrapleura tetraptera, Piper guineense, and Xylopia aethiopicae respectively, while group F received 10mg/kg/bw of LCT together with the combination of the three spices. Vital organs were removed and weighed for organosomatic indices. Blood samples were collected by ocular puncture and analysis for liver biomarkers and antioxidant enzymes carried out. Vital organs were removed and weighed for organosomatic indices. Histological sections of the liver were mounted on slides, stained with hematoxylin and eosin (H&E). Photomicrographs were generated.

Results: Results show a significant ($p=0.05$) increase in Alanine aminotransferase (ALT), Aspartate aminotransferase (AST) and Alkaline phosphatase (ALP) concentration in mice exposed to lambda cyhalothrin alone but a significant decrease observed in groups coadministered the spices. Also the level of all enzymatic antioxidants superoxide dismutase (SOD), Catalase (CAT) and glutathione (GSH) considered decreased in group with lambda cyhalothrin (LCT) alone while there was significant ($p=0.05$) increase in groups coadministered Tetrapleura tetraptera, Piper guineense and Xylopia aethiopia. Liver photomicrograph of animals exposed to lambda cyhalothrin alone shows lymphocyte infiltration in the portal vein while fewer lesions and regenerating hepatocytes were observed in groups coadministered the different local spices. It is concluded therefore that lambda Cyhalothrin induces liver injury and oxidative stress in the exposed mice. All the spices used in this study have significant antioxidant activity against liver injury due to their free radical scavenging potential although the efficacy is highest in combination of spices > Tetrapleura teraptera > Piper guineense > Xylopia aethiopia. For efficacy, individuals may use the combination of all spices, Tetrapleura tetraptera, Piper guineense and small doses of Xylopia aethiopia singly as an antioxidant supplement to counter the toxic effect of insecticides exposure.

Keywords: antioxidant, biomarkers, insecticides, oxidative stress, spices.

1. INTRODUCTION

The increase in the incidence and prevalence of liver diseases remain a major global health burden irrespective of ethnic group, religion, sex or age. The liver is a vital organ in a living organism because it plays an essential role in metabolism and the excretion of various therapeutic agents and xenobiotics from the body [1,2]. Chronic liver diseases have been identified as the fifth most common cause of death in the United Kingdom accounting for about 4.8% deaths among American Indians and Alaska Natives [3,4,5]. According to WHO 2020, liver disease deaths in Nigeria, is about 3.10% of total deaths making Nigeria the second in the world with age adjusted death rate of 64.44 per 100,000 of population. [6,7].

There has been no definite therapeutic agent for a total cure of liver diseases. Documented scientific evidences suggest that most of the available therapeutic agents only facilitate the healing or regeneration of the liver cells [2,8,9,10]. The liver itself has an exceptional regenerative capacity after any cellular injury as a result of xenobiotic exposure (toxic chemicals, ethanol, pesticides, drugs etc.). Antioxidant therapies have been shown to play a crucial role in maintaining balance and preventing the body from several diseases caused by the overproduction of free radicals. Naturally, antioxidant therapies act as free radical scavengers, thereby inhibiting lipid peroxidation [11].

Spices had played a vital role in the lifestyle of people across the globe. They possess potent medicinal properties such as antimicrobial activity. The use of spice are not limited to flavoring agent but as preservatives. Spices such as turmeric, fenugreek, mustard, ginger, onion and garlic have a wide variety of bio functions and their additive or synergistic actions are likely to protect the human body against a variety of injuries. Traditionally, spices as part of the diets, have holistic effects on human health.

Piper guineense commonly known as African black pepper is a West African tropical plant that belongs to the family *Piperaceae*. In some parts of Nigeria, the seeds and leaves are used in preparation of a popular dish consumed by women after childbirth, to enhance the contraction of uterine and expulsion of placenta and other remains from the womb, treatment of rheumatic pains, weight control, respiratory diseases and correction of female infertility problems while the seeds are used as an aphrodisiac

[12,13,14,15,16, 17,]. The effect of aqueous extract of *Piper guineense* seeds on some liver enzymes, antioxidant enzymes and some hematological parameters in albino rats has been reported by [18].

Uda (*Xylopia aethiopica*) also known as Guinea pepper has been shown to have antioxidant, laxative and antimicrobial properties [19], antiseptic and insecticidal property [20]. Phytochemical evaluation shows *Xylopia* is rich in flavonoids, alkaloids, flavonoids, tannins, steroids oligosaccharides, tolerable levels of cyanogenic glycosides in Uda seeds, it is used in the treatment of cough, rheumatism, dysentery, malaria, uterine fibroid boils and wounds in most parts of Africa [20,21].

Aidan fruit (*Tetrapleura tetraptera*) has been documented to have flavonoids, phenols, cardiac glycosides, terpenoids, saponins, and phlorotannins, among others, thus exhibiting varying pharmacological effects. It is an essential ingredient in the preparation of pepper soups for mothers after labour to prevent postpartum contraction [22].

Synthetic pyrethroids account for more than 30% of insecticides used worldwide in agricultural, domestic and veterinary applications [23].

Lambda-cyhalothrin (LCT), a synthetic type II pyrethroid insecticide has extensive uses as an agro-pesticide [10, 24,25]. Residues of LCT have been reported in vegetables and fruits [26], milk and blood of dairy cattle meat [27]. Consistent with its lipophilic nature, LCT has been found to accumulate in biological membranes leading to oxidative damage [28]. It was reported that LCT caused oxidative stress by altering antioxidant systems and increasing lipid peroxidation in mammals [24,25, 29].

Accumulated exposure to these insecticides will eventually damage the liver, as it will not be able to filter the toxins out as quickly as they are being absorbed into the body.

Researchers have aimed at finding solutions of insect control in households, Agriculture and the general environment considering the negative effect of endocrine disrupting pesticides especially on non- target organisms due to the fact that the organs of the organism are their first line of attack. Spices such as *P. guineense* (Uziza), *X. aethiopica* and *T. tetrapleura* (Oshorisha) are used globally and they are readily available commercially for domestic and industrial purposes.

However, there is a paucity of scientific information on the efficacy of these spices on liver cells, hence, this study was designed to assess the possible effect of *Piper guineense*, *Tetrapleura tetraptera*, *Xylopia aethiopica*, against lambda-cyhalothrin induced hepatotoxicity in male mice.

2. MATERIALS AND METHODS

2.1 Experimental Location

The study was carried out in the green house of the Department of Animal and Environmental Biology, Rivers State University, Nkpolu Oroworukwo, Port Harcourt, Nigeria. The experiment was conducted from January to March, 2021

2.2 Experimental Animal and Management

A total of forty-two (42) mice (mean weight 20.57 ± 3.35 g) were used for the study. The mice were housed in rubber case under standard condition and acclimatized for one week. All animals were fed with standard rodent pellet and cool clean water *ad libitum*. All experiments were conducted according to the institutional animal care protocols at the Rivers State University, Nigeria and followed approved guidelines for the ethical treatment of the experimental animals.

2.3 Experimental Design and Procedure

Forty-two mice were assigned to six groups (A-F) of seven mice each. Group A was the negative control and so they were not given any treatment, but pellet and clean tap water. Group B was the positive control and receives 10mg/kg/bw/day of lambda cyhalothrin. Group C receives lambda-cyhalothrin and 20mg/kg/bw/day of aqueous extract of *Tetrapleura tetraptera*, Group D receives lambda-cyhalothrin and 20mg/kg/bw/day of aqueous extract of *Piper guineense*. Group E receives lambda-cyhalothrin and 20mg/kg/bw/day of aqueous extract of *Xylopia aethiopica*. Group F receives lambda-cyhalothrin and 20mg/kg/bw/day of aqueous extract of *Tetrapleura tetraptera*, *Xylopia aethiopica* and *Piper guineense*.

All the groups were exposed to their treatment by oral gavage for 35days. The animals were weighed twice a week and the average weight per week recorded in grams (g). Feed was withdrawn from the animals 24hours before the termination of experiment. Blood samples were collected by ocular puncture and placed in plain sample bottles. Thereafter the samples were centrifuge at 3000g for 10minutes kinetic test kits produced by Cypress diagnostics. Alanine aminotransferase (ALT), Aspartate transferase (AST) activities were determined according to the method of Reitman and Frankel [30]. Alkaline phosphatase (ALP) tests were carried out using Belfield and Goldberg's method. [31]. GSH was determined by the method of Ellman [32].

2.4 Histopathological analysis of the liver

Immediately after dissection of each animal, 0.5g of liver was fixed in 10% neutral formalin and sectioned with a digital Rotatory Microtome (AO spencer No. 820) at 5µm. Histological sections mounted on slides was stained with hematoxylin and counter-stained with eosin (H&E). Photomicrographs were generated with a digital microscope Biosphere Miller B with an image processor DN2 – microscopy image processing software at x40 magnification.

Data obtained were subjected to one way one-way Analysis of Variance (ANOVA), where significant differences were found, pair-wise comparisons were conducted with Tukey test using SPSS 22 software.

3. RESULT

The effect of oral coadministration of cyhalothrin and different local spices on male mice is shown in Fig 1a. Aspartate aminotransferase (AST) concentration significantly ($P=0.05$) increased from 45.21IU/L in group A to 71.26IU/L. in the group gavage cyhalothrin only. This value decreased to 61.2IU/L in group C, coadministered *Tetrapleura tetraptera*, 55.01IU/L with *Piper guineense*, 65.21 and 63.21IU/L in groups E and F respectively. Fig 1b shows a significantly increased value of alkaline aminotransferase (ALT) from 12.02U/L in the control group to 21.03 U/L in group B. There was a steady decrease in values in group C,D and E and further decrease to 12.1IU/L in group F where the combination of all spices were given. Figure 1c shows the value of Alanine phosphatase to be 20.12U/L in the control. This value doubled in group B and later reduced to 29.31 U/L, 30.12U/L, 27.12U/L and 29.1U/L in groups C, D, E, F respectively.

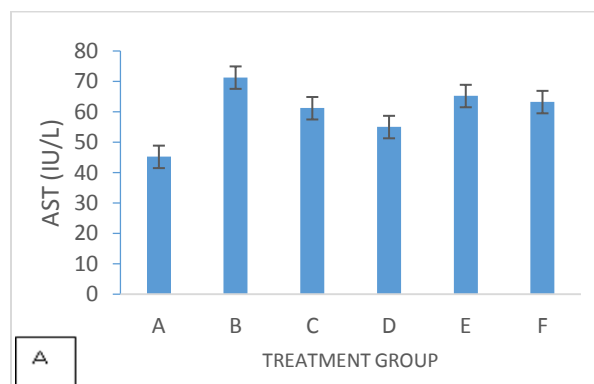


Fig 1A: Concentration of AST (Aspartate aminotransferase) in mice exposed to lambda cyhalothrin and different local spices

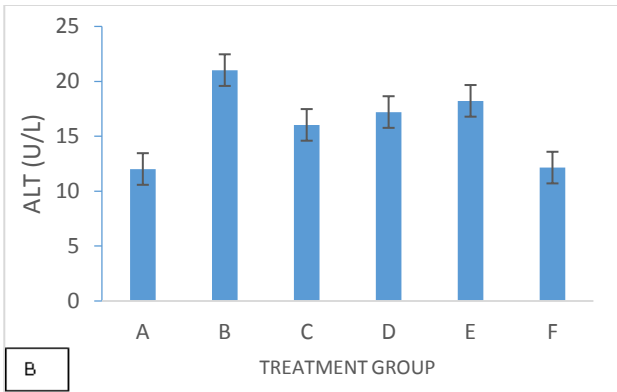


Fig 1B: Concentration of ALT (Alanine aminotransferase) in mice exposed to lambda cyhalothrin and different local spices

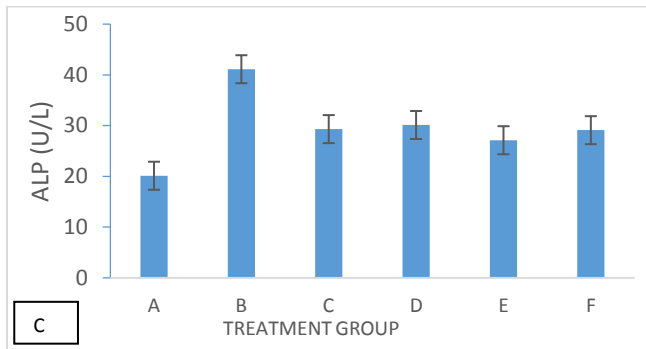


Fig 1C: Concentration of ALP (Alkaline phosphatase) in mice exposed to lambda cyhalothrin and different local spices

Effect of coadministration of lambda-cyhalothrin, and different local spices on the enzymatic antioxidant biomarkers

The level of Glutathione (GSH) in fig 2a decreased from $1.32 \pm 0.02 \mu\text{mol/l}$ in group A to $0.95 \pm 0.03 \mu\text{mol/l}$ in group B. There was a significant ($P=0.05$) increase in the level of GSH in group C to $2.34 \pm 0.54 \mu\text{mol/l}$ and a decrease to $1.08 \pm 0.02 \mu\text{mol/l}$ in group D administered *Piper guineense*. A steady increase was observed in groups E and F administered *Xylopi*a and a combination of the spices to $1.32 \pm 0.05 \mu\text{mol/l}$, $1.52 \pm 0.03 \mu\text{mol/l}$ respectively.

The level of catalase (CAT) in fig 2b decreased from $5.16 \pm 1.22 \text{u/ml}$ in the control group to $4.59 \pm 1.08 \text{u/ml}$ in group B. A significant increase of $6.28 \pm 2.03 \text{u/ml}$ was recorded in group C which later decreased slightly to $6.18 \pm 1.05 \text{u/ml}$ and $5.85 \pm 1.01 \text{u/ml}$ in groups D and E. There was also a significant increase in the level of CAT to $7.32 \pm 2.01 \text{u/ml}$ in group F. Moreover, the concentration of Superoxide dismutase (SOD) in fig 1c also decreased in the control group (group A) from $0.19 \pm 0.03 \text{u/ml}$ to $0.1 \pm 0.02 \text{u/ml}$ in group B. The value

increased to $0.26 \pm 0.02 \mu\text{ml}$ in group C and remained steady in group D until a significant decrease was recorded in group E. The concentration of SOD later increased significantly to $0.38 \pm 0.04 \mu\text{ml}$ in group F.

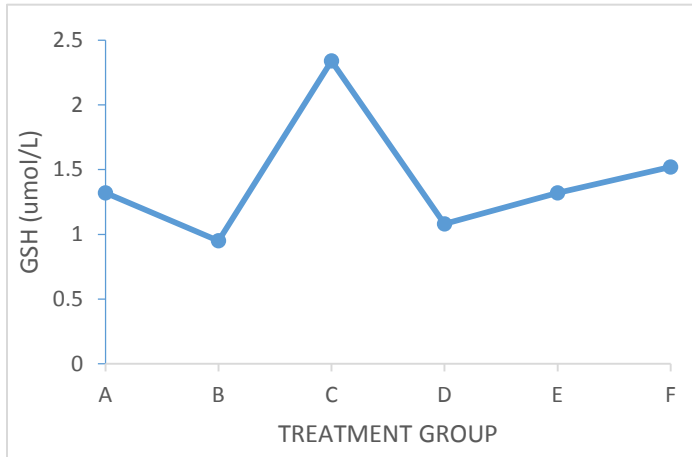


Fig 2a: Effect of lambda cyhalothrin and different local spices on Glutathione level in mice

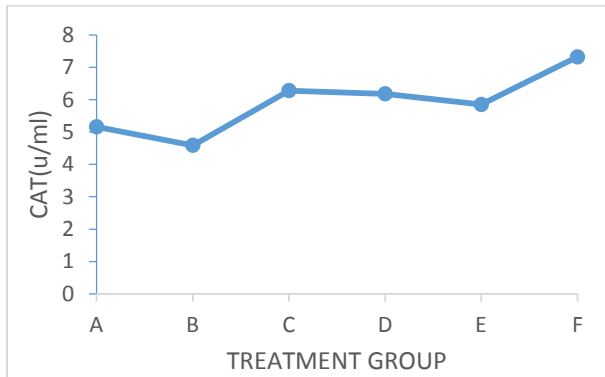


Fig 2b: Effect of lambda cyhalothrin and different local spices on catalase level in mice

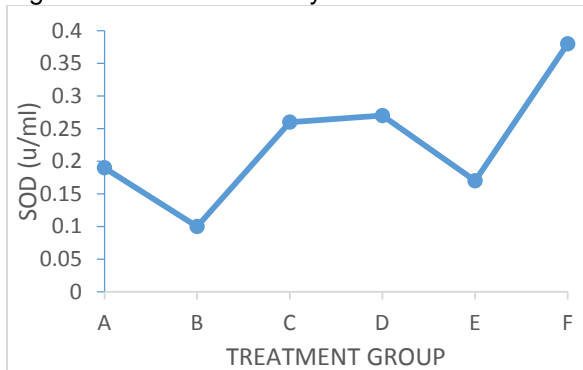
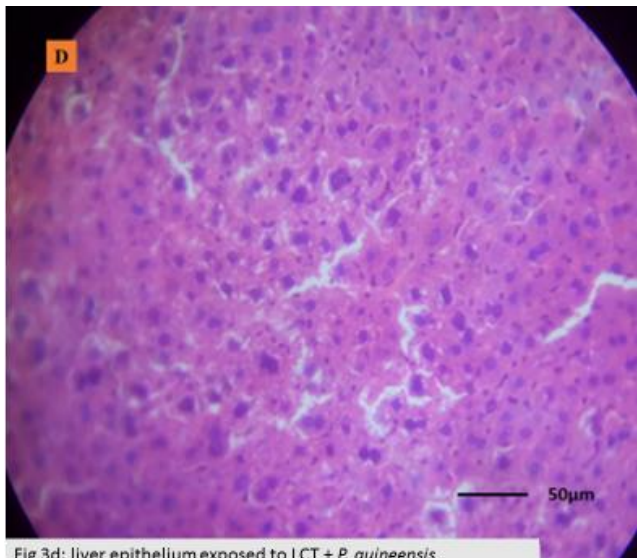
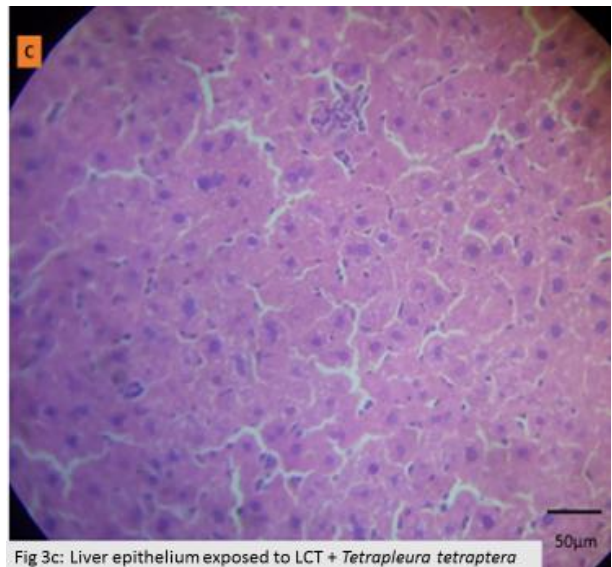
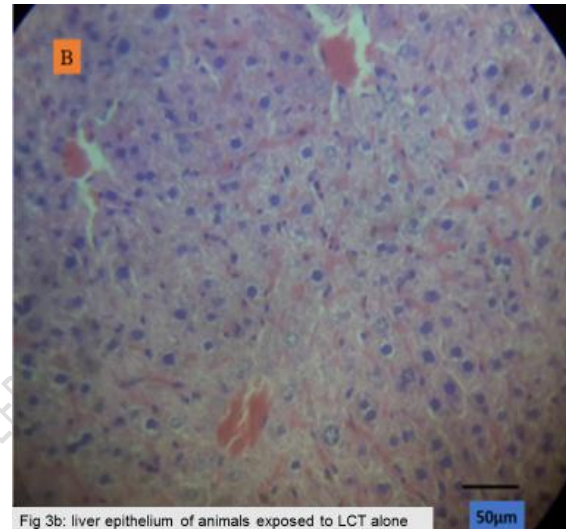
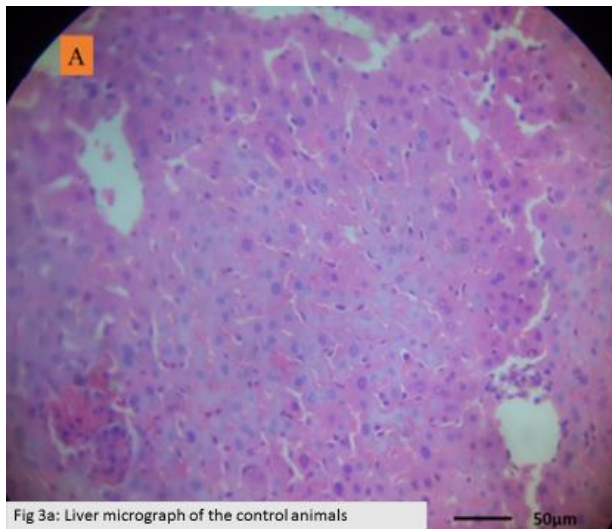


Fig 2c: Effect of lambda cyhalothrin and different local spices on Superoxide dismutase level in mice.

Histopathological evaluation of the liver

Histological examination of the hematoxylin & eosin sections of the liver of the experimental animals in control group reveals normal liver epithelium with full complement of Hepatocytes. Liver epithelium of mice exposed to lambda cyhalothrin alone shows infiltration of erythrocyte and increased mitotic activity as the hepatocytes spirals into division to replace degenerated cells. Group C animals exposed to lambda cyhalothrin and co-administered *Tetrapleura tetraptera* (fig3C) reveals the hepatocytes undergoing regeneration. Liver epithelium from animals exposed to lambda cyhalothrin with *Piper guineense* (group 3d) and *Xylopia aethiopica* (group 3e) exhibited fewer lesion and a regenerating, busy epithelium which is more pronounced in fig 3e. Fig 3f shows liver epithelium with fully regenerated hepatocytes as observed in the control.



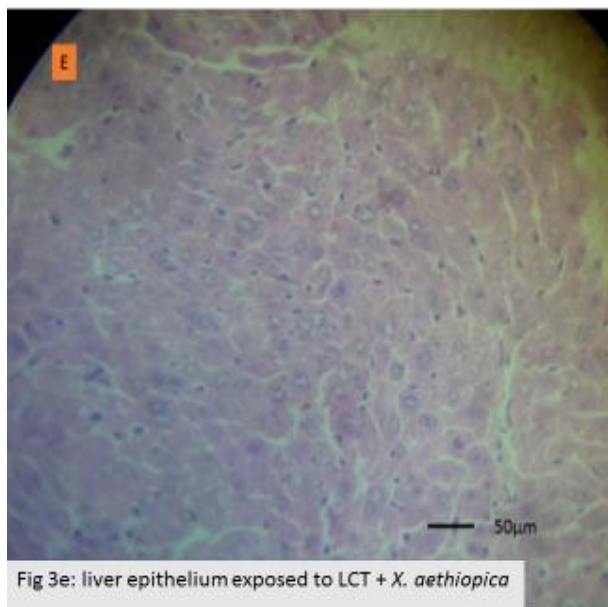


Fig 3e: liver epithelium exposed to LCT + *X. aethiopica*

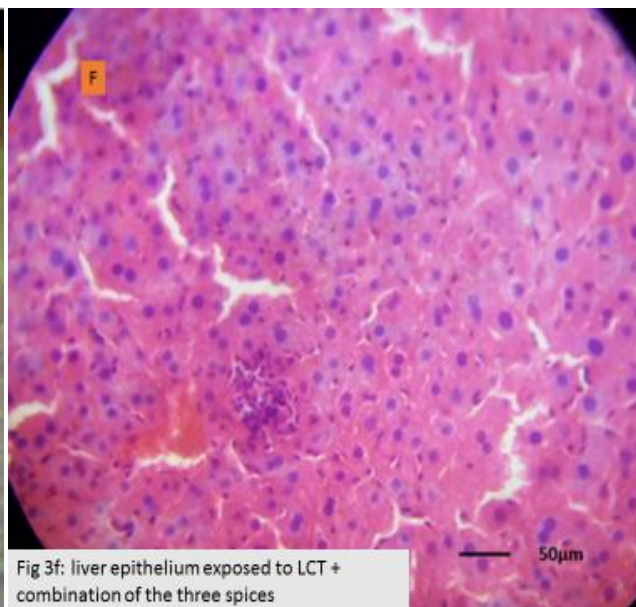


Fig 3f: liver epithelium exposed to LCT + combination of the three spices

4. DISCUSSION

Liver is the first organ to be impacted by foreign compounds that comes through portal circulation. These foreign compounds are predominantly bio-transformed in the liver by the action of metabolizing enzymes including microsomal enzymes, aminotransferases and oxygenase. Earlier investigations reveal that pesticides generate free radicals which have been implicated in the induction of liver lesions in experimental animals exposed to cypermethrin [2], deltamethrin [9], dichlorovos [33,34], as well as induction of metabolite-related disorders. Antioxidant enzymes can protect cellular compounds against damage induced by free radicals. SOD, CAT and GPx are important antioxidant enzymes. The SOD decomposes superoxide radicals and produce H_2O_2 . H_2O_2 is subsequently removed to water by CAT in the peroxisomes, or by GPx oxidizing GSH in the cytosol [33,34,35]. So the activities of these enzymes have been used to assess oxidative stress in cells. Glutathione is a crucial component of the antioxidant defense mechanism and it functions as a direct reactive free-radical scavenger. The decreased level of renal GSH in lambda cyhalothrin- treated rats of the present study may be due to its enhanced utilization during detoxification of lambda cyhalothrin.

The elevated levels of ALT, AST and ALP as well as the reduction in GSH, CAT, and SOD level in the group administered lambda cyhalothrin alone is characteristic of impaired liver function reflected as an initial elevation of the biomarker enzyme levels. The level of all enzymatic antioxidants considered decreased in group B with cyhalothrin alone suggesting that Cyhalothrin induced oxidative stress in the male mice. The significant increase in SOD, Catalase and GSH in groups coadministered *Tetrapleura tetraptera*, *Piper guineense* and *Xylopi aethiopica* shows the protective property of the spices against liver injury. Although it appears that the level of protection conferred on the liver is lower in group E with *X. aethiopica* than those in groups C,D, and F where *Tetrapleura tetraptera*, *Piper guineense* and combination of the spices were administered (fig 2a-f).

Previous reports indicate that during liver damage, there was an observed decreased in antioxidant defenses in the liver exposed to Cypermethrin and Cyhalothrin [2, 10]. [35] however, reported that the level of enzymatic antioxidants SOD, Catalase, GSH showed significant reduction in rat liver while administration of *Citrus limon* fruit extract markedly ameliorated the toxicity of Carbofuran. [11] also reported the protective role of the methanol extract of *Piper guineense* seeds against CCl₄ induced hepatotoxicity. CCl₄ induced increased activities of serum hepatic marker enzymes associated with increased levels of lipid peroxidation and decreased enzymatic antioxidant.

The liver micrographs in this study reflect the remarkable capacity of the liver to regenerate following injuries by undergoing rapid mitotic division as observed in the epithelium exposed to lambda cyhalothrin. This injury to the liver was indicated by the significant elevation of all liver biomarkers examined in this study. The central portal vein was infiltrated with lymphocytes in group B. The increase in the number of hepatocytes captured in liver epithelium of animals exposed to the different spices (fig 3c-3f) is indicative of rapid regeneration going on with coadministration and the antioxidant capability of the various spices. However, fewer lesion were still observed in the group coadministered *Xylopi aethiopica*. [36] reported substantive evidence of antioxidant and hepatoprotective property of *Xylopi aethiopica* leaves in animal models while [37] reported that the administration of *Xylopi aethiopica* leaves can induce hepatic cell damage resulting from the elevation of liver enzymes because of the present of xylopic acid in its constituent. Also histopathological examination of liver reveals a mild to acute hepatitis in *Xylopi aethiopica*

aethiopica leaves treated rats suggesting that aqueous extract of *Xylopi aethiopica* may possess some toxic effect on the liver [38]. However, all the spices used in this study have significant antioxidant activity due to their free radical scavenging potential although the efficacy is highest in combination of spices > *Tetrapleura teraptera* > *Piper guineense* > *Xylopi aethiopica*.

5. CONCLUSION AND RECOMMENDATION

This study concluded that the decreased level of all enzymatic antioxidants considered in group administered cyhalothrin alone suggests that Cyhalothrin induced oxidative stress in the Swiss mice while the significant increase in SOD, Catalase, GSH and rapid hepatocytes regeneration in groups coadministered *Tetrapleura tetraptera*, *Piper guineense* and *Xylopi aethiopica* shows the antioxidant and protective property of the spices against liver injury at varying degrees.

It is recommended that exposure to lambda-Cyhalothrin as an insecticide in homes, offices, and Agricultural settings should be reduced. More so, for efficacy, individuals may use the combination of all spices, *Tetrapleura tetraptera*, *Piper guineense* and small doses of *Xylopi aethiopica* singly as an antioxidant supplement to counter the toxic effect of insecticides exposure.

ETHICAL APPROVAL

The experiment was conducted according to the institutional animal care protocols at the Rivers State University, Nigeria and followed approved guidelines for the ethical treatment of experimental animals.

COMPETING INTERESTS DISCLAIMER:

Authors have declared that no competing interests exist. The products used for this research are commonly and predominantly use products in our area of research and country. There is absolutely no conflict of interest between the authors and producers of the products because we do not intend to use these products as an avenue for any litigation but for the advancement of knowledge. Also, the research was not funded by the producing company rather it was funded by personal efforts of the authors.

REFERENCES

1. Obulor, A. O & Orlu, E. E. (2018). Inhibitory Activity of lycopene on cypermethrin-induced hepatotoxicity and liver injury in male Sprague Dawley Rats. *Journal of pharmacy and Biological Sciences*, 13, 63-73.
2. Singh, D Cho, W.C., Upadhyay, G. (2016). Drug-induced liver toxicity and prevention by herbal antioxidant: an overview. *Frontiers physiol.* 6: 363
3. Stanaway, J.D; Afshin, A; Gakidou, E. (2018) global regional and national comparative risk assessment of 84 behavioural, environmental and occupational and metabolic risks or clusters of risk for 195 countries and territories, 1990-2017: a systematic analysis for the global burden of disease study 2017. *Lancet*, 392: 1923-1994.
4. Murray, C.J; and Lopez, A.D.(1996): Evidence-based health policy- lessons from the burden of disease study. *Science*, 274, 740-743.
5. Suryaprasad, A., Byrd, K., Redd, J., Perdue, D., Manos, M., McMahon, B., (2014). Mortality caused by chronic liver disease among American Indians and Alaska natives in the US 1999-2009. *American Journal of Public health*. 104 (S3).
6. WHO; (2020). Available: <http://www.who.int/hepatitis B/keyfacts/2020>. Accessed on October 2020.
7. Ali, S.A; Ikani, R.O; Onyekwelu, C.K; Obi, S.O; and Ogbonna, C.E. (2020). Epidemiology of chronic liver disease in Nigeria; A review. *Asian Journal of advances in medical Science*; 2(3), 1-6
8. Huang, H.L., Wang, Y.J., Zhang, Q.Y., Liu, B., Wang F.Y. (2012). Hepatoprotective effects of baicalein against CCl₄ induced acute liver injury in mice. *World Journal of gastroenterology*. 18(45). 6605
9. Orlu, E. E. (2014). Deltamethrin-induced Alterations in sperm morphology and spermatogenesis impairment in Adult. Sprague-Dawley Rats. *Research Journal of Applied Sciences, Engineering and Technology*, 7 (11), 2324-2331.
10. Titus, L.K., Orlu, E.E and Obulor, A.O. (2019). Evaluation of the Therapeutic Role of *Citrullus lanatus* and *Annona muricata* Fruit Extracts on Cyhalothrin-induced Toxicity. *Journal of Advances in Biology & Biotechnology*. 22(4): 1-10,
11. Oyinloye, B.E., Osunsanmi, F.O., Ajiboye, B.O., Ojo, A.O, Kappo, P.A. (2017). Modulatory effect of methanol extract of piper guineense in CCl₄ induced hepatotoxicity in male rats. *International Journal of Environmental Research and Public Health*. 14(9) 955.
12. Ekanem, A.P., Udoh, V.F., Oku, E.E (2010). Effects of ethanol extract of piper guineense seeds (Schum and Thonn) on the conception of mice *Mus musculus*. *African Journal of pharmacy and pharmacology*, 4:362-367.
13. Essiett, U.A and Ibanga, U.E(2012). Phytochemical properties of the leaves and stems of piper umbelatum, *Piper guineense*. schum and thorn. *World Journal of Applied Science and Technology*. 4(1).121-126.

14. Oladosun, A. R.N., George, F.O., Obasa, S.O., and Bankole, M.O. (2012). Effect of some plant extracts on some biological parameters of catfish *Clarias gariepinus*. *Journal of Fisheries and Aquatic science*. 10. 1-6.
15. Juliani, R. H., Koroch, A. R., Giordano, L. Amekuse, L., Koffa, A. J., Asante-Dartey, S. E., Simon, J. E. (2013). *Piper guineense* (Piperaceae): Chemistry, Traditional uses and functional properties of West African Black pepper. *African Natural Plant Products*, Volume 11 Discoveries and Challenges in Chemistry Health and Nutrition. ACS symposium series. 1127, 33 – 48.
16. Kim-kabari, B.B., Barimalaa, I.S., Achenwu, S.C. (2011). Effect of three indigenous soices on the chemical stability of smoked dried *Clarias lazerna*; during storage. *African journal of agriculture and nutrition and development*. 11; 5-9.
17. Mbongue, F.G.Y., Kamtchouing, P., Essama, O.J.I., Yewah, P.M., Dimo, T. and Lontsi, D. (2005). Effect of the aqueous extract of dry fruits of piper guineense on the reproductive functions of adult male rats. *Indian Journal of Pharmacology*, 37; 30-32.
18. Uhegbu, F.O., Imo, C., Ugbo, A.E. (2015). Effect of aqueous extract of *Piper guineense* seeds on some liver enzymes, antioxidant enzymes and some hematological parameters in Albino rats. *International Journal of Plant Science*. 4: 167-171.
19. Asekun, O. T. and Adeniyi, B. A. (2004). Antimicrobial and cytotoxic *Xylopiya aethiopia* from Nigeria. *Fitoterapia*, 75, 368 – 370.
20. Konning, G.H., Agyare, C and Ennison, B. (2004). Antimicrobial activity of some medicinal plants from Ghana. *Fitoterapia*. 75. 65-68.
21. Ijeh, I.i., Omodamiro, O.D., and Nwanna, I.J. (2005). Antimicrobial effects of aqueous and ethanolic fractions of two spices *Ocimum gratissium* and *Xylopiya aethiopia*. *Afric. Journal Biotech*. 4(9).953-956.
22. Okoronkwo, N. E. and Echeme, J. O. (2012). Cholinesterase and microbial inhibitory activities of *Tetrapleura tetraptra*. *Journal of Applied and Natural Science*, 4, 156 – 163
23. Prasanth, K.M., Rajini, P.S (2005) fenvalerate-induced oxidative damage in rat tissues and its attenuation by dietary sesame oil. *Food chem. Toxicology*, 43, 299-306
24. Fetoui H., Garoui E.M., Zeghal E. Lambda-cyhalothrin-induced biochemical and histopathological changes in the liver of rats: ameliorative effect of ascorbic acid. *Exp. Toxicol. Pathol*. 2009; 61: 189- 196.
25. Abdel Aziz, K.B and Abdel Rahem, H.M (2010). Lambda, the pyrethroidinsecticide as a mutagenic agent in both somatic and germ cells. *J. Am. Sci*. 6(12), 317-326.
26. Turgut, C. Ornek, H., Cutright, T.J., (2011) Determination of pesticides residues in turkey's table grapes; the effect of integrated pest management organic farming and conventional farming. *Environmental Monitoring Assessment*. 173, 315-323.
27. Muhammad F., Akhtar M., Rahman Z.U., Farooq H.U., Khaliq T., Anwar M.I. (2010). Multi-residue determination of pesticides in the meat of cattle in Faisalabad Pakistan. *Egypt Acad. J. Biol. Sci.*; 2: 19-28.
28. Michelangeli F., Robson M.J., East J.M., Lee A.G. The conformation of pyrethroids bound to lipid bilayers. *Biochem. Biophys. Acta*. 1990; 1028: 49-57.
29. El-Demerdash F.M. Lambda-cyhalothrin-induced changes in oxidative stress biomarkers in rabbit erythrocytes and alleviation effects of some antioxidants. *Toxicol. In Vitro*. 2007; 21: 392-397.

30. Reithman S and Frankel S (1957). A colorimetric method for the determination of serum oxaloacetic and glutamic pyruvic transaminases. *Am. J. Clin. Pathol.* 28(1): 56-63.
31. Belfield, A. and Goldberg, D. (1971). Colorimetric determination of alkaline phosphatase activity enzyme. 12: 561-566.
32. Ellman, G.L. (1959) Tissue sulfahydryl groups. *Arch. Biochem. Biophys.* 82:70—77.
33. Holy, B., Kenanagha B., Onwuli D.O. (2015) Haemato-pathological effects of dichlorovos on blood puncture and liver cells of albino rats. *Journal of Toxicology and Environmental Health Sciences*; 7(2): 18–23.
34. Iboroma, M., Orlu, E.E., Ebere, N., Obulor, A.O. (2018). Androgenic and antioxidant activity of *Stelleria media* on rat following sub-chronic exposure to Dichlorvos. *Journal of Pharmacy and Biological Sciences.* 13(6). 38-46
35. Adikwu, E & Deo, O. (2013). Hepatoprotective effect of Vitamin C.(Ascorbic acid). *Pharmacology and Pharmacy*, 4, 84-92.
- Adadi, P and Kanwugu, O.N. (2020). Potential Application of *Tetrapleura tetraptera* and *Hibiscus sabdariffa* (Malvaceae) in Designing Highly Flavoured and Bioactive Pito with Functional Properties. *Beverages*, 6,22.
37. Obodo, B.N, Iweka, F.K, Obhakan, J.O, Oyadonghan, G.P. and Agbo, G.E. (2013). The effect of *Xylopiya aethiopic*a leaves on bodyweight and growth performance. *International Journal of herbs and Pharmacological research.* 2(2), 14-19.
38. Chris-ozoka, L.E., Ekundayo, V. and Winiki, C. (2015). Histomorphological effects on *Xylopiya aethiopic*a on the liver and kidney of Albino Wistar rats. *Sch. Acad. J. Biosciemce.* 3(2A).150-154