

# Class II malocclusion treatment with the Distal Active Concept technique

---

## ABSTRACT

**Aims:** The aim of this case report is to evaluate the skeletal and dental effects of the Distal Active Concept (DAC) technique in an adolescent female patient.

**Presentation of case:** The patient is a 14-year-old female who presented with a skeletal class II malocclusion, class II division 1 dental relationship, and protrusion of upper and lower incisors. She was treated using the DAC technique which relies mainly on the use of double class II elastics to correct the Class II malocclusion and is indicated for treating young patients presenting a skeletal class II division 1 malocclusion caused by a retrognathic mandible without extraction of premolars. During the distalization phase of the DAC technique, open coil springs are inserted in compression against the maxillary first molars and are associated with double class II elastics on each side to correct the molar et canine class II relationship. Bite turbos made of glass ionomer cement are placed on the occlusal surfaces of the lower first molars to facilitate the forward movement of the mandible.

**Results:** The upper lip protrusion was reduced after retraction of maxillary incisors so that the facial profile became more balanced. The patient's occlusion was finished with a bilateral molar and canine class I relationship. No skeletal changes were obtained. The class II malocclusion was corrected mainly by dentoalveolar compensation. The maxillary incisors were retracted by 2 mm and the mandibular ones were protruded and intruded by 2 mm. Consequently, the overjet decreased from 6 to 2 mm, and the overbite from 4 to 2 mm. The upper first molar tipped slightly distally whereas the lower first molar moved mesially by 2 mm. **Conclusion:** Orthopedic growth modification with the Distal Active Concept therapy can be attained, provided that the patient's remaining pubertal growth is adequate. Otherwise, the skeletal discrepancy will remain the same, and the class II malocclusion will be corrected only by dental camouflage.

*Keywords: class II division 1 malocclusion, class II skeletal discrepancy, Distal Active Concept;*

## 1. INTRODUCTION

Of the many forms of malocclusion, Angle Class II division 1 is the most common type with a frequency of 52% [1]. It is characterized by the protrusion of the upper incisors and lip and the retrusion of the chin which could have an impact on facial esthetics and may lead the patient to seek orthodontic care.

For young children with mixed dentition, the treatment of class II malocclusion is generally provided in two phases. During the early phase, the patient is asked to wear a functional appliance such as mandibular activators [2], [3] or Headgear [4] to reduce the skeletal discrepancy between the upper and the lower jaws, followed by a later phase of orthodontic treatment when the child is in early adolescence. As for teenagers presenting a skeletal class II malocclusion, the treatment is performed preferably in a single phase because of the decreasing growth potential [5].

Different appliances could be employed in the one-phase treatment of class II malocclusion in mandibular retrognathic adolescents such as the Forsus™ spring which forces the mandible to move forward and enhances growth in the mandibular condyles [6]. This effect reduces the sagittal discrepancy between the maxilla and the mandible and improves the overall facial convexity. However, this type of appliance has the slight disadvantage of being expensive for some patients, bulky and not very comfortable. For these reasons, we decided to treat our patient according to a technique known as the Distal Active Concept or DAC which was developed by JJ Akin in 1995 [7]. The aim of this paper is to evaluate the skeletal and dental effects of the DAC technique in an adolescent female patient.

## 2. PRESENTATION OF CASE

### 2.1 Clinical examination and diagnosis

The patient is a 14-year-old female who sought orthodontic treatment with the chief complaint of protrusion of the upper teeth. The pre-treatment photographs are presented in **Figure 1**. Facial photographs showed an ovoid, symmetric form with normal facial proportions and no gingival display upon smiling. The lateral view showed a convex profile because of maxillary protrusion and mandibular retrusion, an obtuse nasolabial angle, and a deep labiomental fold. The Intraoral photographs showed an early adult dentition with ovoid dental arch forms, mild crowding, and no caries. A class II division 1 was noted with deep bite (4mm) and increased overjet (6mm), a deep curve of Spee, and no midline deviation. On the panoramic radiograph, root lengths and periodontium appear normal, the crowns of the third molars are fully developed and no TMJ signs were noted. The Cephalometric radiograph revealed a skeletal Class II relationship (ANB=8). Mandibular plane angle showed a normodivergent craniofacial pattern (SN-GoGn=30). Dentoalveolar compensations for skeletal Class II were evident especially in the lower arch (IMPA=104, I/F=115). The pretreatment cephalometric measurements are shown in **Table I**. The diagnosis of this patient was skeletal class II malocclusion, class II division 1 dental relationship, and protrusion of upper and lower incisors. The patient's diagnosis in the three dimensions is shown in **Table II**.

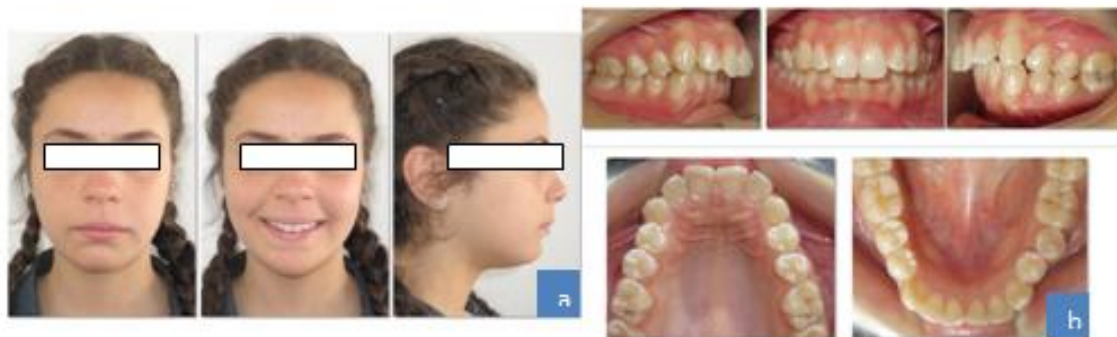

Figure 1. Pretreatment photographs. a, facial photographs. b, intra-oral photographs.

**Table I: Significant cephalometric values.**

	Patient Pre-treatment	Norm	SD
SNA	85°	82°	2°
SNB	77°	80°	2°
ANB	8°	2°	2°
WITS appraisal	7 mm	-2 to +2 mm	
FMA	20°	25°	3°
SN-GoGn	30°	32°	5°
Upper incisor to Frankfort plane (I/F)	115°	107°	5°
Lower incisor to mandibular plane (IMPA)	104°	87°	
Angle Z	73°	76°	

SNA, sella-nasion-A point; SNB, sella-nasion-B point; ANB, A point-nasion-B point; WITS appraisal, Witwatersrand appraisal; FMA, Frankfort horizontal-mandibular plane; SN-GoGn, sella nasion-gonion gnathion; angle Z of Merrifield, Frankfort horizontal-profile line; SD, standard deviation.

**Table II: Patient's diagnosis in three dimensions.**

	skeletal	dental	Soft tissue
Sagittal	Class II	Class II Molar and canine Overjet=6mm	Convex profile
Vertical	normodivergent	Overbite=4mm	Normal facial ratios
Transverse	normal	Buccal cross-bite of lower left second premolar	Facial symmetry

## 2.2 Treatment objectives

The goal of treatment is to:

- create a Class I occlusion
- reduce the skeletal discrepancy by enhancing mandibular growth
- normalize the overjet and the overbite
- improve the facial esthetics

## 2.3 Treatment options

- 1) Extraction of the maxillary first premolars which would correct the overjet, but may have negative esthetic results. At the end of treatment, the patient will still have a Class II molar relationship.
- 2) Extraction of the maxillary first premolars and the mandibular second premolars which would correct the overjet and the class II molar and canine relationship, but will not improve facial esthetics. Also, the crowding in the lower arch is minimal and does not require extractions.
- 3) Non-extraction treatment with Forsus™ spring and growth modification.
- 4) Non-extraction therapy according to the 'Distal Active Concept' technique (this was the accepted option).

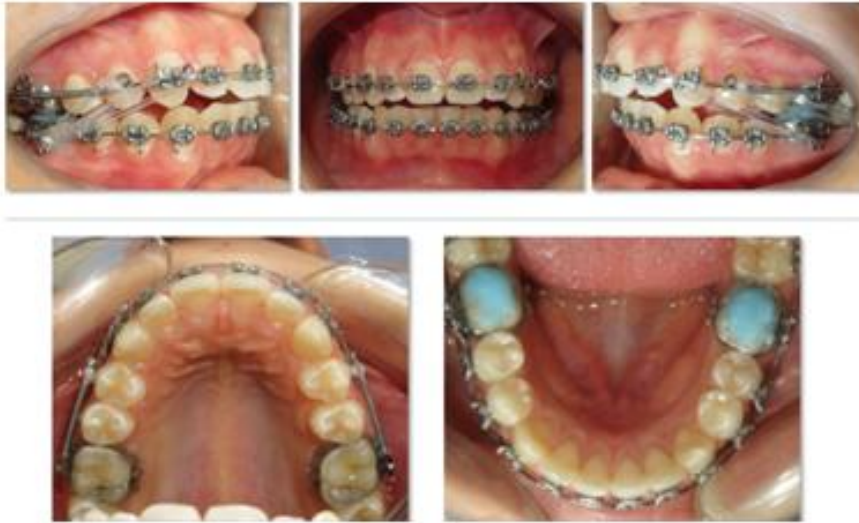## 2.4 Treatment progress

The treatment timeline, as well as the archwire sequence, are listed in **Table III**. Roth prescription was used. The slot sizes were 0.022-in (GAC™ Thin Arch Mini brackets). On the day of appliance placement, orthodontic bands were cemented on the first molars, and tubes were bonded on the mandibular second molars. The remaining dentition was bonded with conventional brackets. A maxillary .016 nickel-titanium archwire and a mandibular .014 NiTi archwire were ligated. After a couple of months, the maxillary and mandibular archwires were changed to .018x.025 NiTi and .017x.025 NiTi respectively and the patient was asked to wear class II elastics mainly at night (4mm, 4oz).

Four weeks later, we initiated the distalization phase (**Figure 2**). Glass ionomer bite turbos were bonded on the occlusal surfaces of mandibular first molars, and the brackets of maxillary premolars were temporarily removed to allow the placement of open coil springs. Maxillary and mandibular .018x.025 stainless steel archwires were ligated. Two helical loops were bent in the upper archwire on each side. The first two loops were placed between the lateral incisors and the canines and served as hooks to attach the class II elastics. The second loops were placed 3 to 4 mm distal to the canines and were used as Stops for the compressed coil springs. The patient was asked to wear double class II elastics on both sides. The first elastic was attached from first helical loop on the upper archwire to mandibular first molar and the second elastic was attached from maxillary canine to mandibular second molar. This phase lasted approximately 3 months.

**Table III: Treatment progress and archwire sequence.**

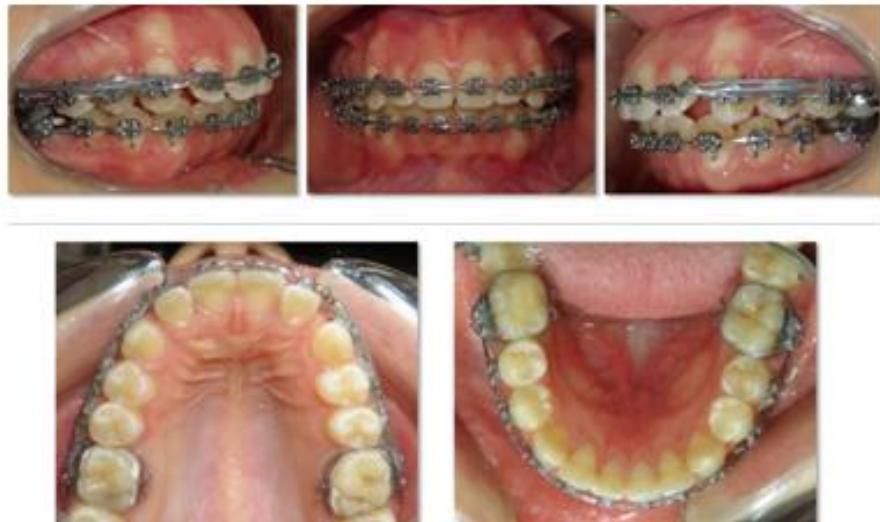Time (months)	Upper dental arch	Lower dental arch
	<b>Leveling phase</b>	
First day	Bonding from first molar to first molar .016 nickel-titanium archwire	Bonding from second molar to second molar .014 NiTi archwire
1	.016x.022 NiTi	.016 NiTi
3	.018x.025 NiTi	.017x.025 NiTi
	Glass-ionomer bite blocks on the mandibular first molars and class II elastics at night	
	<b>Distalization phase</b>	
4	.018x.025 stainless-steel archwire Debonding of the premolars and placement of compressed open coil spring	.018x.025 stainless-steel archwire Double class II elastics
	The patient wasn't seen for 3 months due to Covid-19 restrictions. During this period, proper wear of elastics was stressed.	
9	Bonding of the second molars .017x.025 NiTi	018x.025 stainless-steel
	<b>Retraction of upper incisors and space closure</b>	
11	018x.025 stainless-steel	018x.025 stainless-steel
	Sliding mechanics and double class II elastics The bite turbos were removed gradually	
15	018x.025 stainless-steel with an accentuated curve of Spee	018x.025 stainless-steel Stripping of incisors
17	<b>Finishing phase</b>	
20	<b>Debonding</b>	



**Figure 2. The distalization phase.**

After 9 months into treatment, we attained class I molar and canine relationship, and large diastemas (3 mm) were created between maxillary lateral incisors and canines. The upper premolars and second molars were bonded and a maxillary .017x.025 NiTi archwire was ligated. The mandibular archwire was not changed and the patient wore simple class II elastics for about 12 hours per day to avoid relapse. Two months later, we commenced the space-closing phase using sliding mechanics. Maxillary and mandibular .018x.025 stainless steel archwires were ligated. Two omega loops were bent in the upper archwire distal to the lateral incisors and were used as hooks to attach the elastomeric chains.

At this stage of treatment, the bite turbos were completely removed and the patient was asked to go back to wearing double class II elastics (**Figure 3**). This phase also lasted approximately 3 months.

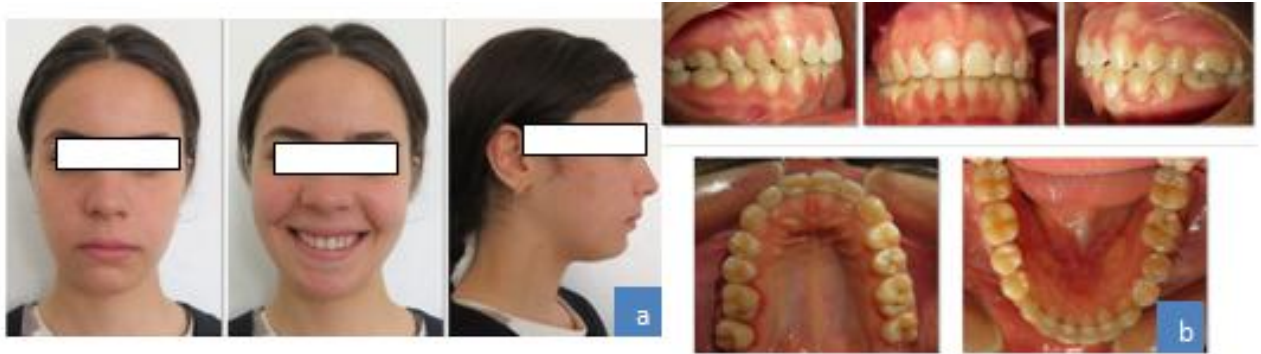

**Figure 3. the space-closing phase.**

During the last few months of treatment, an accentuated curve .018x.025 stainless steel archwire was placed on the maxillary arch, and class II elastics with a vertical component were prescribed to avoid relapse and to improve interdigitation.

### 3. TREATMENT RESULTS

The duration of the orthodontic treatment was approximately 20 months. The posttreatment results were documented in **Figure 4**. The cephalometric tracings before and after treatment were superimposed in **Figure 5**, with the measurements listed in **Table IV**.



**Figure 4.** Posttreatment photographs. a, facial photographs. b, intra-oral photographs.

**Table IV:** Significant pretreatment and posttreatment cephalometric measurements.

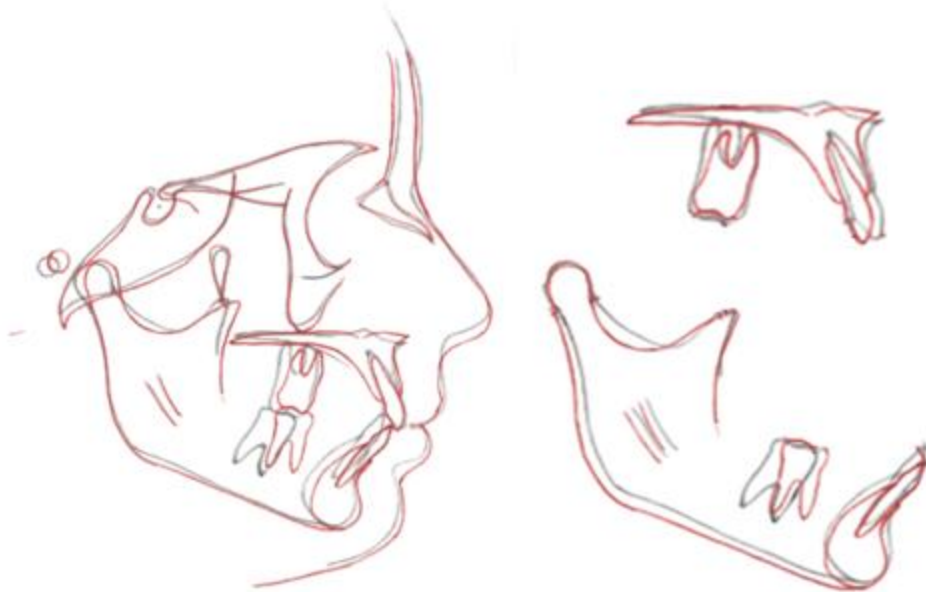
	Patient Pre-treatment	Patient Post-treatment	Norm	SD
SNA	85°	85°	82°	2°
SNB	77°	77°	80°	2°
ANB	8°	8°	2°	2°
WITS appraisal	7 mm	7 mm	-2 to +2 mm	
FMA	20°	20°	25°	3°
SN-GoGn	30°	30°	32°	5°
Upper incisor to Frankfort plane (I/F)	115°	111°	107°	5°
Lower incisor to mandibular plane (IMPA)	104°	108°	87°	
Angle Z	73°	75°	76°	

The upper lip protrusion was reduced after retraction of the maxillary incisors so that the facial profile became more balanced and the labiomentral fold looked less accentuated. The patient's occlusion was finished with a bilateral molar and canine class I relationship. Ideal overjet (2mm) and overbite (2mm) were achieved.

The posttreatment lateral cephalogram showed no skeletal changes. The class II malocclusion was corrected mainly through dentoalveolar compensation; retraction of the maxillary incisors (I/F decreased from 115° to 111°) and protrusion of the mandibular incisors (IMPA increased from 104° to 108°).

The cephalometric superimposition showed that the chin projection improved slightly. The maxillary incisors were retracted by 2 mm and the maxillary molars were tipped distally. The mandibular incisors were protruded and intruded by 2 mm with the pretreatment occlusal plane as reference. The mandibular molars were moved forward by 2 mm.

The appliance was removed after 20 months of treatment. Retainer wires were bonded from canine to canine on both dental arches and the patient was instructed to maintain good oral hygiene and was to be observed for compliance every 3 months for the first year.



**Figure 5. Cephalometric superimpositions showed that the chin projection improved slightly. The maxillary incisors were retracted by 2 mm and the maxillary molars were tipped distally. The mandibular incisors were protruded and intruded by 2 mm and the mandibular molars were moved forward by 2 mm.**

#### 4. DISCUSSION

It has been shown that the distal active concept therapy has both skeletal and dental effects in patients presenting mixed or early permanent dentition [8], [9], [10]. This technique aims to correct the class II discrepancy by enhancing mandibular growth and by moving the lower teeth mesially and the upper teeth distally. In a study by Akinin et al. [10], it was reported that the DAC therapy showed a mandibular growth of 7.6 mm when used during the mixed dentition period whereas the mandibular growth was only 3.9 mm with the same treatment applied on the permanent dentition. From these results, it can be concluded that the older the patient gets, the less skeletal effect will be attained using the DAC technique and, therefore, the correction of the class II malocclusion will be achieved mostly by dentoalveolar compensation. This patient was 14 years old at the beginning of treatment. She had a skeletal and dental class II division 1 malocclusion with protrusion of upper and lower incisors. The authors decided to treat her using the DAC therapy because no extractions of premolars were needed and they hoped to be able to stimulate the mandibular growth which would reduce the skeletal discrepancy and improve the chin projection. This treatment technique is comprised of three main phases; **the leveling phase, the distalization phase, and the space-closing phase**. During the first stage of treatment, both dentitions were aligned using NiTi archwires. It is recommended not to bond the brackets of the maxillary premolars to avoid having to remove them before inserting the coil springs which are necessary for the next phase. Glass-ionomer bite turbos were placed on the mandibular first molars to help the mandible move forward and class II elastics were prescribed at nighttime. Once stainless steel rectangular archwires were reached, open coil springs were placed on the upper archwire between the canines and the first molars, and the patient was asked to wear double class II elastics 24 hours a day. The risk with this technique is that it relies greatly on the patient's compliance with elastic wear. If he or she does not wear them regularly, not only the class II malocclusion will not be corrected but the maxillary anterior teeth will be pushed forward and the overjet will increase considerably. So, it is very important to test the patient's compliance and motivation before indicating this treatment method. **In case of non-compliance, another option would be to use fixed appliances such as the Forsus™ device [11]**. The distalization phase ends once class I molar and canine relationship is achieved. Before starting to close the spaces that were created between the lateral incisors and canines, the maxillary premolars must be bonded, as well as the maxillary second molars if possible. Also, the patient must continue to wear the class II elastics to avoid relapse.

At the end of treatment, the protrusion was reduced after retraction of the maxillary incisors and upper lip so that the facial profile looked more balanced and less convex. The patient was about 15 years old when she started wearing double class II elastics during the distalization phase of treatment. By this time, her pubertal growth spurt has likely ended which explains why the authors were unsuccessful in attaining any mandibular advancement as shown on the posttreatment cephalogram. The maxillary incisors were retracted by 2 mm and the mandibular ones were protruded and intruded by 2 mm. Consequently, the overjet decreased from 6 to 2 mm, and the overbite from 4 to 2 mm. The upper first molar tipped slightly distally whereas the lower first molar moved mesially by 2 mm achieving a class I relationship. These results are in agreement with those of a study by JJ Akinin and al. [10] who reported that in the group of patients presenting adolescent dentition, the maxillary first molar was stable (moved distally by 0.1 mm) while the mandibular molar moved forward by 1.8 mm.

#### 5. CONCLUSION

Orthopedic growth modification with the Distal Active Concept therapy can be attained, provided that the patient's remaining pubertal growth is adequate. Otherwise, the skeletal discrepancy will remain the same, and the class II malocclusion will be corrected only by dental camouflage. Also, this technique relies greatly on patients' compliance with elastic

wear. So, in case of non-compliance, it is recommended to use fixed appliances such as the Forsus™ device.

## CONSENT

All authors declare that written informed consent was obtained from the parents of the patient for publication of this case report and accompanying images. A copy of the written consent is available for review by the Editorial office/Chief Editor/Editorial Board members of this journal.

## COMPETING INTERESTS DISCLAIMER:

Authors have declared that no competing interests exist. The products used for this research are commonly and predominantly used products in our area of research and country. There is absolutely no conflict of interest between the authors and producers of the products because we do not intend to use these products as an avenue for any litigation but for the advancement of knowledge. Also, the research was not funded by the producing company rather it was funded by personal efforts of the authors.

## REFERENCES

1. G. Willems, I. De Bruyne, A. Verdonck, S. Fieuws, and C. Carels, "Prevalence of dentofacial characteristics in a Belgian orthodontic population," *Clin. Oral Investig.*, vol. 5, no. 4, pp. 220–226, Dec. 2001, doi: 10.1007/s007840100128.
2. E. Yüksel Coşkun and E. Esenlik, "A Prospective Study Comparing Adolescent and Post-Adolescent Periods Regarding Effects of Activator Appliance in Patients with Class II Mandibular Retrognathia by Using 3dMDface Analysis and Cephalometry," *Med. Sci. Monit.*, vol. 26, May 2020, doi: 10.12659/MSM.921401.
3. P. Cozza, "Dentoskeletal effects and facial profile changes during activator therapy," *Eur. J. Orthod.*, vol. 26, no. 3, pp. 293–302, Jun. 2004, doi: 10.1093/ejo/26.3.293.
4. M. Kirjavainen and T. Kirjavainen, "Upper Airway Dimensions in Class II Malocclusion," *Angle Orthod.*, vol. 77, no. 6, pp. 1046–1053, Nov. 2007, doi: 10.2319/081406-332.
5. T. Özer, J. D. Kama, and S. Y. Özer, "A practical method for determining pubertal growth spurt," *Am. J. Orthod. Dentofacial Orthop.*, vol. 130, no. 2, p. 131.e1-131.e6, Aug. 2006, doi: 10.1016/j.ajodo.2006.01.019.
6. H. Turkkahraman, S. K. Eliacik, and Y. Findik, "Effects of miniplate anchored and conventional Forsus Fatigue Resistant Devices in the treatment of Class II malocclusion," *Angle Orthod.*, vol. 86, no. 6, pp. 1026–1032, Nov. 2016, doi: 10.2319/122515-887.1.
7. S. Gebeile-Chauty, J.-A. Archer, A. Lautrou, and J.-J. Aknin, "Traitement interceptif DAC: analyse structurale," *Orthod. Fr.*, vol. 78, no. 4, pp. 283–294, Dec. 2007, doi: 10.1051/orthodfr:2007036 (French).
8. S. Dénarié, S. Gebeile-Chauty, and J.-J. Aknin, "Conséquences esthétiques du traitement de la classe II: étude comparative Distal Active Concept (DAC)/Forces Extra-Buccales (FEB)," *Orthod. Fr.*, vol. 81, no. 3, pp. 209–220, Sep. 2010, doi: 10.1051/orthodfr/2010019 (French).
9. S. Gebeile-Chauty, A.-M. Schott, L. Morra, and J.-J. Aknin, "Les forces extra-buccales sont-elles justifiées dans le traitement précoce des classes II?" *Orthod. Fr.*, vol. 80, no. 3, pp. 265–277, Sep. 2009, doi: 10.1051/orthodfr/200902020 (French).
10. J.-J. Aknin and S. Gebeile, "La thérapie du «Distal Active Concept» appliquée à la denture mixte : une étude comparative," *Orthod. Fr.*, vol. 72, no. 4, pp. 355–373, Dec. 2001, doi: 10.1051/orthodfr/200172355 (French).

11. "Class II Skeletal and Class II Dental: Non-Compliant," in *Atlas of Orthodontic Case Reviews*, Hoboken, NJ, USA: John Wiley & Sons, Inc., 2017, pp. 109–126. doi: 10.1002/9781119303787.ch8.

UNDER PEER REVIEW