

Title: **Management of Deeply Carious Pulpally Involved Primary Teeth With Triple Antibiotic Paste – Review and Three Case Reports**

**Abstract**

Root canal treatments are considered as one of the most important therapies in dentistry as they involve in maintaining and preserving the tooth along with its function up to a permissible extent. The root canal system exhibits different as well as complicated anatomical considerations. The necrotic pulp tissue remaining in the canal decreases the effects of root canal irrigants and medicaments and thereby will interfere with the proper and subsequent adaptation of root canal fillings to the dentinal surface. Taking these factors into account, modified disinfection and irrigation treatments are required to properly remove the leftover tissues from the root canal area, as well as to destroy the microorganisms there. Because odontogenic diseases harbour a large number of highly potent microorganisms, numerous treatment combinations, particularly antibiotics, are required to attack the microbiota responsible for the formation of these lesions. Over time as an adjunct to the conventional clinical procedures, antibiotics have begun to enlighten their prime significance. Several antibiotics have been investigated and used to control the dental infections. Triple antibiotic paste (TAP) containing metronidazole, ciprofloxacin and minocycline has been proposed as a root canal medicament due to its highly proven antimicrobial effects in endodontic regenerative procedures. However this combination had been modified in later years to reduce its associated side effects.

**Key Words:** Triple Antibiotic Paste, Pulpotomy, Primary teeth

## **Introduction**

The presence of bacteria within the root canal system is the most common cause of pulp and periapical infections. Because of the morphological and structural variations between primary and permanent teeth, pulpal infections occur more frequently in primary teeth. The enamel layer of deciduous teeth is thinner than the enamel coating of permanent teeth. Multi-visit pulpectomy with stainless steel crown (SSC) or extraction followed by a space maintainer are the traditional treatment options for pulpally damaged teeth<sup>1</sup>. However, pediatric dentists prefer pulpectomy than extractions considering the innumerable benefits of preserving deciduous teeth. But several unconditional factors makes the conventional pulpectomy procedures arduous. The long procedural time taken to effectively complete the procedure will possess as a challenge to the cooperative ability of a child. Second, pulpectomy of abscessed teeth often requires multiple visits with supportive antibiotic therapy. It has been proven that mechanical instrumentation alone is not sufficient in making a bacteria-free environment in canal system<sup>2</sup>. Several in vivo and in vitro experiments have shown that mechanical instrumentation alone is ineffective in properly preparing all regions of the root canal walls and completely eliminating germs.<sup>3</sup> Several well augmented disinfection procedures are required to eliminate microorganisms and their toxins from the root canal system.<sup>4</sup> A suitable material of choice for this would be antibiotics. Thus to overcome these problems the concept of lesion sterilization and tissue repair (LSTR) was introduced which involved the topical placement of triple antibiotic pastes (TAPs) thus aiming to disinfect the canal space and thereby promoting tissue repair.<sup>4</sup> **The following paper presents a mini review about the application of Triple Antibiotic Paste and three case reports in which Triple Antibiotic Paste had been placed following pulpotomy procedure in the primary teeth.**

## **Review**

The complete elimination of microorganisms from the infected root canal is a complex procedure requiring utmost precision and time consumption. Several methods have been evaluated which showed a decline in these microbial colonies. The primary aim of endodontic treatments is to completely eliminate all possible microorganisms from the root canal system and create a favorable sterile environment. This is achieved through the use of aseptic treatment strategies, chemo-mechanical preparation, thorough antimicrobial irrigation, and with suitable intracanal medicaments. Nearly 50-60% of root canal peripherals and ramifications remain uninstrumented. In this existing scenario the remaining infected or necrotic pulpal tissues act as the major nutrition source for the remaining microorganisms in the canal. Hence this can be reduced or eliminated by mechanical instrumentation, thorough irrigation of canals, and placement of medication. In recent years, triple antibiotic paste (TAP), developed by Sato et al. has been shown to be effective in regenerative endodontic procedures on permanent teeth, including necrotic pulp. The literature available determines that the effectiveness of TAP has proven it to be safe for dental use and hence can be used for pulpotomy and pulpectomy in selected deciduous cases. Thus this material has shown several other applications in endodontics which expands its application in varied fields of endodontic therapy.

### **Applications of triple antibiotic paste**

1. Regeneration and revascularization of pulp.

2. Intracanal medicament for the treatment of periapical lesions, external inflammatory root resorption, root fracture and deep carious lesions in primary teeth.
3. Intracanal agent in flare-up cases.
4. Medicated sealer (to prevent possible re-infection)
5. An additive to gutta-percha points in root canal obturation (known as medicated gutta-percha points)

### **Biocompatibility of TAP**

The study conducted by Dasari *et al.* evaluated that the rate of survival of human stem cells of the apical papilla (SCAP) after exposure to different dilutions of TAP showed that, in a clinical situation, a 1000 mg/mL solution is necessary to create pasty slurry for antibiotic pastes. The current clinical situations could be risky for the survival of SCAP cells during TAP dressing and consequently to the ultimate result of dentin-pulp regeneration.<sup>4</sup>

### **The clinical procedure**

Isolation the tooth with rubber dam followed by administration of local anesthetic agent. The carious lesion then removed followed by access cavity preparation .

The most commonly practiced method is as follows cavity is then irrigated with normal saline (0.9%) and dried with cotton pellet. After adequate enlargement of canal orifices the cavity is then filled with triple antibiotic mix and teeth restored with glass ionomer cement, and stainless steel crown is placed in the same visit.<sup>5</sup>

### **Method of preparation**

The antibiotic paste should be freshly prepared and a clean mortar pestle is used for mixing. The three antibiotics ciprofloxacin, metronidazole, and minocycline powder are dispensed and mixed with a ratio of 1:3:3. Then, equal amount of propylene glycol is added to form a creamy paste. Extra paste can be stored in air-tight container for future use. However, the loss of translucency of the paste indicates contamination and it should be discarded. A 20 gauge needle or lentulospirals is placed 1–2 mm short of root apex and medicaments are introduced into the canal using a backfill approach.

### **Triple antibiotic paste removal in young permanent teeth**

The appropriate method for TAP removal is by thorough irrigation and sufficient instrumentation. Complete removal of TAP cannot be achieved by this photon-induced acoustic streaming. Ultrasonic activation is one such widely applied techniques which has given effective results in the removal of TAP from the root canals.<sup>5</sup>

### **Case report-1**

A 5-year old girl reported to the department with the chief complaint of pain in lower right second deciduous molar tooth. The child complained of pain during mastication. The parents stated regarding the child's past dental history that the child had a restoration on the indicative tooth 2 months ago which was done due to caries as reported by the child's parents. The child exhibited Frankel's Type 3 and was cooperative. The child did not exhibit any history of swelling or fever. On clinical and radiographic examination it was found that this tooth had dislodged restoration with slight mobility was identified. **The diagnosis of chronic irreversible pulpitis was made.** All the conventional treatment modalities of pulpectomy and extraction of tooth followed by space maintainer was discussed. However the treatment plan was finalized with the decision of carrying out pulpotomy with placement of Triple Antibiotic Paste was

decided as taking in consideration of child's age and in an attempt of preserving the tooth till its normal exfoliation time.

The child was administered with local anesthesia, Lidocaine 2% with 1:100,000 epinephrine (DENTSPLY, College Ave, York, PA, USA). Following local anesthesia, the remains of dislodged restoration and caries were removed and the pulp chamber access was obtained..

Following which irrigation was thoroughly performed with saline.<sup>5</sup> Triple Antibiotic Paste was mixed to a ratio of 1:3:3 (minocycline, metronidazole and ciprofloxacin) with propylene-glycol as a carrier.<sup>5</sup> The mixture was placed on the pulpal floor and at the canal orifices. A temporary filling was given with zinc oxide eugenol followed by permanent restoration after 15 days and stainless steel crown on 85 after another one month. (Figure. 1-4). Oral hygiene instructions and diet counselling were given to parents. Recall visits for regular checkup to assess the oral status of the child was scheduled every 3 months.<sup>6</sup>

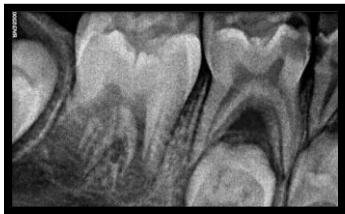

Figure. 1: Preoperative

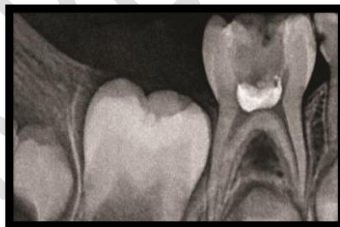

Figure. 2: Postoperative

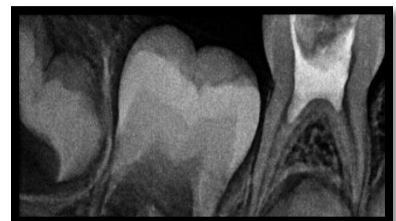

Figure. 3: 15days followup

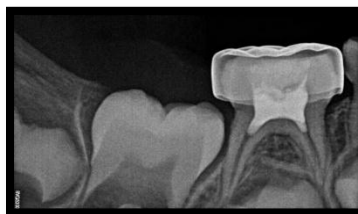

Figure. 4: 1- month follow-up

## Case report-2

A 4-year old boy reported to the department with the chief complaint of pain on upper left back teeth region. The child did not exhibit any history of swelling or fever. This was the child's first dental visit and the child was cooperative exhibiting Frankel's Type 3 behavior. The parents reported that the child complained of severe pain during mastication. Radiographic examination revealed deep carious lesion involving pulp. The diagnosis of chronic irreversible pulpitis was made in relation to upper left first and second deciduous molar teeth. The treatment plan was finalized with the decision of carrying out pulpotomy with placement of Triple Antibiotic Paste as taking in consideration of child's age and in an attempt of preserving the tooth till its normal exfoliation time.

The child was administered with local anesthesia, Lidocaine 2% with 1:100,000 epinephrine (DENTSPLY, College Ave, York, PA, USA). Following local anesthesia, the caries were removed and the pulp chamber access was obtained. Following which irrigation was thoroughly performed with saline. Triple Antibiotic Paste was mixed to a ratio of 1:3:3 (minocycline, metronidazole and ciprofloxacin) with propylene-glycol as a carrier. The mixture was placed on the pulpal floor and at the canal orifices of both the teeth. The teeth were then sealed with final restoration of GIC and stainless steel crowns were placed in the same visit.<sup>7</sup> (Figure. 5-6).

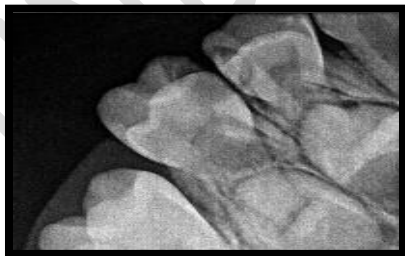


Figure. 5: Preoperative

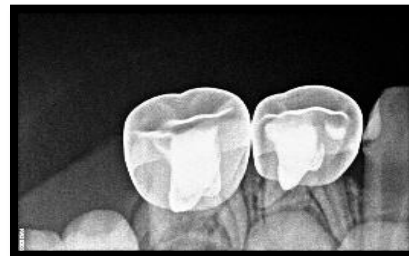

Figure. 6: Postoperative

### report -3

A 7-year old boy reported to the department with the chief complaint of pain on lower right back tooth. The child had past dental history of extraction of root stumps in relation upper front deciduous teeth as reported by the parents. The child exhibited Frankel's Type 3 and was cooperative. On clinical and radiographic examination it was found that the tooth was tender on percussion. Radiographic examination revealed deep carious lesion involving pulp. The diagnosis of chronic irreversible pulpitis was made in relation to lower right deciduous second molar tooth. The treatment plan was finalized with the decision of carrying out pulpotomy with placement of Triple Antibiotic Paste in an attempt of preserving the tooth till its normal exfoliation time.

The child was administered with local anesthesia, Lidocaine 2% with 1:100,000 epinephrine (DENTSPLY, College Ave, York, PA, USA). Following local anesthesia, the caries were removed and the pulp chamber access was obtained. A #10 K-file with RC Prep (Premier, Philadelphia, USA) was used to scout the coronal 5mm of the canals. Irrigation was performed with 1% sodium hypochlorite. TAP was mixed to a ratio of 1:3:3 with propylene-glycol as a carrier. The mixture was placed on the pulpal floor and at the canal orifices of both the teeth. The teeth were then sealed with temporary restoration of zinc oxide eugenol and then restored with stainless steel crowns after 30 days and reviewed after three months after review.<sup>7-8</sup> (Figure. 7-9).

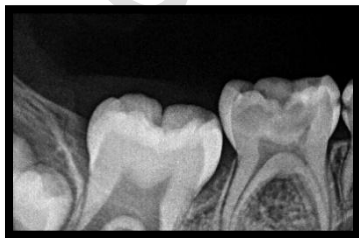

Figure. 7: Preoperative

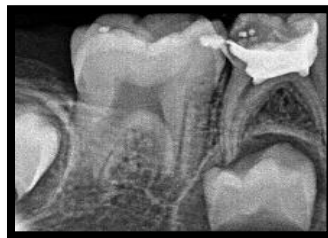

Figure. 8: Postoperative

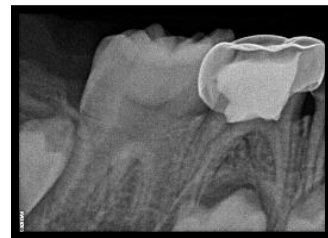

Figure. 9: 1- month follow-up

## **Discussion**

LSTR is an acronym for lesion sterilization and tissue repair. In this method a combination of antibiotics (metronidazole, ciprofloxacin, and minocycline) which are used for controlling of oral infections such as dentinal, pulpal, and periapical lesions.

All the three tablets are powdered and the contents are mixed to a paste with propylene glycol acting as a carrier. The triple antibiotic paste (TAP) contains 1 part of ciprofloxacin and 3 parts of metronidazole and 3 parts of minocycline by weight. Ciprofloxacin is a synthetic fluoroquinolone and has a bactericidal effect. Metronidazole is a broad spectrum nitroimidazole compound active against protozoa and other anaerobic microorganisms. The third drug minocycline is a synthetic derivative of tetracycline with a similar spectrum of action as that of tetracycline. This recent technique of disinfecting the developed oral lesion was invented by the Cariology Research Unit of Nigata University School of Dentistry.<sup>7-8</sup> The important uses of TAP includes pulp regeneration and revascularization of young permanent teeth. In primary teeth a permanent restoration is usually placed in the same visit once the triple antibiotic paste is applied at the canal orifices or introduced into the root canals. The wide spectrum antibacterial activity of Metronidazole due gained its inclusion as the 1st choice drug for triple antibiotic paste preparation. Metronidazole binds to the DNA and disrupts its helical structure and thus leads to rapid cell death. In order to remove all bacteria, the two more antibacterial medications, ciprofloxacin and minocycline (3MIX), were added. Ciprofloxacin, the second medicine of choice, is a synthetic fluoroquinolone that has a quick bactericidal effect and inhibits bacteria's DNA gyrase. It exhibits very potent activity against Gram-negative bacteria. Minocycline is a semisynthetic derivative of tetracycline, primarily bacteriostatic, inhibiting protein synthesis by

binding to 30S ribosomes in susceptible organisms and exhibits broad spectrum activity, however it has got few side effects including tooth discoloration.<sup>7-8</sup>

The first case report follows the technique which was explained by studies conducted by Pinky et.al which showed 100% success rates and complete healing of the lesion. The second and third case reports follows the technique described by Raslan *et al.* and Singh *et al.* who explained that the overall success rates of the 3 Mix group and the ciprofloxacin-metronidazole-clindamycin group were 80.96% and 76.20%, respectively, with no statically significant difference.<sup>7-8</sup>

Another important fact which justifies the use of instrumentation on coronal preparation as carried out in third case report justifies the findings similar to studies conducted by Pinky and Shashibhushan *et al.* which states that on comparing two different methods of performing TAP pulpotomies showed success with either method, with instrumentation of the coronal pulp being more successful than the non-instrumentation group.<sup>5-8</sup> 3 Mix versus ciprofloxacin-minocycline-ornidazole mixture. At 3, 6, and, 12 month follow-up, according to Pinky et al. and Singh *et al.* no statistically significant difference was reported when comparing the clinical and radiographical success rates between ciprofloxacin-minocycline-metronidazole mixture (3 Mix) and ciprofloxacin-minocycline-ornidazole mixture; both groups showed 100% clinical success.<sup>7-</sup>

8

TAP shown to be highly efficient and systematically effective when utilized for pulpal treatment of chronically infected deciduous dentition. Results of 12-month clinical studies comparing conventional pulpectomy procedures to triple antibiotic paste based pulpotomies found that the success rate of these two procedures are comparatively similar.<sup>9-10</sup> The clinical success rates of TAP pulpotomies and conventional pulpectomies were 100% and 96% respectively which were calculated at systematic interval time periods of both six and 12-month intervals.<sup>12</sup> A recent study comparing two different methods of performing TAP pulpotomies showed success with

either method, with instrumentation of the coronal pulp being more successful than the non-instrumentation group. <sup>11-12</sup> Replacement of minocycline with clindamycin or doxycycline can overcome the problem of tooth discoloration up to an acceptable level. <sup>12</sup> Furthermore, some scientists' advocated use of dentin- bonding agent before placement of triple antibiotic paste to reduced discoloration.

### **Conclusion**

Endodontic treatments rely mainly upon the elimination of the involved micro biota from the root canal system. Biomechanical instrumentation does not always provide such an environment in the root canal system. Non-instrumentation methods strategies including regeneration and revascularization of the pulp should be considered especially with antibiotics. Amongst the various combination of antibiotics TAP, owing to its effectiveness on different microorganisms and its diverse applications and triumphs, is of particular interest in endodontic therapy.

The conducted studies till date clearly defines that TAP can be effectively and efficiently used for root canal sterilization and periapical healing in cases of an existing pathological condition. The ability of TAP in managing non-vital young permanent tooth is based on the viable stem cells that are present. Pertaining to the possible draw backs of development of resistant bacterial strains and tooth discoloration TAP appears to be an efficacious material of choice in endodontic therapy.

## **Ethical Approval:**

As per international standard or university standard written ethical approval has been collected and preserved by the author(s).

## **Consent**

As per international standard or university standard, patients' written consent has been collected and preserved by the author(s).

## **References**

1. Nanda R, Koul M, Srivastava S, et al. Clinical evaluation of 3 Mix and other Mix in non-instrumental endodontic treatment of necrosed primary teeth. J Oral Biol Craniofacial Res 2014;4(2):114–119. DOI: 10.1016/j.jobcr.2014.08.003.
2. Jayam, A. bandlapalli, and H. M. Rao, “And kapil s, “lesion sterilization and tissue repair (LSTR): a review,” *Journal of Scientific Dentistry*, vol. 4, pp. 49–55, 2014.

3. Bansal R, Jain A. Overview on the current antibiotic containing agents used in endodontics. *N Am J Med Sci.* 2014;6:351–358.
4. Dasari V, Maroli S, Chowdary L, et al. An in vivo study evaluating lesion sterilization and tissue repair 3 MIX-MP noninstrumentation endodontic treatment as an alternative to conventional endodontic retreatment. *J Heal Res* 2016;3(4):284.
5. C. Pinky, V. Subbareddy, and K. Shashibhushan, “Endodontic treatment of necrosed primary teeth using two different combinations of antibacterial drugs: an in vivo study,” *Journal of Indian Society of Pedodontics and Preventive Dentistry*, vol. 29, no. 2, pp. 121–127, 2011
6. N. Singh, R. Dwivedi, U. C. Chaudhary, R. Singh, S. Faisal, and A. Singh, “Lesion sterilization and tissue repair therapy in primary teeth,” *International Journal of Current Research*, vol. 11, 2017, <https://www.journalcra.com/article/lesion-sterilization-and-tissue-repair-therapy-primary-teeth>.
7. N. Raslan, O. Mansour, and L. Assfoura, “Evaluation of antibiotic mix in Non-instrumentation Endodontic Treatment of necrotic primary molars,” *European Journal of Paediatric Dentistry*, vol. 18, pp. 285–290, 2017.
8. Reddy, G. A., Sridevi, E., Sankar, A. S., Pranitha, K., Gowd, M. P., & Vinay, C. (2017). Endodontic treatment of chronically infected primary teeth using triple antibiotic paste: An in vivo study. *Journal of Conservative Dentistry*, **20**(6), 405.
9. Parhizkar, H. Nojehdehian, and S. Asgary, “Triple antibiotic paste: momentous roles and applications in endodontics: a review,” *Restorative Dentistry & Endodontics*, vol. 43, no. 3, 2018.
10. Z. Mohammadi, H. Jafarzadeh, S. Shalavi, S. Yaripour, F. Sharifi, and J. I. Kinoshita, “A review on triple antibiotic paste as a suitable material used in regenerative endodontics,” *Iranian Endodontic Journal*, vol. 13, no. 1, pp. 1–6, 2018.

11. Zacharczuk, G. A., Toscano, M. A., Lopez, G. E., & Ortolani, A. M. (2019). Evaluation of 3Mix-MP and pulpectomies in non-vital primary molars. *Acta Odontológica Latinoamericana*, **32**(1), 22– 28.
12. M. L. Duarte, P. M. Pires, D. M. Ferreira et al., “Is there evidence for the use of lesion sterilization and tissue repair therapy in the endodontic treatment of primary teeth? A systematic review and meta-analyses,” *Clinical Oral Investigations*, vol. 24, no. 9, pp. 2959–2972, 2020.

UNDER PEER REVIEW