

Maxillary rehabilitation with combined fixed-removable prosthesis using extra coronal semi precision attachment: case report.

Abstract

Creating a hybrid prosthesis using attachments can be a challenging task for the dentist and for dental technician. The dentist should take into consideration the patient's preferences and requests as well as functional and esthetic demands.

Experience and knowledge on the part of the dentist and laboratory technician of difficulties and limitations of each clinical and laboratory step are essential components to successful fabrication and maintenance of these relatively complex restorations.

This article reports a full mouth rehabilitation utilizing fixed and cast removable partial prosthesis, combining them with extra coronal castable semi precision attachment (Ceka preciclix 1271 extra coronal attachment).

Introduction:

Over the past few decades, dental implant therapy became widely acceptable and gained a lot of success and notoriety as the treatment of choice to restore missing teeth, this is true when all factors are favorable but not all patients are good candidates for this treatment modality as there are certain constraints to dental implant therapy such as unfavorable regional anatomy, uncontrolled systematic disease, high dose head and neck radiation, extreme surgical risk or even financial restrictions.^(1,2,3)

Combining fixed and removable partial prosthesis can be considered as an alternative treatment for the rehabilitation of function and esthetics in the case of posterior edentulous arch where abutment teeth are unable to withstand occlusal forces.

The removable partial denture component that engages abutment teeth to resist dislodging forces to make it retentive are either retainers or attachments.^(4,5,6)

The incorporation of attachments can be challenging and needs proper evaluation and respect of rigorous treatment plan to ensure long term clinical success of final restorations. ^(4,5,6).

This article reports a full mouth rehabilitation utilizing fixed and cast removable partial prosthesis, combining them with extra coronal castable semi precision attachment (Ceka preci-clix 1271 extra coronal attachment).

Case report:

A 55-year-old female patient with no relevant medical history was referred to the department of removable partial dentures at the dental clinic of Monastir for prosthetic rehabilitation.

Clinical and radiographic examination revealed at the maxilla the presence of teeth 8,7,6,9,11,12,13 and no mobility, and several insufficient endodontic treatments, defective crown fillings with recurrent caries were noted, along with a favorable crown to root ratio for all teeth. (Fig1,2)

The palate is moderately deep and wide. The edentulous ridge is rounded, moderately high and wide. Tuberosities are well formed and covered by an adherent fibro-mucosa. (Fig1)

At the mandible clinical and radiographic examination revealed the presence of teeth 24,23,22,25,26,27,28,29,18 with an important overlap in the anterior region and no mobility. Several insufficient endodontic treatments, defective crown fillings with recurrent caries were noted. (Fig 1)

All teeth have a favorable crown to root ratio except for the 25,26,24,23 which have unfavorable crown to root ratio and grade 1 degree mobility. (Fig2)

The edentulous ridge is resorbed. The right retromolar pad is resorbed and covered by a firm and adherent fibro-mucosa. (Fig1)

Occlusal examination revealed a maintained vertical dimension of occlusion, an alteration of occlusal plane, dysfunctional anterior guidance, sufficient prosthetic space. (Fig1)

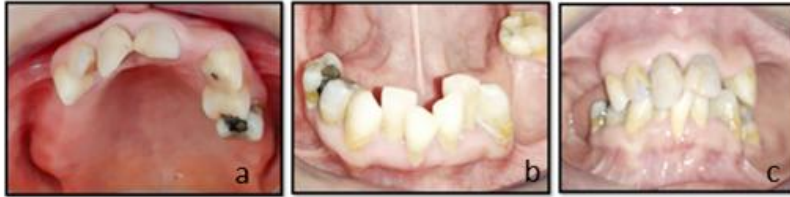

Fig1: Pre-operative intraoral view : a: maxillary arch; b: mandibular arch; c: arch in occlusion.

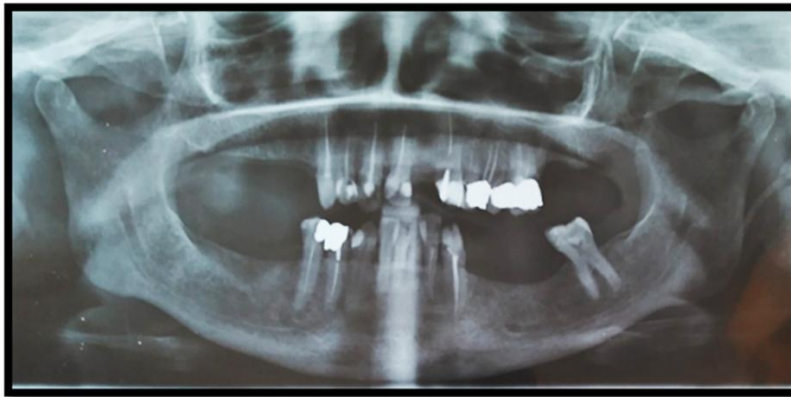

Fig2:Pre-operative panoramic Radiograph .

The preparatory phase included motivation to oral hygiene instructions, extraction of teeth 25,26,24,23, root canal treatments on teeth 12,13,28,29, cavity fillings for teeth 12,13,28,29,18. Considering the extensive caries lesions on teeth 8,7,6 inlay cores were fabricated to improve retention value. (Fig3)

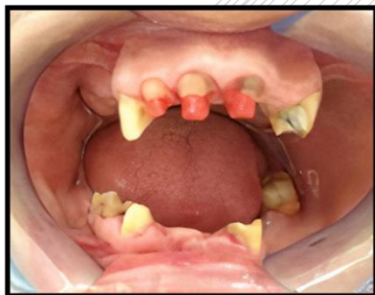

Fig 3: inlay core in calcifiable pattern.

The patient was informed about different treatment modalities, implant dental therapy was rejected for financial limitations, and opted for a combined fixed and

cast removable partial prosthesis retained with semi precision attachments at the maxilla for a better esthetic outcome.

For the mandible the decision was a combined fixed and cast removable prosthesis, attachments weren't indicated for the mandible since the visibility of buccal clasp arm was not a concern.

To Proceed with the treatment plan, diagnostic wax up was fabricated to study the feasibility of the prosthetic rehabilitation and to serve as model for the fabrication of temporary prosthesis as well as a communication tool with the patient. (Fig 4)

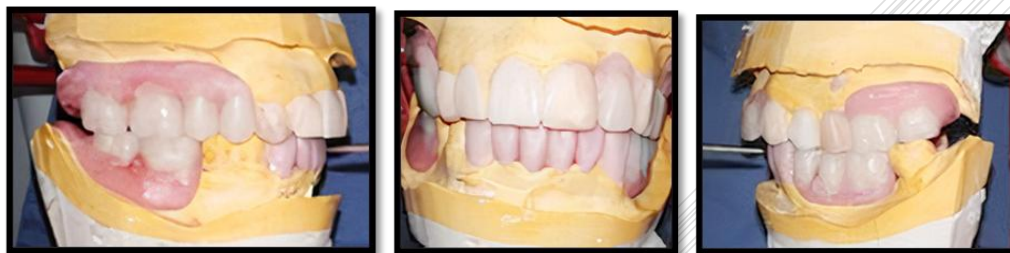

Fig4: Realization of a wax up.

Temporary restorations were essential for the success of treatment plan since they serve as a template for the fabrication of definitive prosthesis and enable clinician evaluate function, esthetics, and phonetics including anterior guidance, vertical dimension of occlusion and occlusal concept. ⁽¹⁾.

After evaluating patient's adaptation to provisional restorations, teeth preparation was finalized and followed by final impressions made with heavy and light silicone materials. (Fig 5)

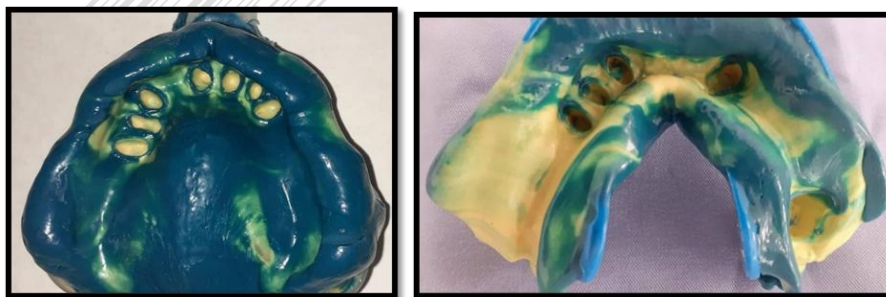


Fig 5: maxillary and mandibular impressions for fixed prosthesis with heavy and light silicone material.

The maxillary working cast was mounted to a semi adjustable articulator using a facebow. Maxillo-mandibular jaw relation was recorded with occlusal rims and used to articulate mandibular working cast.

Wax pattern of fixed restorations was sculpted, and the design included splinting of abutment teeth to ensure evenly distributed occlusal forces to all teeth. (Fig6)

wax teeth arrangement was performed followed by the fabrication of a buccal silicone matrix to analyze the available mesiodistal and occlusogingival space to select the appropriate attachment. (Fig 6)

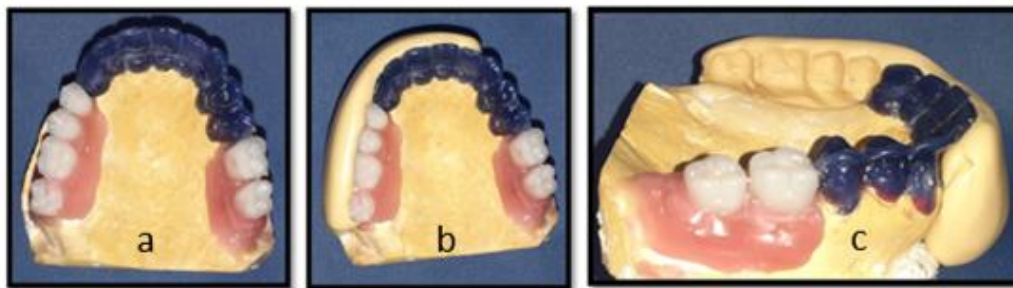


Fig6: buccal silicone matrix to evaluate the available mesiodistal and occluso-gingival space analysis for the selection of attachment: a: wax arrangement of artificial teeth; b: buccal silicone matrix over artificial teeth; c: removing artificial teeth to evaluate prosthetic space.

Maxillary and mandibular working cast were surveyed to determine the most favorable path of insertion then palatal and lingual shelves were carved in the wax patterns for the reciprocating clasp arms and a mesial occlusal rest seat was carved on wax pattern of tooth 18. At this step, attachment was placed (precliclix male keeper) (Fig7) using a surveyor to ensure respect of parallelism followed then by positioning of buccal silicone matrix to control prosthetic space. (fig7)

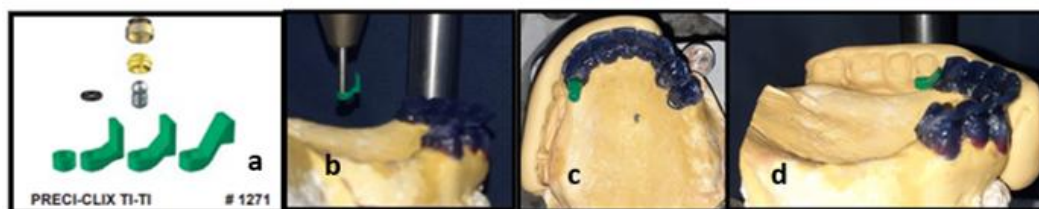


Fig 7: Attachment placement: a: attachment presentation; b: the attachment positioned using a surveyor; c, d: verification of attachment position using silicone matrix.

After casting and reevaluation of prosthetic space (Fig 8), metal copings try in was done and fixed partial dentures were veneered with resin using a pressure/ heat-curing micro-filled veneering material (SR chromasit Ivoclar Vivadent), shade selection was done before teeth preparation according to skin color and age.

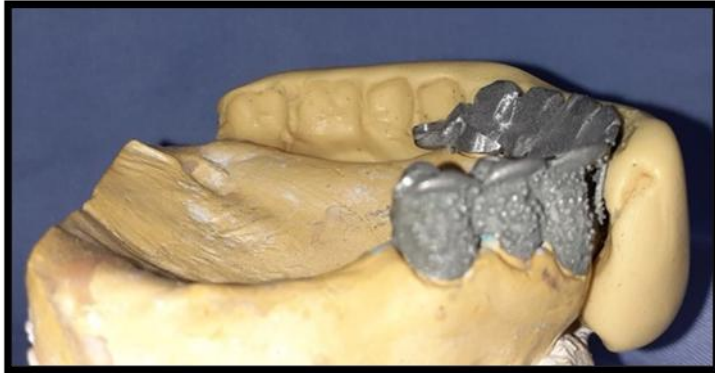

Fig 8: Casting of metal copings and reevaluation of space with buccal silicone matrix.

Anatomical and functional pick-up impressions were taken with acrylic custom trays after border molding with polyether material (3M ESPE Impregum™ Soft FRANCE) then poured. Polyether material is ideal for pick up impressions, it's well known for its rigidity and precision. This enables the dental technician to accurately design and relate the cast removable partial denture to the fixed partial denture. (Fig 9)

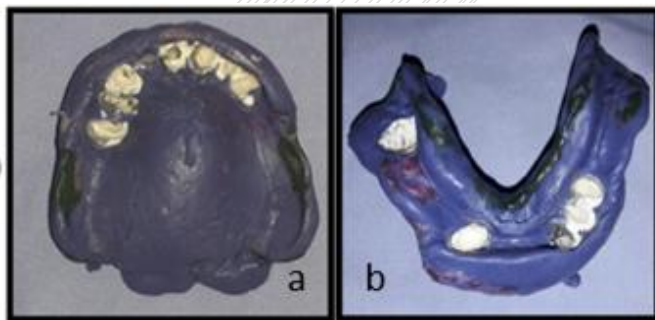


Fig 9: Anatomical and functional pick-up impressions with polyether material, the crowns were provisionally seated for a better stability during the impression: a: Maxillary impression; b: mandibular impression.

Preci-clix duplicating dummy and housing were positioned on the maxillary working cast, then duplicated with reversible hydrocolloid and refractory cast was produced followed by the design and waxing of framework. (Fig10)

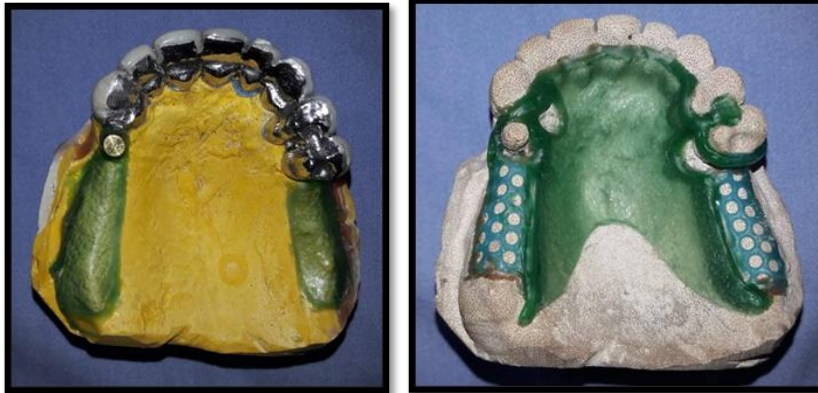

Fig 10: Positioning of preci-clix duplicating dummy and housing on the master cast before making the refractory cast and waxing of metal framework..

The framework was casted in a cobalt- chromium alloy and try-in was carried in the patient's mouth. Artificial teeth shade was selected using as a reference provisional prosthesis for shape and position.

Maxillomandibular jaw relation was record and wax teeth arrangement were done by dental laboratory technician and try in was made to check for occlusion and esthetics. (Fig 11)

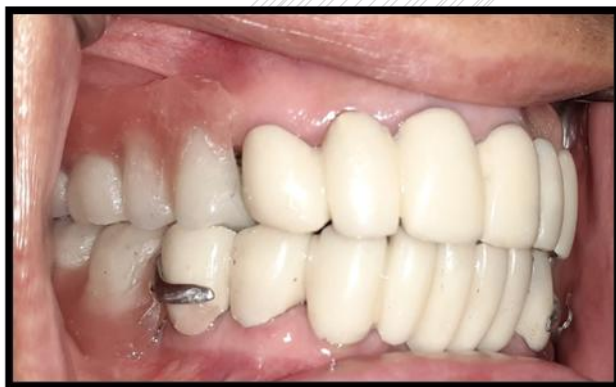

Fig 11: Wax teeth arrangement try in.

The dentures were processed with heat polymerized acrylic resin using conventional technique.

On the final appointment, the titanium male of attachment was cemented in the cast male keeper with glass ionomer cement and rubber dam was placed to prevent self-curing resin flow under the attachment, female part of attachment was attached to the cast removable partial denture with self-curing resin after checking of occlusion. (Fig 12,13,14)

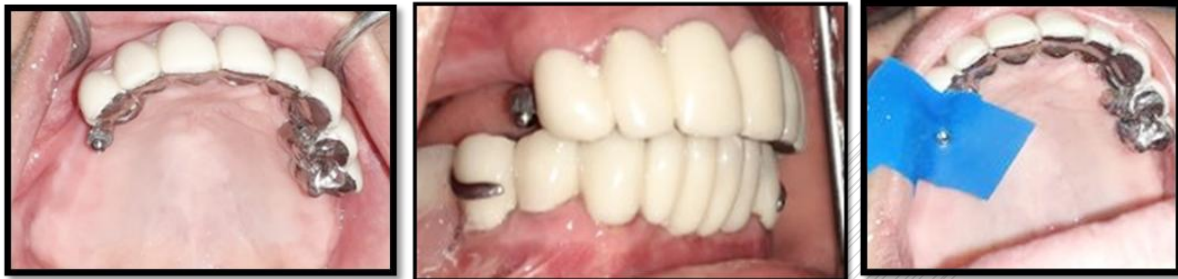

Fig 12: Cementing of the titanium male in the cast male keeper and positioning of rubber dam.

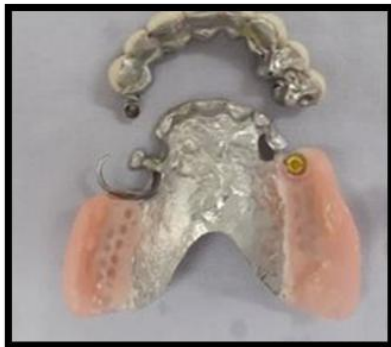

Fig 13: securing female part to the maxillary cast removable denture with self curing resin.

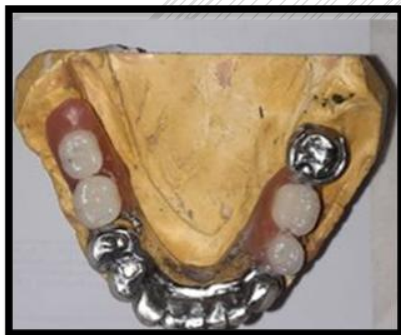

Fig 14: Mandibular combined fixed removable partial prosthesis.

Fixed partial prosthesis was cemented with glass ionomer cement, immediately followed by positioning of removable partial denture to ensure accurate fit and to preserve the path of insertion. Minor occlusal adjustments were carried out and recall programs were scheduled for the patient. (Fig15)

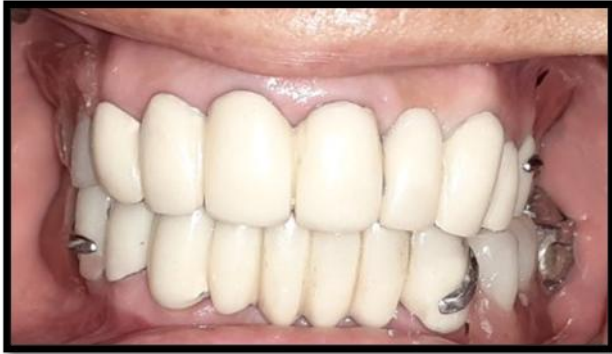

Fig 15: Final prosthetic result.

Discussion:

Attachments can be described as a connector used to join either two fixed restorations or fixed restoration and removable partial prosthesis, it's composed of two closely fitting components. The first component or Matrix is positioned within the normal contours or expanded contours of a cast restorations placed on abutment teeth and the second component or Patrix is attached to the Pontic or removable prosthesis. ^(8,14).

Attachments are classified into precision and semi precision devices. For semi-Precision attachments some or all parts are cast from calcinable patterns while precision attachments are made from prefabricated alloys. Semi precision attachments are less accurate and may lead to errors in the chain of construction of attachment retained prosthesis such as misfit between different components, impairing in insertion and removal path of prosthesis, less resistance to wear and occlusal stress on abutment teeth. ^(7,15,16).

Attachments may offer some advantages. The visibility of buccal arm clasp can be esthetically unacceptable especially when placed on maxillary anterior teeth or premolar abutments. The use of attachments eliminates the need for buccal clasp

arm which results in a better esthetic appearance and a better psychological acceptance of prosthesis. Furthermore, attachments are less stressful to abutment teeth than conventional clasp considering lower torque is applied to abutment teeth in a cervical direction during functional movements. ^(7,1,9,19).

On the other hand, attachments may exhibit several disadvantages such as invasive teeth preparation which can compromise tooth vitality especially if an intracoronal attachment is used, gingival irritation and inflammation if good oral hygiene is not respected, in addition attachments will wear overtime which requires maintenance and subsequently added costs to the patient. ^(7,10,11,12,19).

In the present case, we are faced with posterior edentulous arch, so the design of removable partial denture needs to follow the concept of “broken stress philosophy” which leads to reduced stress on abutment teeth by deriving optimal support from adjacent edentulous ridge. ^(17,18).

Many extra coronal attachments are resilient which means that they permit movement of denture base during occlusal loading, thus indicated in the case of posterior edentulous ridge to ensure evenly distributed forces throughout the arch. ^(13,17).

Meticulous clinical and radiographic examination also careful evaluation of mounted study casts are crucial when considering the use of attachments, these exams provide us with important information concerning crown to root ratio, periodontal health, oral hygiene, height of abutment teeth and eventually prosthetic space. ⁽¹⁹⁾.

Conclusion:

Despite desirable improvements in esthetics, retention and functional efficiency, the use of attachments requires adequate cooperation, good manual dexterity as insertion and removal of removable prosthesis can be challenging for some patients and commitment to recall programs.

Hybrid prosthesis using extra-coronal attachments remain an acceptable esthetic prosthetic alternative. The dentist as well as the dental technician should be well formed to guarantee the success of such treatment modality.

Disclaimer regarding Consent and Ethical Approval:

As per university standard guideline, participant consent and ethical approval have been collected and preserved by the authors

COMPETING INTERESTS DISCLAIMER:

Authors have declared that no competing interests exist. The products used for this research are commonly and predominantly use products in our area of research and country. There is absolutely no conflict of interest between the authors and producers of the products because we do not intend to use these products as an avenue for any litigation but for the advancement of knowledge. Also, the research was not funded by the producing company rather it was funded by personal efforts of the authors.

Bibliography:

1. Michael Patras, Nikitas Sykaras. Esthetic and functional combination of fixed and removable prostheses. *Gen Dent* Mar-Apr 2012;60(2): e47-54.
2. Gallucci GO, Morton D, Weber HP. Loading protocols for dental implants in edentulous patients. *Int J Oral Maxillofac Implants* 2009;24 Suppl:132-146.
3. Byron R Jr, Frazer RQ, Herren MC. Rotational path removable partial denture: An esthetic alternative. *Gen Dent* 2007;55(3):245-250.
4. J. L. Bakers and R. J. Goodkind, *Precision Attachment Removable Partial Dentures*, Mosby, San Mateo, Calif, USA, 1981.
5. D. R. Burns and J. E. Ward, "Review of attachments for removable partial denture design: part 1. Classification and selection," *The International Journal of Prosthodontics*, vol. 3, no. 1, pp. 98–102, 1990.
6. D. R. Burns and J. E. Ward, "A review of attachments for removable partial denture design: part 2. Treatment planning and attachment selection," *The International Journal of Prosthodontics*, vol. 3, no. 2, pp. 169–174, 1990.
7. José Mauricio dos Santos Nunes Reis, Luciano Elias da Cruz Perez, Bruna Fernandes Moreira Alfenas. Maxillary rehabilitation using fixed and removable partial dentures with attachments: A clinical report. *Journal of Prosthodontics* 2014 Jan;23(1):58-63.

8. Sakshi Gupta, Sapna Rani, Arpit Sikri, Aditya Kapoor. Attachment retained cast partial denture: Conventional and contemporary treatment perspectives. *International Journal of Oral Care and Research*. 2016;4(4):312-316.
9. Gopinadh Anne, Krishna Kishore Kadiyala H, Ravi Rakesh Dev J, Mohan Krishna Badisa. Full mouth rehabilitation using fixed partial denture and cast partial denture with attachments and conventional lower denture - A case report. *International Dental Journal of Students Research*. 2017;5(1):25-28.
10. Sharad Vaidya, Charu Kapoor, Yujika Bakshi, Sonam Bhalla. Achieving an esthetic smile with fixed and removal prosthesis using extracoronary castable precision attachments. *The Journal of Indian Prosthodontic Society*. 2015;15(3).
11. Gulshan Kumar Tomar, Mirna Garhnyak, Sitansu Sekhar Das, Shelly Roy. Cast partial denture retained using precision attachment – A case report. *IOSR Journal of Dental and Medical Sciences*. 2016;15(7): V:94-99.
12. Agripina Zaharia, Aureliana Caraiane, Corina Ștefănescu, Rodica Murineanu. Fixed dentures combined with removable dentures retained with extracoronary attachments. *Ovidius Dentistry Journal*. 2014;1(1).
13. Baker JL, Goodkind RJ. A comparison of nonresilient and resilient attachments. The use of "stress directors." In: *Theory and Practice of Precision Attachment Removable Partial Dentures*. St Louis: Mosby, 1981:190–197.
14. Becerra G, MacEntee M. A classification of precision attachments. *J Prosthet Dent* 1987; 58:322–327.
15. Blatterfein L. The use of the semiprecision rest in removable partial dentures. *J Prosthet Dent* 1969; 22:307–332.
16. Boitel RH. Precision attachments: An overview. In: Tylman SD, Malone WFP (eds). *Tylman's Theory and Practice of Fixed Prosthodontics*, ed 7. St Louis: Mosby, 1978:501–568.
17. Wang HY, Zhang YM, Yao D, **Chen JH**. Effects of rigid and nonrigid extracoronary attachments on supporting tissues in extension base partial removable dental prostheses: a nonlinear finite element study. *J Prosthet Dent*. 2011 May;105(5):338-46.
18. Cohn LA. The physiologic basis for tooth fixation in precision-attached partial dentures. *J Prosthet Dent* 1956; 6:220–244.
19. Cunningham DM. Indications and contraindications for precision attachments. *Dent Clin North Am* 1970; 14:595–601.

