

# Reversible Coronary Spasm Induced by Marcaine Mimicking Non-ST Segment Elevation Myocardial Infarction in a Young Patient: A Case Report

## Case Report

### ABSTRACT

Bupivacaine (marcaine) is a long-acting local anesthetic used for skin infiltration, peripheral nerve blocks, epidural and spinal anesthesia. Its application can lead to cardiovascular complications such as: hypotension, bradycardia, cardiac arrest and toxic myocardial injury. Few cases of coronary artery spasm induced by bupivacaine mimicking myocardial infarction have been reported in the literature. We report a case of a reversible coronary spasm induced by marcaine during spinal anesthesia confirmed by a provocative vasoactive test on coronary angiography in a 38-year young patient without a known cardiovascular disease admitted initially for scheduled fissurectomy and hemorrhoidectomy in whom treatment by calcium channel blockers reversed patient's symptoms and electrophysiology signs.

*Keywords: Spinal anesthesia; coronary spasm; myocardial infarction.*

### 1. INTRODUCTION

"Bupivacaine is a long-acting local anesthetic widely used for skin infiltration, peripheral nerve blocks, epidural and spinal anesthesia. However, its application can lead to cardiovascular complications such as: hypotension, bradycardia, cardiac arrest and toxic myocardial injury" [1]. "Cardiovascular side effects can be divided into two 2 categories; one is relative to the degree of myocardial conduction depression whilst the second is relative to negative inotropic action" [2]. "Data on cardiac events caused by epidural injection of anesthetics products is limited" [3] We report a case of a reversible coronary spasm induced by bupivacaine (marcaine) during spinal anesthesia confirmed by the vasoactive test on coronary angiography in a young patient with a fortuitous discovery of diabetics Mellitus type 2 who was initially admitted at the gastroenterology department for scheduled fissurectomy and hemorrhoidectomy operation.

### 2. CASE PRESENTATION

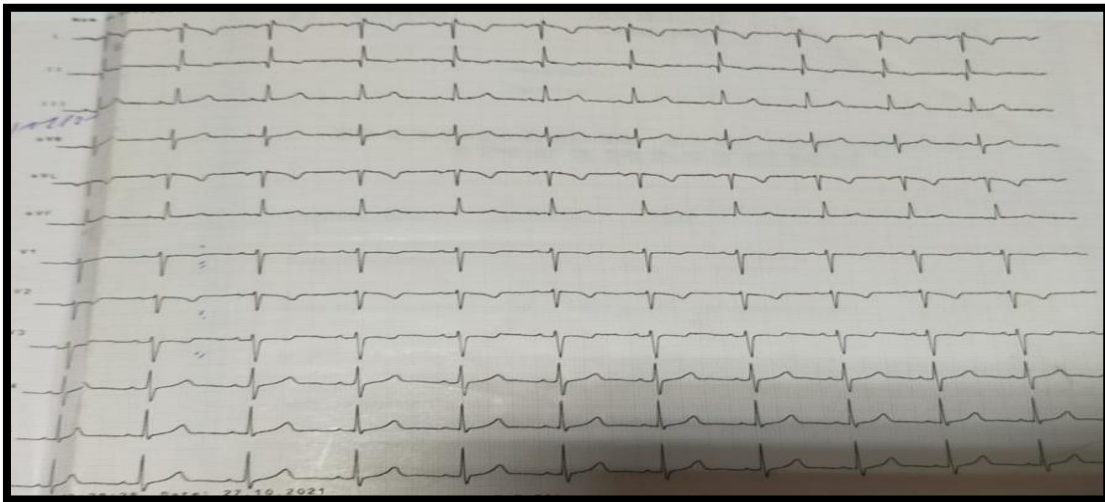
A 36-year-old patient with a history of COVID-19 infection treated 3 months before was transferred

to the cardiology emergency department for typical acute constrictive retrosternal chest pain radiating to the upper left arm with no other associated clinical signs, 30 minutes after receiving spinal anesthesia with bupivacaine (marcaine) and fentanyl for scheduled fissurectomy and hemorrhoidectomy operation. On admission the patient presented moderate chest pain compared to the time of anesthesia infusion. Physical exam showed a blood-pressure (BP) of 120mmHg systolic-pressure and 80mmhg diastolic-pressure, heart rate of 85 beats per minute, body temperature of 36.9°C and good atmospheric oxygen saturation (99%). The cardiovascular and pleuropulmonary examination was without abnormalities. The ECG taken at the time of attack showed negative T wave repolarization disorders in septo-apical and lower lateral leads which became normal after transfer to the cardiology emergency department (Figs. 1 and 2). The echocardiography performed showed no wall motion abnormalities with an LVEF of 66% according to biplane Simpson calcul (Fig. 3). Biological assessments showed a rise in the high sensitive cardiac troponin marker to 1204ng/ml with a recent fortuitous discovery of diabetes mellitus type 2, elevated glycated

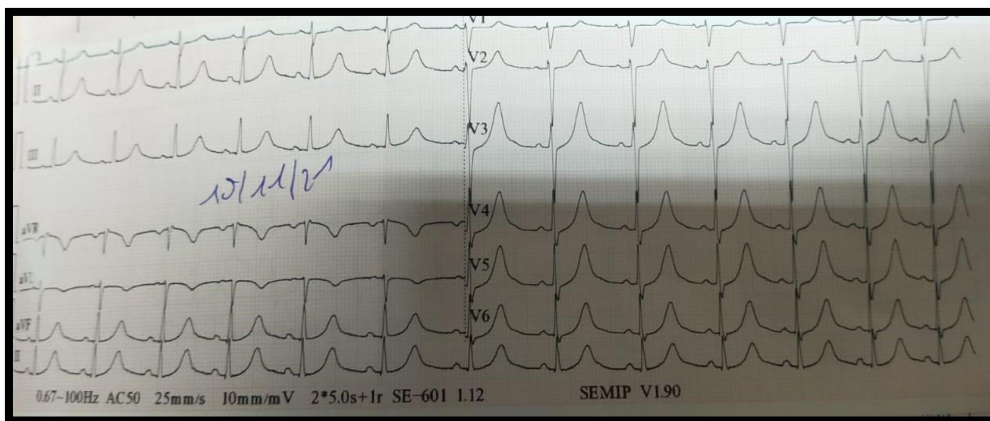
hemoglobin (HBA1c) at 7.8%. The rest of the biological assessment was without abnormality, namely normal liver and kidney function.

In this situation, diagnostic hypotheses evoked were either non-ST segment elevation myocardial infarction (NSTEMI), stress-induced cardiomyopathy, cardiac toxicity mimicking an NSTEMI due to spinal anesthesia products of (marcaine-fentanyl), takotsubo cardiomyopathy mimicking myocardial infarction or coronary spasm. Coronary angiography showed healthy coronary arteries network without visualization of atherosclerotic plaques (Fig. 4).

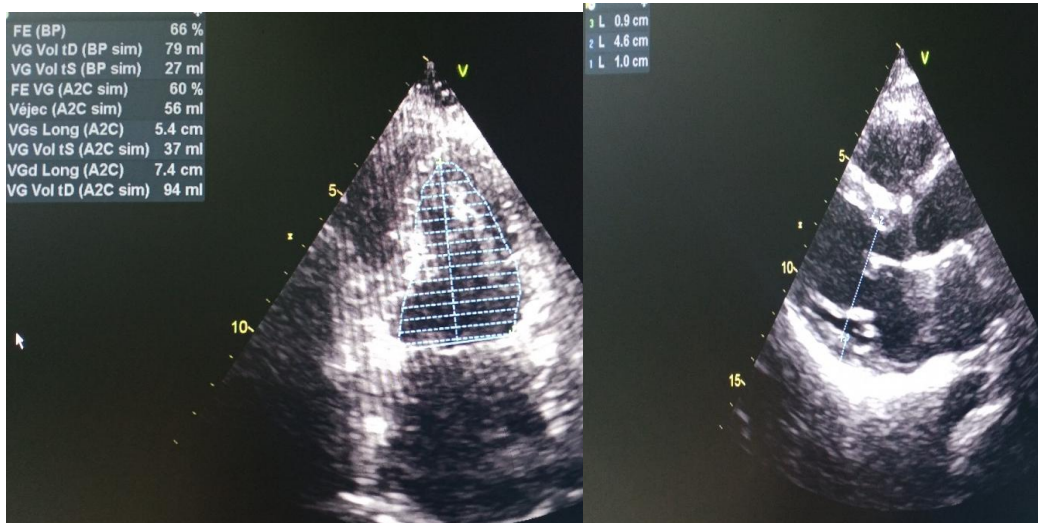
The diagnosis of coronary spasm was retained in view of the stupefaction of the angina, normalization of the ECG after sedation of the angina, normal echocardiography findings, normal coronary angiography and regression of the high sensitive cardiac troponin marker. The patient was prescribed on discharge a calcium channel blocker based on amlodipine 5mg 1/2 tab/day and vasodilator based on nicorandil with an identity card of allergy to bupivacaine (marcaine).



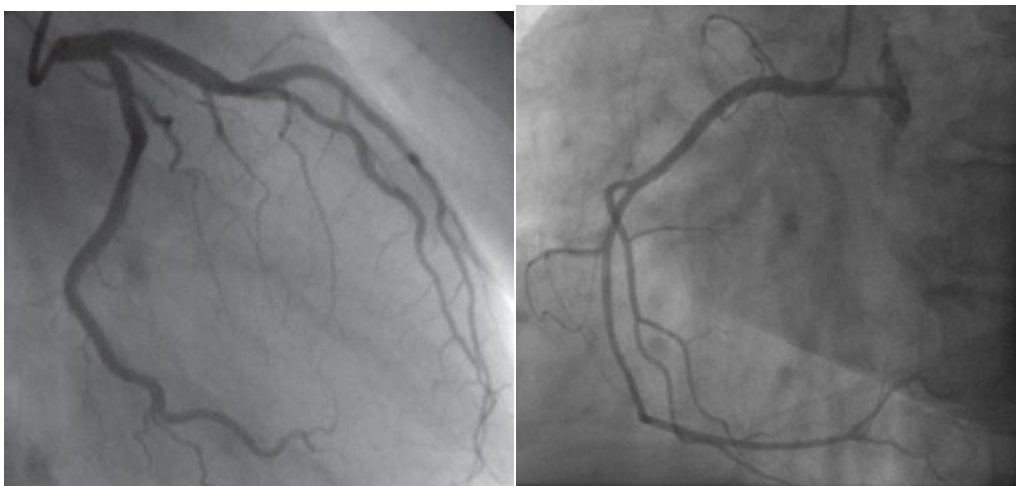**Fig. 1. ECG during per-critical chest pain showed Negative T wave in the septo-apical and lower lateral leads**



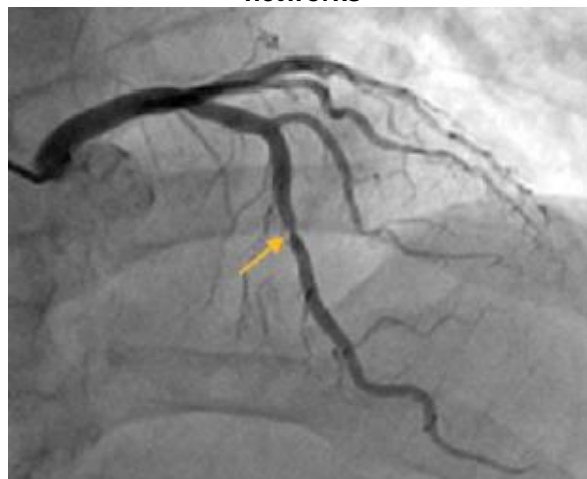**Fig. 2. ECG after transfer to the ICU**



**Fig. 3. Trans-thoracic echocardiography showing a LVEF of 66% by biplane Simpson technic with no wall motion abnormalities**



**Fig. 4a. Coronary angiography images of normal left and right heart coronary arteries networks**



**Fig. 4b. Coronary angiography image (RAO Cranial) of coronary artery spasm (arrow) after injection of a vasoactive (acetylcholine) product during coronary angiography**

### 3. DISCUSSION

We described a rare case of a reversible coronary artery spasm confirmed by coronary angiography that resulted in a variant angina in a young healthy patient without a known history of cardiovascular disease or cardiovascular risk factor initially admitted in the Gastro-enterology department for programmed fissurectomy and hemorrhoidectomy after epidural administration of bupivacaine as regional anesthesia. Spontaneous reversibility of the coronary spasm and immediate resolution of clinical symptoms was achieved with oral administration of nitroglycerine. Our patient had only one episode of variant angina which occurred during the epidural infusion of the anesthetic agent, bupivacaine hydrochloride, which has a serum half-life elimination range of 1.5 – 5.5 h in adults. Nitrates and calcium-channel blockers are the well-established treatment modality in the management of variant angina [4] which was used in our patient resulting in the cessation of the angina.

“Bupivacaine has a relative central nervous system (CNS) and adverse cardiovascular effects. CNS side effects usually occurs before cardiovascular signs and symptoms. These includes tongue numbness, light headedness, visual disturbance and muscular twitching” [5]. “More fatal side effects include convulsion, coma and respiratory arrest” [5,6]. In our patient only cardiovascular effects such as variant angina was reported without the manifestation of CNS side effects of bupivacaine. It's also known that bupivacaine induces arrhythmia and myocardial depression due to the blocking of sodium channels in the cardiovascular system [6]. Bupivacaine significantly decreases the maximum diastolic potential and the action potential amplitude in myocardial tissue, and prolongs the ratio of effective refractory period to action potential duration [7].

“Dogs developed hypotension, respiratory arrest, ventricular tachycardia and ventricular fibrillation after bupivacaine administration” [8]. Coven and al. reported “two cases of accelerated idioventricular rhythm during spinal anesthesia of bupivacaine during cesarian section” [9] whereas Cotileas and al. reported a case of myocardial depression and pulmonary edema [10] as in our case but without pulmonary edema.

“Although the precise mechanism of coronary artery spasm is unknown, endothelial dysfunction, changes in autonomic tone

(excessive alpha-adrenergic activity or stimulation of the parasympathetic nervous system), imbalance of vasoconstrictor-vasodilator mediators, the use of illicit substances, primarily cocaine, and alkalosis has been implicated to trigger coronary spasm in susceptible patients” [11-13]. “A number of pharmacological agents that can induce coronary artery spasm has been identified including ergonovin and acetylcholine that have been used for provocative testing during coronary angiogram” [11-16]. In our case acetylcholine was used as a provocative testing substance for coronary spasm which came positive. The patient was put on treatment based on calcium channel blockers to prevent recurrent attacks in the future and reduce myocardial damage.

“Occurrence of coronary spasm has been reported as a sporadic complication of combined general and epidural anesthesia” [17-19] or epidural anesthesia alone as in our case [20,21]. “In some of the reported cases, the development of coronary spasm did not cause serious sequelae” [19]. In our case, NSTEMI caused by atheromatous plaque was the first diagnosis suspected which was rapidly ruled out with the aid of a coronary angiography and patient was put on proper medical treatment after confirmed diagnosis of coronary spasm.

### 4. CONCLUSION

Angina due to coronary artery spasm induced by epidural anesthesia is a rare. Owing to the risk of myocardial ischemia and/ or fatal arrhythmias/conduction disturbances, continuous monitoring of cardiac rhythm and prompt diagnosis of coronary spasm is crucial with early initiation of nitroglycerine infusion. Strong clinical suspicion, early use of echocardiography and angiography are recommended to detect perioperative coronary spasm. Coronary angiography with provocative testing is gold standard technic in the diagnosis of coronary artery spasm. The search for cardiovascular risk factors should be systematic in diagnosed patients for optimal treatment and follow-up in order to reduce morbi-mortality.

### DISCLAIMER

The products used for this research are commonly and predominantly use products in our area of research and country. There is absolutely no conflict of interest between the authors and producers of the products because we do not intend to use these products as an avenue for

any litigation but for the advancement of knowledge. Also, the research was not funded by the producing company rather it was funded by personal efforts of the authors.

## ETHICAL APPROVAL

As per international standard or university standard written ethical approval has been collected and preserved by the author(s).

## CONSENT

As per international standard or university standard, patients' written consent has been collected and preserved by the author(s).

## COMPETING INTERESTS

Authors have declared that no competing interests exist.

## REFERENCES

1. Waldemar Elikowski, Małgorzata Małek-Elikowska, Marek Słomczyński, Karolina Horbacka, Jarosław Bartkowski, Bartosz Kalawski. Transient left ventricular dysfunction due to coronary spasm after spinal anesthesia with bupivacaine. *Pol Med J.* 2017;256:177–180.
2. Ryu HY, Kim JY, Lim HK, Yoon J, Yoo BS, Choe KH, Lee SH. Bupivacaine induced cardiac toxicity mimicking an acute non-ST segment elevation myocardial infarction. *Yonsei Medical Journal.* 2007;48:331-6.
3. Michael Mutlak & Eugenia Nikolsky. Severe coronary artery spasm induced by epidural injection of bupivacaine hydrochloride: A case report *Acute Cardiac Care.* 2011;13(3):155–158.
4. Tern S, Bayes de Luna A. Coronary artery spasm: A 2009 update. *Circulation.* 2009;119:2531 – 4.
5. Ho Yoel Ryu, Jang Young Kim, Hyun Kyo Lim, Junghan Yoon, Byung-su Yoo, Kyung-Hoon Choe and Seung-Hwan Lee. Bupivacaine induced cardiac toxicity mimicking and acute non-ST segment elevation Myocardial Infarction. *Yonsei Medical Journal.* 2007;48:331-336.
6. Kasuya Y, Okumura Y, Tanabe K, Suzuki A. A case of cardiac arrest with coronary artery spasm during lumbar epidural anesthesia. Available: <https://pubmed.ncbi.nlm.nih.gov/11244779/>
7. Moller R, Covino BG, Cardiac electrophysiologic properties of bupivacaine and Lidocaine compared with those of ropivacaine, a new amide local anesthesia. *Anesthesiology.* 1990;73: 322-9.
8. Feldman HS, Arthur GR, Pikanen M, Hurley R, Doucette AM, Covino BG. Treatment of acute systemic toxicity after the rapid intravenous injection of ropivacaine ad bupivacaine in the conscious dog. *Anesth Analg.* 1991;73: 373-84.
9. Coven G, Arpesella R, Ciceri M, Preseglio I, Cardani A. Accelerated idioventricular rhythm during spinal anesthesia for cesarean section. *Int J Obstet Anesth.* 2003;12:121-5.
10. Cotileas P, Myrianthefs P, Haralambakis A, Cotsopoulos P, Stamatopoulon C, Ladakis C, et al. Bupivacaine-induced myocardial depression and pulmonary edema. A case report *J Electrocardiol.* 2000;33:291-6.
11. Giancarlo Pirozzolo, Valeria Martínez Pereyra, Astrid Hubert, Fabian Guenther, Udo Sechtem, Raffi Bekeredjian, Heiko Mahrholdt, Peter Ong, Andreas Seitz .Coronary artery spasm and impaired myocardial perfusion in patients with ANOCA: Predictors from a multimodality study using stress CMR and acetylcholine testing *Int J Cardiol.* 2021;343:5-11.
12. Ong P, Athanasiadis A, Hill S, Vogelsberg H, Voehringer M, Sechtem U. Coronary artery spasm as a frequent cause of acute coronary syndrome: The e CASPAR (coronary artery spasm in patients with acute coronary syndrome) study. *J Am Coll Cardiol.* 2008;52:523 – 7.
13. Pozzati A, Pancaldi LG, Di Pasquale G, Pinelli G, Bugiardini P. Transient sympathovagal imbalance triggers “ ischemic ” sudden death in patients undergoing electrocardiographic Holter monitoring. *J Am Coll Cardiol.* 1996;27:847 – 52.
14. Acikel S, Dogan M, Sari M, Kilic H, Akdemir R. Prinzmetal. Variant angina in a patient using zolmitriptan and citalopram. *AmJ Emerg Med.* 2010;28:257. 3 – 6.
15. Sueda S, Kohno H, Fukuda H, Ochi N, Kawada H, Hayashi Y, et al. Clinical impact of selective spasm provocation tests: Comparisons between acetylcholine and ergonovine in 1508 examinations. *Coron Artery Dis.* 2004;15:491 – 7.
16. Ye-Fei Li, Yu Zhang, Liang Chen, Kou-Long Zheng, Hui-He Lu, Zhen-Qiang Sheng. Diagnosis of coronary artery

- spasm by ergonovine provocation test of radial artery. *Sci Rep.* 2021;11 :3767.
17. Ichikawa J, Kurata J, Nishiyama K, Ozaki M. Case of coronary spasm during thoracic surgery under combined epidural-general anesthesia. *Masui.* 2007;56:425–8.
  18. Wang BS, Kim M, Kang SK, Hwang BM, Son HJ, Cheong IY. Severe hypotension caused by coronary spasm during recovery from combined spinal epidural anesthesia. *Korean J Anesthesiol.* 2008; 54:343 – 6.
  19. Ornek E, Ornek D, Murat SN, Turfan M. Angiographic documentation of coronary artery spasm induced by anesthesia. *J Anesth.* 2010 ;24 :452 – 5.
  20. Easley RB, Rosen RE, Lindeman KS. Coronary artery spasm during initiation of epidural anesthesia. *Anesthesiology.* 2003;99:1015– 7.
  21. Mallick PN, Upadhaya SP, Das AK, Singh RK. Takotsubo cardiomyopathy mimicking postoperative myocardial infarction in a young healthy patient. *Indian Journal of Anaesthesia.* 2013;57:193.