

Case study

Cardiac hydatid cyst in the right ventricle: uncommon localization of atypical chest pain

ABSTRACT

Hydatidosis is a parasitic infection, often disseminated, common in breeding countries with contact with dogs.

caused by cysts containing larvae of the tapeworm *echinococcus granulosus*

pulmonary localization is the most frequent followed by hepatic damage, cardiac extension is infrequent, involvement of the right ventricle is extremely rare. which may progress to fatal complications such as cardiogenic shock and **massive** pulmonary embolism

We report the observation of a young patient presenting for atypical chest pain with discovery of a solitary hydatid cyst in the right heart.

Key word: hydatid cyst ,chest pain ,right ventricle, parasitic infection

INTRODUCTION

Hydatidosis also known as Hydatid disease or **echinococcosis** a potentially serious, sometimes fatal, parasitic infection caused by cysts containing the larval stages of the *Echinococcus granulosus* (E. granulosus) tapeworm (Dog Tapeworm). It can occur worldwide and is especially common in cattle-rearing countries.

As for the disease's localization, pulmonary hydatidosis is the most frequent followed by hepatic, and cardiac localization is rare (0.5–2%).

Hydatidosis of the right ventricle alone is exceptional, and is six times rarer than the left ventricle, and can lead to fatal complications such as pulmonary embolism, systemic dissemination, and anaphylactic shock in case of cyst rupture.

Purpose: To report a rare case of cardiac hydatid disease of the right ventricle, highlighting the clinical particularities of this disease in addition to the importance of multimodality imaging for its assessment.

Case Presentation

We report the case of a 18-year-old woman living in the countryside, with no significant medical history, who presented to the emergency department with pseudo-anginal chest pain and **palpitations. Laboratory** tests found hypereosinophilia, cardiac biomarkers and routine tests were normal. Chest x-ray and abdominal ultrasound findings were unremarkable.

Electrocardiogram (ECG) showed repolarization **abnormalities in antero**-apical and inferior leads.

The transthoracic echocardiography performed showed good left ventricular function with an ejection fraction of 60% in Simpson biplane

The right ventricle was of normal size and function with a tissue Doppler S 'wave at the tricuspid valve annulus at 13cm / s , no significant valve disease was noted on color and continuous Doppler (Figure 1)

the right ventricle was the seat of a large hyperechoic mass, attached to the apical part of the interventricular septum, without obstruction visible on color Doppler, and without interventricular communication measuring 47 x39x36mm (Figure 1).

Cardiac computed tomography identified a thin-walled, oval, regular, fluid density mass implanted on the right side of the interventricular septum (IVS) and extending to the RV apex (Figure 2). Hydatid cyst was the most likely diagnosis considering the patient's rural environment and the fact she lived with dogs; followed by the less likely possibility of a congenital heart cyst, which was confirmed with positive hydatid serology.

Early and urgent surgery was decided, and cardiac cystectomy was performed. Postoperative specimens analysis confirmed the diagnosis by showing a hydatid cyst with live scolices of *Echinococcus granulosus*.

The postoperative period was uneventful and the patient was discharged home on albendazole with good clinical evolution.

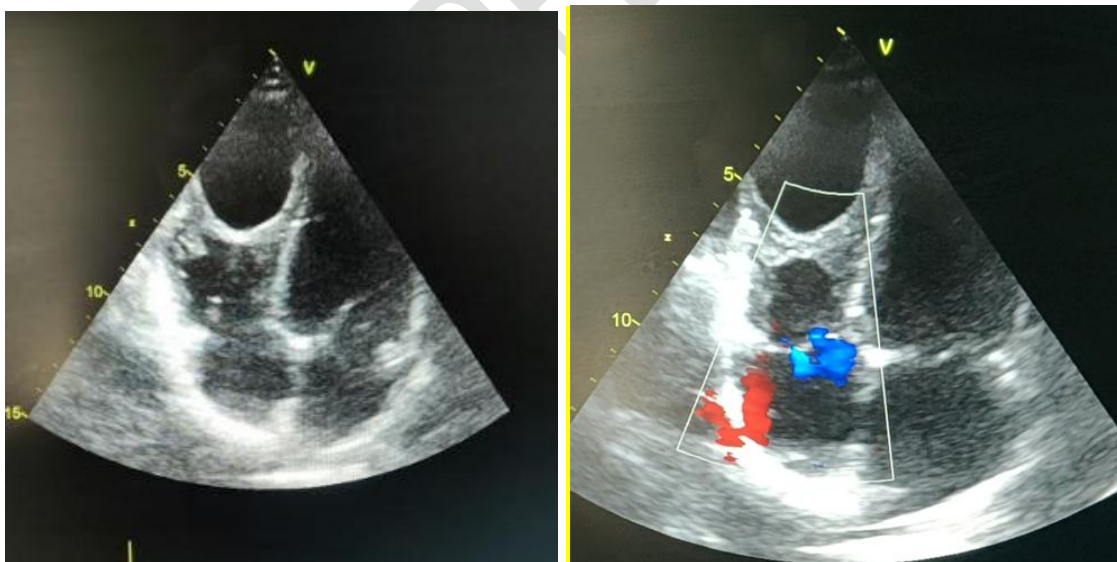


Figure 1: apical four chambers Transthoracic echocardiography showing hydatid cyst image in right ventricular apical region

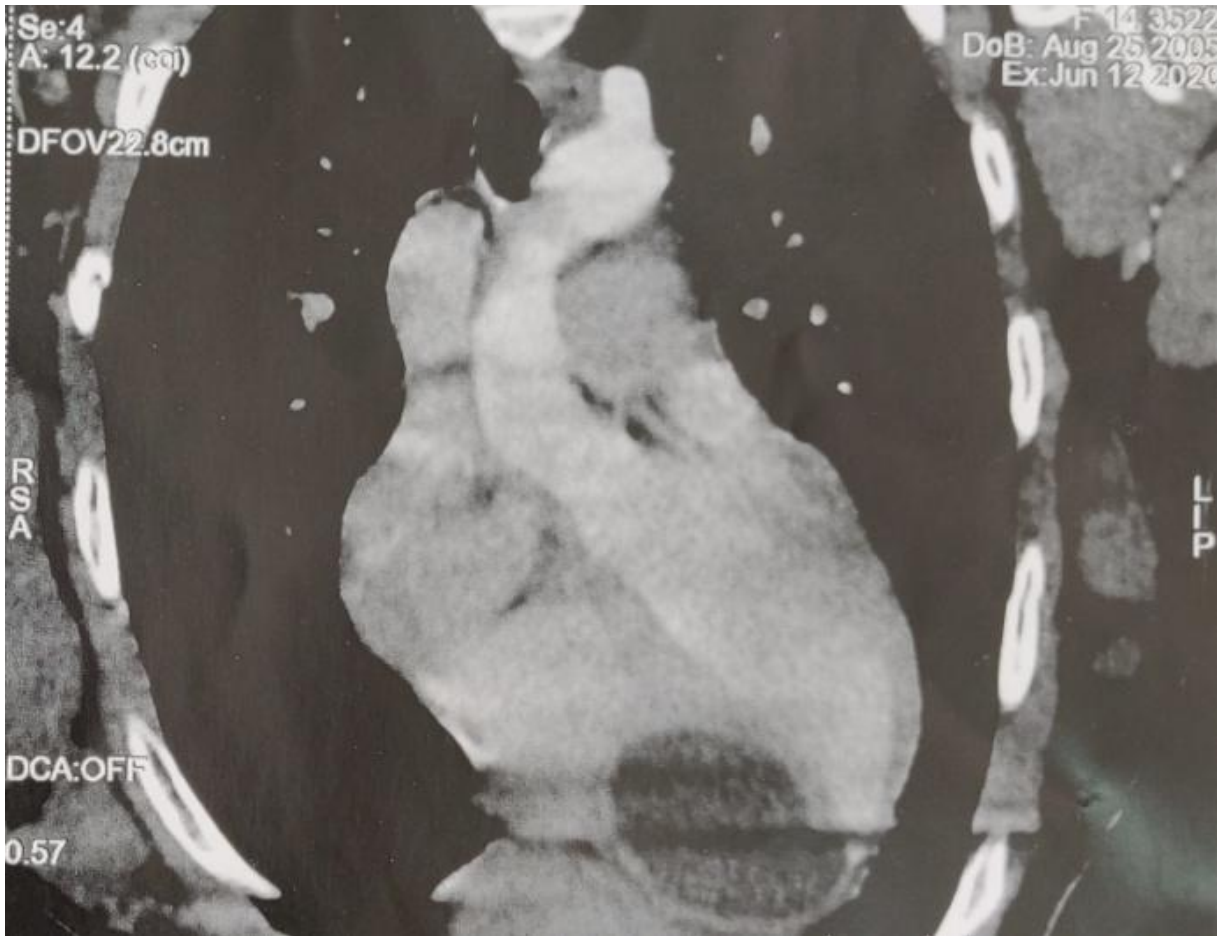

Figure 2: Cardiac computed tomography image of the hydatid cyst

DISCUSSION

Hydatid cyst is a widespread pathology in breeding countries, especially in Africa and Asia, however, epidemiological studies on human echinococcosis are still not available [1-2].

Cardiac involvement is mainly by systemic extension of the left heart, localization in the right ventricle is a very rare entity (6 times greater than the left ventricle), due to a rich left vascularization [3].

The rarity of this localization is due to the continuous cardiac contractile activity avoiding the attachment of the parasitic eggs at the level of the wall.

the cardiac localization is explained by the coronary penetration during a blood passage, while passing at the level of the myocardium, after several years of development, the cyst finally forms at the level of the heart, especially left ventricular by its size and its vascularisation [4].

The risk of natural progression is cavitory compression, due to high compliance at the level of the right ventricle, with risk of massive pulmonary embolism, anaphylactic shock if rupture, and low cardiac output due to a decrease in left ventricular filling [5].

The ECG and chest x-ray do not show specific signs.

Echocardiography is the first-line examination for detection, localization, monitoring in the context of cardiac hydatid cyst. In our patient, the use of another multimodal imaging allowed the study of extracardiac extension in order to guide the surgery [6].

The treatment is based on urgent surgical excision under cardiopulmonary bypass, the cyst must be completely resected and the contents aspirated with its membrane, coverage with albendazole is essential for up to 12 weeks postoperatively. [7].

The risk of recurrence is still present, requiring biological and radiological monitoring, with emphasis on good prevention [8].

CONCLUSION

Cardiac localization of hydatid disease is rare. The clinical polymorphism, the latency and the severity of the complications are the essential characteristics. Treatment is mainly surgical. There is a risk of recurrence, hence the importance of biological and radiological monitoring. Good prevention in endemic countries is the key to the global eradication of this parasitic infection

Ethical Approval:

As per international standard or university standard written ethical approval has been collected and preserved by the author(s).

Consent

As per international standard or university standard, respondents' written consent has been collected and preserved by the author(s).

REFERENCES

[1] Orah A Y, Faqe DA, Kadoura M, Kakamad FH, Yaldo FF, Aziz SQ. Cardiac Hydatid cysts; presentation and management. A case series. *Ann Med Surg (Lond)*. 2018; **7**(30): 18- 21

[2] Sadjjadi SM. Present situation of echinococcosis in the Middle East and Arabic North Africa. *Parasitol Int*. 2006; **55**(Suppl): S197- 202

[3] Noaman H, Rawaf S, Majeed A, Salmasi AM. Hydatid cyst of the heart. *Angiology*. 2017; **68**(9): 765- 768.

[4] Wadhawa V, Shah J, Doshi C, et al. Surgical overview of cardiac echinococcosis: a rare entity. *Interact Cardiovasc Thorac Surg*. 2018; **27**(2): 191- 197.

[5] Gençpınar T., Güzeloğlu M., Aykut K., Albayrak G., Hazan E. A rare localization of hydatid cyst: right ventricular free wall cyst fistulized to the ventricular cavity. *J Cardiovasc Surg*. 2013;1:13–15.

[6] Joughadi Z., Ailal F., Dreoua N., Eddine A.Z., Abid A., Skalli A. Kyste hydatique cardiaque. *Presse Med*. 2004;33:1260–1263.

[7] Oueslati S., Saïd W., Saaidi I., Djebbi M., Charrada L., Rezgui L. Imagerie du kyste hydatique du Cœur. *Presse Med*. 2006;35:1162–1166.

[8] Ohri S., Sachdeva A., Bhatia M., Shrivastava S. Cardiac hydatid cyst in left ventricular free wall. *Echo Res Pract*. 2015;2:K17–K19

[9] İpek G., Omeroglu S.N., Goksedef D., Balkanay O.O., Kanbur E., Engin E. Large cardiac hydatid cyst in the interventricular septum. *Tex Heart Inst J*. 2011;38:719–722.