

**UNICUSPID AORTIC VALVE: AN ADULT CASE REPORT**

**ABSTRACT:**

The unicuspid aortic valve is a very rare congenital disease that usually presents in the 3rd to 5th decade of life-and usually with severe aortic stenosis or regurgitation. Diagnosis can be made with 2- or 3-dimensional transthoracic or transesophageal echocardiography. It is mostly complicated by aortic dilatation and left ventricular hypertrophy. We present the case of a 35 years old, symptomatic patient with a unicuspid aortic valve, complicated by dilatation of the ascending aorta, with left ventricular hypertrophy.

**KEYWORDS:**

Aortic unicuspid valve, transesophageal echocardiography, aortic dilation,

## INTRODUCTION:

The unicuspid aortic valve (UAV) is a rare congenital aortic valve malformation in the general population (1). Mostly asymptomatic; its incidence is underestimated (2). Diagnosis can often be made with 2-dimensional (2D) transthoracic echocardiography (TTE) or transesophageal echocardiography (TEE) (3), and when done, it is often confused with the one of a bicuspid aortic valve. Definitive treatment is surgical replacement of the valve, performed when significant aortic stenosis or regurgitation develops. We present an illustrative case.

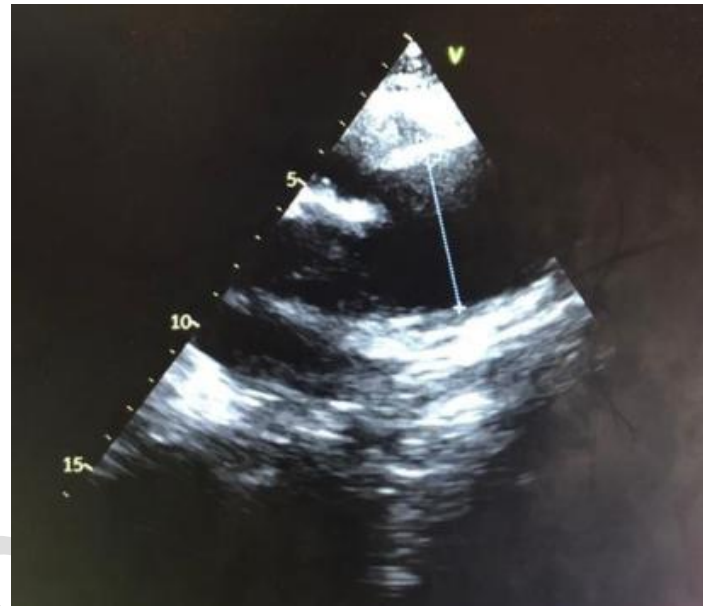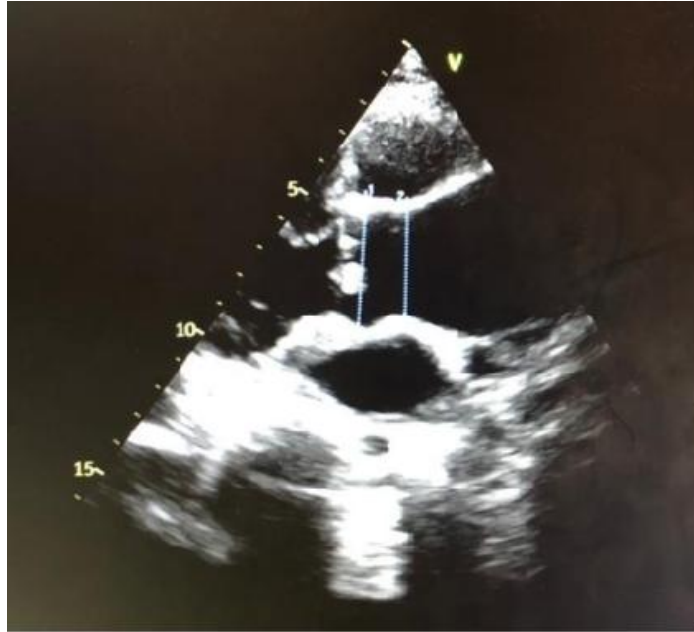## CASE REPORT:

A 35-year-old man presented with progressive dyspnea on exertion over the course of the last year. He reported a history of repeated sore throat and smoking. He reported no family history of cardiac disease or sudden cardiac death. At the time of his presentation, he was hemodynamically stable. Physical examination was significant for a grade 3/6 systolic ejection murmur heard over the right upper sternal border, without any sign of cardiac failure.

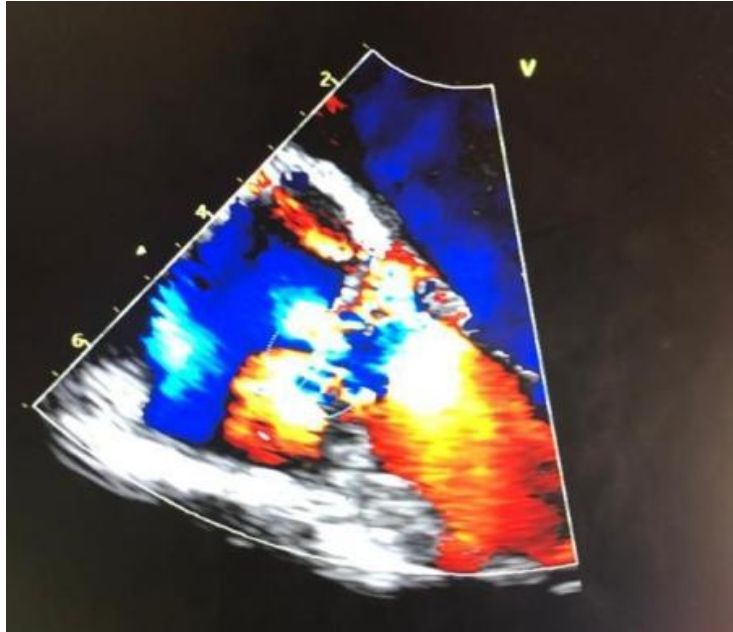
An electrocardiogram revealed sinus tachycardia with left ventricular hypertrophy, repolarization abnormalities.

A TTE showed a dilated left ventricle (60mm), hypertrophied (septum=14mm, LV wall=13mm) with a globally conserved contractility and an ejection fraction of 55%. The aorta was dilated (sinus=38mm, ascendant= 48mm), (Figure 1). Moderate aortic stenosis with a maximum velocity of 3.7 m/s, a mean gradient of 34 mmHg, and a calculated aortic valve area of 1.3 cm<sup>2</sup> with a severe aortic regurgitation (Rvol=114ml, EROA=50mm<sup>2</sup>, Pisa=11mm) were diagnosed. On 2D TTE, it was hard to verify whether the aortic valve appeared to be unicuspid or bicuspid. Transesophageal echocardiography confirmed a stenotic, severely regurgitant, unicuspid and unicommissural aortic valve. (Figure 2 and 3)

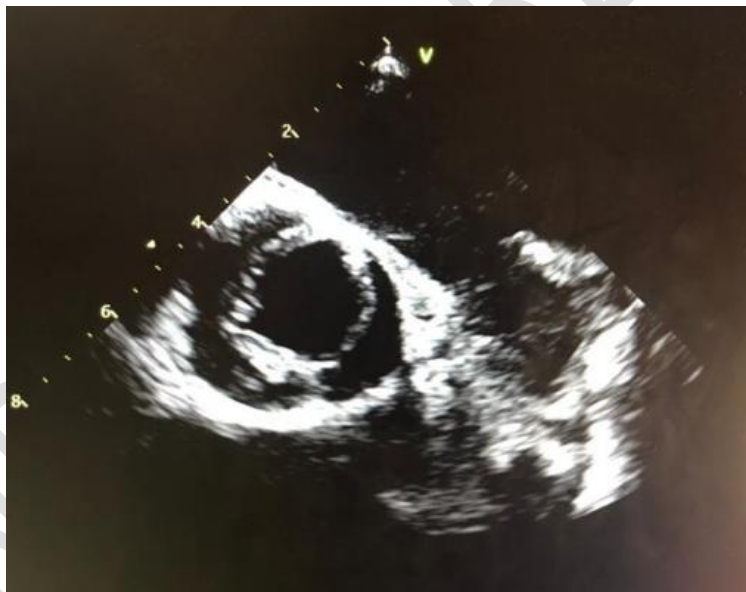The patient was scheduled for surgical discussion but he was lost to follow-up.



**Figure 1 : TTE showing aortic dilation (sinus=38mm, Ascendant=48mm)**



**Figure 2 : TEE showing severe aortic regurgitation**



**Figure 3 : TEE showing unicuspid and unicommissural aortic valve**

## DISCUSSION:

UAV is a rare form of aortic valve malformation with a prevalence of 0.02% in the adult population. (4) During embryogenesis, UAV develops due to failure of the 3 aortic cusps to separate before birth. (3) Based on the lateral attachment of the commissures to the aorta at the orifice, whether present or absent, we describe two forms : unicuspid acommisural and unicuspid unicommissural UAV (5), and in this second form, the orifice is larger, so the patients mostly remain asymptomatic until the 3rd to 5th decade of life, and that was the case with our patient.

The commonest concomitant cardiac pathologies found with UAV include severe aortic stenosis or mixed stenosis and regurgitation (6), aortic root and ascending aortic dilatation, aneurysm or dissection and aortic dissection which typically requires surgical intervention. (7) Left ventricular dilatation might be present at the time of diagnosis, as in our case. (8)

The diagnosis of UAV can be made with use of 2D or 3D TTE or TEE, (9) cardiac computed tomography, or cardiac magnetic resonance imaging (10), but it is best imaged by means of echocardiography which allows diagnostic accuracy of aortic valve morphology in most patients, and visualises the commissural attachment zone, the valvular orifice, the free edge of the leaflet, and the configuration of the aortic valve. Besides, echocardiography can even distinguish true from false unicuspid aortic valves and remains a reliable method for the pre-operative diagnosis, preferable to the radiological diagnostic tools mentioned above (which also help by virtue of their promising assessment of aortic valve morphology, including the exact morphology of the aortic valve and the severity of the aortic stenosis and regurgitation). (11)

From the therapeutic point of view, in the event of balanced aortic disease, surgery is indicated when symptoms exist or in case of left ventricle (LV) repercussions (LV dilation or alteration of the LVEF <50%). (12) In asymptomatic patients, Rosenhek's team identified a  $V_{max} \geq 5$  m / s as the most predictive factor for subsequent surgery (13), a reproducible parameter reflecting both the severity of stenosis and regurgitation.

Aortic valve repair, including bicuspidisation, can be performed with low risk and excellent operative results. (14)

## **CONCLUSION:**

Unicuspid unicommissural aortic valve is a rare congenital disorder that often leads to severe aortic stenosis, that should be suspected in infants presenting with aortic stenosis. TEE has relatively high sensitivity and specificity for the diagnosis. Patients usually present in the 3rd to 5th decade of life and often must undergo corrective valve replacement. Aortic dilatation should be well recognized and routinely assessed in the initial evaluation and follow up of these patients.

## **Consent:**

As per international standard or university standard, patient's consent has been collected and preserved by the authors.

## **BIBLIOGRAPHIE:**

- 1- B. Slostad, C. Witt, P. Leary. Unicuspid Aortic Valve Demographics, Comorbidities, Echocardiographic Features, and Long-Term Outcomes. *Circulation*. 2019;140:1853–1855
- 2- S. Yuan, J. Lavee, S. Yuan, and H. Jing. The unicuspid aortic valve. *Cardiovasc J Afr*. 2010 Apr; 21(2): 113–114.
- 3- S. Singh, P. Ghayal, A. Mathur, M. Mysliwicz, C. Lovoulos, P. Solanki, and J. Maher. Unicuspid Unicommissural Aortic Valve: An Extremely Rare Congenital Anomaly. *Tex Heart Inst J*. 2015 Jun; 42(3): 273–276.
- 4- Novaro GM, Mishra M, Griffin BP. Incidence and echocardiographic features of congenital unicuspid aortic valve in an adult population. *J Heart Valve Dis*. 2003 Nov; 12(6):674-8.
- 5- Anderson RH. Understanding the structure of the unicuspid and unicommissural aortic valve. *J Heart Valve Dis*. 2003 Nov; 12(6):670-3.
- 6- T. Connelly, W. Kolcow, Y. Smyth, and D. Veerasingham. Unicuspid aortic valve presenting with cardiac arrest in an adolescent. *BMJ Case Rep*. 2015; 2015: bcr2015211166.

- 7- Kang SD, Seol SH, Park BM, Kim DK, Kim KHJ. Incidental diagnosis of the unicuspid aortic valve with ascending aortic aneurysm in an asymptomatic adult. *Cardiovasc Ultrasound*. 2011 Jun; 19(2):102-4.
- 8- Murphy BA, Groban L, Kon ND. Diagnosis of a unicuspid aortic valve using transesophageal echocardiography. *J Cardiothorac Vasc Anesth*. 2003 Feb; 17(1):82-3.
- 9- Brantley HP, Nekkanti R, Anderson CA, Kypson AP. Three-dimensional echocardiographic features of unicuspid aortic valve stenosis correlate with surgical findings. *Echocardiography*. 2012 Sep; 29(8):E204-7.
- 10- Gibbs WN, Hamman BL, Roberts WC, Schussler JM. Diagnosis of congenital unicuspid aortic valve by 64-slice cardiac computed tomography. *Proc (Bayl Univ Med Cent)*. 2008 Apr; 21(2):139.
- 11- Debl K, Djavidani B, Buchner S, Poschenrieder F, Heinicke N, Schmid C. Unicuspid aortic valve disease: a magnetic resonance imaging study. *Rofo*. 2008 Nov; 180(11):983-7.
- 12- Vahanian A, Alfieri O, Andreotti F et al. Guidelines on the management of valvular heart disease (version 2012): The Joint Task Force on the Management of Valvular Heart Disease of the European Society of Cardiology (ESC) and the European Association for Cardio-Thoracic Surgery (EACTS). *Eur Heart J* 2012;33:2451-96.
- 13- Zilberszac R, Gabriel H, Schemper M et al. Outcome of combined stenotic and regurgitant aortic valve disease. *J Am Coll Cardiol* 2013;61(14):1489-95.
- 14- Schäfers HJ, Aicher D, Riodionycheva S, Lindinger A, Rädle-Hurst T, Langer F. Bicuspidization of the unicuspid aortic valve: a new reconstructive approach. *Ann Thorac Surg*. 2008 Jun; 85(6):2012-8.