

## *Case Report*

# **Rescue Venous-Arterial Extracorporeal Membrane Oxygenation and Impella Support of Left Ventricle as a Bridge to Surgery in a patient with Retrosternal Goiter**

### **Abstract:**

Surgical management of anterior mediastinal masses (AMM) compressing major airways and vascular structures is challenging. Careful planning for surgical resection and expecting potential complications can be life saving for the patient. Venous-arterial extracorporeal membrane oxygenation (VA ECMO) has been used as a bridging strategy to removal of a large compressing mass. We are reporting our experience with a case that required Impella placement in addition to VA ECMO due to severe ventricular dysfunction.

Keywords: ECMO, Retrosternal goiter, Split-sternum thyroidectomy

### **Introduction**

Extracorporeal membrane oxygenation has been described in reports as a successful means of bridging patients with AMMs causing

extrinsic airway compression during induction chemotherapy or surgical treatment [1-3]. Extracorporeal membrane oxygenation (ECMO) therapy has changed the way physicians view supportive treatment for cardiac, respiratory, or combined cardiopulmonary failure. An oxygenator is a gas exchange device that uses a semipermeable membrane in order to separate a blood compartment from a gas compartment [3,4]. The ECMO therapy process consists of deoxygenated blood withdrawn through a drainage cannula by an external pump, which then passes through the oxygenator, and is finally returned to the patient through a reinfusion cannula [6]. In this case we are presenting the importance of utilizing VA ECMO and Impella support system as a rescue and bridging strategies in the case of large AMM.

### **Case Presentation:**

43 years old female presented to Ear-Nose-Throat (ENT) outpatient clinic with an incidental retrosternal mass detected by routine chest x-ray (CXR) and confirmed by computed-tomography (CT) neck and chest detected during a preoperative evaluation for an elective surgery. Patient was completely asymptomatic and denied any complains. This includes no dyspnea, chest pain or discomfort, dysphasia, dysphagia, symptoms of hypothyroidism or hyperthyroidism.

Past medical history was not significant with any comorbidities. Past surgical history includes previous liposuction and abdominoplasty 4 years ago. Patient denies smoking, alcohol use, or known allergy.

Vital signs were within the normal range limits. Complete physical examination was conducted. Examination, including head and neck, was unremarkable other than previous surgical scars.

**Management:**

Laboratory investigations, including complete blood count (CBC), basal metabolic panel (BMP), coagulation profile, and thyroid function tests (TFT), were within normal limits.

Pulmonary function test was done, and no abnormality detected. Transthoracic echocardiography (TTE) showed ejection fraction (EF) 60% with no

valvular abnormalities. CT neck and chest with intravenous contrast showed a large multinodular goiter measuring 11x67x97 mm with mass effect in the form of tracheal shift to the left side and a compression on superior vena cava (SVC) Figure 1.

Thoracic surgery team were consulted regarding the patient for surgical plan. The patient was admitted to chest diseases hospital, Kuwait. Preoperative assessment and evaluation by the thoracic and anesthesia team was performed. Multidisciplinary discussion between the thoracic surgery, ENT, anesthesia, and the patient. Surgical plan and possible complications were discussed. Patient was scheduled to undergo total thyroidectomy with sternotomy.

### **Hospital Course:**

During the induction of anesthesia patient developed hypotension and not responding to medications. Patient was immediately intubated. Patient was placed on venoarterial extracorporeal membrane oxygenation (VA ECMO). Trans-esophageal echocardiography (TEE) done by cardiologist which showed severe left ventricle dilation with EF 20% and global hypokinesia. Initial impression by cardiology team included critical left coronary artery occlusion. Cardiac angiography was done which showed patent coronary vessels and incidental patent

foramen ovale (PFO). Impella ventricular support system was fixed for the patient and then shifted to the intensive care unit (ICU).

The patient was managed by a multidisciplinary team and the hemodynamics improved markedly. Repeated TTE showed normalization of left ventricle EF with disappearance of cardiac dyskinesia. Patient weaned from VAT ECMO and removed uneventfully third day post-placement. Following day, PFO closure done under TEE guidance followed by Impella removal.

On the seventh day of admission, the patient underwent total thyroidectomy through transthoracic neck incision by ENT team followed by mini sternotomy and excision of retrosternal goiter by thoracic team Figure 2. Immediate improvement of respiratory and cardiovascular parameters was noted after the removal of the retrosternal goiter. The patient was extubated the following day in the ICU and continued to be managed by a multidisciplinary team including cardiology, cardiac surgery, thoracic surgery, ENT, ICU, endocrinology, and hematology.

Patient was discharged to the ward on the 3<sup>rd</sup> day post-operative. In the ward, her course was uneventful and was discharged home on the 9<sup>th</sup> day. Follow-up appointments showed improved recovered without any residual impairment.

## **Discussion**

Vascular compression and airway obstruction are a life-threatening pathology. Acute fatal decompensation of cardiopulmonary circulation may occur during sedation or induction of anesthesia through direct compression of large mediastinal mass<sup>7,8</sup>. We are presenting a case of retrosternal goiter which initially was fixed on VA ECMO for hemodynamic. To our knowledge this is the first anterior mediastinal mass case report to use Impella ventricular support system in addition to VA ECMO to provide hemodynamic support after failure of initial improvement on VA ECMO.

Careful planning for ECMO support is a major factor in preventing cardiopulmonary collapse and patient loss. The timing of cannulation can be a point of contention by the treating medical provider<sup>4</sup>. In a case series reported by Leow et al, 2 out of 3 cases were lost<sup>9</sup>. Mortality was attributed to delay in diagnosis, late ECMO placement and lack of preparedness. Therefore, elective ECMO based on clinical and radiological findings may help in avoiding catastrophic consequences and necessity to cannulation in peri-arrest setting<sup>8</sup>.

The choice of ECMO mode is determined case by case. The literature reports the use of venovenous (VV) or VA ECMO depending on the degree of compression on airway or major vessels<sup>11,12</sup>. The necessity of choosing VA ECMO support in our case was due to tumor compression to SVC which led to decrease

cardiac contractility and output. Studies recommend the establishment of ECMO support in high-risk patients before anesthesia induction<sup>14,15</sup>.

Our case underlines the importance of communication and rapid response to hemodynamic changes. Despite the placement on VA ECMO support, the patient hemodynamics remained unstable. Intraoperative TEE supported the indication for further intervention. Following the placement of Impella improvement of patient's hemodynamics was noted.

## **Conclusion**

ECMO support is gaining importance as a rescuing or bridging technique to mass resection. Our case report presents the possibility of utilization of Impella in addition to VA ECMO support in cases of failure to respond to initial supportive measures during cardiopulmonary collapse.

## **Ethical approval**

Ethical approval was received from the Ethics Board of the Chest diseases hospital and ministry of health in Kuwait.

## Consent

Written informed consent was obtained from the patients' parents for publication of this case report and any accompanying images.

## References

- 1- Lueck C, Kuehn C, Hoepfer MM, Ganser A, Eder M, Beutel G. Successful use of extracorporeal membrane oxygenation during induction chemotherapy in a patient with mediastinal tumor mass of a T lymphoblastic lymphoma. *Ann Hematol.* 2016;95:1719–1721.
- 2- Worku B, DeBois W, Sobol I, Gulkarov I, Horn EM, Salemi A. Extracorporeal membrane oxygenation as a bridge through chemotherapy in B-cell lymphoma. *J Extra Corpor Technol.* 2015;47:52
- 3- Nokes BT, Vaszar L, Jahanyar J, Swanson KL. VV-ECMO–assisted high-risk endobronchial stenting as rescue for asphyxiating mediastinal mass. *J BroncholIntervPulmonol.* 2018;25:144–7.
- 4- Squiers JJ, Lima B, DiMaio JM: Contemporary extracorporeal membrane oxygenation therapy in adults: fundamental principles and systematic review of the evidence. *J Thorac Cardiovasc Surg.* 2016, 152:20-32.

- 5- Sauer CM, Yuh DD, Bonde P: Extracorporeal membrane oxygenation use has increased by 433% in adults in the United States from 2006 to 2011. *ASAIO J.* 2015, 61:31-36.
- 6- Abrams D, Combes A, Brodie D: Extracorporeal membrane oxygenation in cardiopulmonary disease in adults. *J Am Coll Cardiol.* 2014, 63:2769-2778.
- 7- Chao VT, Lim DW, Tao M, Thirugnanam A, Koong HN, Lim CH. Tracheobronchial obstruction as a result of mediastinal mass. *Asian Cardiovasc Thorac Ann.* 2006;14:e17–8.
- 8- Ramanathan K, Leow L, Mithiran H. ECMO and adult mediastinal masses. *Indian J Thorac Cardiovasc Surg.* 2021;37:338-343.
- 9- Leow L, Sampath HK, Yong KJ, Kofidis T, Tam JKC, MacLaren G. Rescue extracorporeal membrane oxygenation for massive anterior mediastinal masses. *J Artif Organs.* 2021;24(4):450-457.
- 10- Wilson SM, Lojek ASB, Zamora-Berridi GJ, Hodgson JA. Not your average mediastinal mass: a care of a large mediastinal teratoma in a patient with a history of polio disease. *Military Medicine.* 2021;usab343.
- 11- Worku B, DeBois W, Sobol I, Gulkarov I, Horn EM, Salemi A. Extracorporeal membrane oxygenation as a bridge through chemotherapy in B-cell lymphoma. *J Extra Corpor Technol.* 2015;47:52–4.

- 12- Shao Y, Shen M, Ding Z, Liang Y, Zhang S. Extracorporeal membrane oxygenation-assisted resection of goiter causing severe extrinsic airway compression. *Ann Thorac Surg.* 2009;88:659–61.
- 13- Nokes BT, Vaszar L, Jahanyar J, Swanson KL. VV-ECMO-assisted high-risk endobronchial stenting as rescue for asphyxiating mediastinal mass. *J Bronchology Interv Pulmonol.* 2018;25:144–7.
- 14- Erdos G, Tzanova I. Perioperative anaesthetic management of mediastinal mass in adults. *Eur J Anaesthesiol* 2009;26:627–32.
- 15- Jeong YI, Jun IG, Ha SS, Kwon HJ, Lee YM. Extracorporeal membrane oxygenation for the anesthetic management of a patient with a massive intrathoracic goiter causing severe tracheal obstruction with positional symptoms. *Medicine.* 2019 Oct;98(42):e17650.

UNDER

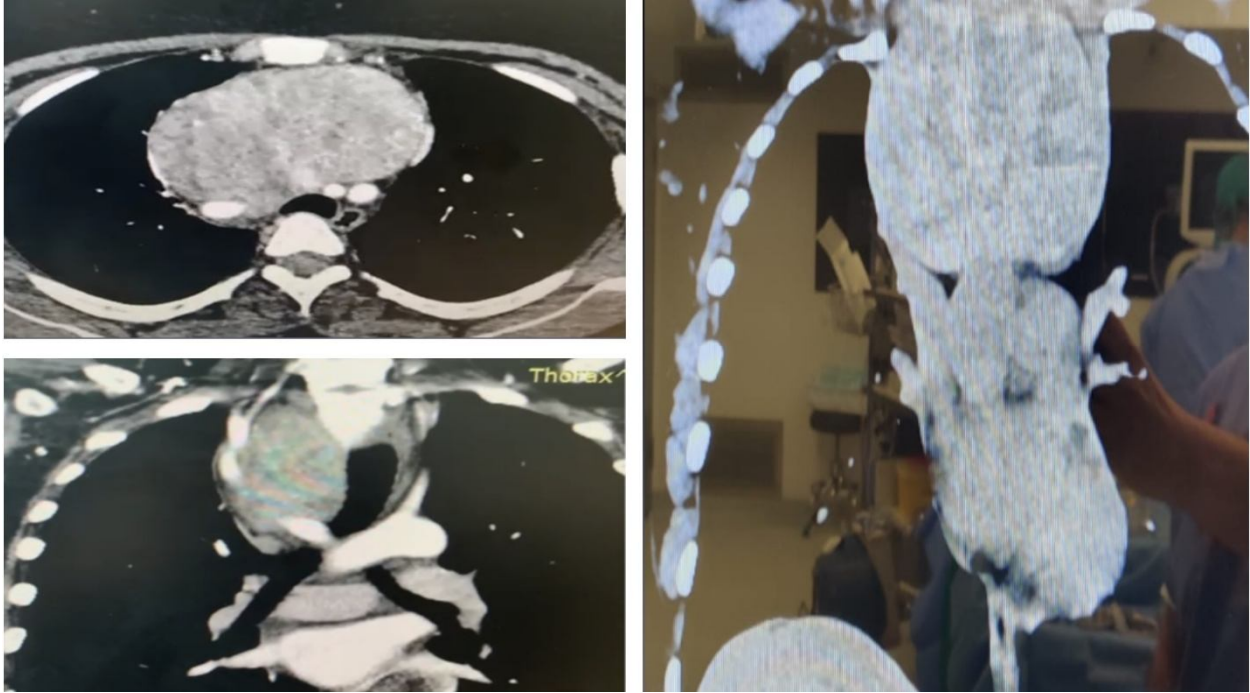


Figure 1:CT scan showing large multinodular goiter with mass effect in a form of left tracheal shift and SVC compression

UNDER P...

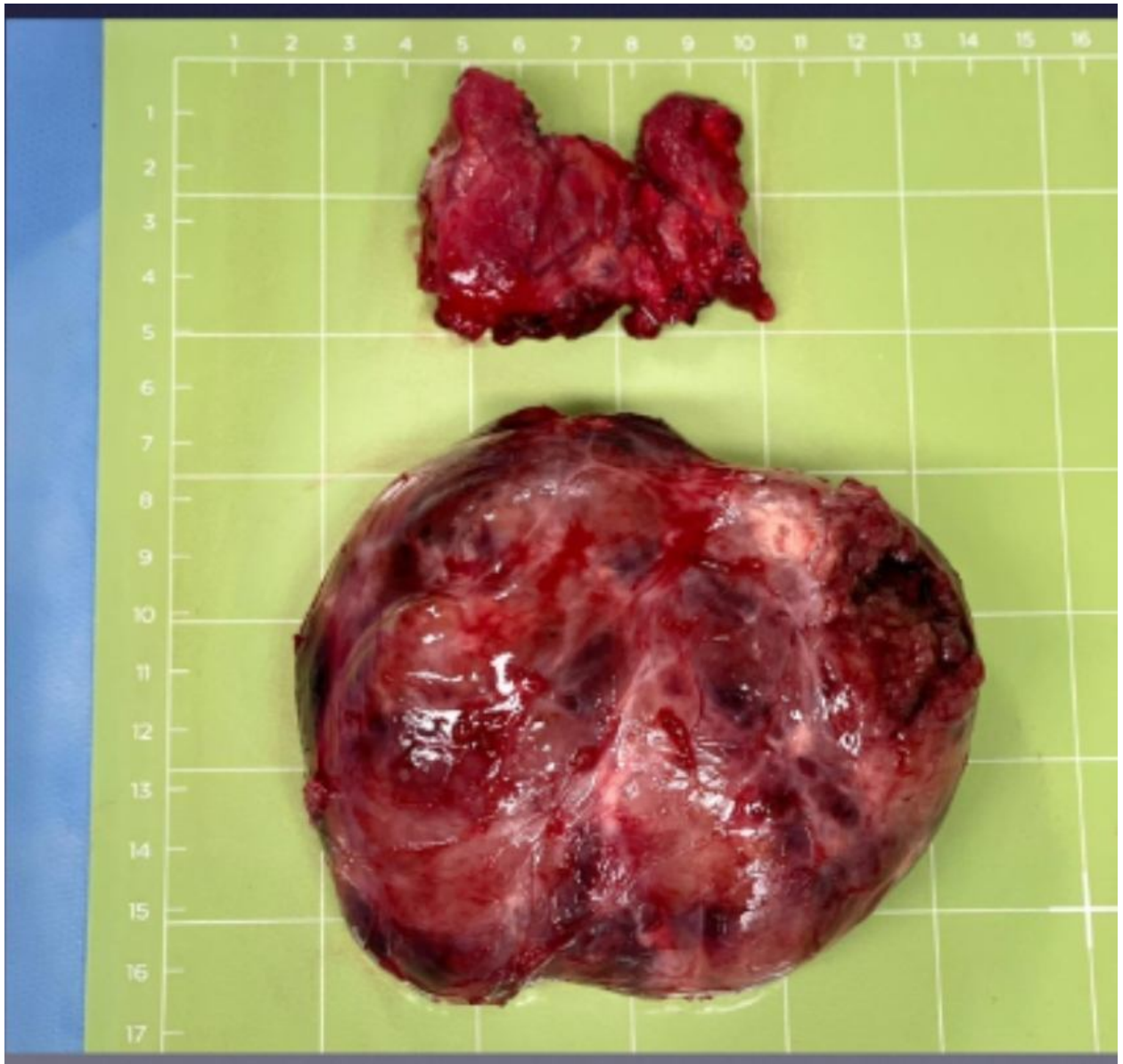


Figure 2: Retrosternal goiter

