

### **Foreign body extraction in presence of severe airway edema in pediatric cases**

#### **Abstract**

Foreign body aspiration is a common emergency in pediatric requiring immediate intervention. Foreign bodies aspiration is an emergency that requires immediate intervention. We are describing management of foreign body aspiration with severe edema and inflammation. Patients underwent emergent bronchoscopy to confirm diagnoses. Initial bronchoscopy failed to extract the foreign body, so it was repositioned in lower part of the airway tree and was started on antibiotics, steroid, and nebulization. Second trail of bronchoscopy 48 hours later successfully removed the foreign body. The case report concludes that edematous and inflamed airway can be managed medically before safe removal of the foreign body. Repositioning the foreign body down allow more ventilation to non-obstructed part of the lung.

Keywords: Airway edema, Bronchoscopy, Foreign body, Thoracic, Respiratory

## Introduction

Foreign body aspiration is a life threatening condition associated with high morbidity and mortality in pediatric group<sup>1,2</sup>. This is found due to narrow airway in pediatric age and immature protective mechanism<sup>3,4</sup>. Symptoms may include coughing, choking and wheezing followed by asymptomatic period<sup>5</sup>. Here we describe the utilization of antibiotics and steroids in addition to repositioning the foreign body in managing edematous and inflamed upper airway.

## Case Presentation

### Case 1

A 6-years old girl with 7 month history of repeated admissions to hospital for chest infections, presented to casualty with 1 day history of dyspnea. Physical examination showed tachypnea, decrease in oxygen saturation and inspiratory stridor. Chest x-ray done and no abnormality was detected (figure 1). Four days prior to presentation the patient was seen by ENT specialist who diagnosed her as a case of laryngitis. Detailed history was obtained and found positive for history of choking chicken bone 7 months ago. Foreign body aspiration was suspected. Arterial blood gas showed respiratory alkalosis  $P_H$  7.5 and  $PaCO_2$  4.7 kPa. Chest x-ray was unremarkable. The patient underwent flexible and rigid bronchoscopy size 3.7 to 5.5 mm under general anesthesia for foreign body removal. The foreign body (bone) was found in the right main bronchus. Severe airway edema and inflammation was present, preventing safe extraction of the bone (Figure 2). The bone was repositioned to the right lower bronchus. The patient intubated and shifted to pediatric intensive care unit (PICU). She was started on Intravenous dexamethasone, ceftriaxone, and nebulization.

Two days following the initial bronchoscopy, the patient underwent rigid bronchoscopy size 5 mm with fiberoptic guidance, which showed subsidence of edema. The bone was successfully and safely removed without any difficulty (Figure 3). The patient was shifted back to PICU for observation. Patient was extubated same day and shifted to the ward to continue medical treatment. Two days later she was discharged home.

### Case 2

A 2-year old previously healthy presented to the hospital with acute onset of dyspnea following aspiration pistachio shell. On examination the patient was in respiratory distress. Auscultation of the chest showed decrease air entry bilaterally with inspiratory stridor. Chest x-ray showed fully expanded lung without any abnormality. Laboratory investigations including CBC, serum electrolytes and blood gas analysis were within normal limits and chest x-ray didn't show any abnormality. Flexible followed by rigid bronchoscopy were done under general anesthesia for foreign body extractions. Foreign body was found in the subglottic

region of the trachea. Trial of foreign body extraction attempted but failed due to severe edema and size of the foreign body proportional to the vocal cord. The foreign body repositioned to the right main bronchus. The patient was intubated and shifted to the PICU. She was started on antibiotics and steroids. Computed tomography (CT) scan was done which showed foreign body in the right main bronchus and right lower lobe collapse. Second bronchoscopy was done three days following the initiation of steroids and ceftriaxone. The foreign body was safely removed without any difficulty. In addition, edema and inflammation of the airway were improved. Patient was shifted back to the PICU. She was extubated in the same day and shifted to the pediatric ward. Antibiotics and steroids were continued in the ward and the patient was discharged after 2 days.

## **Discussion:**

Diagnosing foreign body aspiration require high index off suspicion. A systemic review showed only 60% recall history of aspiration in adult population<sup>6</sup>. One study showed 20% of pediatric patients may present more than 7 days post aspiration<sup>7</sup>. Some adult patients may not develop clinical symptoms for years, especially if foreign body lodged in lobar or segmental bronchi<sup>8</sup>. This is relatively rare in pediatric group due to smaller airway diameter, making them at higher risk for airflow obstruction<sup>9</sup>. Relying on chest x-ray is equivocal since 28% of x-rays may not show any abnormalities and 16% may reveal radio opaque objects<sup>10</sup>. Undiagnosed foreign body aspiration is associated with various complications such as pneumonia, bronchiectasis, and atelectasis<sup>1,7</sup>. In the first case, following foreign body aspiration the patient had repeated admissions for upper and lower respiratory tract infections which led to airway edema and upper airway obstruction. Debeljak et al found organic foreign bodies induce edema and inflammation<sup>11</sup>.

Long lasting retained foreign bodies have been linked with parenchymal destruction<sup>12</sup>. In our cases, no sequelae was noted prior and during the follow up. As a general rule, care must always be taken to avoid pushing foreign body distally<sup>13</sup>. In our cases, foreign body was pushed to lower bronchus due to failure of extraction to allow maximum ventilation possible of the lung until edema resolve. De Kruif HF et al reported in adult cases possibility of postponing the extraction of foreign body complicated with granulation tissue and to start intravenous corticosteroids<sup>15</sup>. Some studies showed patients who were started on corticosteroids, antibiotics, bronchodilators, and physiotherapy following bronchoscopy and foreign body removal had less complications reported<sup>15,16</sup>. This case report, we report the effectiveness of utilizing steroids, antibiotics, and nebulizers prior to foreign body extraction from the airway in the presence of airway edema.

## **Conclusions:**

Thorough history taking is required for diagnosis of foreign body aspiration. Normal initial investigations don't exclude necessity for bronchoscopy. Antibiotics, steroids and nebulization should be utilized prior to foreign body removal in edematous airway.

## Ethical approval

Ethical approval was received from the Ethics Board of the Chest diseases hospital and ministry of health in Kuwait.

## Consent

Written informed consent was obtained from the patients' parents for publication of this case report and any accompanying images.

## References

- 1- Joshua D. Rovin and Bradley M. Rodgers. Pediatric Foreign Body Aspiration. *Pediatrics in Review* 2000; 21;86.
- 2- Haddadi S, Marzban S, Nemati S, Kiakelayeh SR, Prvizi A, Heidarzadah A. Tracheobronchial Foreign-Bodies in Children; A 7 Year Retrospective Study. *Iran J Otorhinolaryngol* 2015; 27 (82):377-85.
- 3- Jose A, Cataneo M, Cataneo DC, Ruiz Jr RL. Management of tracheobronchial foreign body in children. *Pediatr Surg Int* 2008; 24(2):151–6.
- 4- Zhong B, Sun S, Du JT, Deng D, Liu F, Liu YF. et al. Risk factors for lower respiratory tract infection in children with tracheobronchial foreign body aspiration. *Medicine* (2019) 98:10.
- 5- Lea E, Nawaf H, Yoav T, Samet E, Zonis Ze'ev, Kugelman A. Diagnostic evaluation of foreign body aspiration in children: a prospective study. *J Pediatr Surg* 2005; 40: 1122–7.
- 6- Sehgal IS, Dhooria S, Ram B, Singh N, Aggarwal AN, Gupta D, et al. Foreign body inhalation in the adult population: experience of 25,998 bronchoscopies and systematic review of the literature. *Respiratory Care* 2015; 60(10): 1438–48.
- 7- Oncel M, Sunam GS, Ceran S. Tracheobronchial aspiration of foreign bodies and rigid bronchoscopy in children. *Pediatrics International* 2012;54:532–5.
- 8- Ramos MB, Fern´andez-Villar A, Rivo JE, Leiro V, Garcia-Fontan E, et al, "Extraction of airway foreign bodies in adults: experience from 1987– 2008," *Interactive CardioVascular and Thoracic Surgery* 2009;9(3): 402–5.
- 9- Cramer N, Jabbour N, Tavarez MM, Tavarez MM, Taylor RS. Foreign body aspiration. *StatPearls Publishing*: 2019 Jan-.

- 10- Salih AM, Alfaki M, Alam-Elhuda DM. Airway foreign bodies: A critical review for a common pediatric emergency. *World J Emerg Med* 2016. 7 (1):5-12.
- 11- Debeljak A, Sorli J, Music E, Kecelj P. Bronchoscopic removal of foreign bodies in adults: experience with 62 patients from 1974-1998. *Eur Respir J.* 1999;14(4): 792-5.
- 12- Al-Majed SA, Ashour M, Al-Mobeireek AF, Al-Hajjaj MS, Alzeer AH, Al-Kattan K. Overlooked inhaled foreign bodies: late sequelae and the likelihood of recovery. *Respir Med* 1997; 91(5): 293-296
- 13- Hewlett JC, Rickman OB, Lentz RJ. Foreign body aspiration in adult airways: therapeutic approach *J Thorac Dis* 2017 Sep 9(9):3398-3409
- 14- De Kruif HF, Innemee A, Giezeman D, Spoelstra-de-Man A.M.E.. Collapse due to acute aspiration of the foreign body. *NETH J CRIT CARE* 2013; 17:23-6.
- 15- Baharloo F, Veyckmans F, Francis C, Bieltlot M, Rodenstein D. Tracheobronchial foreign bodies. *Chest* 1999; 115:1357-62.
- 16- Luddemann JP, Hollinger LD. Management of foreign bodies of the airway. In: Shields TW, Lo Cicero J, Ponn RB 5<sup>th</sup> ed. *General Thoracic Surgery*. WB Saunders, Philadelphia, PA, 2000; 853–62.

UNDER PEER REVIEW

**Figure Legends**

Fig. 1. Chest X-Ray without abnormal findings

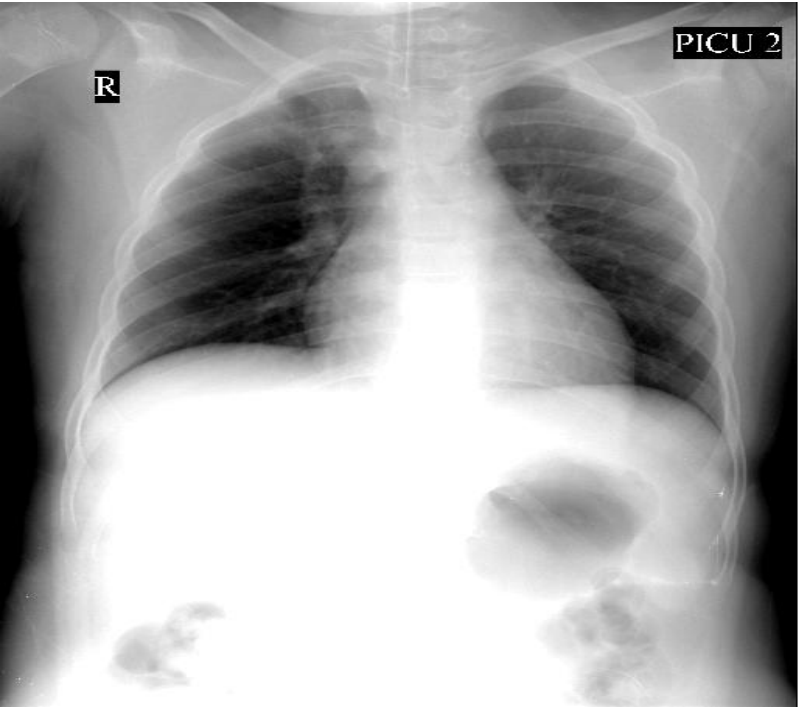
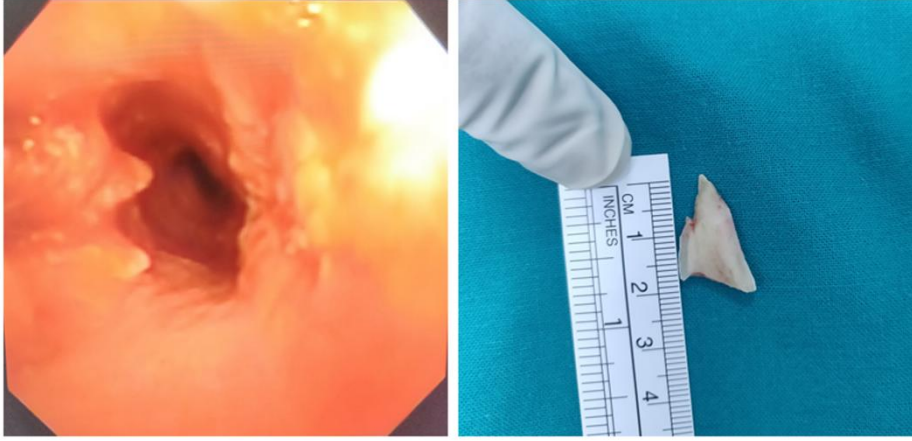


Fig. 2. Bronchoscopic view of foreign body obstructing right main bronchus

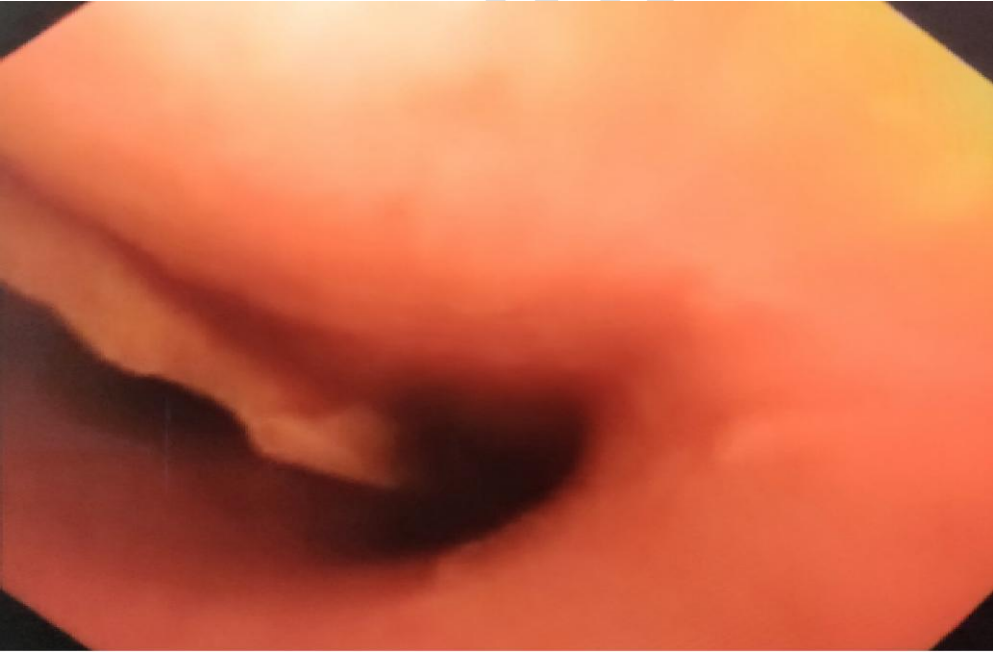

Fig. 3. Right bronchus following removal of foreign body. Chicken bone was removed



1

UNDER PEER REVIEW