

Strangulated femoral hernia in a man. (A case report)

Abstract :

In men, the femoral hernia may clinically resemble an inguinal hernia. Especially when the hernia is turned upwards and covers the medial end of the inguinal canal. The confusion is then more pronounced. It is rare in men. The diagnosis is clinical and should be treated urgently when it is a strangulation.

This is a 50-year-old patient who is admitted with a strangulated femoral hernia. On clinical examination, there was an irreducible, painful, non-impulsive left inguinal swelling. The patient underwent a segmental bowel resection with terminal bowel anastomosis and a Mac Vay left femoral hernia repair. The postoperative follow-up was favourable with a 1-year follow-up.

we would like to share a very difficult clinical case and our experience with the support of the literature. This is a challenge to clinicians and surgeons above all.

Keywords : Hernia ; Femoral hernia ; Strangulation ; Treatment.

Introduction :

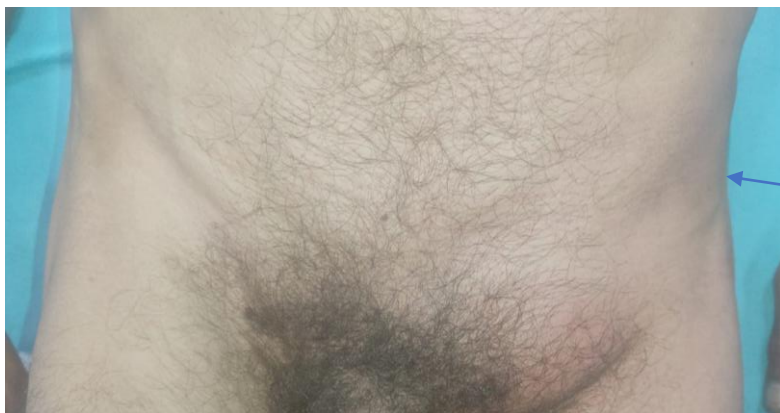
Femoral hernias are relatively uncommon, making up 2-8% of all adult groin hernias and less than 5% of all abdominal wall hernias. About 60% of femoral hernias are on the right, 30% on the left and 10% bilaterally (1). They are mostly observed among adults (40–70 years), much more common in women than in men, and are frequently associated with incarceration and strangulation (2). As the femoral opening is a rigid opening, this hernia is prone to incarceration and strangulation. So, early diagnosis and treatment is very essential (3).

We report on a case who presented with a strangulated femoral hernia. The patient underwent a segmental bowel resection with terminal bowel anastomosis and a Mac Vay left femoral hernia repair. The postoperative follow-up was favourable with a 1-year follow-up.

Case report :

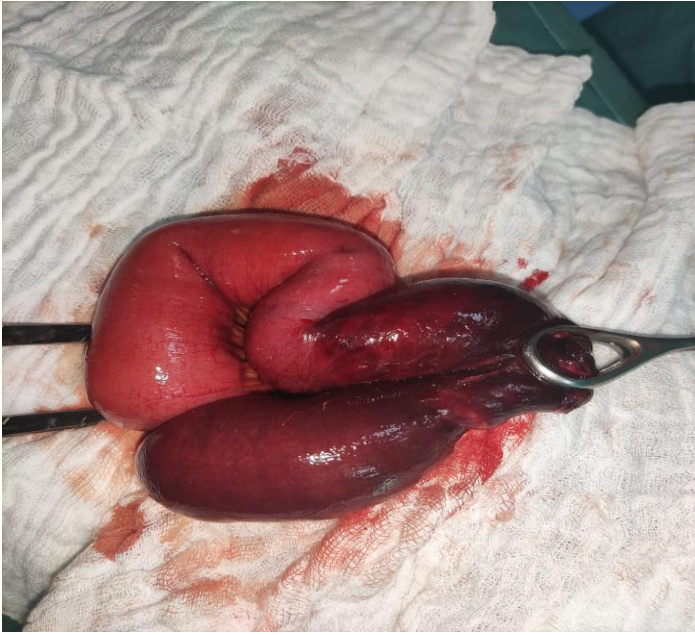The patient was 50 years old, a chronic smoker, cannabis user and alcoholic. Admitted for a painful and non reducible left inguinal swelling which was complicated by an occlusive

syndrome with vomiting. The patient is haemodynamically and respiratorily stable with zero status of performance. On clinical examination, there was an irreducible, painful, non-impulsive left inguinal swelling (**Pic. 1**) on coughing and rectal touch, the rectal ampulla was empty. The patient underwent a segmental bowel resection with terminal bowel anastomosis and a Mac Vay left femoral hernia repair. On exploration, a necrotic loop of the gallbladder was found (**Pic. 2**) after opening the hernia sac. The patient resumed transit at D3 post-op and was declared discharged at D4 post-op. The postoperative follow-up was favourable with a 1-year follow-up.



femoral hernia

Pic. 1) the image shows the left inguinal swelling



Pic. 2) The image shows the necrotic bowel loop.

Discussion :

«A femoral hernia is an uncommon, acquired condition, which has been reported in less than 5% of all abdominal wall hernias, with a female to male predominance of 1.8:1. It is twice as common in parous as non-parous women. Approximately 60% of femoral hernias are found on the right, 30% on the left, and 10% bilaterally » (4).

The low incidence of femoral hernias causes them difficult to study in randomized trials and existing literature is mainly based on patient series of varying sizes (5).

« These occur when there is weakness in the femoral canal and arise inferior to the inguinal ligament, protruding through the femoral ring. They lie medial to the femoral nerve and vessels, often indenting or compressing the femoral vein, and lateral to the lacunar ligament and inferior aspect of the inguinal canal » (6).

Femoral hernias usually contain preperitoneal fat or segments of the small bowel; nonetheless, other contents, such as stomach, colon, appendix... (2).

The commonest presentation is that of a strangulated femoral hernia. It can sometimes present as necrotising fasciitis or small bowel obstruction (7).

The diagnosis of groin hernias is clinical, based on history and examination (8).

Delayed diagnosis or misdiagnosis occurs in 35–75% of patients and contributes to increased morbidity. Some femoral hernias are diagnosed in the preoperative period as groin hernia recurrence (8).

« The findings of epiploic appendagitis would be seen however the hernial sac is above the inguinal ligament. In an indirect inguinal hernia the sac arises lateral to the inferior epigastric vessels and often compresses the fat in the inguinal canal into a lateral crescent. A blind ending thickened tubular structure with attachment to the caecum representing the inflamed appendix, potentially containing an appendicolith at its base with periappendiceal fat stranding within a femoral hernial sac. Gas containing diverticulum with colonic wall

thickening and pericolic fat stranding and often adjacent free fluid in a femoral hernial sac » (6).

« If incarceration or strangulation dictates the need for an emergent operation, the preperitoneal approach is the preferred method. This operation requires general or spinal anesthesia, which may result in a slightly higher risk of cardiopulmonary complications in elderly individuals. The affected area or disease can be reached rapidly with excellent visualization of the external iliac-femoral vein structure.

Laparoscopic management of femoral hernias using totally extraperitoneal (TEP) or transabdominal preperitoneal (TAPP) have also been described » (4).

Conclusion :

Femoral hernia in men is very rare. It can cause difficulties for clinicians and surgeons. The diagnosis is confirmed clinically. Imaging tests have no place in this context. Its treatment is surgical. One must be very careful when dealing with a strangulated hernia because it is an extreme emergency that the patient must not be left to wait and must be operated on immediately.

Ethical Approval:

As per international standard or university standard written ethical approval has been collected and preserved by the author(s).

Consent

As per international standard or university standard, patients' written consent has been collected and preserved by the author(s).

Reference :

1. Ogbuanya AUO, Olisa FU, Ewah RL, Nweke O, Ugwu NB. Femoral Hernia: Epidemiology and challenges of management in a sub-saharan African Country. Asian J Med Sci. 1 nov 2020;11(6):77-83.
2. Viveiros D, Lázaro A, Carvalho H. Femoral Hernia Containing the Right Fallopian Tube: A Rare Finding. Rev Bras Ginecol Obstet. août 2019;41(08):520-2.
3. Femoral hernia in male.pdf.
4. Sucandy I, Kolff J. Incarcerated femoral hernia in men: Incidence, diagnosis, and surgical management. North Am J Med Sci. 2012;4(11):617.
5. Marciniuk P, Jagielak D, Rogowski J, Gumieła P, Bury K. Femoral hernia in the era of TAVI – a potential obstacle for transfemoral approach: a case report and literature review. BMC Surg. déc 2020;20(1):26.

6. McArthur C, McArthur D. Epiploic Appendagitis in a Femoral Hernia. *Radiology Case*. 25 mai 2019;13(5):10-4.
7. Doddi S, Sagar V, Singhal T, Balakrishnan S, Smedley F, Sinha P. Femoral Hernia with a Twist. *Case Reports in Medicine*. 2010;2010:1-3.
8. Aneiros Castro B, Cano Novillo I, García Vázquez A, López Díaz M, Benavent Gordo MI, Gómez Fraile A. Pediatric femoral hernia in the laparoscopic era: Pediatric femoral hernia. *Asian J Endosc Surg*. août 2018;11(3):233-7.

UNDER PEER REVIEW