

Cecal Volvulus: Etiology Uncommon of intestinal occlusion Acute

ABSTRACT

Caecum volvulus is, in frequency, the second part of the colon concerned by volvulus after the sigmoid and before the transverse colon. This pathology occurs in the cecum with abnormal mobility. The mechanism of volvulus can be summarized in 2 either by torsion or tilting. The clinical picture is that of an acute intestinal occlusion by strangulation. The abdomen without preparation (ASP) and the abdominal CT are the radiological examinations of the first choice for the diagnosis. It is a surgical emergency, the conduct of which is to make a resection of the cecum and the terminal ileum. We report the case of a cecal volvulus admitted to the emergency room with an acute intestinal obstruction, the diagnosis was confirmed by an abdominopelvic CT scan and the treatment consisted of an ileocecal resection with immediate restoration of continuity, the postoperative follow-up was simple

keywords: Cecal volvulus, Bowel obstruction, Manual untwisting, Caecopexy

Introduction

The first description of cecal volvulus was made by Rokitsky in 1837[1].

The volvulus of the cecum is an axial torsion of the cecum, involving the terminal ileum due to abnormal fixation of the cecum [2].

“It is responsible for 25-40% of all colonic volvuli in adults. It represents the second most frequently affected part of the colon by volvulus after the sigmoid” [4]. “The clinical signs are of a similar intestinal obstruction and they are not specific to cecal volvulus, and it is difficult to differentiate cecal volvulus from other forms of intestinal obstruction” [3]. The diagnosis may be delayed.

“Acute caecal volvulus may progress to caecal gangrene with necrosis and then to perforation leading to acute peritonitis. Abdominal radiography and abdominal CT are the essential radiological procedures for the diagnosis of the volvulus of the cecum” [6]. “The only effective treatment for cecal volvulus is surgical resection” [5].

Patient and observation

He is a 38-year-old patient followed for chronic dermatitis under corticotherapy and was admitted to the emergency room for occlusive syndrome with symptomatology evolving five days before the consultation with clinical examination: conscious patient stable on the hemodynamic and respiratory plan. The examination noted a distended abdomen, hypertympanic, the hernial orifices were free and the rectal ampulla was empty. The biological workup revealed an HB 13 g/d; hyperleukocytosis with predominantly PNN at 15 000 elements/mm³, CRP was elevated to 150 mg/l, renal function was normal urea 6 mmol/L, creatinemia 10 mg/l, unprepared abdomen in the standing position, which revealed a hydroaerobic level of the greaves and abdominal CT which showed a colonic occlusion on volvulus of the colon with the collapse of the left and right colonic frame with highlighting of an aspect of whirl sign at the level of the right flank (Figure 1, Figure 2).

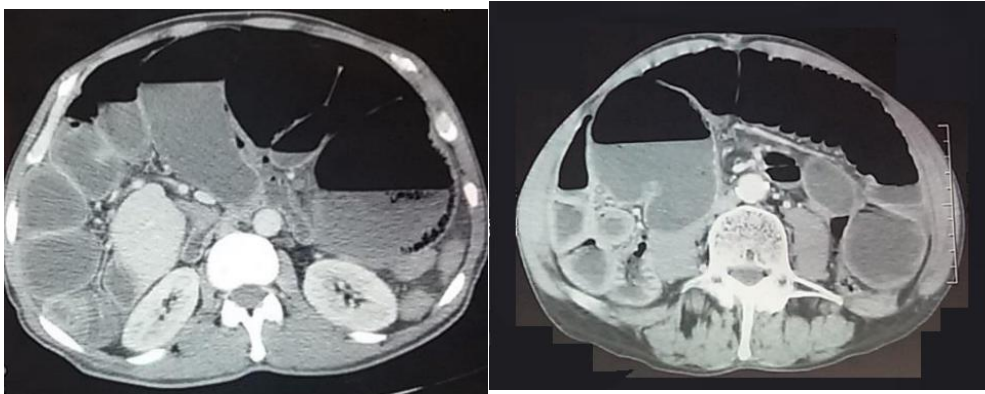


Figure. 1. transversal cut Abdominal CT

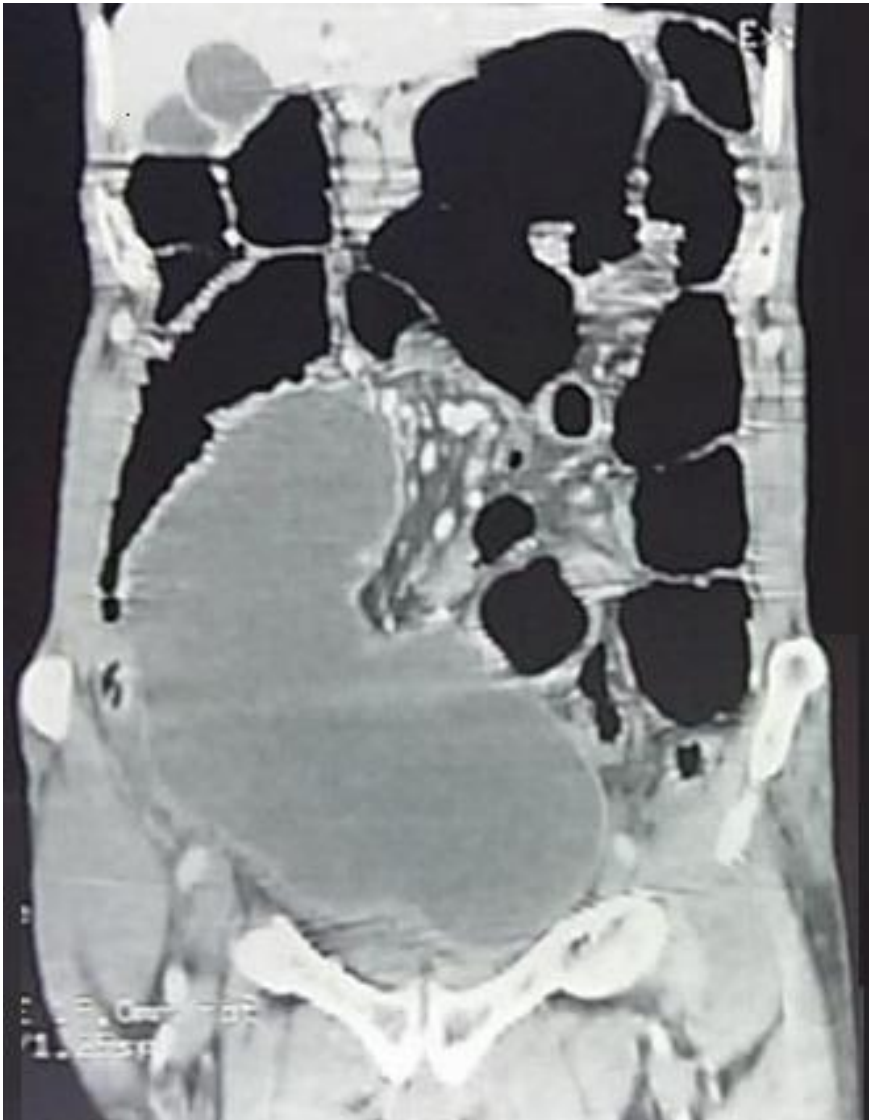


Figure. 2. Frontal Reconstruction Abdominal CT

the patient was operated in the emergency room, approached by laparotomy with the exploration we found a volvulated cecum realizing 1 turn of a spire in the anticlockwise direction (Figure 3), the patient had an ileocecal resection with manuaileocolic terminal-lateral anastomosis .

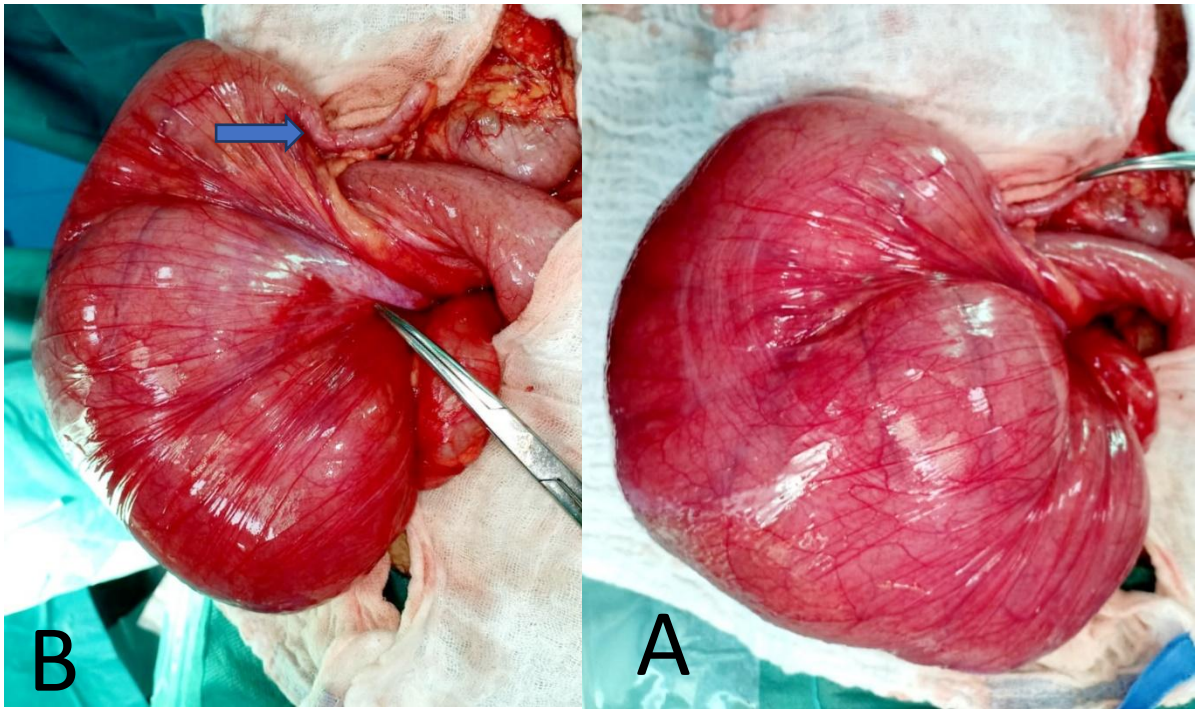


Figure. 3. Intraoperative view showing; A: unfixed Cecum to the retroperitoneum after manual untwisting. B: Appendix (arrow)

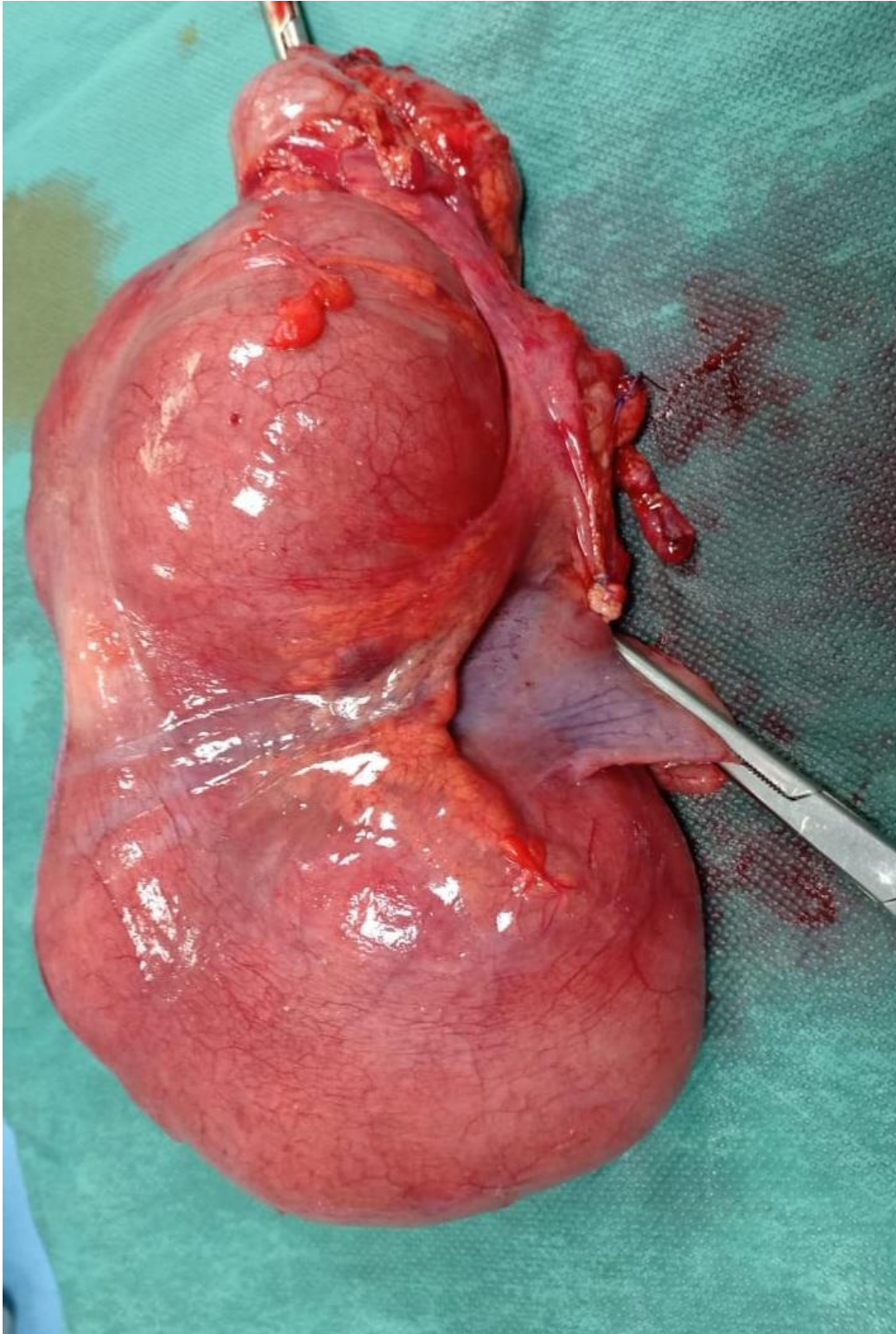


Figure. 4. After operative view showing

Discussion

Caecal volvulus is a rarely diagnosed clinical situation for intestinal obstruction [7] and an uncommon etiology [7]. It is responsible for about 1 to 1.5% of all intestinal obstructions, while 20 to 40% of all colonic volvulus. Its incidence is 2.8-7.1 cases per million population per year [4].

The volvulus of the cecum is a torsion of the right colon around its mesenteric axis which is only possible if the proximal colon is mobile or if congenital anomalies in which the right colon does not fuse properly with the lateral peritoneum [9] Excessive mobility of the cecum is due to an incomplete embryological rotation of the intestine or to a defect in the attachment of the ascending colon to the posterior parietal peritoneum [14,15].

Caecal volvulus may occur as a result of adhesions due to abdominal surgery, chronic constipation, pregnancy, or prolonged immobility [11]. Two types of volvulus have been described: either by a rotation of the colon around its axis, with the cecum remaining in the right lower abdominal or by a tilting of the cecum associated with a rotation of the colon which is then placed in the left upper abdominal quadrant of the abdomen [12,16,17]. The diagnosis of cecal volvulus is difficult because the clinical signs are not specific and the intensity of the pain is extremely variable [15].

Cugnenc et al. reported in a series a mean age of onset of cecal volvulus of 61.8 years and no gender-related predisposition was established [10].

“The Mobile caecum syndrome has been reported to occur in nearly 50% of patients before the onset of acute volvulus” [13].

“Typically, patients present with generalized abdominal pain or predominantly lower quadrant abdominal pain with abdominal distension, and pain resolution after the passage of flatus, The physical findings in patients during symptomatic episodes may include high pitched bowel sounds and right lower quadrant abdominal tenderness. However, these abnormal physical findings generally disappear as the patients’ symptoms resolve” [18].

“In the acute volvulus stage, the patient typically presents with signs of acute bowel obstruction and it is difficult to differentiate caecal volvulus from other forms of small bowel obstruction. A tender and dilated cecum may be palpable in the patient with low BMI, and may help to differentiate cecal volvulus from other forms of bowel obstruction” [19].

In the advanced stage, patients typically present with generalized and severe abdominal pain, peritoneal irritation disturbances of consciousness , and hemodynamic instability [20].

The unprepared abdominal film can be useful for diagnosis, but its sensitivity is generally low [12] with three typical signs present: dilatation of the cecum; a single hydroaerobic level in the right lower quadrant; and absence of gas in the right colon.

However, up to 30% of patients do not have these radiographic features [21].

“Barium enema is not recommended for patients with suspected perforation and gangrene” [22,23].

“CT scan replaced barium enema as the preferred imaging modality for the diagnosis of acute cecal volvulus” [6]. The abdominal CT scan is a powerful diagnostic tool, it allows the diagnosis of an associated complication such as ischemia or perforation [16].

“The three pathognomonic CT signs associated with acute cecal volvulus are: “whirl signs”, “coffee bean” and “bird beak”; In the setting of acute cecal volvulus, the whirl is composed of the spiraled loop of the collapsed caecum, with low attenuating fatty mesentery and engorged mesenteric vessels” [6]. “Visualization of a gas-filled appendix is also a CT scan sign associated with cecal volvulus. The CT scan may show signs of intestinal necrosis or ischemia, which manifest as submucosal edema, diminished or non-enhancement of the intestinal wall, pneumatosis intestinalis, or signs of intestinal perforation such as pneumoperitoneum” [6].

Several studies have reported “successful colonoscopic reduction of cecal volvulus. The success rate of colonoscopic reduction of cecal volvulus is only 30% with the risk of colonic perforation colonoscopy is not recommended for the treatment of cecal volvulus”. [24]

It is generally accepted that the only effective treatment for cecal volvulus is surgery.

Endoscopic detorsion is feasible in the absence of severe ischemia but carries a non-negligible risk of perforation [8]. Treatment has three goals: to remove the obstacle by detorsion, if possible, to treat progressive complications, and to prevent recurrence [25]. It remains a controversial subject. Right hemicolectomy with primary anastomosis is recommended by several teams even in the absence of colonic necrosis because it eliminates the risk of recurrence [26-27]. Caecostomy is effective for the prevention of recurrence but carries a high risk of wall infection and exposes the risk of digestive fistula requiring a closure procedure

Laparoscopic procedures are being increasingly used to manage cecal volvulus. Several reports of laparoscopic treatment of cecal volvulus were published [5] and infectious complications are less frequent with caecopexy but recurrences are more frequent [2].

Conclusion

The variability of the topography of the ileocecal region and its peritoneal attachments is important. Caecal volvulus should be considered in patients with acute abdominal pain, especially when there are suggestive radiological signs. The diagnosis is most often delayed due to non-specific clinical signs. Rapid and adapted management is necessary to decrease the risk of morbidity and mortality.

Ethical Approval:

As per international standard or university standard written ethical approval has been collected and preserved by the author(s).

Consent

As per international standard or university standard, patients' written consent has been collected and preserved by the author(s).

REFERENCES

- [1] C. Rokitansky, Intestinal strangulation, *Arch. Gen. Med.* 14 (1) (1837) 202–210.
- [2] R. Rabinovici, D.A. Simansky, O. Kaplan, et al., Cecal volvulus, *Dis. Colon Rectum* 33 (9) (1990) 765–769.
- [3] E. Pulvirenti, L. Palmieri, A. Toro, I. Di Carlo, Is laparotomy the unavoidable step to diagnose caecal volvulus? *Ann. R. Coll. Surg. Engl.* 92 (5) (2010) 27–29.
- [4] R. Bandurski, K. Zareba, B. Kedra, Cecal volvulus is a rare cause of intestinal obstruction, *Pol. Przegl. Chir.* 83 (9) (2011) 515–517.
- [5] T. Tushimi, H. Kurazumi, Y. Takemoto, K. Oka, T. Inokuchi, A. Seyama, et al., Laparoscopic rectopexy for mobile cecum syndrome manifesting as cecal volvulus: report of a case, *Surg. Today* 38 (4) (2008) 359–362.
- [6] E. Delabrousse, P. Sarliève, N. Saille, S. Aubry, B.A. Kastler, Cecalvolvulus: CT findings and correlation with pathophysiology, *Emerg. Radiol.* 14 (6) (2007) 411–415.
- [7] J. Habre, N. Sautot-Vial, C. Marcotte, D. Benchimol, Caecal volvulus, *Am. J. Surg.* 196 (5) (2008) 48–49.
- [8] Friedman JD, Odland MD, Burbrick MP. Experience with colonic volvulus. *Dis Colon Rectum.* 1989; 32(1): 409- 416. PubMed | Google Scholar
- [9] J.A. Wolfer, L.E. Beaton, B.J. Anson, Volvulus of the cecum. Anatomical factors in its etiology, *Surg. Gynecol. Obstet.* (1942) 882–894
- [10] P.H. Cugnenc, F. Gayral, H. Larrieu, M. Garbay, Volvulus aigu du cæcum : à propos de 10 observations, *Chirurgie* 108 (3) (1982) 279–283
- [11] D.G. Howard, J. Catto, Cecal volvulus. A case for nonresectional therapy, *Arch. Surg.* 115 (3) (1980) 273–277.

- [12] Pirró N, Merad A, Sielezneff I, Sastre B, Di Marino V. Volvulus du cæcum, bases anatomiques et physiopathologie: à propos de 8 cas consécutifs. *Morphologie*. 2006; 90(1): 197- 20. PubMed | Google Scholar
- [13] K.J. Printen, Mobile cecal syndrome in the adult, *Am. Surg.* 42 (3) (1976) 204–205
- [14] Berger JA, Leersum MV, Plaisier PW. Cecal volvulus: Case report and overview of the literature. *European Journal of Radiology Extra*. 2005; 55(4): 101-103. PubMed | Google Scholar
- [15] O'Mara CS, Wilson TH Jr Stonesifer GL, Stonesifer L, Cameron JL. Cecal volvulus: analysis of 50 patients with long-term follow-up. *Ann Surg.* 1979; 189(6): 724- 731. PubMed | Google Scholar
- [16] Moore CJ, Corl FM, Fishman EK. CT of cecal volvulus: unraveling the image. *AJR Am J Roentgenol.* 2001; 177(1): 95-98. PubMed | Google Scholar
- [17] Perret RS, Kunberger LE. Case 4: Cecal volvulus. *AJR Am J Roentgenol.* 1998 Sep; 171(3): 855-60. PubMed | Google Scholar
- [18] J.R. Anderson, J.O.M. Mills, Caecal volvulus: a frequently missed diagnosis? *Clin. Radiol.* 35 (1) (1984) 65–69.
- [19] J.L. Donhauser, S. Atwell, Volvulus of the cecum with a review of 100 cases in the literature and a report of six new cases, *Arch. Surg.* 58 (2) (1949) 129–148.
- [20] T.E. Madiba, S.R. Thomson, The management of cecal volvulus, *Dis. Colon Rectum* 45 (2) (2002) 264–267.
- [21] W.J. Halabi, M.D. Jafari, C.Y. Kang, V.Q. Nguyen, J.C. Carmichael, S. Mills, et al., Colonic volvulus in the United States: trends, outcomes, and predictors of mortality, *Ann. Surg.* 259 (2) (2014) 293–301.
- [22] W.S. Young, Further radiological observation in caecal volvulus, *Clin. Radiol.* 31 (4) (1980) 479–483.
- [23] E.T. Consorti, T.H. Liu, Diagnosis and treatment of caecal volvulus, *Postgrad. Med. J.* 81 (962) (2005) 772–776.
- [24] J.R. Anderson, G.H. Welch, Acute volvulus of the right colon: an analysis of 69 patients, *World J. Surg.* 10 (2) (1986) 336–342.
- [25] C.S. O'Mara, T.H. Wilson Jr., G.L. Stonesifer, G.L. Stonesifer, J.L. Cameron, Cecal volvulus: analysis of 50 patients with long-term followup, *Ann. Surg.* 189 (6) (1979) 724–731
- [26] Breda R, Mathieu L, Mlynski A, Montagiani L, Duverger V. Volvulus du cæcum. *J Chir (Paris)*. 2006; 143(1): 330-2. PubMed | Google Scholar
- [27] Sedik A, Bar EA, Ismail M. Cecal volvulus: Case report and review of literature. *Saudi Surg J.* 2015; 3(2): 47-9. PubMed | Google Scholar
- [28] Meyers JR, Heifetz CJ, Baue Æ. Cecal volvulus: a lesion requiring resection . *Arch Surg.* 1972; 104(6): 594- 599. PubMed | Google Schola