

# Acute Appendicitis due to *Enterobius vermicularis* : three case reports and literature review

---

## ABSTRACT

Pinworm infection is highly contagious considered to be the most common helminth infection, The association of this parasitic infestation with pathogenesis of acute appendicitis had been studied for many years, and is still unclear. We present three cases of enterobiasis of appendix presented as acute appendicitis in whom emergency appendectomy was performed. The finding of *E. vermicularis* in appendectomy pathological specimens is a rare incident, parasitic infections rarely cause acute appendicitis.

*Keywords: Appendix, acute inflammation, Appendectomy, Enterobius vermicularis*

## 1. INTRODUCTION

*E. vermicularis* (pinworm) is a small, white obligate nematode that affects 1000 million individuals worldwide and is considered to be the most common helminth infection.(1) The association of this parasitic infestation with acute appendicitis varies from 0.2%–41.8% worldwide.(2) We present three cases of enterobiasis of appendix presented as acute appendicitis

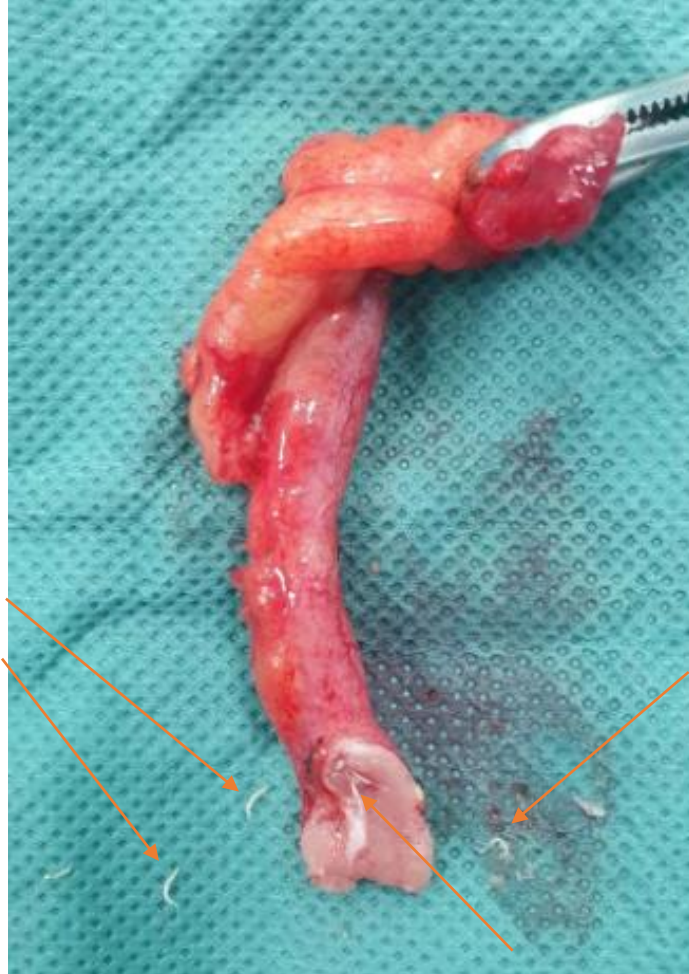## 2. MATERIAL AND METHODS

CASE 1 : A 39-year-old man presented with a 48-hour history of abdominal pain located in the right lower quadrant. His physical examination revealed tenderness in the right iliac fossa, local guarding and rebound tenderness at the McBurney point, **Rectal examination without particularities and the rest of the clinical examination normal** consistent with signs of acute appendicitis. His body temperature was 39,3°C. Laboratory investigations showed a moderately elevated white cell count (12,000/mm<sup>3</sup>) **CRP 16 mg/l**. The ultrasound showed a swollen appendix is identified, reaching a diameter of 12 mm, an appendectomy was performed, Macroscopic examination showed multiple worms visible adherent to the mucosa, The patient was discharged from hospital one day after the surgery and has been treated with albendazole.

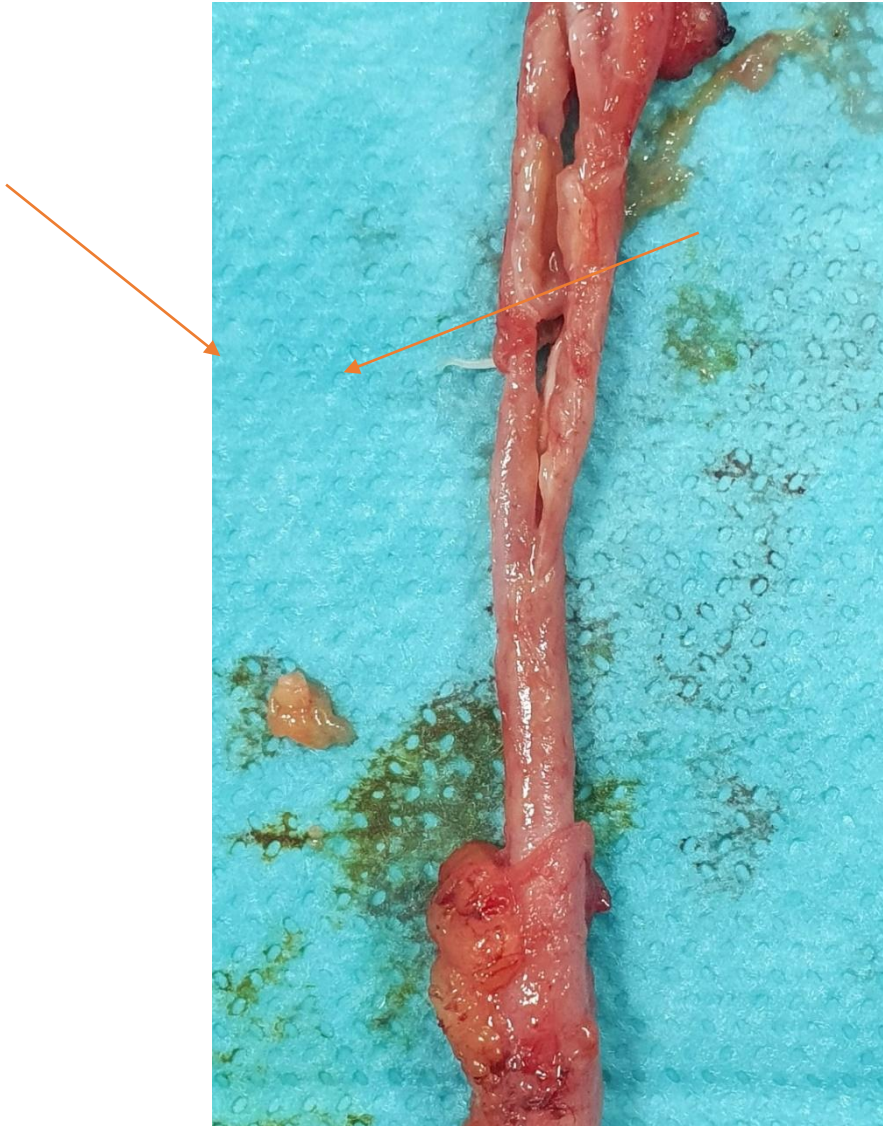
CASE 2 : A 32-year-old woman walked into the emergency room due to abdominal pain. Physical examination revealed fever of 39°C blood pressure (12/70 mmHg) and heart rate (75 beats/min) tenderness in the right iliac fossa **Rectal examination without particularities and the rest of the clinical examination normal**. Laboratory data on admission showed white blood cell count of 14340/mm<sup>3</sup> **CRP 12 mg/l**. An abdominal ultrasound revealed showed a non-compressible and inflamed appendix. An appendectomy was performed, The examination of spicemen showed multiple intraluminal worms The patient was discharged from hospital on the first postoperative day and has been treated with albendazole.

CASE 3 : A 17 years-old man Admitted to surgical emergency due to right iliac fossa pain, abdominal examination revealed a muscular defense in the right lower quadrant of the abdomen, **Rectal examination without particularities and the rest of the clinical examination normal** Laboratory data on admission showed white blood cell count of 15350/mm<sup>3</sup> **CRP 6 mg/l**. The abdominal ultrasound showed acute appendicitis measuring 10 mm in diameter. An appendectomy was performed

**The patients spicemen examination showed multiple intraluminal worms. The patients recovered well and were discharged one day after the operation with treatment with antihelminthic drugs.**



**Figure 1.** Multiple worms of *Enterobius vermicularis* after opening of the resected appendix.



**Figure 2.** Multiple worms of *Enterobius vermicularis* after opening of the resected appendix.

### **3. RESULTS AND DISCUSSION**

*E. vermicularis* (pinworm), formerly known as *Occiur vermicularis* or *oxyurides*, is a small, white obligate nematode that affects 1000 million individuals worldwide. It has also been referenced in the ancient writings of Hippocrates, as far back as 430 BC, However, it was Fabrius in 1634 who first described involvement of the worm in appendicitis. (1)

Pinworm infection is highly contagious and spreads through human-to-human transmission, by swallowing infectious pinworm eggs , these eggs are usually deposited onto a surface or object by a person who's been infected. The cycle of infection begins with the ingestion of these microscopic eggs.(3) Once the eggs enter the body, they remain in the intestine until

they hatch and mature, as adults, the female pinworms move into the colon and exit the body through the anus at night, Female pinworms lay eggs in the folds of skin around the anus and then return to the colon. The most common clinical presentation of pinworm infection is perianal itching, predominantly occurring at night-time.(4)

When a person scratches the affected area, the pinworm eggs transfer to the fingers. The eggs can survive for several hours on the hands, the eggs can transfer from contaminated fingers directly to food or liquids, also Children transfer pinworm eggs easily because they may put infected toys or other objects directly into their mouths.(4)

Nocturnal anal pruritus is the main symptom, with anorexia, behavioral problems (irritability, insomnia, nightmares) and sometimes pain in the right iliac fossa suggestive of appendicitis (13, 14]. Sometimes, parasitological examination of the stools allows the eggs to be found and often adults in variable quantities, between 1 and 117 (15). The exit of pinworms through an appendectomy scar has already been reported (16). The detection of pinworms in appendicitis is quite frequent: 1.62% in frequent: 1.62% in Nepal [49], 2.5% in France (17), 2.9% in Iran (18), 3.5% in Iran (18), 3.8% in Turkey (25), 4.1% in Denmark (in 2,200 appendicitis cases) (23), 7.3% in Tunisia (in 5,000 appendicitis) (19). In these studies, pinworms were found more often in a healthy appendix (8.4%) than in an inflammatory appendix (20), sometimes with lymphoid hyperplasia (21) and an infiltrate of eosinophilic eosinophilic infiltrate in the lamina propria (22). This pathology is mostly encountered in adolescents, with a sex ratio of 1 and it is as if the adult worms were leaving the leave the inflammatory appendages or avoid entering them (23), appendages (23), Pinworms are mainly endoluminal and sometimes intraparietal (22). A case of appendicular syndrome has been reported, with pinworms in Meckel's diverticulum (24).

Despite that the relationship between *E. vermicularis* and pathogenesis of appendicitis had been studied for many years, the influence of the parasite to induce inflammation is still unclear.(5) Although pinworm may have a role in causing appendiceal discomfort or appendiceal chronic inflammation due to obstruction of the lumen of appendix, or they may elicit hypersensitivity reaction in the tissues causing clinical picture of acute appendicitis, The majority of cases have no acute inflammation .(6,7)

The laparoscopic appendectomy is safe and efficient operative procedure over open method , it provides clinically beneficial advantages, However, in this cases it runs the risk of contamination of the peritoneal cavity with worms. (8)

Pharmacological eradication with antihelminthics such as mebendazole is also required and Education about hand hygiene should also be provided (5)

In the case of chronic recurrent infection, simultaneously treating all (including asymptomatic) members of a household (parents, siblings, grandparents, fellow occupants) has proved a successful approach.(4)

Parasites have been implicated in 1.9-25% of appendicitis cases of appendicitis depending on the authors and countries (9, 10). Many parasites have been found in the appendix: pinworms, whipworms, roundworms (11), taenia, amoebae, Anisakis, an association being naturally possible (12). Anguillidae have also been found in countries where the prevalence of this parasitosis is high, as well as as well as bilharziasis, essentially *Schistosoma haematobium* [1] (Table III). Parasites that may be responsible for appendicitis include mainly helminths and somehelminths and some

protozoa, as shown in Table III, already Table III, which is already many years old, but which is still is still valid.

Parasite	Nombre	Pourcentage
Amibes	2 510	3,02
Oxyures	319	0,63
Trichinella	191	0,38
Trichocéphales	146	0,29
Ascaris	97	0,19
Giardia	61	0,12
Ankylostomes	51	0,10
Taenia saginata	24	0,04
Anguillules	21	0,04
Hymenolepis nana	17	0,03
Taenia solium	16	0,03
Bothriocéphale	11	0,02
Paragonimus	9	0,01
Balantidium	6	0,01
Schistosma mansoni	6	0,01
Schistosoma japonicum	5	0,01
Fasciolopsis buski	2	0,004
Wuchereria bancrofti	2	0,004
Fasciola hepatica	1	0,002

**Table 1.** Parasites found in a study of 50,000 human appendages

#### 4. CONCLUSION

The finding of *E. vermicularis* in appendectomy pathological specimens is a rare incident, parasitic infections rarely cause acute appendicitis. (3) The treatment of choice is surgical resection of the appendix and Pharmacological eradication with antihelminthics. (6)

#### REFERENCES

1. Dunphy L, Clark Z, Raja MH. *Enterobius vermicularis* (pinworm) infestation in a child presenting with symptoms of acute appendicitis: a wriggly tale! *BMJ Case Reports*. 6 oct 2017;bcr-2017-220473.
2. Efraimidou E, Gatopoulou A, Stamos C, Lirantzopoulos N, Kouklakis G. *Enterobius Vermicularis* infection of the appendix as a cause of acute appendicitis in a Greek adolescent: a case report. *Cases Journal*. déc 2008;1(1):376.
3. Panidis S, Paramythiotis D, Panagiotou D, Batsis G, Salonikidis S, Kaloutsi V, et al. Acute appendicitis secondary to *Enterobius vermicularis* infection in a middle-aged man: a case report. *J Med Case Reports*. déc 2011;5(1):559.
4. Wendt S, Trawinski H, Schubert S, Rodloff AC, Mössner J, Lübbert C. The Diagnosis and Treatment of Pinworm Infection. *Deutsches Ärzteblatt international* [Internet].

29 mars 2019 [cité 19 juin 2022]; Disponible sur: <https://www.aerzteblatt.de/10.3238/arztebl.2019.0213>

5. Habashi R, Lisi MP. Acute appendicitis and *Enterobius vermicularis* infestation. *CMAJ*. 29 avr 2019;191(17):E477-E477.

6. Hammood ZD, Salih AM, Mohammed SH, Kakamad FH, salih KM, Omar DA, et al. *Enterobius vermicularis* causing acute appendicitis, a case report with literature review. *International Journal of Surgery Case Reports*. 2019;63:153-6.

7. Alejandro Villalobos C, Fernández-SanMillán D, López-Tomassetti Fernández E, Hernández Hernández JR. Acute Appendicitis Due to Parasitosis. *Cirugía Española (English Edition)*. mai 2018;96(5):306-8.

8. Mohammed N, Mohamed F. Incidental Acute Appendicitis due to *Enterobius vermicularis*. *Clin Med Img Lib [Internet]*. 3 oct 2021

9. Collins D.C., A study of 50 000 specimens of the human appendix, *Surgery Gynec. Obst.* 101 (1955) 437-445

10. Essomba A., Chichom Mefire A., Fokou M., Ouassouo P., Masso Misse P., Esiene A. et coll., Abdomens aigus d'origine parasitaire : analyse rétrospective de 135 cas, *Ann. Chir.* (2006) 194-197

11. Villamizar E., Mendez M., Bonilia E., Varon H., De Onatra S., *Ascaris lumbricoides* infestation as a cause of intestinal obstruction in children: experience with 87 cases, *J. Pediatr. Surg.* 31 (1996) 201-214

12. Gupta S.C., Gupta A.K., Keswani N.K., Singh P.A., Tripathi A.K., Kristhan V., Pathology of tropical appendicitis, *J. Clin. Pathol.* 42 (1989) 1169-1172.

13. Budd J.S., Armstrong C., Role of *Enterobius vermicularis* in the aetiology of appendicitis, *Br. J. Surg.* 74 (1987) 748-749.

14. Wiebe B.M., Appendicitis and *Enterobius vermicularis*, *Scand. J. Gastroenterol.* 26 (1991) 336-338

15. Coutelen F., Deblock S., Biguet J., Capron A., L'oxyure appendiculaire, À propos de 132 appendicectomies chez les enfants du nord de la France, *Echo Méd. Nord* 27 (1956) 114-131

16. Cazin A., Clotteau J.E, Bourée P., Fistule stercorale spontanée à oxyures : à propos d'un cas, *Bull. Soc. Pathol. Exot.* 72 (1979) 164-168.

17. Galley F, Houcke M, Poirriez J, Coisne F., Parasitoses appendiculaires dans le nord de la France, *Presse Med* 14 (1985) 843.

18. Ramezani A.M, Dehghani M.R., Relationship between *Enterobius vermicularis* and the incidence of acute appendicitis, *Southeast As. J. Trop. Med. Pub. Hlth* 38 (2007) 20-23.

19. Khodjet El Khil A., Zitouna M.M., Chadli A., Maamouri M.T., L'oxyure appendiculaire, À propos de 368 cas, *Nlle Presse Méd.* 10 (1981) 2585- 2586.

20. Sah S.P., Bhadani P.P., Enterobius vermicularis causing symptoms of appendicitis in Nepal, Trop. Doct. 36 (2006) 160-162
21. Da Silva D.F., da Silva R.J., da Silva M.G., Sartorelli A.C., Rodrigues M.A., Parasitic infection of the appendix as a cause of acute appendicitis, Parasitol. Res. 102 (2007) 99-102.
22. Makni S., Makni F., Ayadi A., Jlidi R., L'oxyurose appendiculaire, À propos de 205 cas, Ann. Chir. 52 (1998) 668.
23. Wiebe B.M., Appendicitis and Enterobius vermicularis, Scand. J. Gastroenterol. 26 (1991) 336-338
24. Abramson D.J., Acute appendicitis and a Meckel's diverticulum with Enterobius vermicularis, Am. Surg. 32 (1966) 343-346.
25. Yildirim S., Nursal T.Z., Tarim A., Kayaselcuk F., Noyan T., A rare cause of acute appendicitis, Scand. J. Infect. Dis. 37 (2005) 757-759