

# Perforation of Diverticulum of Jejunum: A Rare Gastrointestinal Presentation

## Case Report

### ABSTRACT

Small bowel diverticula are very rare. The incidence ranges from 0.06 to 1.3%, with high prevalence after 60 years of age. Of these small intestinal diverticula, the duodenal diverticulum is more common, followed by jejunal and ileal diverticula. Jejunal diverticula are rare and are usually asymptomatic acquired lesions. If symptomatic, chronic nonspecific symptoms like pain, nausea and malnutrition may occur and sometimes acute symptoms such as gastrointestinal bleeding, peritonitis and obstruction may occur. Chronic pain and malabsorption occur in 40% of cases, but perforation occurs only in 2.3–6.4% of all patients with diverticula [1]. This case report describes a emergency case of 87 years old man with a 2 days history of pain abdomen. Plain radiograph study of abdomen shows the presence of gas under both diaphragmatic domes, suggesting a hollow viscus perforation. Physical examination suggested of soft abdomen with generalised tenderness of whole abdomen, more marked in right upper and lower quadrants. Emergency laparotomy was done, which revealed mesenteric border of jejunum having multiple diverticula, one of which was perforated approximately 15 cm distal to duodena-jejunal junction.

*Keywords: Jejunal; diverticulum; perforation.*

### 1. INTRODUCTION

“Small bowel diverticula are very rare. The incidence ranges from 0.06 to 1.3%” [2]. “With the exception of Meckel’s diverticulum, which is congenital, all other diverticula are commonly acquired. Of these, duodenal diverticula was the most common (in 79% of patients), followed by jejunal or ileal diverticula (18%) and diverticula of all other segments together (3%)” [3]. “The incidence of diverticula increases with age and peaks between the 6<sup>th</sup> to 8th decades of life. A jejunal diverticulum is usually asymptomatic, only 29% of the patients had symptoms such as nausea, abdominal pain, and malabsorption. Complications such as perforation, adhesions, fistulas, and peritonitis are more common than massive lower gastrointestinal hemorrhage, and these complications are reported in only 10% of cases” [2]. Herein we report a case of jejunal diverticulosis which presented to us with perforation of one of the diverticula. Surgery is

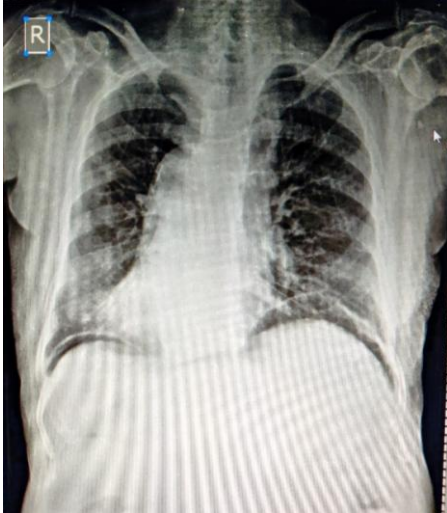
the definitive treatment of choice in diverticular perforation as in our case.

### 2. CASE REPORT

We report the case of an 87-year-old man who presented to our hospital emergency room complaining of abdominal pain for 2 days. The patient had a history of decreased appetite and generalized weakness for the past 1 month. The patient has a history of Anaemia in past 6 months, Diabetes Mellitus Type 2 and Hypertension for the past 20 years, for which he was on continuous treatment. Patient had history of left side knee surgery 8 years back for traumatic injury. Family history was negative for any gastrointestinal complaints.

During the general physical examination, the patient was alert, oriented towards time, place and people. His vital signs showed a pulse rate of 79 beats/min, blood pressure of 100/60 mm

Hg and a saturation of 98% in room air. On abdominal examination, generalised tenderness was present more marked in right upper and lower quadrants of abdomen, guarding present, rebound tenderness present. Laboratory studies showed Haemoglobin-10.2 g/dl, WBC count- 19,300/mm<sup>3</sup> and Platelet count-162000/mm<sup>3</sup>. A plain radiograph of abdomen showed free air under both diaphragmatic domes [Fig. 1]. Initial resuscitation of patient was done with intravenous fluids and antibiotics.



**Fig. 1. XRAY Erect Abdomen: Free air seen under both domes of diaphragm**

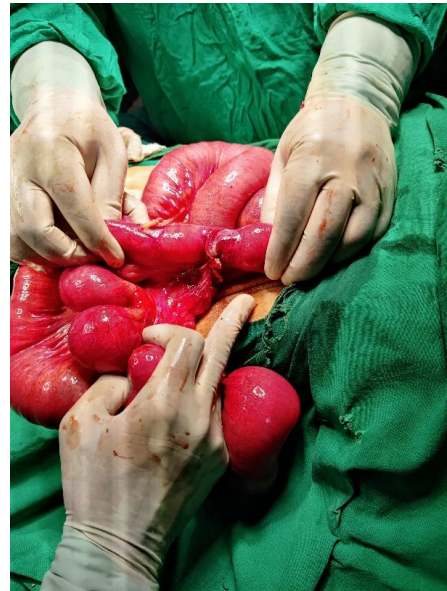
Patient was taken in operating room for emergency laparotomy. On opening of abdomen, multiple diverticula were noted at mesenteric border of jejunum for length of about 45 cm,

### 3. DISCUSSION

“Jejunal diverticula are the least common type of all small intestine diverticula, with an incidence of less than 1%, and are slightly more common in men” [3,4]. “These pseudodiverticula can be pathologically described as an acquired outpouching of mucosa commonly found on the mesenteric border of the jejunum” [5]. “Multiple diverticula were observed in 77% of cases” [6].

“The Clinical diagnosis of diverticular perforation can be difficult because its symptoms can resemble any other exacerbation of acute abdomen and the diagnosis can easily be confused with other causes of an acute abdomen such as diverticulitis of sigmoid colon, appendicitis, peptic ulcer perforation or ischemic disease of intestine” [7]. “The typical presentation of jejunal diverticula mainly is intermittent abdominal pain, alongwith flatulence, diarrhoea or constipation in 10% to 30% cases. In a series of 112 cases of jejuno-ileal diverticulosis

diverticulum of which had perforation of size around 0.5\*0.5 cm at around 15 cm distal to the duodeno-jejunal junction [Fig. 2]. Resection of segment of jejunum containing diverticula was done and then end to end anastomosis was done. Patient was shifted to ICU and was extubated one day after surgery. Patient was shifted to general ward the next day.



**Fig. 2. Intra Operative image showing multiple jejunal diverticula on mesenteric border with perforation of one diverticulum**

analysed by Tsiotos et al., 42% were asymptomatic” [3].

“Among symptomatic patients, diarrhoea (58%) was the most common clinical presentation, followed by chronic pain in abdomen (51%) and abdominal distension (44%). Common acute complications include diverticulitis, bleeding, bowel obstruction, and perforation” [5].

“Standing or sitting abdominal X-rays are useful for the assessment of acute abdomen, but it has a limited contribution of only providing information on intra-peritoneal free air and air-fluid bowel levels to the diagnosis of perforated jejunal diverticulosis. Abdominal Computerised Tomography (CT) has been for quite sometime the most valuable imaging technique for determining the presence, location and etiology of gastrointestinal perforation” [7]. Oral and intravenous dual-contrast CT Abdomen can help diagnose perforated jejunal diverticulum, based on the following findings: free intra-peritoneal air,

concentrated bubbles of extra luminal air near the bowel wall, asymmetric localised thickening of the bowel wall, edema or thickening of the fat or fascial planes surrounding the diverticulum.

“However, there are multiple causes of small bowel perforation that must be taken in consideration for differential diagnosis. Meckel's diverticulitis is one of the most common examples among another diverticular disease of the small bowel. But, unlike the jejunal diverticulum, Meckel's diverticulum is a true congenital diverticulum involving the antimesenteric side of the small intestine” [7]. Meckel's diverticulitis is more common in adults with intussusceptions causing bowel obstruction more than perforation or bleeding. NSAIDs are another contributory factor to ulcers and perforations [8,9]. Although they mainly affect the stomach or ileum, their effects are not limited to these areas and can affect any point in the small intestine [10,8]. It is difficult to distinguish Perforated neoplasms and neoplasm in the jejunum is lymphoma in most of the cases.

Indication of intervention is when complications occur. In our case, a partial resection of the segment of jejunum containing diverticula was done to prevent complications in future in the rest of the diverticula. Invagination, excision and simple closure are associated with higher mortality than resection [6]. Emergency surgery is needed in 8 to 30% of patients with complications [7].

#### 4. CONCLUSION

Although colonic diverticulitis and diverticular perforation is usually suspected in oldage patients having presentation of abdominal pain and fever, differential diagnosis of jejunal diverticulitis should be taken into consideration. High degree of suspicion is required clinically, owing to the low incidence of the condition. Early diagnosis and rapid treatment are required to prevent complications and to improve the outcome of the patient. And in case of perforation of perforation like in our case patient require urgent lifesaving surgeries.

#### ETHICAL APPROVAL

As per international standard or university standard written ethical approval has been collected and preserved by the author(s).

#### CONSENT

As per international standard or university standard, patients' written consent has been collected and preserved by the author(s).

#### COMPETING INTERESTS

Authors have declared that no competing interests exist.

#### REFERENCES

1. Staszewicz, Wojciech et al. Acute ulcerative jejunal diverticulitis: case report of an uncommon entity. *World Journal of gastroenterology*. 2008;14,40:6265-7. DOI:103748/wjg.14.6265
2. Akhrass R, et al. Small-bowel diverticulosis: perceptions and reality. *Journal of the American College of Surgeons*. 1997;184,4: 383-8.
3. Zager, Jonathan S, et al. Jejunal diverticulosis: a rare entity with multiple presentations, a series of cases. *Digestive surgery*. 2000;17.6:643-645.
4. Tsiotos, Gregory G., Michael B. Farnell, and Duane M. Ilstrup. Nonmeckelian jejunal or ileal - diverticulosis: an analysis of 112 cases. *Surgery*. 1994; 116.4:726.
5. Benson, Raymond E, Claude F. Dixon, John M. Waugh. Nonmeckelian diverticula of the jejunum and ileum. *Annals of surgery*. 1943;118.3:377.
6. Patel, Vishal Arun, et al. Jejunal diverticulosis is not always a silent spectator: a report of 4 cases and review of the literature." *World journal of gastroenterology: WJG*. 2008;14.38:5916.
7. Singh S, Sandhu HP, Aggarwal V. Perforated jejunal diverticulum: A rare complication. *Saudi J Gastroenterol*. 2011;17:367.
8. Gurala D, Idiculla PS, Patibandla P, Philipose J, Krzyzak M, Mukherjee I. Perforated jejunal diverticulitis. *Case Reports in Gastroenterology*. 2019;13(3):521-525.
9. Leigh N, Sullivan BJ, Anteby R, Talbert S, Perforated jejunal diverticulitis: a rare but important differential in the acute abdomen. *Surgical Case Reports*. 2020;6(1):1-7.
10. Akbari ME, Atqiaee K, Lotfollahzadeh S, Moghadam AN, Sobhiyeh MR. Perforated jejunal diverticula- a rare cause of acute abdominal pain: a case report. *Gastroenterol Hepatol Bed Bench*. Summer. 2013;6(3):156-8. PMID: 24834264; PMCID: PMC4017513.

