

# **Cervicothoracic Lymphangioma in an Adult: A Rare Entity**

## **Abstract**

### **Background**

Lymphangiomas are uncommon benign lymphatic malformations most commonly seen in the head and neck region. Cervical lymphangiomas with intrathoracic extension are very rare clinical entity and comprise only 1% of the cases.

### **Case Report**

We report here a rare case of a 25 year old female, with complaints of a huge soft, cystic fluctuant and transilluminant swelling involving the right side of the neck and chest. On imaging, it revealed a multilocular thoracocervical mass, which was isointense on T1 and hyperintense on T2, occupying right anterosuperior, middle and posterior mediastinum compressing the upper lobe of the right lung and extending supraclavicularly. Patient was managed surgically via multidisciplinary approach. Histopathological examination confirmed the diagnosis of lymphangioma

### **Discussion and Conclusion**

Imaging and histopathological examination play a key role in diagnosis of lymphangiomas. Such extensive lymphangiomas require complete surgical excision and should be performed by experienced surgeons as this is essential to prevent further recurrences.

**Keywords:** Lymphangiomas, Thoracocervical, Histopathology, Magnetic Resonance Imaging

## **Introduction**

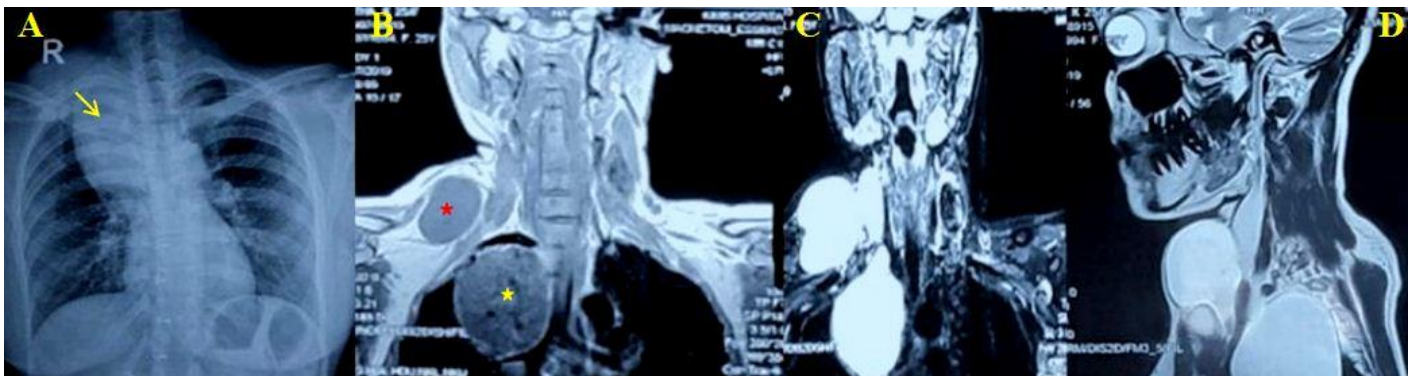
Lymphangiomas are uncommon benign lymphatic malformations most commonly seen in the head and neck region. Cervical lymphangiomas with intrathoracic extension are very rare clinical entity and comprise only 1% of the cases.

## **Case Presentation**

A 25 year old female patient presented to our otolaryngology department with complaints of painless swelling over right side of the neck, which was gradually progressive in size for 3 months. Patient had no complaints of change in voice, dyspnoea or dysphagia. She gave history of similar swelling in the past for which she underwent surgery 7 years back and histopathological examination (HPE) of the excised specimen report revealed Cystic hygroma. Following surgery she was asymptomatic for 6 years. There was no history of similar complaints at birth or in any of the family members.

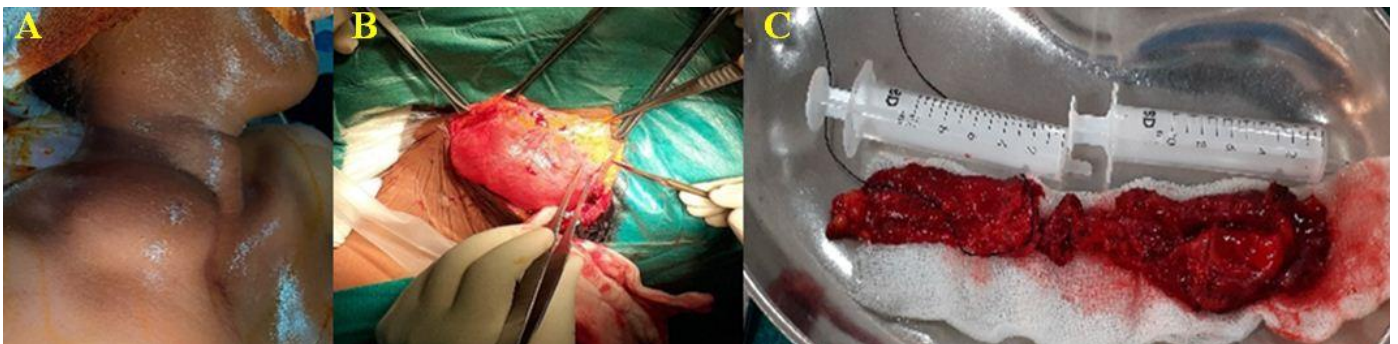
Clinical examination of the neck, revealed a swelling of size 12x6 cm involving lower third of the right side of the neck and extending into the right supraclavicular area. A previous surgical scar was noted over the anterior aspect of upper chest. No discharging sinuses were visualised over the swelling. There was no local rise of temperature or tenderness on palpation of the swelling. The swelling was soft, fluctuant, compressible and brilliantly transilluminant. On further evaluation, ultrasonography of the neck revealed a 12x8.9x8.6cm anechoic cystic lesion in the right side of neck in the subcutaneous plane with multiple septations with avascularity causing compression of the right internal jugular vein. Chest radiograph anteroposterior view revealed a large homogeneous opacity in the anterior mediastinum compressing the upper lobe of the right lung (Fig.1A). Magnetic resonance

imaging (MRI) of the neck and chest revealed a thoracocervical mass of 27x12x14 cm occupying right anterosuperior, middle and posterior mediastinum compressing the upper lobe of the right lung and extending into right lower neck subclavicularly. It was compressing the lower part of the right internal jugular vein. Mass was multilocular and septate with thick walls. T1 weighted images were isointense whereas T2 weighted images showed hyperintensity (Fig.1). All the routine haematological investigations and 2D ECHO were under normal limits.



**Fig. 1.** (A) Chest radiograph AP view showing a large homogeneous opacity (yellow arrow) in the anterior mediastinum compressing the upper lobe of the right lung. (B,C and D) Magnetic resonance imaging (MRI) of the neck and chest showing a thoracocervical mass (red asterix-cervical part, yellow asterix-thoracic part) which is isointense on T1 and hyperintense on T2 weighted images. (B) T1 weighted coronal section isointense on T1 weighted images and (C) T2 weighted coronal section and (D) T2 weighted sagittal sections.

After obtaining consent from the patient, under general anaesthesia surgical excision was performed by a team of Otolaryngologists and Cardiothoracic surgeons. A large dumbbell shaped cystic swelling was seen occupying the right hemithorax which was seen extending subplatysmally and substernally with a connection behind the clavicle, without causing any compression of the trachea and oesophagus. The cyst was completely excised via neck exploration and right anterior thoracotomy approach with sparing the internal jugular vein and the phrenic nerve (Fig. 2). The excised cyst was sent for HPE. Haemostasis was attained. Postoperative period was uneventful. HPE revealed collapsed cystic spaces with supporting fibromuscular connective tissue, lymphoid aggregates with focal giant cell reaction which was suggestive of Lymphangioma. Patient was followed up for 2 years, which showed no



recurrence.

**Fig. 2.** (A) Clinical image of large cystic swelling involving the lower neck and upper chest on the right side. (B and C) Intraoperative image of the cervicothoracic cyst.

## Discussion

Lymphangiomas are degenerative lesions arising from the lymphatics, and can be classified as: simple lymphangiomas, cavernous lymphangiomas and cystic hygromas.[1] Cystic

hygromas are composed of cysts and sinuses, varying in size from a few millimetres to several centimetres in diameter. They usually present as a cystic masses containing eosinophilic acellular lymph fluid.[1].

Although congenital in most of the cases which show usual presentation at birth, sometimes they seem to manifest for the first time in young adults which was the presentation in our case. They can appear anywhere in the head and neck. On palpation they feel cystic and transilluminate. They may remain static or involute, but in some cases they gradually increase in size and occasionally, especially after internal haemorrhage or infection, and can grow rapidly causing compression on trachea leading to life threatening airway obstruction. 90% of the lymphangiomas develop on the body surface, 75% are seen in the neck, mostly involving the posterior triangle and 20% in the axilla.[2,3] 1% of the cystic lymphangiomas have mediastinal localization.[4] The common features helpful in the diagnosis of lymphangiomas are uni or multilocular predominantly cystic masses with clear borders, septations with lobular contours, contiguous extension along the neurovascular planes of mediastinum without mass effect.[5] These findings of lymphangiomas were also seen in our case, with rare presentation in an adult. On Imaging, lymphangiomas are hyperintense on T2-weighted MRI images, and are isointense on T1-weighted.[6]. Treatment options include surgical excision, intralesional sclerosant therapy and radiotherapy.[5] Surgical excision is considered as the treatment of choice. Various surgical approaches include via neck dissection, thoracotomy and mediastinal dissection with sternotomy.

## **Conclusion**

The diagnosis of cervicothoracic lymphangioma is usually made on clinical grounds, but CT and MRI scanning are complimentary in helping to accurately determine the size, exact

anatomical location, and relationship to important structures as well as aiding in surgical planning. Surgical excision remains the treatment of choice but it is challenging due to close association with vital structures and is therefore best undertaken by a multidisciplinary approach to prevent recurrence.

### ***Acknowledgements***

The authors would like to gratefully acknowledge and thank the faculty, patient and attendants for accepting for publication.

### ***Declaration of Competing Interests***

The author(s) declared no potential conflicts of interest with respect to the research, authorship, and/or publication of this article.

**Authors Contributions:** Dr Sourabh and Dr Mounika collected the data, designed and prepared the manuscript, Dr Khabeer and Dr Shoban did critical review of the final manuscript

### ***Funding***

The author(s) received no financial support for the research, authorship, and/or publication of this article

### ***Consent***

Informed written consent was obtained from the patient.

"All authors declare that 'written informed consent was obtained from the patient for publication of this case report and accompanying images. A copy of the written consent is available for review by the Editorial office/Chief Editor/Editorial Board members of this journal."

**ORCID id** - Mounika Reddy Y <https://orcid.org/0000-0002-6987-4924>

## References

1. Watkinson, J.C., Clarke, R.W., Jones, T.M., Paleri, V., White, N., & Woolford, T. (Eds.). (2018). Head & Neck Surgery Plastic Surgery: Volume 3: Head and Neck Surgery, Plastic Surgery 2018.(8th ed.).<https://doi.org/10.1201/9780203731000Scott>
2. Ravitch, Mark M. Cystic hygroma. *Pediatric surgery*.1986;1:536
3. Grasso DL, Pelizzo G, Zocconi E, Schleef J Lymphangiomas of the head and neck in children. *Acta Otorhinolaryngol Ital*. 2008; 28(1):17-20.
4. Teramoto, K, & Suzumura, Y. Mediastinal cavernous lymphangioma in an adult. *General thoracic and cardiovascular surgery*. 2008;56(2):88-90.
5. Prasad GR, Nori M, Naseeruddin MD Rao JVS, Quadri SS. Giant Thoracocervical Lymphangioma with Multivisceral Involvement: A Different Concept. *International journal of phonosurgery and laryngology*. 2014;4(2): 63-66.
6. Ozel A, Uysal E, Dokucu AI, Erturk SM, Basak M, Cantisani V. US, CT and MRI findings in a case of diffuse lymphangiomatosis and cystic hygroma. *J Ultrasound* 2008;11(1):22-25. doi:10.1016/j.jus.2007.12.002