

Case study

BILATERAL VARICOCELE CO-EXISTING WITH SUB-ACUTE APPENDICITIS : A CASE REPORT

ABSTRACT

Introduction

The diagnosis of bilateral varicocele and sub-acute appendicitis co-existing in the same patient is rare and we report the management of a patient who presented to Lily Hospitals Limited, Warri, Delta State, Nigeria with both recurrent right iliac fossa pain and scrotal pain.

Case presentation

A 27 year old male who presented with recurrent scrotal pain of 3 years duration and recurrent right iliac fossa pain of 2 years duration. Following evaluation, the diagnosis of bilateral varicocele and sub-acute appendicitis was made and he subsequently had open bilateral inguinal varicocelectomy and open appendicectomy at the same sitting under regional anaesthesia. He had uneventful post-operative recovery and was subsequently discharged.

Conclusion

A thorough evaluation of patients presenting with scrotal and right iliac fossa pains is invaluable to avoid missing the diagnosis of both bilateral varicocele and appendicitis when they co-exist in the same patient.

Keywords: Varicocele, appendicitis, pain

INTRODUCTION

The presentation of scrotal pain and right iliac fossa pain is uncommon with the report of such rare in the literature. Commonly seen are patients presenting with either scrotal pains or right iliac fossa pains resulting from either varicocele or appendicitis respectively.

Varicocele is the dilation of veins of the pampiniform plexus draining the testis. Bilateral varicocele is the dilation of the pampiniform plexus draining both testis. Appendicitis is the inflammation of the appendix, symptoms include right lower abdominal pain, nausea, vomiting and decreased appetite¹. Sub-acute appendicitis is part of the non-acute variants of appendicitis, others include recurrent and chronic appendicitis, they are rarely diagnosed and remain subjects of case reports.²

CASE PRESENTATION

A 27 year old male who presented to the Urology Clinic, Lily Hospitals Limited, Warri, Delta State, Nigeria with complaints of recurrent scrotal pains of 3 years duration and right iliac fossa pain of 2 years duration. Scrotal pain was insidious in onset, dull aching, does not radiate to any part of the body, not worse at any time of the day, no known aggravating or relieving factors, the scrotal pain was not associated with scrotal swelling, lower urinary tract symptoms, urethral discharge or haematuria. There was no associated history of infertility. The right iliac fossa pain was insidious in onset, colicky, does not radiate to any part of the body, aggravated by strenuous activities and cough, no known relieving factors, not associated with fever, anorexia, nausea, vomiting or abdominal distension. There was no past history of surgery and he was not allergic to any medications. Patient has been on analgesics and antibiotics with no improvement which led to his presentation to our facility for expert management.

Physical examination revealed right iliac fossa tenderness with positive Rovsing's sign and bilateral grade 2 varicoceles.

Investigations requested were- Scrotal Doppler ultrasound scan that revealed bilateral dilated pampiniform plexus of veins above 3 millimeters in keeping with varicoceles (fig 1) Abdominal ultrasound scan that revealed sub-acute appendicitis (fig 2) Urinalysis that was normal with normal Full blood count, Serum electrolytes, urea and creatinine. The diagnosis of bilateral varicocele with subacute appendicitis was made.

He subsequently had bilateral Open Inguinal Varicocelectomy and Open Appendicectomy done by the Consultant Urologist and General Surgeon respectively at the same sitting under regional anaesthesia.

Intraoperative findings were bilateral dilated pampiniform plexus of veins and retroileal inflamed appendix measuring about 12 centimeters (fig 3) He had uneventful post-operative recovery and was discharged home 3 days after surgery. He is currently on follow up visit with complete resolution of both right iliac fossa pain and scrotal pain.

After surgery, histopathology report of the resected appendix revealed lymphoid follicular hyperplasia with no evidence of malignancy while that of the resected varicocele segment revealed features consistent with varicocele

DISCUSSION

Appendicitis with varicocele reports in literature are few. Varicoceles may begin with the onset of puberty at around the age of 15 years³, most are left sided and left sided predominance is explained by turbulent venous flow related to the right angle insertion of the left testicular vein into the left renal vein⁴. Varicocele is a physical abnormality present in 11.7% of men with normal semen analysis and 25.4% of men with abnormal semen⁵. Varicocele can lead to male infertility, scrotal swelling or pain and progressive ipsilateral testicular atrophy as complications. Our index patient presented with the complication of scrotal pain and had treatment for that. The exact relationship between reduced male fertility and varicocele is unknown but a meta-analysis showed that semen improvement is usually observed after surgical correction⁶. Varicoceles are graded according to the Dublin grading system from grades 1 to 3⁷. Our patient had bilateral grade 2 varicoceles. The surgical correction of varicocele was

first described by Tulloch in 1952⁸.The surgical treatment for varicocele can be done open or laparoscopically and our index patient had an open surgical treatment.

Appendicitis is the most common acute surgical condition of the abdomen⁹, with a lifetime occurrence of 7%¹⁰. The diagnosis of appendicitis is mainly clinical but when unclear, close observation, medical imaging and laboratory tests can be helpful¹¹.The two most common imaging modalities used for the diagnosis of appendicitis are abdominal ultrasound scan and abdominal computerized tomography scan¹¹.Our index patient had abdominal ultrasound scan during the initial evaluation although the diagnosis was clear earlier from the clinical evaluation. In 1889, Mc Burney published a series of reports on appendicitis and the therapeutic management and since then, appendicectomy has been the standard treatment for uncomplicated appendicitis¹². Appendicectomy can be done open or laparoscopically and our index patient had open appendicectomy.

CONCLUSION

The diagnosis of both bilateral varicoceles and appendicitis in the same patient occurring around the same time is rare. Thorough clinical evaluation is thus pertinent during evaluation of patients presenting with right iliac fossa pain and scrotal pain to avoid missing such pathologies when they co-exist in the same patient.

DECLARATIONS

Ethical approval

Not applicable

Consent to participate

A written consent was signed by the patient

Consent for publication

Not applicable

Availability of data and material

Not applicable

REFERENCES

1. Graffeo CS, Counselman EL. Appendicitis. *Emergency Medicine Clinics of North America* 1996; 14: 653-71
2. Berk DR, Sylvester KG. Subacute appendicitis. *Clin.Pediatr.(Phila.)* 2005 ; 44: 363-365.
3. Steeno O, Knops J, Declerck L, Adimoelja A, Vande Voorde H. Prevention of Fertility Disorders by Detection and Treatment of Varicoceles at School and College Age. *Andrologia* 1976; 8: 47-53
4. Sabanegh E, Agarwal A. Male Infertility. In: Wein AJ, Kavoussi LR, Novick AC, Partin AW, eds. *Campbell-Walsh Urology*. 10th ed. Philadelphia: Saunders, Elsevier Inc; 2012. Pp 636-637
5. Said S, Aribarg A, Virutamsen P, Chutivongse S, Koetsawang S, Meherjee P, et al. The Influence of Varicoceles on Parameters of Fertility in a Large Group of Men Presenting to Infertility Clinics. *Fertility and sterility* 1992; 57: 1289-93
6. Agarwal A, Deepinder F, Cocuzza M, Agarwal R, Short R, Sabanegh E, et al. Efficacy of Varicocelectomy in Improving Semen Parameters: New Meta-analytical Approach. *Urology* 2007; 70: 532-38
7. Hirsh AV, Cameron KM, Tyler JP, Simpson J, Pryor JP. The Doppler Assessment of Varicoceles and Internal Spermatic Veins Reflux in Infertile Men. *British Journal of Urology* 1980; 52: 50-56
8. Tulloch WS. A Consideration of Sterility Factors in the Light of Subsequent Pregnancies.11.Sub fertility in the male. *Edinburgh Med J* 1952; 59: 29-34
9. Liu CD, Mc Fadden DW. Acute Abdomen and Appendix. In: Greenfield LJ, Mulholland MW, Oldham KT, Zelenock GB, Lillemoe KD, eds. *Essentials of Surgery: Scientific Principles and Practice*. 2nd ed. Philadelphia: Lippincott-Raven, 1997. Pp 1246-61
10. Hardin M. Acute Appendicitis: Review and Update. *Am Fam Physician* 1999; 60:2027-34
11. Paulson EK, Kalady MF, Pappas TN. Clinical Practice. Suspected Appendicitis. *New England Journal of Medicine* 2003; 348: 236-42
12. Mc Burney C. Experiences with Early Operative Interference in Cases of Disease of the Vermiform Appendix. *NY Med J* 1889; 50:1676-84

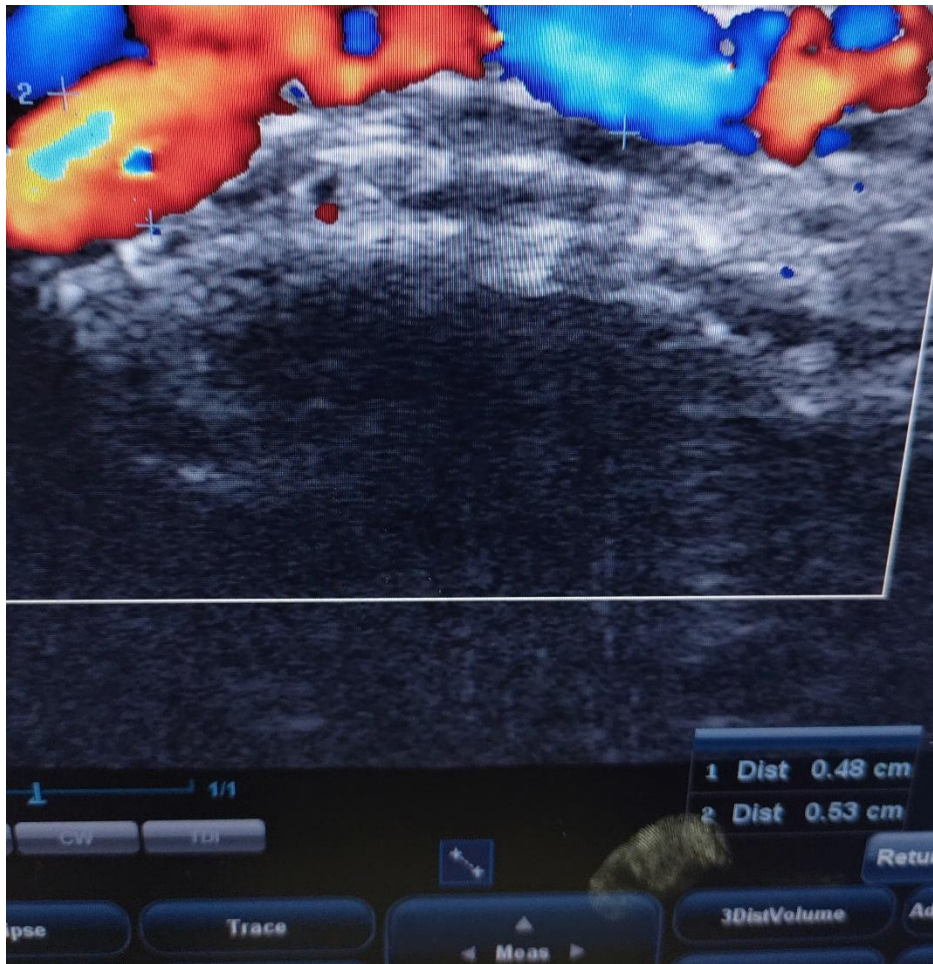


Fig 1: Scrotal Doppler Ultrasound scan revealing dilated pampiniform plexus of veins

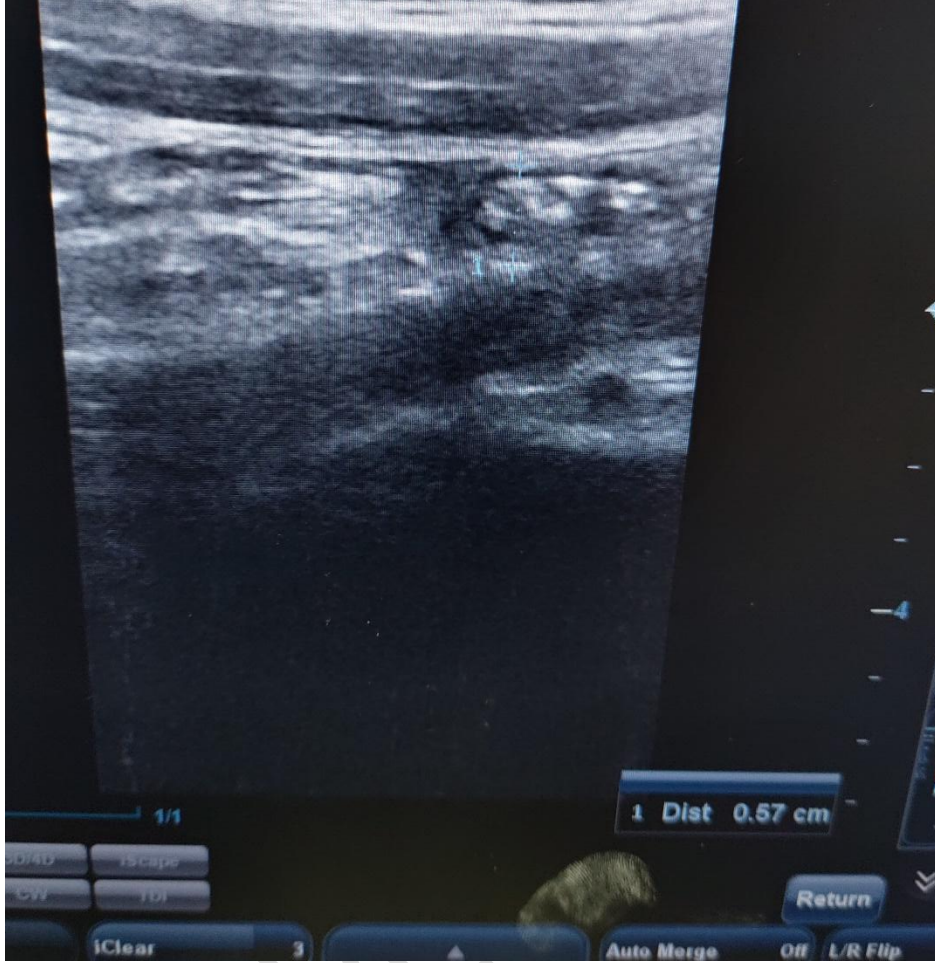

Fig 2: abdominal ultrasound scan revealing inflamed appendix

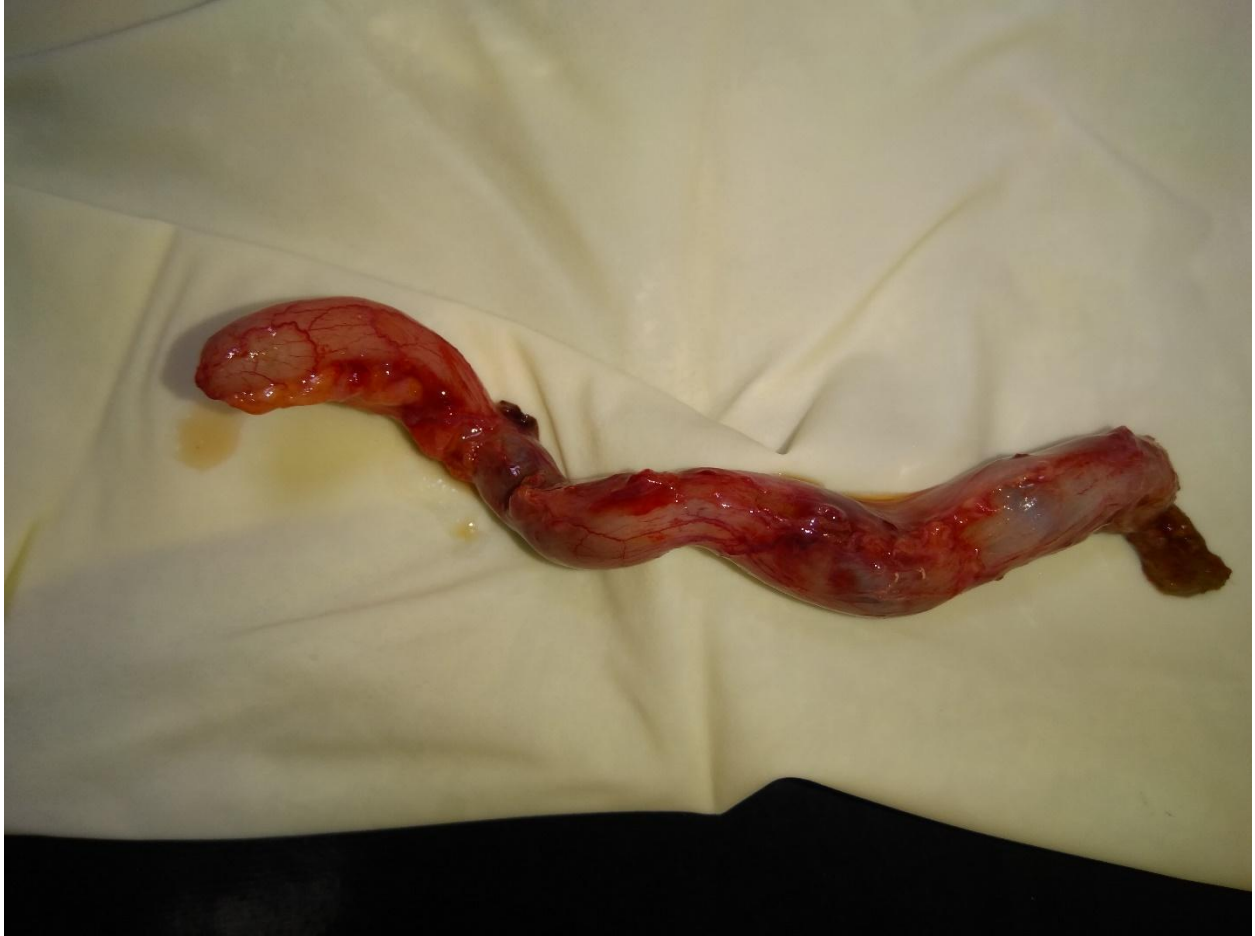

Fig 3: Resected Appendix Specimen

UNDER P