

Case study

Chylous ascites in small bowel obstruction

Running title: Chylous ascites

Abstract

Chylous Ascites (CA) is an uncommon finding of lymphatic fluid throughout the peritoneal cavity. It most commonly occurs in adults due to malignancy or liver cirrhosis and there is limited evidence on its presence in small bowel obstruction (SBO). We present a case of a 53 year old man who presents with a SBO in a virgin abdomen and CA intraoperatively. He had viable bowel with no enterectomy required and had an uneventful recovery. This report discusses the relevance of CA in SBO and how it can be a reassuring finding in this context.

Keywords

Chylous ascites, small bowel obstruction

Introduction

Chylous ascites (CA) is a white milky fluid found in the peritoneal cavity secondary to extravasation of lymphatic structures. It is a rare occurrence with an incidence of 1 in 20 000 operations performed [1]. There are various causes of CA with the most common in adults being malignancy usually lymphoma or ascites from liver cirrhosis. Other causes include fistulas, trauma, surgery, congenital abnormalities, radiation as well as idiopathic causes [2-9]. The finding of CA can be particularly alarming as it is associated with high mortality rates of 50-70% being reported in adults. The prognosis and treatment however is **dependent** on aetiology [1,2].

Small bowel obstruction (SBO) is most commonly caused by adhesions arising in about 4.6% of patients who have had prior abdominal surgery [10]. The presence of SBO in an unoperated or “virgin” abdomen can raise the suspicion of malignancy however in majority of cases the aetiology is benign. The incidence of CA in SBO with a virgin abdomen is a very rare occurrence, with only one similar case reported in the literature [6].

Case report

A 53 year old man presented himself with cramping epigastric pain beginning 12 hours prior with nausea and vomiting . He had opened his bowels the day prior and was otherwise a fit and healthy man with no past medical history or regular medications. His blood test results were unremarkable with normal inflammatory markers and electrolytes. A computed tomography (CT) scan was performed in portal venous phase which showed a closed loop small bowel obstruction involving the proximal jejunal loops. There was also a small amount of free fluid in the pelvis but no features suggestive of bowel perforation (Figure 1 and 2).

He was admitted to the Acute Surgical Unit and taken to theatre later that evening for an emergency diagnostic laparoscopy which was converted to a laparotomy. He was found to have omental adhesions to the left lateral abdominal wall and a long segment of small bowel adjacent to the descending colon contained within the omental adhesion. This segment of bowel was dilated and had the appearance of lymphatic congestion with pale discolouration of the associated mesentery (Figure 3). There was also white coloured free fluid which had the appearance of chyle and

was sent off for triglycerides which returned as 600mg/dL. The fluid was also sent off for culture which revealed no growth. The omental adhesions were taken down and the small bowel run which was all viable and no enterectomy was required.

The patient recovered uneventfully and was discharged on day 3 post operatively. He had one presentation to the emergency department on day 6 post operatively for abdominal pain which resolved after opening bowels. A follow up 3 months post operatively revealed no pathologies.

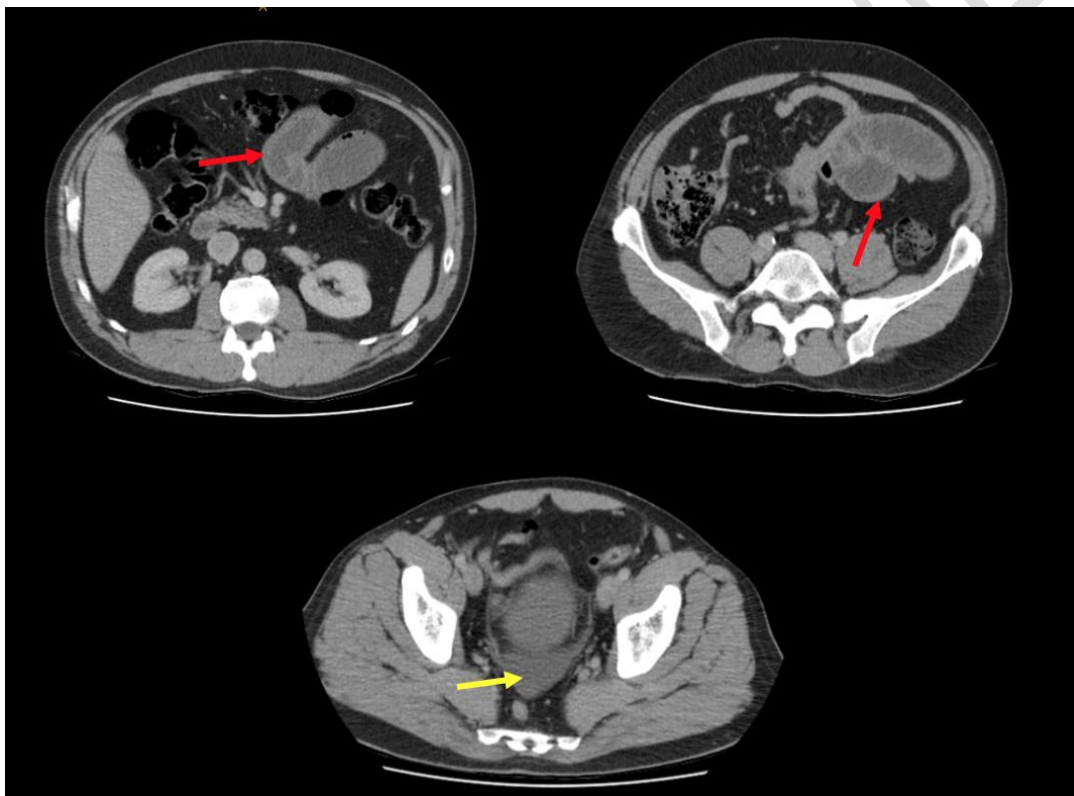


Figure 1: Axial computed tomography images on presentation with red arrows pointing to bowel obstruction and yellow arrow pointing to free fluid in pelvis

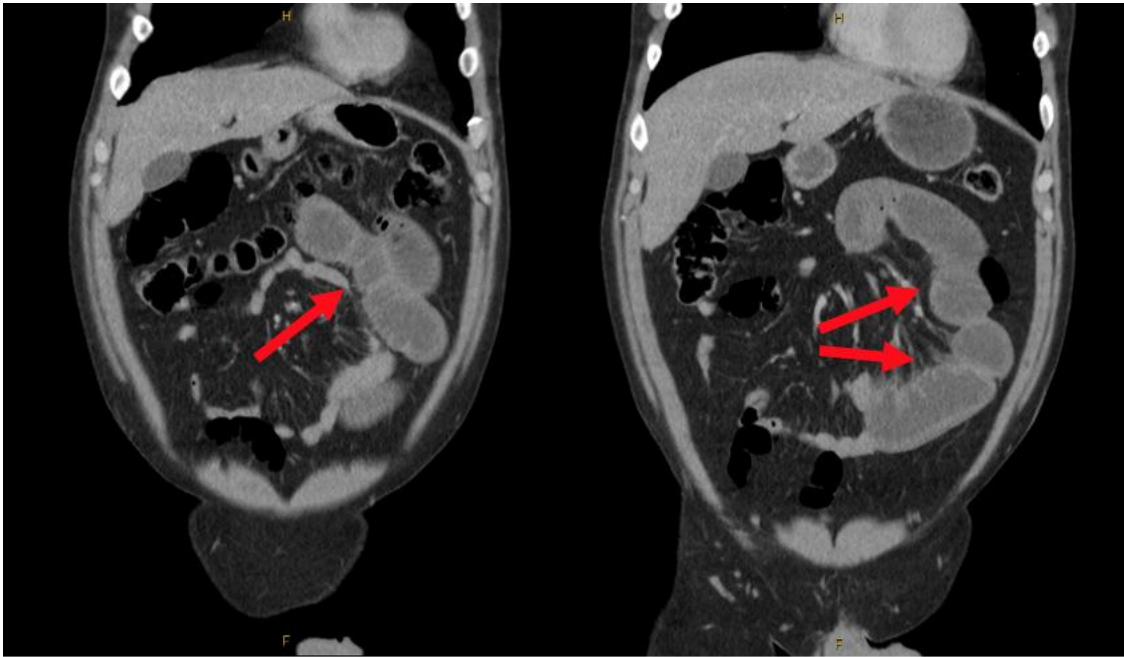


Figure 2: Coronal computed tomography images on presentation with red arrows pointing to bowel obstruction

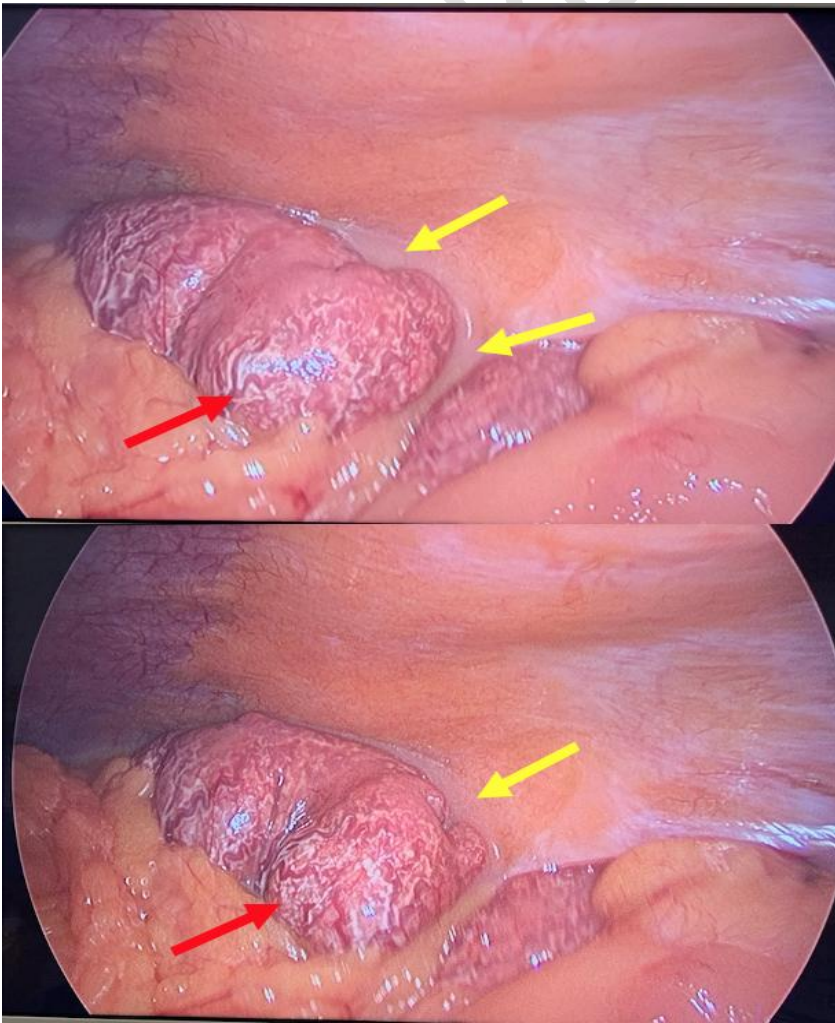


Figure 3: Intra-operative images of small bowel with congested lymphatics (red arrow) and chylous ascites (yellow arrow)

Discussion

Diagnosis of true CA requires peritoneal fluids with a triglyceride level of >110 mg/dl. The main differential diagnoses of CA are pseudo-chylous ascites or chyliform ascites. Pseudo-chylous ascites occur when peritoneal fluid contains pus whereas chyliform ascites are as a result of lecithin containing fluid from the degradation of cells from malignancy or infection [1,2]. In our patient, the level of triglycerides in peritoneal fluid was 600mg/dl which confirmed the diagnosis of true CA.

There are three main causative mechanisms of CA in adults. Lymphatic obstruction as a result of malignancy leading to fluid leakage, or damage of the lymphatic structures due to local tumour invasion. Fistula formation between lymphatics, mesentery or peritoneum as a result of surgery, trauma or adhesions and retroperitoneal lymphatic duct leakage from congenital disorders are representing rare causes of CA [1,2]. In this case, lymphatic obstruction due to the presence of mesenteric compression from an internal hernia and SBO was the cause.

Evidence suggests that presence of CA in SBO from internal hernias or midgut volvulus may be a reassuring sign with favourable outcomes [3-5,7]. The incidence of CA in SBO is difficult to characterise due to its rare occurrence however the majority of reports which detail such cases do not require enterectomy and have uneventful postoperative courses [3-5,7]. Some studies hypothesise that the presence of CA may be an indicator of bowel viability as lymphatics function under a lower pressure and are the first to become occluded in SBO whereas the arterial supply remains patent and is required for lymph production and CA accumulation [3,5]. Our case was also consistent with this hypothesis as all bowel was viable with no enterectomy required with an uncomplicated recovery.

CA in SBO is reported in patients who have undergone previous abdominal surgery with only one case of CA in a virgin abdomen reported [6]. In this case the patient was found to have multiple omental adhesions which resulted in an internal hernia. We hypothesise the cause of these adhesions to be a previous episode of diverticulitis which remained untreated leading to inflammatory adhesions.

Conclusion

The presence of CA is an uncommon finding particularly in SBO in a patient with a virgin abdomen. The identification of CA is important as it can be a reassuring sign, indicating patency of arteriovenous supply of the bowel. Further large cohort studies are required to understand the relationship between CA and SBO.

Disclaimer regarding Consent and Ethical Approval:

As per university standard guideline, participant consent and ethical approval have been collected and preserved by the authors

References

1. Aalami OO, Allen DB, Organ CH Jr. Chylous ascites: a collective review. *Surgery*. 2000; 128:761–778
2. Bhardwaj R, Vaziri H, Gautam A, Ballesteros E, Karimeddini D, Wu GY. Chylous ascites: a review of pathogenesis, diagnosis and treatment. *J Clin Transl Hepatol*. 2018; 6:105–113
3. Akama Y, Shimizu T, Fujita I, et al. Chylous ascites associated with intestinal obstruction from volvulus due to Petersen's hernia: report of a case. *J Surg Case Rep*. 2016; 2:77. DOI 10.1186/s40792-016-0207-9
4. Dimitrios A, Carr RA, Painter R, et al. Chylous ascites in the setting of internal hernia: a reassuring sign. *Surg Endos*. 2021; <https://doi.org/10.1007/s00464-021-08545-4>
5. Koh YX, Chng JK, Tan HC, Chung AYP. Intestinal torsion causing Chylous ascites: a rare occurrence. *Singapore Med J*. 2013; 54(4); e88-e90. doi: 10.11622/smedj.2013089
6. Leaning M. Chylous ascites as a sequelae of primary small bowel volvulus in a virgin abdomen. *J Surg Case Rep*. 2021; 5: 1-3. doi: 10.1093/jscr/rjab176
7. Morosin T, Robles MSD. Chylous ascites as a marker for intestinal viability in a small bowel obstruction: a case report. *J Surg Case Rep*. 2021; 9: 1-3. <https://doi.org/10.1093/jscr/rjab411>
8. Murugan K, Spence RAJ. Chylous peritonitis with small bowel obstruction. *Ulster Med J*. 2008;77:132–3.
9. Najjari K, Ghafouri AH, Mahmoudabadi HZ. Chyloperitoneum due to small bowel obstruction following laparoscopic Roux-en-Y Gastric Bypass: a case report and review of literature. *Obes Surg*. 2021; 31:1855-1857.