

## Case study

### Multiple Ulnar artery aneurysms of hand: A Case report

#### Abstract:

Ulnar artery aneurysm is a rare entity in the upper extremity. Most common causes for aneurysm of ulnar artery are trauma, infection, immunologic reasons, embolism, congenital connective tissue disorders and atherosclerosis. Since the ulnar artery is entangled with the nerve in the hand region, its diagnosis and treatment is crucial for hand function. There is a high chance for ischemia in the ulnar artery territory due to progressive thrombosis or embolism from the aneurysmal site. We present a case of ulnar artery aneurysm of left-hand palmar aspect which was effectively managed by surgical resection and anastomosis.

#### Key words:

Ulnar artery Aneurysm, Hand, Micro vascular anastomosis

#### Introduction:

Ulnar artery aneurysm in the palm is a rare entity<sup>1</sup>. Multiple arterial aneurysms in the distal segment of the ulnar artery at palmar arch level is less frequent<sup>2</sup>. Trauma, arteriosclerosis, congenital disorders are considered to be primary reasons for multiple aneurysms. Proper early diagnosis and treatment is necessary to prevent arterial complications like thrombosis and embolism in the territory of ulnar artery. Patients may develop symptoms related to compression of ulnar nerve as the artery traverses close to the nerve in the palm. We present a case of aneurysm of ulnar artery involving left hand palmar aspect which was effectively managed by surgical resection and anastomosis.

#### Case report:

A 40-year male patient presented to the outpatient department with a pulsatile mass in two regions of the left palm. Patient noticed the swelling for a duration of 5 years gradually increasing in size with on and off radiating pain to the ulnar two fingers. On physical examination, there was two pulsatile swelling in the palm, one at the flexor zone 3 level measuring approximately 3.5cm x2.5 cm and one at the flexor zone 4 level measuring approximately 3cm x 2cm with intact ulnar nerve sensation and motor function [Figure 1]. On Allen's test, when the pressure is applied on the ulnar artery, the swelling disappeared but failed to fill even on releasing the pressure on radial artery. CT Angiogram showed two aneurysms in the palm in ulnar artery territory with incomplete palmar arch [Figure 2]. Explaining the complication of thrombosis, embolism and compression neuropathy, the patient was taken up for surgical exploration. The surgery was done under axillary block with tourniquet control. Distal forearm volar veins were marked before application of tourniquet to anticipate the requirement of vein graft for ulnar artery reconstruction [Figure 3]. Careful dissection was performed under microscope to avoid injury to ulnar nerve. Two aneurysms arising from the ulnar artery was separated from the adjacent structures [Figure 4]. One of the aneurysms was ligated and removed. The smaller proximal aneurysm was involving a segment of ulnar artery and so, the resection of involved segment with end-to-end ulnar artery anastomosis was done to secure the

vascularity of the hand distal to aneurysm [Figure 5]. The specimen was sent to Histopathological examination [Figure 6]. Histopathology report showed thick-walled cyst with dilated vascular channel containing blood clots consistent with true aneurysm. Post procedure hand perfusion was confirmed by indocyanine dye injection study. Post operative period was uneventful with no evidence of neuro vascular deficit in ulnar territory [Figure 7].

#### **Discussion:**

Aneurysm of ulnar artery at multiple levels in palm are very rare entity<sup>1</sup>. Conventionally, the superficial palmar branch of the radial artery and the superficial palmar branch of the ulnar artery forms the superficial palmar arch. But the ulnar artery contributes as the main feeding vessel<sup>3</sup>. In our particular case scenario, we found during clinical examination that the filling of the aneurysm was completely by ulnar artery with incomplete palmar arch. Hence, the surgeon needs to think about reconstruction of the ulnar artery with vein graft prior to exploration. Veins of proper size matching the ulnar artery at palm level should be marked well before the exploration to avoid intraoperative difficulty. Planning for restoration of ulnar artery territory vascularity, either by means of direct end to end anastomosis or with interposition reverse vein graft is a must if there is clinical evidence of incomplete palmar arch. Multiple Ulnar artery aneurysm and its surgical treatment is reported rare in the literature<sup>4-8</sup>. The blood supply of the hand is primarily derived from the superficial and the deep palmar arches. The superficial palmar arch is formed mainly by the ulnar artery. Ulnar artery enters the palm with the ulnar nerve in the Guyon's canal. The superficial palmar arches are formed by the ulnar artery which completed by the superficial palmar branch of the radial artery and sometimes added by the arteria radialis indicis, a branch of arteria princeps pollicis or the median artery<sup>9,10</sup>. Complete knowledge of the arterial supply of the hand is necessary to carrying out procedures as there are chances of variations from normal palmar arch.<sup>11</sup> The superficial palmar arch has been broadly divided into two categories: complete and incomplete. The difference is classified according to the presence or absence of an arch formed either by ulnar and the radial vessels. A plan to understand the arch pattern is necessary to carry out a safe hand surgery. In these types of cases, even though we did not find any relation to trauma, infection, immunologic reason, or connective tissue disorders, a possibility of these aetiology should always be considered. Thorough clinical examination to know the palmar arch continuity and nerve examination will certainly avoid neurovascular complication in multiple aneurysms of ulnar artery territory.

#### **Conclusion:**

Multiple ulnar aneurysms of palm are rare disorders and can be treated surgically. In our case, because of the multiple size of the aneurysm detected in the ulnar artery, one was excised by ligation and the other was salvaged by segmental resection and end-by-end anastomosis of the ulnar artery. Careful planning and proper dissection are key to prevent neurovascular complication in hand.

#### **Disclaimer regarding Consent and Ethical Approval:**

As per university standard guideline, participant consent and ethical approval have been collected and preserved by the authors

#### **References:**

1. Conkbayir C, Emiroğlu O, Birtan H, Cerit L. Ulnar artery aneurysm—A rare cause of mass on wrist. *Cor et Vasa*. 2017 Oct 1;59(5):e496-8.
2. G.R. Silcott, V.L. Polich, Palmar arch arterial reconstruction for the salvage of ischemic fingers, *American Journal of Surgery* 142 (1981) 219–221.
3. Doscher W, Viswanathan B, Stein T, Margolis I. Hemodynamic assessment of the circulation in 200 normal hands. *Ann Surg*. 1983;198:776.
4. F. De Santis, G. Martini, G. Mani, et al., Forearm and hand arteries' aneurysms – case report of bilateral true ulnar artery aneurysm in the hypothenar eminence and review of literature, *Vascular* 21 (2013) 169–176.
5. Kumar Y, Hooda K, Lo L, Karol I. Ulnar artery aneurysm and hypothenar hammer syndrome. *Case Reports*. 2015 Nov 24;2015:bcr2015211444.
6. Meals CG, Carey GB, Higgins JP, Chang B. Ulnar artery aneurysm in a 6-month-old: a case report. *Hand ( N Y)* 2017;12:118-20.
7. Stalder MW, Sanders C, Lago M, Hilaire HS. Multilocular true ulnar artery aneurysm in a pediatric patient. *Plastic and Reconstructive Surgery Global Open*. 2016 Jan;4(1).
8. Kishi Y. A case of congenital aneurysm of the ulnar artery of the palm. *Plast Aesthet Res* 2020;7:3. <http://dx.doi.org/10.20517/2347-9264.2019.50>
9. Buch C, Devora CM, Johnson LY, Rahimi OB, Kar R. Incomplete superficial palmar arch and bilateral persistent median artery. *International journal of surgery case reports*. 2019 Jan 1;58:205-7.
10. H. Kaplanoglu, O. Beton, Evaluation of anatomy and variations of superficial palmar arch and upper extremity arteries with CT angiography, *Surg. Radiol.Anat.* 39 (2017) 419–426.
11. Arquez HF, Hurtado DK. Variations of the superficial palmar arches: A cadaveric study. *J Chem Pharmaceut Res*. 2016;8(5):6-14.

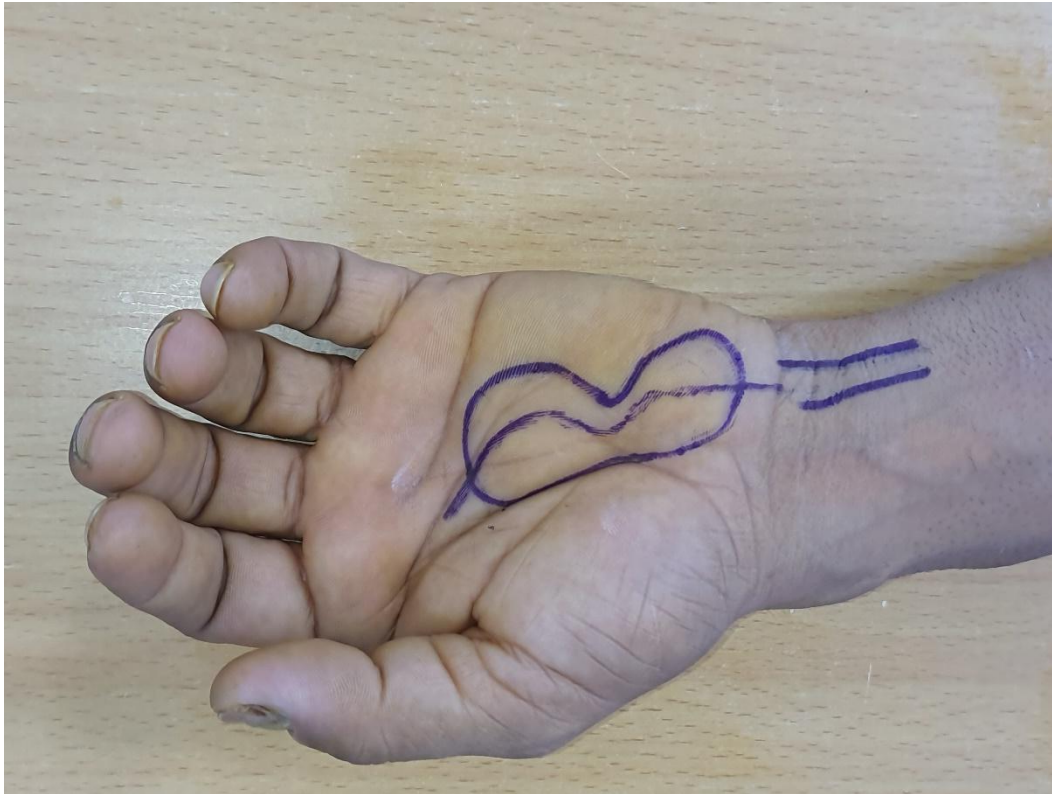


Figure 1: Two Pulsatile swelling in palm – Ulnar artery territory

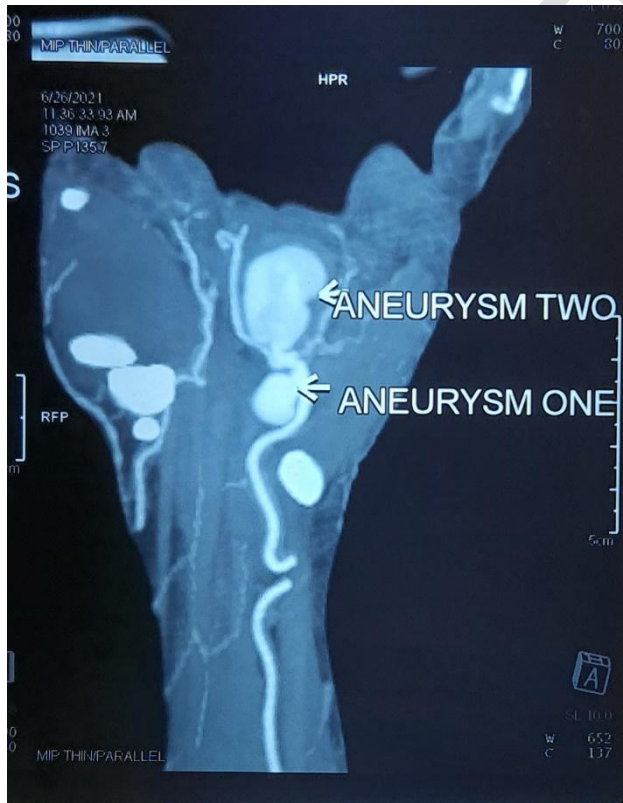


Figure 2: CT angiogram of left hand showing multiple aneurysms of ulnar artery with incomplete palmar arch

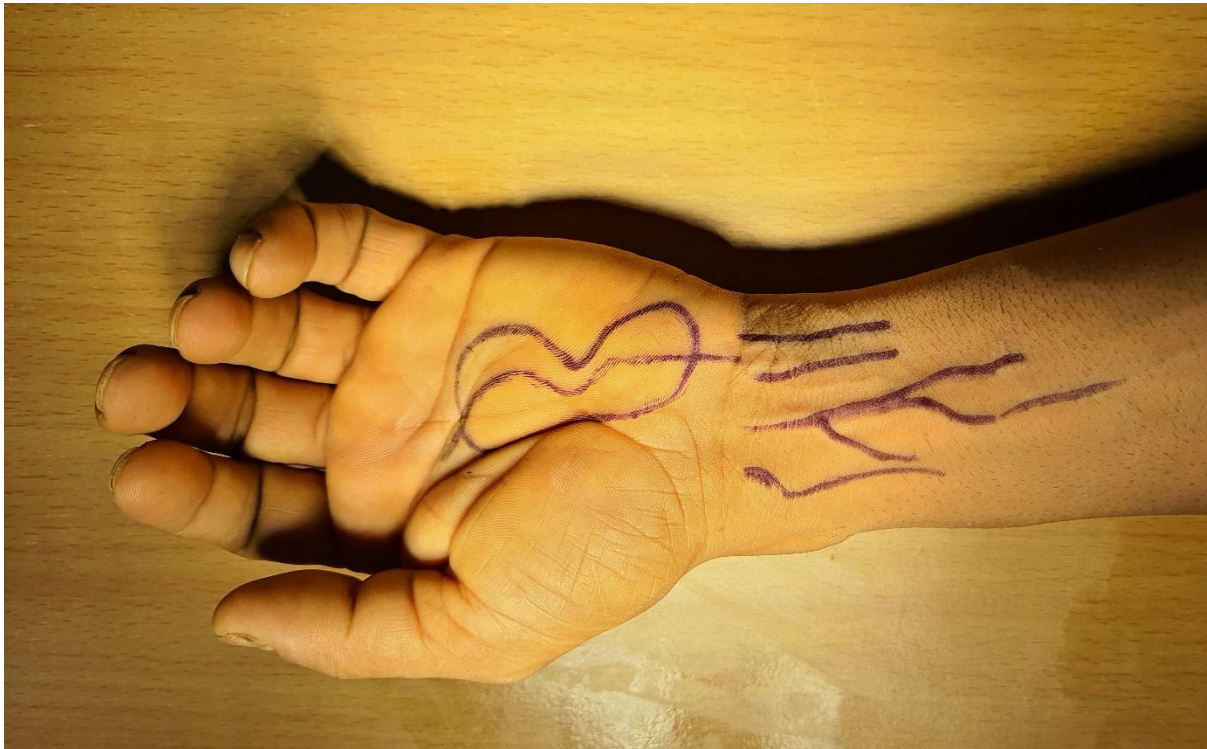

Figure 3: Intraoperative marking of distal forearm volar veins for ulnar artery reconstruction

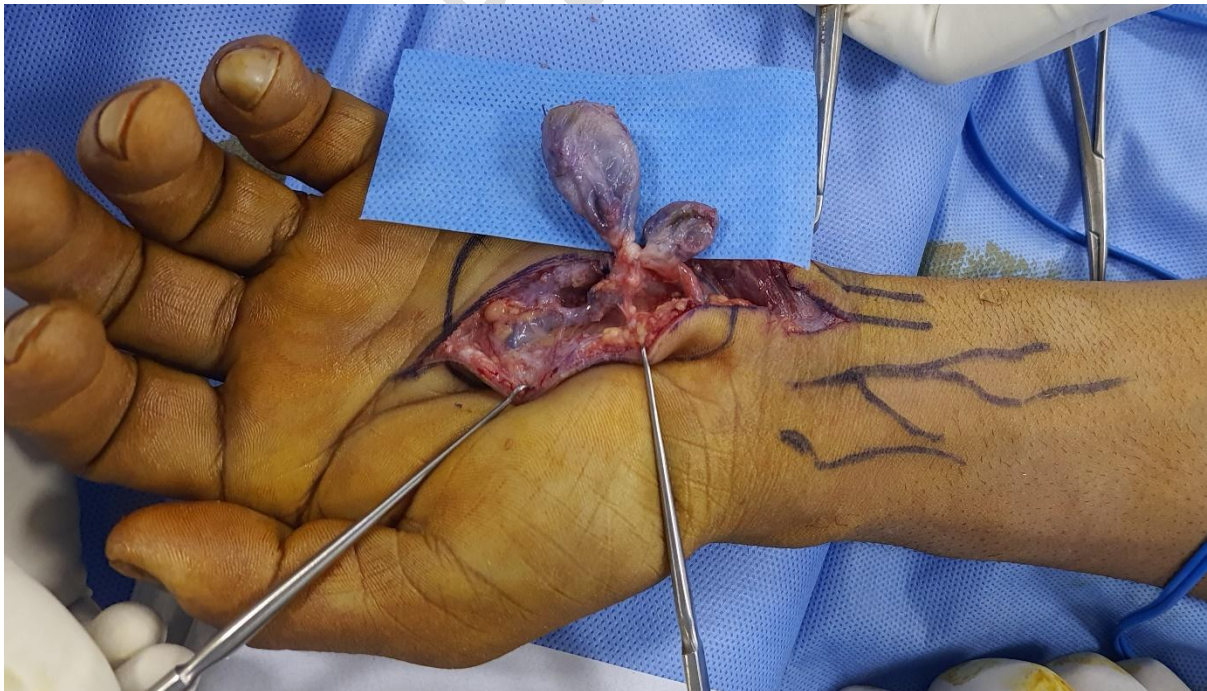


Figure 4: Intraoperative finding with 2 aneurysms ulnar artery palm level

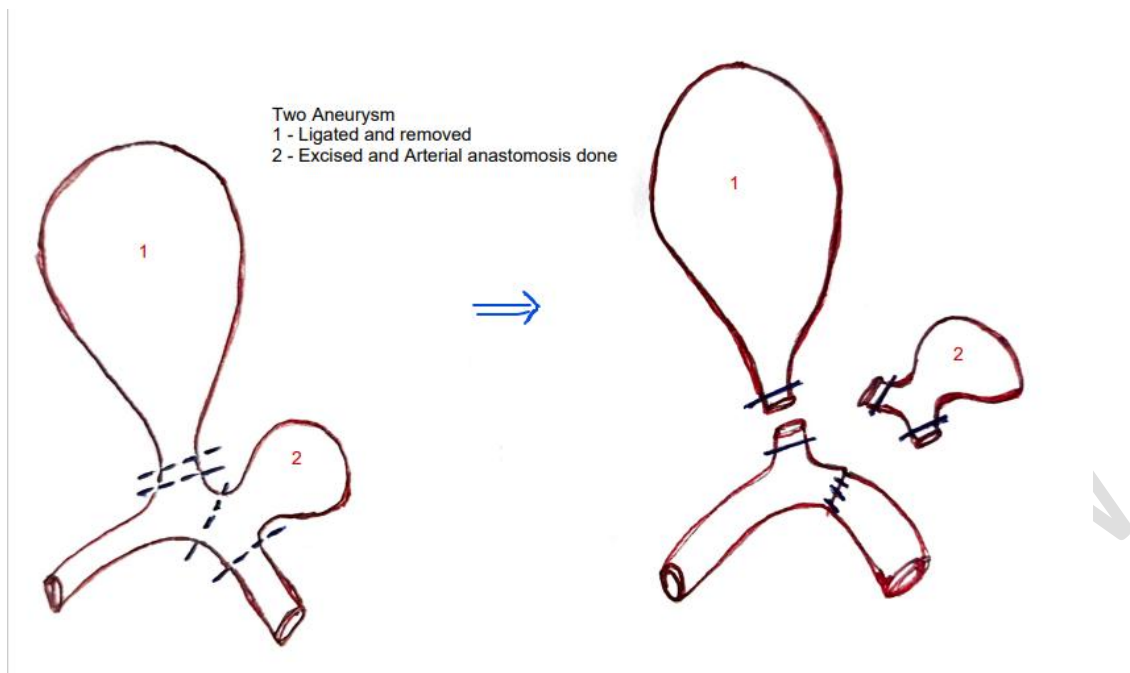


Figure 5: Resection of distal aneurysm and resection & anastomosis of proximal aneurysm

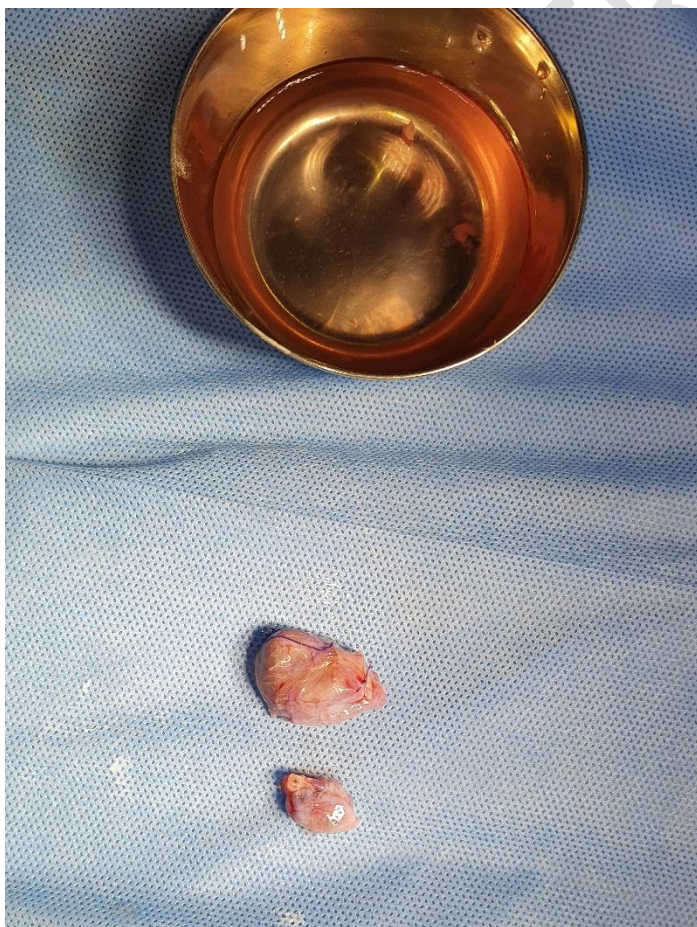
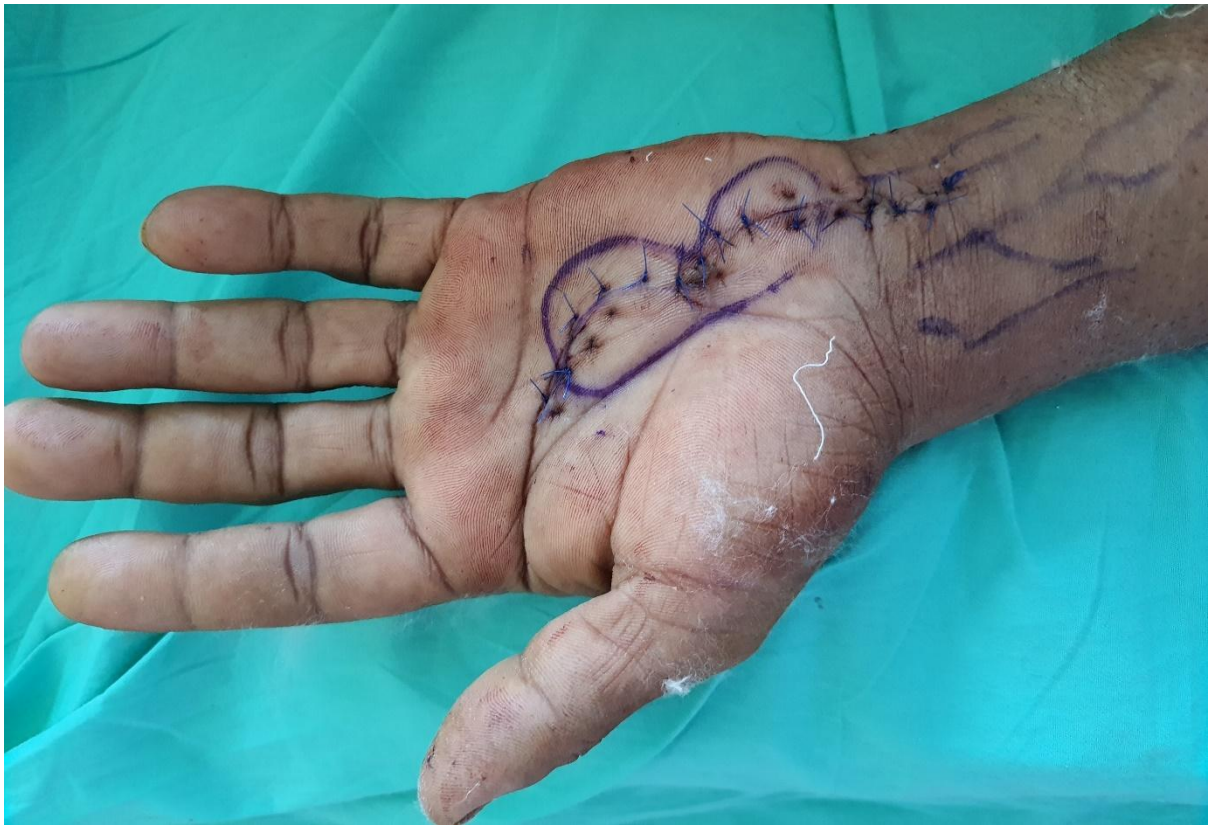
Figure 6: Aneurysm excised specimen sent for histopathological analysis



**Figure 7: Late postoperative picture of Hand**

UNDER PEEER