

Case report

PARENCHYMA SPARING LIVER RESECTION [PSLR] AS A VIABLE OPTION FOR MULTIFOCAL COLORECTAL LIVER METASTASES – A CASE REPORT AND REVIEW OF LITERATURE

Abstract

Colorectal liver metastases [CRLM] is the usual natural course of disease in about one third to half of the colorectal cancer patients. The management of CRLM has come across various changes and modifications in the last two decades. **Surgical resection has always been the best treatment option providing a good survival benefit. However, this is challenged by the need to preserve adequate liver remnant, preventing post- hepatectomy liver failure, oncological clearance and leaving a good quality remnant to favour post operative liver hypertrophy.** Here we present a case of CRLM in a 63-year-old gentleman, that was multifocal involving both the lobes of liver and how parenchyma sparing liver resection using a conglomeration of multiple non-anatomical resections proved to be an effective option under these challenging circumstances.

Keywords: Colorectal liver metastases, post- hepatectomy liver failure, non-anatomical resections, metastatic lesions

Introduction

Liver is the most common site for metastases owing to its rich, dual blood supply. Almost 50% of liver metastases are from gastrointestinal malignancies and Colorectal liver metastases [CRLM] is the most common form of metastatic lesions to the liver. This can be either at the time of initial diagnosis or within 6 months of **diagnosis[synchronous] or later [metachronous].** In nearly 35 % of the cases, liver is the only site for metastases. **Colorectal liver metastases were once thought of as systemic disease that involves other organs and systems, until recently when local liver therapy in the form of liver resection has been reported** to results in 5-year survival of 27–39%. [1, 2]. Here we report a case of colorectal liver metastases that was multifocal and how it was successfully managed with surgical resection.

Case Report

Our patient is a 63-year-old gentleman, with no known comorbidities who was initially evaluated for complaints of giddiness with loss of consciousness. On evaluation he had anaemia, serum CEA of 3.4 ng/ml and was suggested endoscopic examinations. His colonoscopy revealed a circumferential proliferative growth in the ascending colon suspicious of malignancy. Colonoscopy biopsy was suggestive of adenocarcinoma. Contrast enhanced Computed tomography of his abdomen and chest revealed no metastatic lesions and he underwent right hemicolectomy with ileocolic side to side anastomosis. Intraoperatively he had an 8x8x7 cm irregular mass at the hepatic flexure and distal ascending colon, that was adherent to right Gerota fascia and the lateral wall of second part of duodenum. No evidence of liver surface lesions nor peritoneal or omental deposits. Post operative recovery was uneventful. His histopathological examination revealed an grade III, poorly differentiated adenocarcinoma with all the margins being free of tumour. Totally 19 regional lymph nodes were examined in the biopsy specimen, of which 6 nodes showed metastatic deposits. He received adjuvant chemotherapy with 4 cycles of FOLFOX regimen. His follow up serum CEA was 4.47ng/ml after the completion of 4 cycles [pre-operative CEA – 3.4 ng/ml]. He was subjected to a whole-body PET CT scan which showed unremarkable anastomotic site nor a significant lymphadenopathy. However, there were few hypermetabolic hypodense lesions in liver, largest being 2.9 * 2.5 cms [SUV max 7.0] in the segment VII, all likely to be metastases. Magnetic Resonance Imaging of upper abdomen with contrast showed a normal sized liver with multiple well-defined lesions in both lobes of liver suggestive of colorectal liver metastases. Computed tomography revealed multiple hypodense lesions in liver parenchyma both lobes in segments VIII [1 lesion, 1.2 * 1.0 cms], VII [4 lesions, largest 3.1 * 2.8 cms], II [3 lesions, largest 1.2 * 1.0 cms] and IV [1 lesion, 1.7 * 1.4 cms]. [Figure 1] His performance status was good [KS 0] and hence we proceeded with a diagnostic laparoscopy to rule out extra hepatic intra-abdominal disease followed by PSLR. Intraoperative ultrasound was used to locate the liver lesions and the margins of resection were marked. Parenchymal transection done using CUSA and a non-anatomical resection of segment VII with adjoining portion of segment VIII containing 5 lesions, segment II/III containing 3 lesions, a surface lesion in segment IVb and a sub-centimetric lesion in segment V. [Figure 2] IOUS was done at the end of the PSLR to ensure that no lesions were left behind in the FLR. The surgery was done with minimal blood loss and the post operative recovery was uneventful with the patient being discharged on post-operative day 5.

Discussion

Colorectal cancer is the third most common form of cancer worldwide and is the third most common cause of cancer related deaths. Resectable liver metastases that are left untreated have an average survival of about 6–12 months and on rare occasions longer than 2 years. [3]

Surgical resection for CRLM has increasingly becoming the standard of care over the recent two decades. Whenever the metastases are limited to the liver and is technically possible to resect leaving an adequate future liver remnant [FLR], there is overwhelming literature to support the survival benefit. Reports of actuarial 5-year survival of 25–40% following liver resection as compared to those who are treated with chemotherapy alone who rarely survive up to five years. [4]

Wei et al had reported a very low post-operative mortality of 1.7 % and a morbidity of 19 % in their large series of 10-year experience in surgical resection for CRLM. [5] With technical advances and improved perioperative intensive care, the mortality of liver resection is usually less than 10%.

There are significant differences between minor hepatic resections which involves resection of less than 3 liver segments and major hepatic resections involving resection of more than 3 liver segments. Blood loss, number of blood products transfused, operating room time and overall morbidity was found to be significantly higher following major hepatic resections. [6] The outcome after successful liver resection for CRLM is independent of the technique or energy devices used and is almost similar for both minor and major hepatectomies. So, considering the need to preserve an adequate liver remnant, minor hepatectomies should always be preferred whenever feasible. [7]

The success of Parenchyma sparing liver resection [PSLR] lies in the delicate balance between the two conflicting objectives, namely, achieving a complete tumour resection with curative intent and preserving as much liver parenchyma as possible to avoid post-hepatectomy liver failure. Post-hepatectomy liver failure (PHLF) is the major cause of death in these patients undergoing major hepatectomy and it is directly proportional to the quantity and quality of the FLR. [8]

With limited tumour burden PSLR looks like a straightforward option by combining segmentectomies and non-anatomical resections. It is when the tumour burden is high, we turn towards other treatment options and other relevant techniques to make PSLR feasible. These techniques are broadly categorised into those which tend to reduce the tumour load such as conversion chemotherapy, Trans-arterial chemoembolization [TACE], radio-frequency ablation [RFA], microwave ablation [MWA] etc and those that preserve or increase the amount of FLR which include portal vein embolization [PVE], two-stage hepatectomy [TSH], associated liver partition and portal vein ligation for staged hepatectomy [ALPPS] etc. All these recent developments have made removal of multiple, often bilateral liver lesions that were otherwise considered unresectable a possibility.

Even with portal vein occlusion (either ligation or embolization), almost 40% of patients never become eligible for surgical resection, either because of insufficient hypertrophy or disease progression during the long waiting periods ranging between 6 to 12 weeks that is required to achieve the desired hypertrophy. [9] Also, those who fail to complete the second stage have worse survival than those treated with chemotherapy alone. [10] The drawbacks of these techniques are that they involve major vessel excision and the removal of major portion of the liver which actually makes redo surgery for any recurrence almost impossible. This is an added advantage of PSLR where no major vessels are resected and redo surgery is still a viable option for recurrence. [11]

Apart from increasing the FLR, another great concern is the high incidence of parenchymal injury associated with downsizing chemotherapy such as steatosis, steatohepatitis and sinusoidal obstruction syndrome, which determine the postoperative risk. Parenchyma Sparing Liver Resection [PSLR] addresses all the drawbacks of major resection by preserving non-tumour parenchyma as well as what is considered a sufficient tumour margin. PSLR intends to avoid major liver resections and also the techniques to induce FLR hypertrophy simultaneously providing equal or sometimes better perioperative and long-term outcomes.[12].

Most crucial aspect in successful parenchyma sparing liver resection [PSLR] is the availability of high-quality imaging. Intra operative imaging in the form of intraoperative ultrasound has proved beyond doubt its role in guiding surgeons to plan their resections with anatomic precision. A lesion is generally considered resectable, when it can be resected with an adequate negative margin, simultaneously allowing for preservation of adequate FLR. To achieve the oncological clearance of liver tumours while planning a PSLR, a minimum margin of even 1 mm of peritumoural margin or positive vascular margin (R1 vascular) is acceptable. [13] An independent functional liver segments should have an adequate portal and arterial inflow, venous outflow and an effective biliary drainage. To plan for a parenchyma preserving hepatic resection, a knowledge of the background liver is absolute necessary. The minimal adequate liver remnant volume varies from 20 to 40% in normal liver to 30–40% in CASH [Chemotherapy Associated Steato-Hepatitis] and atleast 50% in case of advanced fibrosis or cirrhosis. [14] The goal of PSLR is to achieve adequate liver remnant without compromising the oncological safety and efficacy. [15]

Conclusion

With careful surgical planning, CT volumetry, appropriate pre operative imaging and the use of intra operative ultrasound PSLR is an extremely viable option for CRLMs in patients with good to moderate performance status and PSLR should be in the armamentarium of hepatobiliary surgeons.

References.

- [1] Y. Fong, J. Fortner, R. L. Sun, M. F. Brennan, and L. H. Blumgart, "Clinical score for predicting recurrence after hepatic resection for metastatic colorectal cancer: analysis of 1001 consecutive cases," *Annals of Surgery*, vol. 230, no. 3, pp. 309–321, 1999.
- [2] M. A. Choti, J. V. Sitzmann, M. F. Tiburi et al., "Trends in long-term survival following liver resection for hepatic colorectal metastases," *Annals of Surgery*, vol. 235, no. 6, pp. 759–766, 2002.
- [3] J. S. Wagner, M. A. Adson, and J. A. Van Heerden, "The natural history of hepatic metastases from colorectal cancer. A comparison with resective treatment," *Annals of Surgery*, vol. 199, no. 5, pp. 502–508, 1984.
- [4] H. F. Hwitzhur, W. Novotny et al., "Bevacizumab plus irinotecan, fluorouracil, and leucovorine for metastatic colorectal cancer," *The New England Journal of Medicine*, vol. 350, pp. 2335–2342, 2004.
- [5] A. C. Wei, P. D. Greig, D. Grant, B. Taylor, B. Langer, and S. Gallinger, "Survival after hepatic resection for colorectal metastases: a 10-year experience," *Annals of Surgical Oncology*, vol. 13, no. 5, pp. 668–676, 2006.
- [6] Deng, G, Li, H, Jia, G-Q, et al. Parenchymal-sparing versus extended hepatectomy for colorectal liver metastases: A systematic review and meta-analysis. *Cancer Med.* 2019; 8: 6165– 6175.
- [7] C. Riediger, M.W. Mueller, F. Geismann, A. Lehmann, T. Schuster, C.W. Michalski, et al., Comparative analysis of different transection techniques in minor and major hepatic resections: a prospective cohort study, *Int. J. Surg.* 11 (9) (2013) 826–833.
- [8] Rahbari NN, Garden OJ, Padbury R, Brooke-Smith M, Crawford M, Adam R, Koch M, Makuuchi M, Dematteo RP, Christophi C, et al. Posthepatectomy liver failure: a definition and grading by the International Study Group of Liver Surgery (ISGLS) *Surgery.* 2011;149:713–724.
- [9] Giuliante F, Ardito F, Ferrero A, Aldrighetti L, Ercolani G, Grande G, Ratti F, Giovannini I, Federico B, Pinna AD, et al. Tumour progression during preoperative chemotherapy predicts failure to complete 2-stage hepatectomy for colorectal liver metastases: results of an Italian multicenter analysis of 130 patients. *J Am Coll Surg.* 2014;219:285–294.
- [10] Brouquet A, Abdalla EK, Kopetz S, Garrett CR, Overman MJ, Eng C, Andreou A, Loyer EM, Madoff DC, Curley SA, et al. High survival rate after two-stage resection of advanced colorectal liver

metastases: response-based selection and complete resection define outcome. *J Clin Oncol*. 2011;29:1083–1090.

[11] Guido Torzilli, Lucas McCormack, Timothy Pawlik. Parenchyma-sparing liver resections; *International Journal of Surgery* 82 (2020) 192–197.

[12] Gold JS, Are C, Kornprat P, Jarnagin WR, Gönen M, Fong Y, DeMatteo RP, Blumgart LH, D'Angelica M. Increased use of parenchymal-sparing surgery for bilateral liver metastases from colorectal cancer is associated with improved mortality without change in oncologic outcome: trends in treatment over time in 440 patients. *Ann Surg*. 2008;247:109–117.

[13] G. Torzilli, L. Viganò, A. Fontana, F. Procopio, A. Terrone, M.M. Cimino, M. Donadon, D. Del Fabbro, Oncological Outcome of R1 Vascular Margin for Mass Forming Cholangiocarcinoma. A Single Center Observational Cohort Analysis, *HPB*, Oxford, 2019 Sep 14, <https://doi.org/10.1016/j.hpb.2019.08.015> pii: S1365-182X (19)30707-5.

[14] K. Kubota, M. Makuuchi, K. Kusaka, T. Kobayashi, K. Miki, K. Hasegawa, Y. Harihara, T. Takayama, Measurement of liver volume and hepatic functional reserve as a guide to decision-making in resectional surgery for hepatic tumours, *Hepatology* 26 (5) (1997) 1176–1181.

[15] R.B. Adams, T.A. Aloia, E. Loyer, T.M. Pawlik, B. Taouli, J.N. Vauthey, et al., Selection for hepatic resection of colorectal liver metastases: expert consensus statement, *HPB* 15 (2) (2013) 91–103.

FIGURE LEGENDS

Figure 1: Computed tomography image showing multiple hypodense lesions in liver parenchyma both lobes in segments VIII, VII, II and IV.

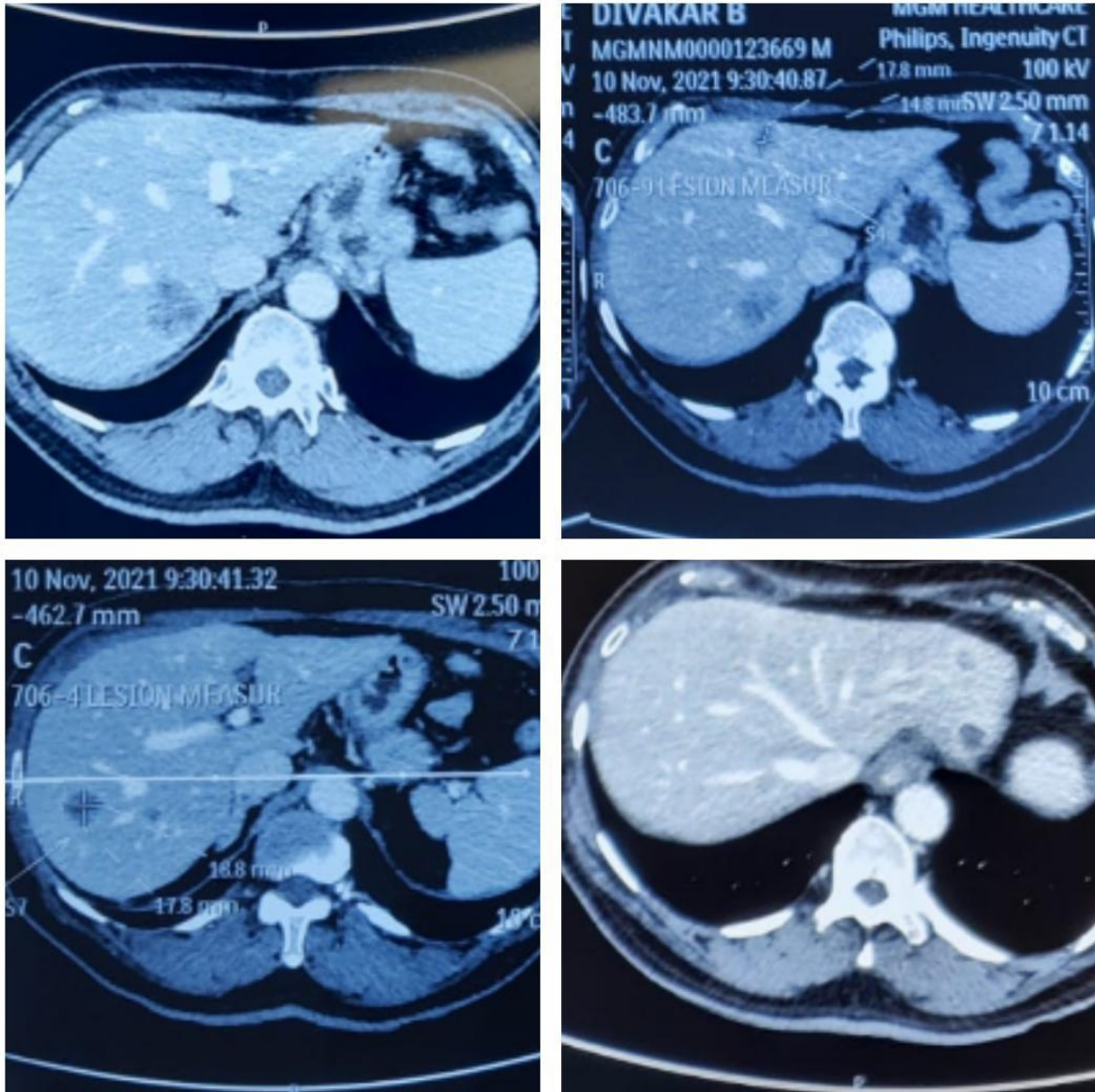
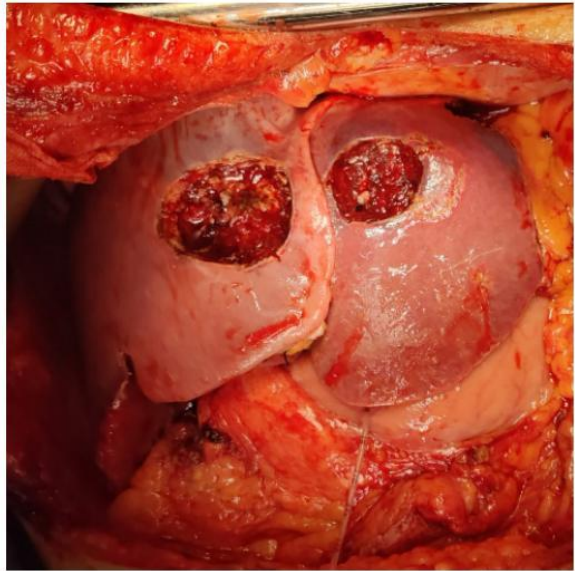
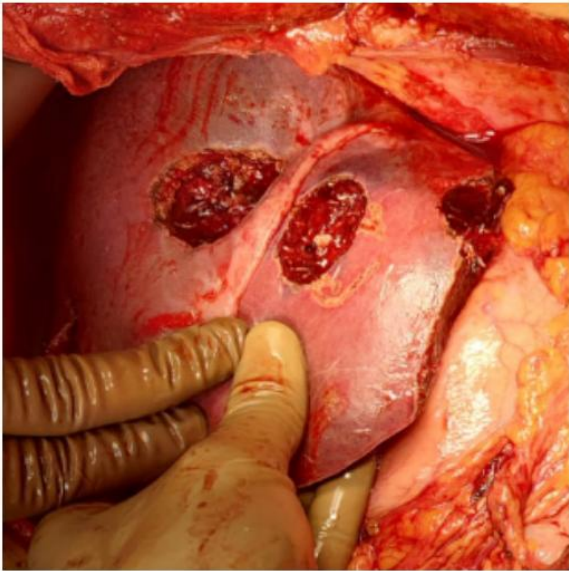
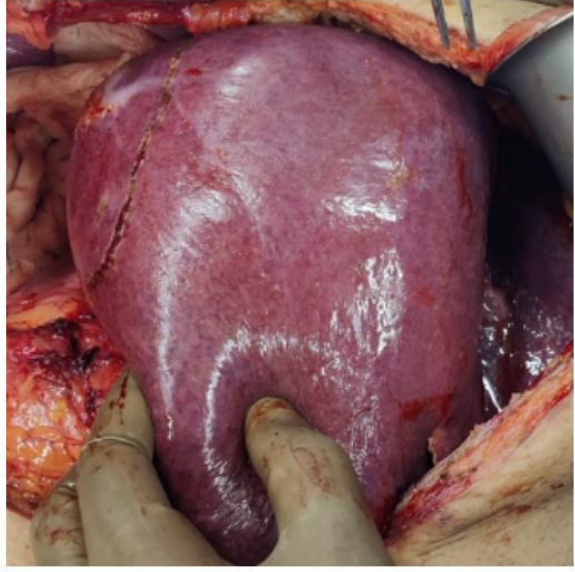
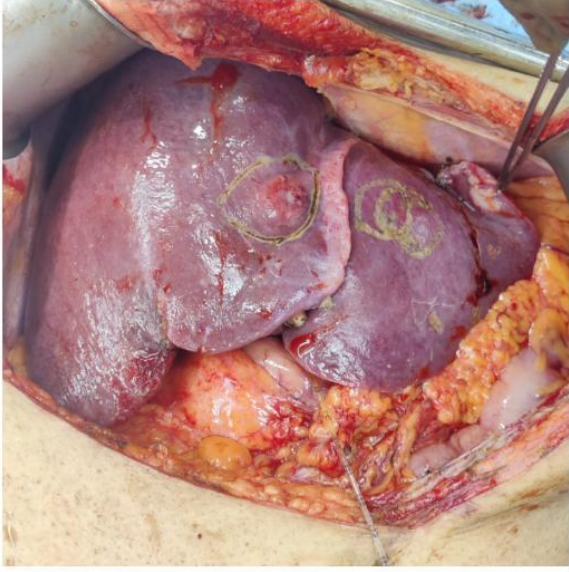


Figure 2: Parenchymal transection done using CUSA and a non-anatomical resection of segment VII with adjoining portion of segment VIII containing 5 lesions, segment II/III containing 3 lesions, a surface lesion in segment IVb and a sub-centimetric lesion in segment V.



UNDEL