

# A Rare cause of small bowel obstruction in a 2-year-old child.

Sara Husain<sup>1</sup>, Aqeela J. Madan<sup>1</sup> and Saeed Alhindi<sup>2</sup>

1. Department of Surgery-Pediatric Surgery Unit, Salmaniya Medical Complex, Manama, Bahrain

2. Department of Surgery-Pediatric Surgery Unit, Clinical Lecturer, Arabian Gulf University, Manama, Bahrain

## Abstract

We report the case of a 2-year-old child with small bowel obstruction due to a phytobezoar. Initial imaging studies failed to identify its etiology: this included an abdominal CT scan, revealing small bowel obstruction with a transitional zone in the ileum, but without a clear cause. Phytobezoar impacted in the mid-of-the-ileum was discovered to be the source of the obstruction during an exploratory laparotomy. Histopathology confirmed the diagnosis. Phytobezoar is a rare entity in children, and much less common as a cause of small bowel obstruction.

Key Words: Phytobezoar; Small Bowel Obstruction; Children

## Introduction

Bezoars can result from any indigestible or poorly digestible substance, capable of forming concretions within the gastrointestinal tract, including both the stomach and small intestine. Phytobezoars are composed of vegetable matter and are an unusual cause of small bowel obstruction (SBO); they account for about 0.4-4% of all mechanical bowel obstructions. However, the symptoms are not significantly different from those caused by the usual aetiologies of SBOs. The most common site of obstruction is the terminal ileum, with surgery as the preferred treatment.<sup>1</sup>

Small intestinal phytobezoars are almost always obstructive. Intestinal perforation, secondary to obstruction, is not well-documented in the literature, but a few cases have been reported<sup>2</sup>. Small bowel phytobezoars are extremely rare in the paediatric population, with a few cases reported in the literature, in patients that are less than three years of age.<sup>3</sup> Here, we report a case presenting with acute intestinal obstruction and a small bowel phytobezoar in a 2-year-old-girl.

## Case Presentation

This 2-year-old was not known to have any medical illnesses, so was brought into the emergency department by her parents, with a history of bilious vomiting and irritability for three days. Associated symptoms included decreased activity, fever, abdominal pain, and constipation.

Family history was negative for any similar condition; in addition, her drug and social history were unremarkable. On general examination, she was conscious but lethargic, and looked sick. Her vital signs were within normal limits except for a low-grade fever.

Her abdomen was distended, but when palpated was found to be tender: there was no palpable mass, and no rebound tenderness or signs of peritonitis.

Preliminary laboratory tests were ordered, including a complete blood count, as well as urea, creatinine, and a coagulation profile, all within normal limits. The electrolyte panel revealed a low potassium level of 2.8 mmol/L. Imaging studies were also conducted, including chest and abdominal x-rays. The chest x-rays were unremarkable, without air under the diaphragm, which may have suggested a perforation. However, the plain abdominal films showed dilated small bowel loops with multiple air-fluid sacs.

An ultrasound of the abdomen was done, which ruled out any intussusception, but showed dilatation of the small bowel loops. **(Figure<sup>1</sup>)** In view of a suspected intestinal obstruction, an urgent computed tomography (CT) scan of the abdomen was done to identify the aetiology of the obstruction and localize the transitional zone, if any; this demonstrated a SBO with a transitional zone in the terminal and distal ileal loops. No clear aetiology of the obstruction was otherwise identified. **(Figure<sup>2</sup>)**

We proceeded with resuscitation of intravenous fluids, electrolyte replacement, and nasogastric tube placement. The patient was taken to the operating theatre and underwent an exploratory laparotomy with a small bowel enterotomy and the removal of a foreign body.

The bowel was examined from the duodenojejunal junction up to the ileocecal junction, as we anticipated a palpable foreign body. The dilated small bowel loops were healthy up to the site of the foreign body. However, they were not ischemic and were thus unperforated. There was no malrotation or bands noted.

A 3 cm x 4 cm foreign body could be felt, and was impacted in the mid-ileum, as the small bowel collapsed from the foreign body (bezoar). The foreign body was blackish, round, and firm with a hair-like consistency. **(Figures. 3A, B) (Figure. 4)** An enterotomy was performed, and was extracted from the site.

### **Outcome and follow up**

The patient recovered well, and was discharged on the fifth postoperative day. Subsequent histology was consistent with having discovered a phytobezoar. She was followed in the outpatient clinic for two weeks while making a prompt recovery.

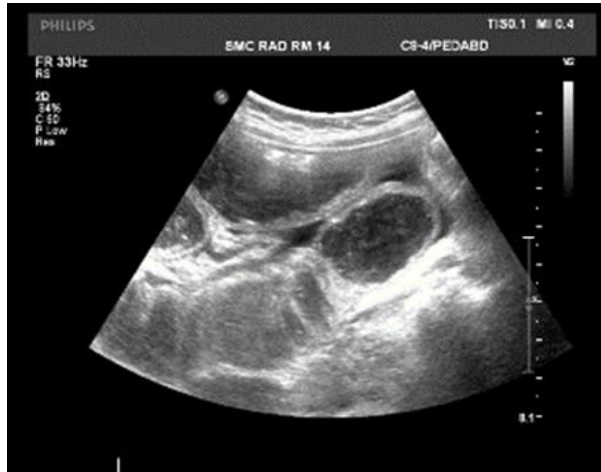

Figure.1 Ultrasound of the abdomen and pelvis, showing dilated bowel loops.

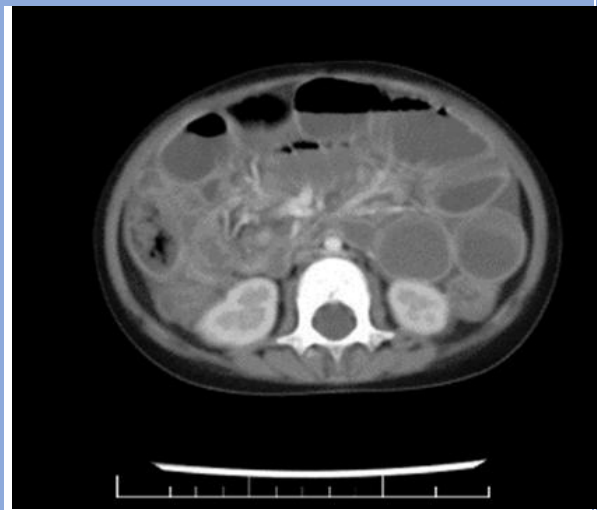

Figure.2 A CT scan abdomen and pelvis image, showing multiple dilated small bowel loops.

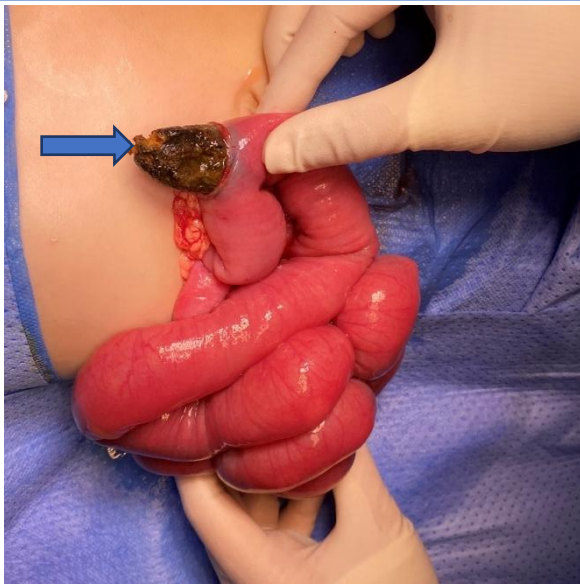


Figure-3-The phytobezoar is seen (blue arrow) through the enterotomy site.

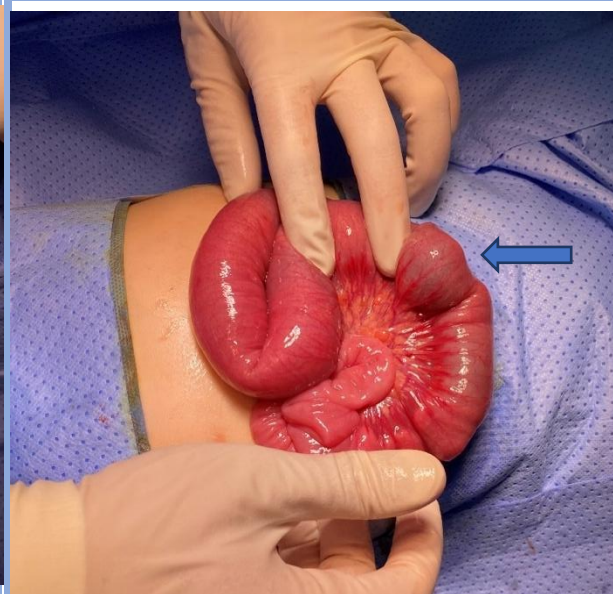
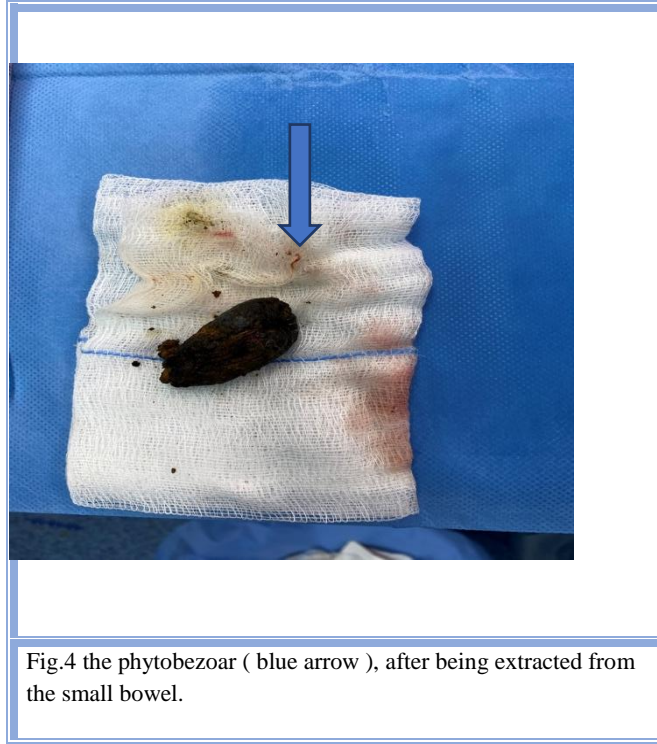

Figure-3-B: Healthy appearing small bowel, with a palpable obstructing mass\foreign body (blue arrow).



## Discussion

Bezoar is a tight collection of undigested material, that may present as a gastric outlet or intestinal obstruction. These can include lactobezoars (milk), phytobezoars (plant), trichobezoars (hair), or pharmacobezoars (medication).<sup>5-6</sup> The most common is the phytobezoar in adults and trichobezoars in children, as described in Debakey and Oschsner's literature review.<sup>8</sup>

Some contributing factors in bezoar formation were identified, including a history of previous surgery, poor mastication, overindulgence in foods with high fibre content, loss of pyloric function, gastric motility, and hypoacidity, which all play an important role in bezoar formation.<sup>4-5</sup> These factors are commonly observed in the adult age group, compared to children, in whom bezoar formation is rare.

Highlighting paediatric age groups, the literature reviewed some children of different age groups. In those cases, the most common causes included high fibre intake, ingestion of persimmon, mental retardation, and underlying behavioural disorders, such as pica.<sup>9-10</sup>

The location of bezoar impaction varies, the most frequent being the stomach, as mentioned in the literature. Second is the small intestine. Gastric bezoars are more common in adults, especially those with a previous history of gastric surgery. About 20% of patients have a history of surgery, altering gastric motility and emptying.<sup>6</sup>

As stated, the most common location of primary small bowel bezoars is the terminal ileum followed by the jejunum. The ileum is the narrowest portion of the small bowel and is almost always causing intestinal obstructions.<sup>12</sup> Bezoars can also arise in the small bowel diverticula, in a segment of the bowel associated with stricture formation. Intestinal content of the diverticulum may form concretions (bezoars) and can migrate out and subsequently obstruct the small bowel.<sup>11</sup>

Clinical symptoms are largely dependent on the location of the bezoar, whether in the stomach or intestine: they vary from nonspecific gastrointestinal symptoms such as abdominal pain, nausea, and vomiting to bowel obstruction, if impacted in the intestine.

A retrospective study of small bowel obstructions, secondary to a phytobezoar, showed that 100% of patients in this study had epigastric or generalised abdominal pain, associated with severe nausea and vomiting. Physical examination identified signs of acute obstruction in all patients who presented with faecaloid vomiting and abdominal tenderness.<sup>11</sup> Imaging modalities failed to identify the bezoar as the cause of the bowel obstruction. It was only found intraoperatively, and later confirmed by the histopathology report.

Preliminary imaging tests, such as plain abdominal film, showed only air-fluid sacs and dilated bowel loops, whereas the abdominal CT scan showed features of bowel obstruction without clear aetiology, which raises the question of its usefulness in detecting bezoars.

A study of 14 patients with small bowel obstructions due to phytobezoar showed that CT scan of the abdomen failed to detect it in 14 patients (93%), whereas in one (7%) patient, images consistent with intraluminal bezoar and dilatation in proximal segments were observed.<sup>11</sup>

Treatment options focus on removing the bezoar and preventing its recurrence. The literature has described many nonsurgical interventions, such as endoscopic retrieval, enzymatic therapy, or therapies like nasogastric lavage or suctioning, **NAAC( N-acetylcysteine)**, or carbonated beverages for gastric bezoars.<sup>7</sup> There was not enough data or studies on paediatric age groups, so this was not an option in our case, as the patient had a mid-ileal bezoar causing the bowel obstruction.

Surgical intervention was reserved for cases with perforation, bleeding, and obstruction as in ours.<sup>6-7</sup> The surgical approach can be either open or laparoscopic, depending on the size, location, number of bezoars,

the centre, feasibility, and the surgeon's experience. Laparoscopic approach mostly included enterotomy and retrieval; with few cases reported similar approach and results.<sup>13-14</sup>

Through our review of the literature, our patient was considered young enough to have a phytobezoar-related SBO. Given the age groups found, they ranged between 4-14 years old. One case mentioned was similar to our own patient's age, i.e., 12 months, presenting with a small bowel obstruction due to a parsnip phytobezoar.<sup>3</sup>

Prevention includes dietary counselling, treatment of any underlying behavioural illnesses, such as pica, and endoscopic assessment to retrieve any remnant bezoars to in turn prevent future migration to the small bowel - which may again cause obstruction.

## Conclusion

Bezoars are considered rare in paediatric age groups. The cases reported were mainly secondary to abnormal dietary habits or those with underlying behavioural illness. That said, a detailed dietary history can aid in the diagnosis, given that certain types of food ingestion play a role in bezoar formation.

Diagnosis by imaging modalities, such as CT scan of the abdomen alone, are insufficient. It may aid in the diagnosis, but in most cases they failed to detect the bezoar as in our case; a number of cases with a final diagnosis were made with the histopathology report.

The main target of treatment is early diagnosis, tackling complications, and preventing recurrence. Treatment is mainly case-dependent, as each may present differently, based on the location. In our case here, it presented as a small bowel obstruction, thus, treated surgically.

Prevention includes dietary counselling, treatment of any underlying behavioural illnesses, such as pica, and endoscopic assessment to retrieve any remnant bezoars to in turn prevent future migration to the small bowel - which may again cause obstruction,

## Disclosure

This case report was performed in the pediatric surgery unit, department of surgery, and the pediatric department, Salmaniya medical complex, Bahrain.

## Ethical Approval:

As per international standard or university standard ethical approval has been collected and preserved by the authors.

## Consent

Verbal consent was obtained from the parents.

## Conflicts of Interest

The authors declare that there are no conflicts of interest.

## References

- [1] Pujar A, Pai S. Phytobezoar: a rare cause of small bowel obstruction. *Journal of clinical and diagnostic research: JCDR*. 2013 Oct;7(10):2298.
- [2] Amoroso S, Scarpa MG, Poropat F, Giorgi R, Murru FM, Barbi E. Acute small bowel obstruction in a child with a strict raw vegan diet. *Archives of disease in childhood*. 2018 May 14.
- [3] Garcia DI, Head WT, Leshner AP. Parsnip phytobezoar causing small bowel obstruction. *Journal of Pediatric Surgery Case Reports*. 2019 Aug 1;47:101227.
- [4] Saeed ZA, Rabassa AA, Anand BS. An endoscopic method for removal of duodenal phytobezoars. *Gastrointest Endosc*. 1995;41:74–76.
- [5] Escamilla C, Roble..campos R, Parrilla-Paricio p . LuJan-Mompean J, Liron-Rulz R, To"all»Martinez JA. Intestinal obstruction and bezoars. *J AmCo/ISurg* 1994;179:285-288
- [6] Wang PY, Skarsgald ED, Baker RJ. Carpet bezoar obstruction of the small intestine. *J Pediatr Surg* 1996;31:1691-1693
- [7] Salena BJ, Hunt RH: Bezoars, in Sleisenger MH, Fortran JS (eds): *Gastrointestinal Disease: Pathophysiology, Diagnosis, Management* (ed 5), chap 35. Philadelphia, PA, WB Saunders Company, 1993, pp 758-763
- [8] DeBaakey M, Ochsner A. Bezoars and concretions: A comprehensive review of the literature with an analysis of 303 collected cases and a presentation of 8 additional cases. *Surgery*. 1939 Jan 1;5(1):132-60.
- [9] Lou CC, Lin JN, Wang KL. Gastrointestinal phytobezoar in children. *Changeng yi xue za zhi*. 1990 Sep;13(3):208-13
- [10] Phillips MR, Zaheer S, Drugas GT. Gastric trichobezoar: case report and literature review. *In Mayo Clinic Proceedings* 1998 Jul 1 (Vol. 73, No. 7, pp. 653-656). Elsevier.
- [11] Yakan S, Şirinocak A, Telciler KE, Tekeli MT, Deneçli AG. A rare cause of acute abdomen: small bowel obstruction due to phytobezoar. *Turkish Journal of Trauma and Emergency Surgery*. 2010 Sep 1;16(5):459-63.

[12] Teo M, Wong CH, Chui CH. Food bolus - an uncommon cause of small intestinal obstruction. Aust N Z J Surg 2003;73(Suppl 1):A47.

[13] Bhau KS, Ahmad MM. Laparoscopy Assisted Management of an Unusual Case of Pomegranate Seed Phytobezoar Causing Small Gut Obstruction in a Child – A Case Report. Int J Sci Stud 2021;9(3):7-10.

[14] Aboukacem BM, Ghaleb M, Khemir A, Souai F, Gharbi M, Ben Safta Y, *et al.* Laparoscopic assisted foreign body references intestinal obstructions 14 extraction from the small bowel: A case report. Int J Surg Case Rep 2017;41:283-6.