

Title of the article: Paediatric Primary Peritonitis: A rare entity among immunocompetent individuals rearing its head again during this COVID-19 pandemic era.

Hidhaya Selvan Ramakrishnan, Aatikah Rashidah , Nur Bazlaah Bahari, Vethunan Tamalvanan,
Khairuzi Salekan

Department of General Surgery, Hospital Sultanah Nora Ismail, Jalan Korma, Taman Soga, Batu Pahat, 83000 Johor, Malaysia

Abstract:

Primary peritonitis is a unique entity that has taken backstage in terms of incidence in recent years, especially in those immunocompetent individuals. Here, we present the case of a young 6-year-old girl that presented to the emergency room with generalised abdominal pain and Class II septic shock. The patient had then undergone laparotomy, prophylactic appendicectomy and peritoneal lavage. Diagnosis of primary peritonitis was then subsequently made, and the patient had completed a broad-spectrum antibiotic course and recovered well. The discussion reviews the impact of lockdown imposed in view COVID-19 infection in terms of delay in seeking medical treatment, the pathogenesis of the primary peritonitis, and different management modalities.

Keywords: primary peritonitis, immunocompetent, covid-19 batu pahat

Introduction:

Primary peritonitis by definition, is a peritoneal infection without any evidence of intra peritoneal septic focus.(1) Primary peritonitis is a rare cause of peritonitis in the paediatric age group in this modern world, unlike secondary and tertiary peritonitis.(2) It represents less than 1% of all paediatric

emergencies.(1) The pathophysiology of the condition is not fully understood; however, lymphatic or hematogenous spread of the organism to the peritoneal lining is thought to be the cause of this condition, along with ascending infection from the genital and urinary tract.(3) This entity is uncommon in general, more so in immunocompetent paediatric age group.(3) To the best of our knowledge, this represents one of the first of such reported cases in Malaysia, especially during this pandemic era which we would like to share and discuss.

Case History

An immunocompetent 6 years old presented with fever and continuous diffuse abdominal pain of 4 days duration, which was then associated with anorexia, vomiting and diarrhoea starting 2 days prior to presentation to our centre. Upon further history from the mother, she also noted that the child had been having a sore throat for the past 1 week prior to presentation to the hospital. The child was in class II shock with marked tachycardia (160-170 beats/minute), normotensive (109/60mmHg), poor pulse volume and poor hydration. Physical examination of the abdomen revealed peritonitis with diffuse generalised tenderness, rebound tenderness and guarding. The child was also febrile (39.8°C) and severely dehydrated. Laboratory investigation showed marked elevated white cell count and compensated metabolic acidosis. The renal function test was normal. Laboratory investigations are depicted in (Table 1). Abdominal X-ray showed ground glass appearance over the right side with the bowels pushed to the left side of the abdomen (Figure 1- Abdominal X-ray of the patient showing ground glass appearance over the right side suggestive of fluid filled peritoneal cavity). No air under the diaphragm on chest X-ray. The impression of perforated appendicitis was made, and the patient was given adequate fluid resuscitation before the operation.

The patient then subsequently had transverse laparotomy in view peritonitis. Upon entering the peritoneal cavity noted about 100mls of frank pus, mainly at the right paracolic gutter and the pelvic region. However, in view of no obvious perforation noted at the appendix (Figure 2- Intra operative finding of the appendix, which was normal with slight serosa inflammation, normal in texture and not

thickened suggest that it is not the primary pathology intraoperatively) but grossly purulent contamination. Subsequently, small bowels were run through, which showed no Meckel diverticulum or any perforation. Other organs such as the gallbladder, large bowel, stomach, lesser sac, and pancreas showed no abnormality. Methylene blue test through the Ryle tube was then done to check for distal oesophagus and stomach perforation; however, it was also negative. Hence the diagnosis of primary peritonitis was made for the patient. Prophylactic appendectomy was then done for the patient along with peritoneal lavage. Cultures of the peritoneal fluid and slough showed no growth of any organism.

The post-op period for the patient was fairly uneventful except that the patient developed post-op ileus, which was resolved by post-op day 6. The white blood cell has dropped during post op period as shown in (Chart 1). The child recovered well and was discharged from our centre after completion of intravenous broad-spectrum antibiotic. Histopathological examination of the appendix, which was sent, came back as a normal appendix.

Laboratory test	Patients value	Reference Range
Haemoglobin(g/L)	12.1	13.0-17.5
Hematocrit(%)	37.7	39.8-52.2
Platelet($10^9/L$)	443	150-410
White blood count($10^9/L$)	38.7	4.5-11
Urea(mg/dl)	4.6	2.8-7.2
Creatinine(mg/dl)	41	45-84
Ph	7.4	7.35-7.45
Hco3	14.3	22-26

Table 1: Laboratory investigation result of the patient upon initial presentation to the centre.

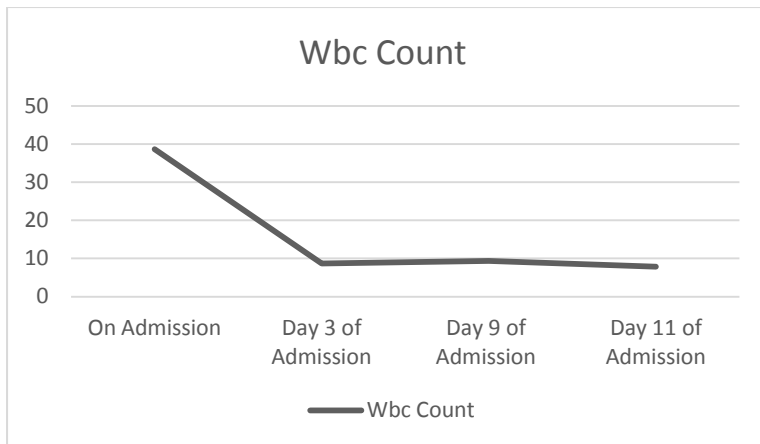


Chart 1: Graph showing the wbc trend of the patient over the course of the stay in the hospital.

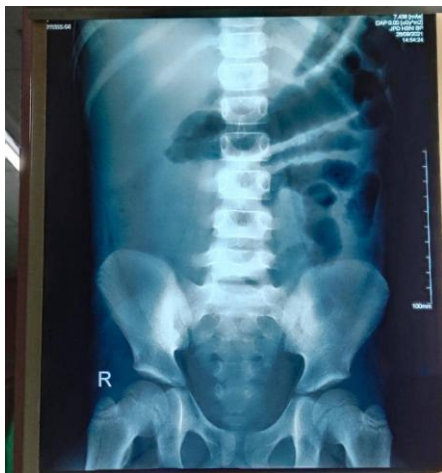

Figure 1: Abdominal X-ray of the patient showing ground glass appearance over the right side suggestive of fluid filled peritoneal cavity

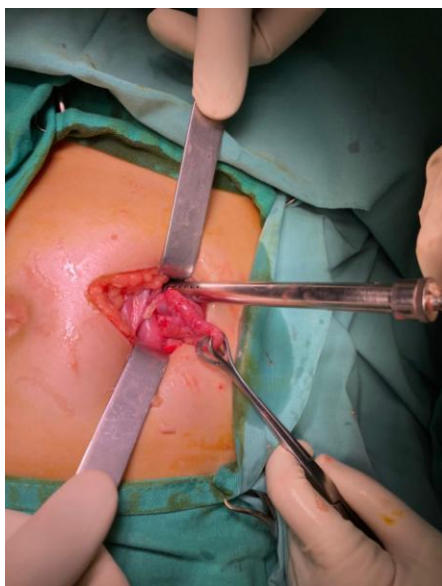


Figure 2: Intra operative finding of the appendix which was normal with slight serosa inflammation, normal in texture and not thickened to suggest that it is not the primary pathology intraoperatively.

Discussion:

Primary peritonitis is rare, especially in this antibiotic era. However, in March 2020, the Malaysian gov has imposed a lockdown to curb the spread of Covid-19 infection(6). This was then followed by another 2 lockdowns of varying durations. These lockdowns have limited the people's movement in general, and in some extreme cases, some patients present at a later stage. To curb Covid-19 infection risk among the healthcare workers, clinically stable patients and those that can be managed non surgically are recommended to be managed non surgically.(5) These are some of the reasons that likely caused the haematogenous spread of the initial infective foci in this child, which is exudative tonsillitis. This tickles the curious mind of the health givers on how exactly this entity happens, which will be discussed in further detail below and the options of the treatment available for such cases encountered next.

Primary peritonitis is defined as spontaneous, diffuse peritoneal infection without another intra-abdominal process or source.(6) Currently, it makes up less than 2% of all acute abdominal emergencies.(1)This condition is much more common in the paediatric age group compared to adults.(3) And it also seems to have preponderance towards females compared to males.(3) Primary peritonitis can occur in all age groups but is most commonly seen in the age of 4-9 years.(3) The child in this report is a girl and she is 6 years old.

The exact aetiology of the condition is not fully understood. Hematogenous, lymphatic, gastrointestinal, genital tract and urinary tract have all been looked at as a possible route of infection.

Streptococcus Pneumoniae was identified as the causative agent in the majority of cases from previous years.(3) Some of the other organisms which have been identified in causing primary peritonitis are listed in (Table 2)(7). In this child, the hematogenous spread is the likely source of the peritonitis as the patient had exudative tonsillitis, which was not treated for several days. However, as the peritoneal culture was not fruitful in identifying the causative organism, there is no conclusive

answer for the infective source. Isolation of the same organism in the peritoneal fluid and other sources of infection were used to identify the organism responsible for this condition. In some case reports, the isolation of organisms from vaginal swab was the reason for the conclusion that the condition is caused by ascending infection from the genital tract.(2) The reasons for some of the cases are not able to identify the organism from the peritoneal culture, such as in this case is the possibility of viral origin(3) and administration of prophylactic broad-spectrum antibiotics(8). In this current Covid-19 pandemic era, the possibility of the Covid-19 causing this entity should be investigated. Alpha variant of coronavirus has been linked to causing peritonitis in cats(9). Even the currently infamous beta-variant coronavirus, which has been shown to infect the gastrointestinal tract via the angiotensin II-converting enzyme receptor, which is present in enterocytes in the ileum and colon, causing inflammation of the affected part of the bowels(10) points towards the possibility of the Covid-19 causing peritonitis in previously well patients. Besides this, patients of Covid-19 have shown to have a hypercoagulable state which causes intravascular coagulation causing bowel ischemia and perforation(11). In this child, however, antigen testing for Covid-19 was negative, and none of the family members had any Covid-19 infection symptoms and any recent contact with Covid-19 patients.

Microorganism	Spontaneous Bacterial Peritonitis (%)
<i>Escherichia coli</i>	37
<i>Klebsiella pneumoniae</i>	17
<i>Pneumococcus</i>	12
<i>Streptococcus</i>	9
Miscellaneous Gram -ve	10
Miscellaneous Gram +ve	14
Polymicrobial	1

Table 2: Showing some of the organisms identified in causing the spontaneous bacterial peritonitis and the percentage based on previous literature.

The laparoscopic approach for abdominal surgery has made many advances in recent years. It has many advantages such as faster recovery, reduced risk of infection and reduced post-operative pain. Historically speaking, many surgeons would see peritonism as a contraindication for laparoscopic approach to the case due to higher risk of bacteraemia and endotoxemia(12) due to changes in the intestinal permeability and pneumoperitoneum. However, more recent studies showed that the laparoscopic approach is feasible and carries less risk and faster recovery than laparotomy, even in those present with peritonism.(12–15) This is because the recent studies show that systemic endotoxemia occurs at a much lower degree in laparoscopic surgery than laparotomy(16,17). Hence laparoscopic approach should be considered for intra-abdominal surgery, especially in cases of primary peritonitis whereby there is no intra-abdominal pathology/source for the peritonitis. Drainage of intra-abdominal collection and inspections of the intra-abdominal organs can be done via the laparoscopic method instead of the laparotomy. Peritoneal lavage is also part of the management of primary peritonitis as it is required to treat sepsis. Laparoscopic lavage has been used to treat intra-abdominal collection and sepsis, but a meta-analysis done on laparoscopic lavage showed a higher incidence of post-operative intra-abdominal abscess, which beats the purpose of the surgical intervention to treat the sepsis(18).

Retrospectively, the need for surgical intervention could be questioned if the diagnosis was known prior. However, the surgical team attending to this patient faced a critically ill child with clinical and radiologically showing signs of intra-abdominal pathology pointing to septic shock secondary to perforated appendicitis, in which timely intervention is essential. This points towards classical indication for surgical exploration at the earliest. Moreover, in the district setting of the centre in which this patient presented to whereby laparoscopic surgeries are not readily available due to the cost and other limitations associated with it, laparotomy is the appropriate option for this patient. In cases of primary peritonitis, one of the important aspects of management is to rule out secondary peritonitis (intra-abdominal cause of sepsis). There is a diagnostic dilemma associated with primary peritonitis

and difficulty in differentiating this entity from other causes of peritonitis, such as perforated appendicitis. Diagnostic methods such as CT scans have advanced leaps and bounds in recent years in terms of the accuracy in detecting intra-abdominal pathology. It has specificity and sensitivity in detecting pathology in the appendix of about 87% and 100% and 89% and 99%, respectively(19). With this, a more conservative treatment of CT scan to rule out secondary peritonitis along with paracentesis or image-guided drainage can be attempted for primary peritonitis (22). However, more prospective studies and research would be needed on this. With that being said, the more common pathology encountered in clinical settings would still be perforated appendicitis which cannot be ruled out completely with a CT scan; hence it would not be advisable to drain in the assumption that it is primary peritonitis.

Conclusion

Primary peritonitis is very much present at the current time, even in the immunocompetent individual. As pointed out earlier, it might become more common whilst the population is in lockdown and there is a delay in seeking medical attention. Although patients generally respond well with broad spectrum antibiotics, secondary peritonitis should always be excluded first. There is a need for a more tailored approach of management which best suited for each patient. This case study also highlights the impact of lockdown imposed in view COVID-19 infection in terms of delay in seeking medical treatment, the pathogenesis of the primary peritonitis, and different management modalities.

Disclaimer regarding Consent and Ethical Approval:

As per university standard guideline, participant consent and ethical approval have been collected and preserved by the authors

References:

1. Khilji MF. Primary Peritonitis—A Forgotten Entity. *European Journal of Pediatric Surgery Reports* [Internet]. 2015 May 8 [cited 2021 Oct 4];3(1):27. Available from: [/pmc/articles/PMC4487121/](#)
2. Mustafa M, Menon J, Muniandy RK, Sieman J, Sharifa AM, Illzam EM. PP 74-79 2 .Deapetment of Gastroenterology. *IOSR Journal of Dental and Medical Sciences* [Internet]. 14:2279–0861. Available from: [www.iosrjournals.org](#)
3. TG Armitage MB, ChB, FRCSE, RCN Williamson M. *Chir. FRCS*. 21.full(1) - Shortcut. *Postgraduate Medical Journal* [Internet]. 1983 [cited 2021 Oct 4]; Available from: [https://pmj.bmj.com/content/59/687/21](#)
4. Covid-19: Malaysia to go into nationwide pause from March 18 and what we know so far - TODAY [Internet]. [cited 2021 Oct 17]. Available from: [https://www.todayonline.com/world/covid-19-malaysia-goes-nationwide-pause-march-18-and-what-we-know-so-far](#)
5. Garis Panduan KKM | COVID-19 MALAYSIA [Internet]. [cited 2021 Oct 17]. Available from: [https://covid-19.moh.gov.my/garis-panduan/garis-panduan-kkm](#)
6. Hranjec T, Watson CM, Sawyer RG. Peritonitis: Definitions of Primary, Secondary, and Tertiary. *Encyclopedia of Intensive Care Medicine* [Internet]. 2012 [cited 2021 Oct 4];1723–9. Available from: [https://link.springer.com/referenceworkentry/10.1007/978-3-642-00418-6_84](#)
7. Causative microorganisms of spontaneous bacterial peritonitis,... | Download Table [Internet]. [cited 2021 Oct 19]. Available from: [https://www.researchgate.net/figure/Causative-microorganisms-of-spontaneous-bacterial-peritonitis-bacterascites-and_tbl2_6285712](#)
8. Salzer WL. Peritoneal dialysis-related peritonitis: challenges and solutions. *International Journal of Nephrology and Renovascular Disease* [Internet]. 2018 Jun 11 [cited 2021 Oct 18];11:173. Available from: [/pmc/articles/PMC6001843/](#)

9. Feline Infectious Peritonitis (FIP) | International Cat Care [Internet]. [cited 2021 Oct 4]. Available from: <https://icatcare.org/advice/feline-infectious-peritonitis-fip/>
10. Takegawa PH, Silva MC, Belluco C, Mitsunaga T, Pegolo P, Miranda ML, et al. “Inflammatory peritonitis in a child with COVID-19”. *Journal of Pediatric Surgery Case Reports* [Internet]. 2021 Dec 1 [cited 2021 Oct 18];75:102077. Available from: <https://linkinghub.elsevier.com/retrieve/pii/S2213576621002980>
11. Neto IJFC, Viana KF, Silva MBS da, Silva LM da, Oliveira G de, Cecchini AR da S, et al. Perforated acute abdomen in a patient with COVID-19: an atypical manifestation of the disease. *Journal of Coloproctology* [Internet]. 2020 Jul 1 [cited 2021 Oct 18];40(3):269. Available from: </pmc/articles/PMC7261449/>
12. Sangrasi AK, Talpu KAH, Kella N, Laghari AA, Abbasi MR, Qureshi JN. Role of laparoscopy in peritonitis. *Pakistan Journal of Medical Sciences* [Internet]. 2013 Jul [cited 2021 Oct 10];29(4):1028. Available from: </pmc/articles/PMC3817755/>
13. Sauerland S, Agresta F, Bergamaschi R, Borzellino G, Budzynski A, Champault G, et al. Laparoscopy for abdominal emergencies. *Surgical Endoscopy And Other Interventional Techniques* 2005 20:1 [Internet]. 2005 Oct 24 [cited 2021 Oct 10];20(1):14–29. Available from: <https://link.springer.com/article/10.1007/s00464-005-0564-0>
14. Agresta F, Michelet I, Coluci G, Bedin N. Emergency laparoscopy. *Surgical Endoscopy* 2000 14:5 [Internet]. 2014 Apr 9 [cited 2021 Oct 10];14(5):484–7. Available from: <https://link.springer.com/article/10.1007/s004640000022>
15. Agresta F, Simone P de, Bedin N. The Laparoscopic Approach in Abdominal Emergencies: A Single-Center 10-Year Experience. *JSLs : Journal of the Society of Laparoendoscopic Surgeons* [Internet]. 2004 [cited 2021 Oct 10];8(1):25. Available from: </pmc/articles/PMC3015501/>

16. M S, F C, S C, G A. Intestinal permeability and systemic endotoxemia after laparotomic or laparoscopic cholecystectomy. *Annals of Surgery* [Internet]. 2006 Mar 1 [cited 2021 Oct 19];243(3):359–63. Available from: <https://europepmc.org/article/med/16495701>
17. Schietroma M, Carlei F, Cappelli S, Amicucci G. Intestinal Permeability and Systemic Endotoxemia After Laparotomic or Laparoscopic Cholecystectomy. *Annals of Surgery* [Internet]. 2006 Mar [cited 2021 Oct 19];243(3):359. Available from: [/pmc/articles/PMC1448948/](https://pubmed.ncbi.nlm.nih.gov/1448948/)
18. R C, S DS, DG W, R T, I A, J R, et al. Laparoscopic lavage versus surgical resection for acute diverticulitis with generalised peritonitis: a systematic review and meta-analysis. *Techniques in coloproctology* [Internet]. 2017 Feb 1 [cited 2021 Oct 19];21(2):93–110. Available from: <https://pubmed.ncbi.nlm.nih.gov/28197792/>
19. Hernanz-Schulman M. CT and US in the Diagnosis of Appendicitis: An Argument for CT1. <https://doi.org/10.1148/radiol09091211> [Internet]. 2010 Mar 10 [cited 2021 Oct 19];255(1):3–7. Available from: <https://pubs.rsna.org/doi/abs/10.1148/radiol.09091211>