

### **Is spermatic cord torsion exclusively an adolescent emergency?**

#### **Abstract:**

Testicular torsion is a surgical emergency defined as the torsion of the spermatic cord in the tunica vaginalis. It occurs mainly in adolescents. Beyond 6th hours, irreversible lesions start to appear. Therefore, the prognosis of the testicle will depend on the time taken to treat it. The main differential diagnoses are torsion of the testicular appendages and orchiepididymitis. In adults, it poses a diagnostic problem leading to a high rate of orchiectomy. We are reporting a 46-years old patient with a history of recurrent urethritis and orchiepididymitis who came with scrotal pain associated with fever and urinary tract symptoms in whom the diagnosis of a neglected testicular torsion was made. Surgical exploration found a necrotic testicle with the presence of spermatic cord twist. An orchiectomy was performed. The postoperative follow up was simple. With this case, the authors remind us that testicular torsion is a real urological emergency that requires a race against time. Whatever the age and the history, it must be the first diagnosis to be evoked (until proven otherwise) in front of any acute scrotum seen in the emergency.

**Key words:** scrotal pain, orchiepididymitis, testicular torsion, ultrasound, orchiectomy

#### **Introduction**

Testicular torsion is defined as the torsion of the spermatic cord in the tunica vaginalis (1). It is a functional emergency that threatens the vital prognosis of the testicle. It occurs mainly during the first year of life and at the pubertal period. It is a surgical emergency and the preservation of the testicle concerned depends mainly on the duration of the evolution and the degree of torsion. Torsion of the testicular appendages and orchiepididymitis are the main differential diagnoses. (2). In adults, it poses a diagnostic problem leading to diagnostic errancy or missed diagnosis, which compromises the chances of testicular salvage (3). We are reporting a case of testicular torsion in a 46 years old patient with a history of urethritis and orchiepididymitis that resulted in orchiectomy

#### **Clinical Case**

A 46 years old patient with a history of recurrent urethritis and orchiepididymitis presented to our center for scrotal pain associated with fever that has been evolving for over 72 hours. He had consulted 48 hours earlier in another center for acute left scrotal pain with fever and irritative urinary signs. The clinical examination revealed a patient with performans status at I, hemodynamically stable with a swollen and temperature at 38,3° C., painful, reddish left scrotal with an ascending, tense testicle (image 1) and Prehn's sign was negative . The contralateral testicle was normal. Scrotal doppler ultrasound showed an enlarged left testicle with regular contours and hypoechoic, heterogeneous, poorly defined areas and the absence of vascular supply with a twisting spiral appearance and a small left hydrocele (image 2). The

right testicle was normal. The patient was taken to the operating room after a signed consent for exploratory scrototomy and possibility of orchidectomy. On the surgical exploration, the left testicle was necrotic (blackish) with the presence of a twisted spermatic cord sign (picture 3). An orchiectomy was performed. The postoperative follow up was simple.

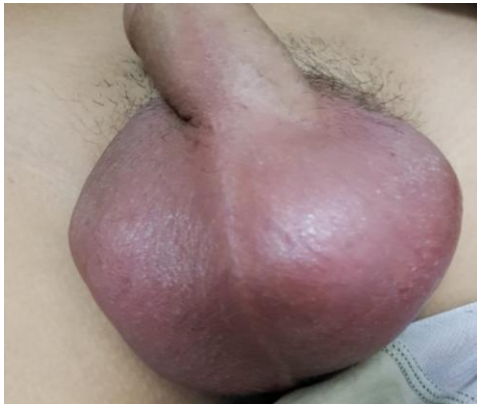

Image 1: swollen, reddish left scrotal with an ascended testicle

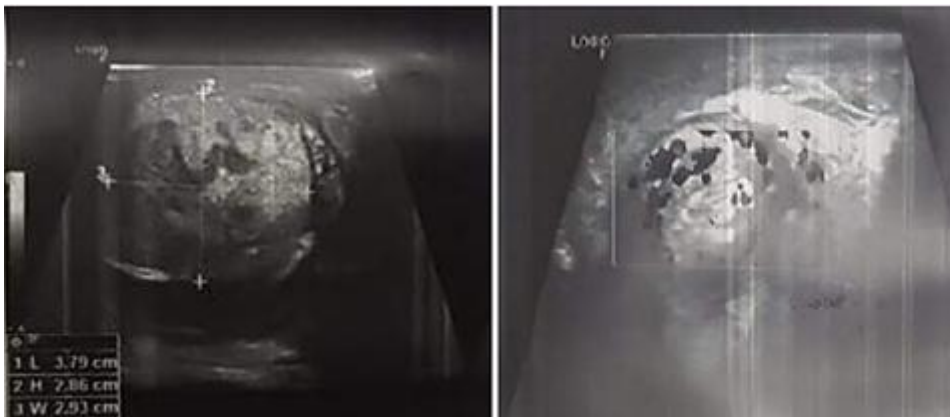


Image 2: Ultrasound showed an enlarged left testicle with regular contours and hypoechoic, heterogeneous, poorly defined areas and the **the absence of vascular supply** with a twisting spiral.

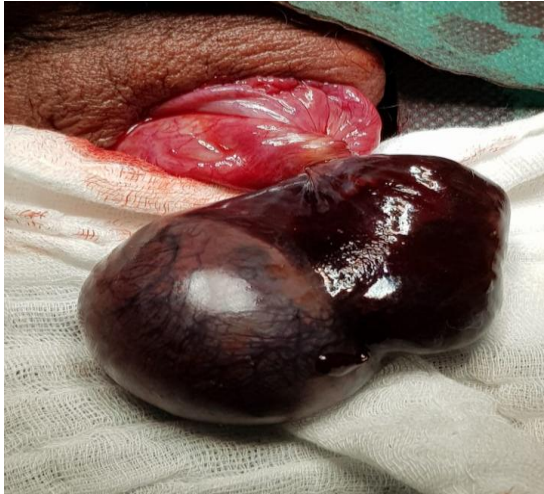

Image 3: Necrotic testicle and twisted spermatic cord

## Discussion

In the case of spermatic cord torsion, the sudden interruption of blood flow to the testicle leads to acute ischemia and then testicular necrosis within a few hours if no treatment is undertaken. This risk is variable, depending on the number of turns of the coil, the tightness or looseness and the duration of the torsion (4). It is generally accepted that irreversible damage will start after 6 hrs or after only 4 hrs in case of an extremely twisted spermatic cord (5). In our present case, the symptomatology was of 72 hours of evolution. This explains the presence of necrosis.

Testicular torsion occurs mainly in adolescents, with more than 65% of incidents occurring before 18 years of age (6). In a study of 27, Bah et al reported that in 70.3% of cases, the age was less than 25 years (7). A review of 25 (1) showed that 6% of testicular torsions occurred at 31 years or older. One case was reported in a subject over 60 years of age (8). Torsion in adults or elderly subjects is not often encountered and only a few cases are described in isolation.

Among the predisposing factors, anatomical abnormalities, exercise, cold and trauma have been reported (1). None of these factors were found in our patient.

In the acute phase, torsion of the spermatic cord presents as an acute scrotal pain in an adolescent or young adult. It is most often spontaneous in onset (8). The pain is sudden, unilateral, intense, rapidly progressive or maximal, preventing normal walking, with variable radiations (inguinal region, lumbar fossa) (9). The patient is initially non febrile, with fever appearing only after several hours in case of testicular necrosis. Digestive signs with nausea and vomiting are present in 40% of cases, and functional urinary signs (dysuria, pollakiuria) are found in 5% of cases (1). Reactive edema or erythema is sometimes present. The cremasteric reflex is classically abolished (10). At an advanced stage, testicular necrosis sets in. It is associated with a decrease in pain. Congestive signs with edema of the scrotum and a reactive hydrocele may be observed. Fever or feverishness may be present. The differential diagnosis with orchiepididymitis is more difficult. Neglected forms may evolve into aseptic necrosis with progressive atrophy of the testis or sometimes purulent melting with risk of skin

fistulization (2). Exploration showed a testicle with a blackish appearance (necrotic) and the presence of twisting cord sign . In the absence of pathological damage, the testicle is smooth, shiny, pearly white in color and firm in consistency (11).

Color Doppler ultrasound is the most widely used diagnostic imaging method for testicular torsions. It has a sensitivity of 63% to 99% and a specificity of 97% to 100% (12). Ultrasound has been used to make the diagnosis of testicular torsion by identifying an avascular formation making a twisted cord sign in appearance. The sonographic appearance of a testis in a vascular distress with hypoechoic, heterogeneous, poorly limited areas was in favor of necrosis. The hydrocele was of reactionary origin. In the present case, ultrasound was used to diagnose a neglected testicular torsion and to eliminate orchiepididymitis.

In case of testicular torsion, an exploratory scrototomy is necessary. Depending on the condition of the testicle, an orchidectomy or orchidopexy may be performed. If the testis is not viable, an orchidectomy is performed (13). Since the testis was necrotic, an orchidectomy was performed.

The prognosis correlates with the earliness of the procedure. The overall rate of testicular preservation after torsion is 40% to 70%, but we have 100% preservation before 3 hours, 90% before 6 hours, and less than 50% after 10 hours (14). A lack of suspicion of testicular torsion in elderly patients may result in a missed or delayed diagnosis, compromising the chances of testicular salvage (3).

The consequences on the contralateral testicle are often underestimated. Indeed, an individual's fertility may be compromised as soon as a unilateral torsion occurs, even if it is treated in time. Fertility problems are found in 36% to 39% of patients after torsion and the spermogram is normal in only 5% to 50% of cases during long-term follow-up (4). The spermogram performed at 3 months post orchidectomy was without abnormalities.

## **Conclusion**

Testicular torsion is not an exclusive urological emergency of the adolescent. It can occur at any age. In front of any acute scrotal pain, even in an adult or elderly subject with previous episodes of orchiepididymitis, testicular torsion must be the first diagnosis to be evoked and surgical exploration is necessary at the slightest doubt. Ultrasound has an important place in the diagnosis, especially in the case of neglected torsion. Testicular preservation depends on the rapidity of the treatment.

## **References**

1. Anderson JB, Williamson RCN Testicular torsion in Bristol: a 25 year review. *Br J Surg.* 1988; 75 : 988–992.
2. Audenet, F. (2012). Torsion du cordon spermatique et des annexes testiculaires : physiopathologie, diagnostic et principes du traitement. *EMC - Urologie*, 5(2), 1–7.
3. Tang YH, Yeung VH, Chu PS, Man CW. A 55-Year-Old Man with Right Testicular Pain: Too Old for Torsion?. *Urol Case Rep.* 2017;11:74-75. Published 2017 Feb 7. doi:10.1016/j.eucr.2016.11.023.

4. Visser AJ, Heyns CF. Testicular function after torsion of the spermatic cord. *BJU Int* 2003;**92**:200–3.
5. C. Yang, B. Song, J. Tan, X. Liu, G.H. Wei Testicular torsion in children: a 20-year retrospective study in a single institution *Scientific World Journal*, 11 (2011), pp. 362-368.
6. R. Witherington, T.S. Jarrell Torsion of the spermatic cord in adults *J Urol*, 143 (1990), p. 62.
7. BAH, O. R., ROUPRET, M., GUIRASSY, S., et al. Aspects cliniques et thérapeutiques de la torsion du cordon spermatique: étude de 27 cas. *Progrès en urologie*, 2010, vol. 20, no 7, p. 527-531.
8. M.J.S. Dennis, S.F. Fahim, P.T. Doyle Testicular torsion in older men *Br Med J (Clin Res Ed)*, 294 (6588) (1987 Jun 27), p. 1680
9. Cubillos J, Palmer JS, Friedman SC, Freyle J, Lowe FC, Palmer LS. Familial testicular torsion. *J Urol* 2011;**185**:2469–72.
10. Rabinowitz R. The importance of the cremasteric reflex in acute scrotal swelling in children. *J Urol* 1984; 132:89-90.
11. Bouchet A, Cuilleret J (1985) Anatomie topographique, descriptive et fonctionnelle, Tome IV. SIMEP, Paris.
12. G.T. Yusuf, P.S. Sidhu A review of ultrasound imaging in scrotal emergencies *J Ultrasound*, 16 (4) (2013), pp. 171-178.
13. Meria P et Brunet P. Torsion du cordon spermatique et des annexes testiculaires. *Encycl Méd Chir (Editions Scientifiques et Médicales Elsevier SAS, Paris, tous droits réservés)*, Techniques chirurgicales – Urologie, 41-415, 2000, 4 p.
14. Cummings JM, Boullier JA, Sekhon D, Bose K. Adult testicular torsion. *J Urol* 2002;167:2109–10.

UNDER PEE!