

Delayed bilateral pulmonary embolism six months after mild SARS-CoV-2 infection: A case report

Abstract

Introduction

Severe Acute Respiratory Syndrome Coronavirus 2 (SARS-CoV-2) has been one of the most globally impactful diseases. It has been associated with significant morbidity and mortality, particularly due to acute respiratory distress syndrome (ARDS) in the acute stage. Venous Thromboembolism (VTE), particularly pulmonary embolism is well associated in the acute stages. Occurrence after initial recovery remains a rare encounter.

Case Presentation

A 49-year-old previously healthy gentleman was admitted following an acute onset severe shortness of breath. On examination he was tachypneic, tachycardic with clear lungs on auscultation. He had a S1Q3T3 pattern on his ECG with elevated d-dimer. Computed Tomography Pulmonary Angiogram revealed bilateral pulmonary embolism. There were no risk factors for VTE other than a mild SARS-CoV-2 infection 6 months back with persistent low grade systemic inflammation. Malignancy and thrombophilia screening was negative.

Conclusion

This case report highlights the possibility of the pro-coagulopathy state caused by SARS-Cov-2 virus infection to persist for a prolonged period even following a mild clinical infection. It raises the concern regarding the need for prolonged anticoagulation even after recovering from the initial infection.

Keywords: Pulmonary embolism, embolus, SARS-CoV-2, enoxaparin, thrombophilia

Introduction

The COVID-19 pandemic was declared on 11th March 2020 by the World Health Organization (WHO). It was caused by the novel coronavirus, Sever Acute Respiratory Syndrome Coronavirus 2 (SARS-CoV-2). It has made a significant global impact since its emergence and caused significant morbidity and mortality all over the world.

Several cardiovascular and respiratory complications have been reported to be associated with this infection [1]. Both arterial and venous thrombosis have been reported with venous thromboembolism (VTE) being the more frequent one [2]. These complications were particularly seen in the acute illness specially amongst patients receiving Intensive Care Unit (ICU) care for Acute Respiratory Distress Syndrome

(ARDS). Delayed pulmonary embolism following discharge of patients with moderate COVID-19 pneumonia, not receiving ICU care, have rarely been reported [3]. Although interstitial pneumonia leading to potentially fatal ARDS remain the most concerning complication VTE has also being a significant problem to the medical units, combating this infection.

This case is unique in that the patient had only a mild SARS-CoV-2 infection which was uncomplicated and managed with home quarantine and no anti coagulation. He then developed a bilateral pulmonary embolism almost six months later which led to a cardio-respiratory arrest. VTE occurring so late after a mild infection has seldom been encountered in clinical practice. It questions the current recommendations regarding anticoagulation following discharge of these SARS-CoV-2 infected patients.

Case Report

A 49-year-old previously healthy male presented with a sudden onset severe shortness of breath. He had no fever or cough and denied any trauma to the chest. However, he did complain of a pleuritic type left sided chest pain. This has been present on and off for the last two weeks and was worse at the time of admission. Following admission, he developed a cardio-respiratory arrest and underwent cardiopulmonary resuscitation for five minutes after which he had spontaneous breathing. His post arrest period was uneventful. However, he continued to have pleuritic type chest pain and shortness of breath.

Retrospective history revealed that he had a SARS-CoV-2 infection six months back that was confirmed using an oropharyngeal swab for PCR. He was home quarantined and had fever, sore throat, a non-productive cough and a mild shortness of breath lasting for about one week. He has no other significant past medical or surgical history. He is a social drinker and consumes around 2 beers once a week. He denies smoking and recreational drug abuse. He denies any risky sexual activities. He had no family history of thrombophilia, malignancy or any auto immune disease. He had no history of prolonged immobility or trauma. He was unvaccinated for SARS-CoV-2.

After resuscitation he was still tachypneic. His saturation was 93% on air. Bilateral air entry was normal with no added sounds on respiratory examination. His blood pressure was 120/70 mmHg and he had a pulse rate of 110 per minute which was regular.

His blood investigations are listed in Table 1.

His chest X-ray was normal. ECG showed a S1Q3T3 pattern with a Right Bundle Branch Block and sinus tachycardia. Arterial Blood Gas revealed respiratory alkalosis. His wells score for pulmonary embolism was 4.5. A clinical suspicion of pulmonary embolism was made. He underwent a Computed Tomography Pulmonary Angiogram (CTPA) which showed pulmonary embolism in bilateral second order branching pulmonary arteries with small wedge infarctions in bilateral lower lobes (Figure 1). A Trans esophageal echo showed an ostium secundum atrial septal defect with no right atrial or right ventricular dilation. There was no evidence of pulmonary hypertension. Bilateral lower limb Duplex scan was negative for Deep

Table 1: Pathological test results

Vein Thrombi. Tumor markers for occult malignancy were negative. He underwent a full body Contrast enhanced CT scan which did not reveal any malignancies. Thrombophilia screening done 3 months later for antithrombin III, protein S, protein C were normal and negative for lupus anticoagulant, anticardiolipin, anti $\beta 2$ GPI antibodies, and factor V Leiden. His covid antibodies were positive with a SARS-CoV-2 total antibody titer >45 (Reactive). Oropharyngeal and Nasopharyngeal Swab PCR for SARS-CoV-2 were repeatedly negative at admission.

He was diagnosed with Bilateral Pulmonary Embolism secondary to past SARS-CoV-2 infection.

He was treated with Therapeutic doses of subcutaneous enoxaparin 1mg/kg twice a day. Warfarin too was started an adjusted to maintain INR 2-3. He had a good follow up and Warfarin was continued for 6 months and then stopped. He had no further complications of significance during follow up. He has been referred to the cardio thoracic unit for reassurance and follow up for the atrial septal defect.

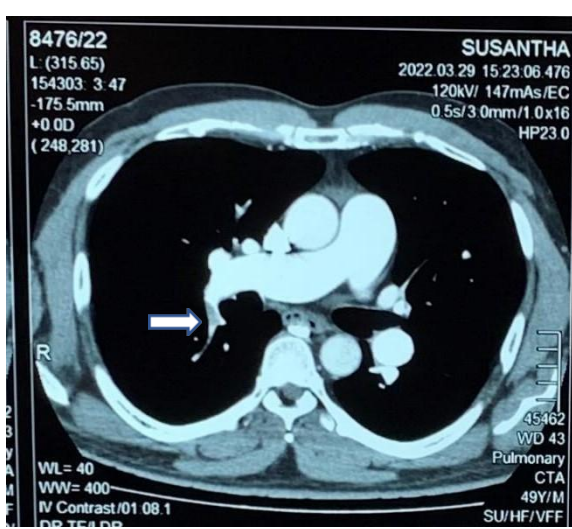


Figure 1

Figure 1: CT scan image

Arterial Blood Gas		
pO2 (mmHg)	75	(80–100)
pCO2 (mmHg)	25	(35–45)
pH	7.47	(7.35–7.45)
O2 saturation (%)	93	(>95)
Full Blood Count		
RBC ($\times 10^3/\text{mm}^3$)	4.84	(4.00–5.00)
Hb (g/dl)	14.9	(12.0–15.0)
Platelets ($\times 10^3/\text{mm}^3$)	256	(130–400)
Biochemical parameters		
D-dimer (mg/dl)	1560	(0–232)
Highly sensitive Troponin I (ng/dl)	0.012	(0.000–0.034)
C-reactive protein (mg/dl)	11.2	(<6)
ESR (mm/hour)	36	(<20)
Partial thromboplastin time (sec)	33	(30–40)
Prothrombin time (sec)	10.6	(9.5–13.8)
Occult cancer markers		
CEA	2.49	(0.0–5.0)
Ca 19-9	7.8	(0.0–37.0)
Alfa-fetoprotein	4.5	(<8.0)
PSA	0.12	(<2.5)
Thrombophilia markers		
Antithrombin III	96	(80–120)
Protein S	85	(75–130)
Protein C	82	(70–140)
Lupus anticoagulant	Absent	Absent
Anticardiolipin antibodies	0	(0–20)
Anti $\beta 2$ GPI antibodies	0	(0–20)
Factor V Leiden	Absent	Absent
SARS-CoV-2 markers		
PCR	Negative	
Antibody	Reactive	

Discussion

Sufficient evidence exists that SARS-CoV-2 could predispose patients to increased thrombotic disease in the venous and arterial circulations [4]. In a study of an ARDS population, 16.7% patients were diagnosed with pulmonary embolism [5]. Another study showed that screening by complete duplex ultrasound in 26 intensive care unit patients showed a peripheral VTE prevalence of 67% [6].

Previous studies show that most cases of VTE have been seen in critically ill patients during the acute infection [7]. Occasionally it has also been reported in mild SARS-CoV-2 infections usually within a few days after discharge [8]. Very few episodes of VTE occurred later but usually in the first 4 weeks after SARS-CoV-2 clearance [9]. Occurrences after the first 4 weeks were rarely encountered during literature review.

Several theories have come to explain the pro-thrombotic state during SARS-CoV-2 infection. Severe inflammation, hypoxia, endothelial dysfunction, platelet activation and stasis could be the reason for this pro-thrombotic state. Pulmonary microvascular thrombosis is probably due to extensive pulmonary damage involving alveoli and the pulmonary micro vessels [7]. Pulmonary embolism of larger vessels is presumably due to a combination of inflammation-mediated damage to systemic and pulmonary veins, systemic hypercoagulability and venous blood stasis in bedridden patients. This concept of pro-inflammatory state during the infection has led to widespread

use of immunosuppressive medication during acute infection.

This patient had residual systemic inflammation which was evident by the high inflammatory markers even six months after the acute infection. This could explain the reason behind his pro-thrombotic state that led to the pulmonary embolism. There have been reports of other immune mediated diseases including myasthenia gravis [10], and autoimmune myocarditis [11], occurring late after SARS-CoV-2 infection. This further supports that the residual inflammatory state could be the culprit. A new infection with SARS-CoV-2 was excluded in this patient due to the negative PCR results at admission.

Conclusion

SARS-CoV-2 infection both active and past should be considered as an important risk factor for both arterial and venous thrombosis. Physicians should always consider the possibility of thromboembolic phenomena amongst patients who have a history of SARS-CoV-2 infection, even though other risk factors for thrombophilia are absent. This case report particularly highlights the fact that an inflammatory state leading to a pro-thrombotic state could persist for as long as six months following an infection with SARS-CoV-2. This brings up the concern that anti-inflammatory agents and anti-coagulants may be of benefit for prolonged duration even amongst patient with mild infection.

Informed Consent

Informed written consent was obtained from the patient to publish details regarding the patient's condition including photographic evidence.

References

- [1] Driggin E, Madhavan MV et al. “Cardiovascular considerations for patients, health care workers, and health systems during the coronavirus disease 2019 (COVID-19) pandemic.” *J Am Coll Cardiol* 2020;75:2352–2371.
- [2] Klok FA, Kruip MJHA et al. “Incidence of thrombotic complications in critically ill ICU patients with COVID-19”. *Thromb Res* 2020;191:145–147.
- [3] Mohamad Kanso, Thomas Cardi, Halim Marzak et al. “Delayed pulmonary embolism after COVID-19 pneumonia: a case report” *European Heart Journal - Case Reports, Volume 4, Issue 6, December 2020, Pages 1–4*,
- [4] Bikdeli B, Madhavan MV, Jimenez D, Chuich T, Dreyfus I, Driggin E et al. “COVID-19 and thrombotic or thromboembolic disease: implications for prevention, antithrombotic therapy, and follow-up.” *J Am Coll Cardiol* 2020;75:2950–2973.
- [5] Llitjos J-F, Leclerc M, Chochois C et al. “High incidence of venous thromboembolic events in anticoagulated severe COVID-19 patients”. *J Thromb Haemost* 2020;18:1743–1746.
- [6] Poissy J, Goutay J, Caplan M et al. “Pulmonary embolism in patients with COVID-19: awareness of an increased prevalence.” *Circulation*. 2020;142(2):184–186.
- [7] Klok FA, Kruip M, van der Meer NJM et al. “Confirmation of the high cumulative incidence of thrombotic complications in critically ill ICU patients with COVID-19: an updated analysis”. *Thromb Res*. 2020;191:148–150.
- [8] Dutch COVID & Thrombosis Coalition. Kaptein FHJ, Stals MAM, Grootenboers M, Braken SJE, Burggraaf JLI, van Bussel BCT, et al. “Incidence of thrombotic complications and overall survival in hospitalized patients with COVID-19 in the second and first wave.” *Thromb Res*. 2021;199:143–148.
- [9] Vechi HT, Maia LR, Alves MDM. “Late acute pulmonary embolism after mild coronavirus disease 2019 (COVID-19): a case series.” *Rev Inst Med Trop Sao Paulo*. 2020;62:e63
- [10] Assini A, Gandoglia I, Damato V, Rikani K, Evoli A, Del Sette M. “Myasthenia gravis associated with anti-MuSK antibodies developed after SARS-CoV-2 infection”. *Eur J Neurol*. 2021;28(10):3537–3539.
- [11] Nicol M, Cacoub L, Baudet M, Nahmani Y, Cacoub P, Cohen-Solal A, et al. “Delayed acute myocarditis and COVID-19-related multisystem inflammatory syndrome.” *ESC Heart Fail*. 2020;7(6):4371–4376

