

EFFECT OF *Decryodes edulis* (AFRICAN BLACK PEAR) AQUEOUS LEAVES EXTRACT ON LIVER ENZYME MARKERS OF ACETAMINOPHEN-INDUCED HEPATOTOXICITY IN WISTAR RATS

ABSTRACT

Aim: This study investigated the effect of aqueous extract of *Dacryodes edulis* (African Black Pear) on liver enzyme markers associated with acetaminophen-induced hepatotoxicity. **Method:** Qualitative phytochemical screening was done on the aqueous leaves extract of *D. edulis* and *in vivo* experiment was carried out afterwards. 20 adult male Wistar rats were used which were randomized into 5 groups of 4 rats each. Group 1 served as the positive control and were fed with rat pellets and water only, Group 2 served as acetaminophen control and were fed with rat pellets and water and then treated with 2g/kg acetaminophen only, Group 3, 4 and 5 was served 2g/kg acetaminophen and treated with 100mg/kg, 150mg/kg and 200mg/kg of stock solution of the plant extract in addition to rat pelleted feed and water *ad libitum*. The experimental process lasted for 14 days after which blood samples were collected for liver enzyme assay. Alanine aminotransferase (ALT), asparatate aminotransferase (AST) and alkaline phosphatase (ALP) were assayed using Randox Kits. **Results:** Result obtained revealed that aqueous extract of *Dacryodes edulis* significantly ($p < 0.05$) reduced acetaminophen hepatotoxicity at a dose dependent rate evident by the reduction in the levels of AST, ALT, ALP, Urea and creatinine. **Conclusion:** The result showed the hepatoprotective effect of *Dacryodes edulis* against toxicity induced by acetaminophen induction in the liver and this is due to the phytochemicals present in the leaf part of *Dacryodes edulis*. Hence, *Dacryodes edulis* has hepatoprotective potential against acetaminophen liver damage.

Key Words: *Decryodes edulis*, Aqueous leaves extract, Liver enzyme markers, Acetaminophen, Hepatotoxicity, Phytochemicals

INTRODUCTION

To maintain metabolic balance in higher organisms, the liver is the primary organ that metabolizes xenobiotics and endogenous chemicals. As a result, the liver is the target of several metabolic assaults, which can lead to altered homeostasis and hepatic disorders [1]. Acetaminophen has excellent antipyretic properties, is a moderate analgesic, and is almost anti-inflammatory. It works by suppressing prostaglandin synthesis via the cyclo-oxygenase 3 enzyme (a cox-1 enzyme alternative product) [2]. “Its metabolism takes place at the microscopic level within liver microsomes. Acetaminophen hepatotoxicity is caused by the hazardous NAPQI (N-acetyl-para-benzo-quinone imine) metabolite, which is caused by mitochondrial malfunction and results in adenosine triphosphate (ATP) depletion. Other hepatotoxic mechanisms include the formation of toxic free radicals like peroxynitrite from the reaction of superoxide and nitric oxide, which then form nitrotyrosine adducts inside the mitochondria” [3].

Dacryodes edulis is a dioecious shade-loving species native to the humid tropical zone's non-flooded woodlands. It is a medium-sized evergreen tree that grows to 18-40 meters in the forest but no higher than 12 meters in plantations [4,5,6]. “It has a modest branching structure and a dense crown. The bole has a diameter of 50-170cm, is short, shallowly fluted, and is more or less sinuous. The bark is yellowish-grey to pale-grey in colour, and it is often rough, with lenticels and horizontal folds that secrete white aromatic resin. The leaves are complex, imparipinnate, and have 5-8 leaflets. They are shiny and pubescent, with the pubescence fading as they get older” [6,7].-“They are oblong-lanceolate to ovate-lanceolate, up to 20 (-30) x 6 (-8)cm in size, generally cuneate to rounded at the base, and asymmetric. They have an acuminate apex and an

entire, glabrescent border. Flowers are unisexual, subtended, three lobed, and showy, with a caducous low bract” [6,7].

The fruit of *D. edulis* var. *edulis* in Nigeria is enormous, elongated, and cylindrical, measuring more than 5x2.5cm. The fruit pulp is thick, ranging from 3.5 to 9 mm in thickness. The branchlets are usually strong and ascending, and the tree has whorled branching. The fruit of *D. edulis* var. *parvicarpa*, on the other hand, is small, spherical or conical, and usually smaller than 5x2.5cm. The fruit pulp is very thin, measuring roughly 2-3.5mm thick. The tree's branching is frequently bifurcate, with slender, drooping branchlets[8]. The fruits are edible, and the bark, leaves, stem, and roots have all been used to treat various ailments [9]. Its phytochemical richness, which includes saponins, alkaloids, flavonoids, and tannins, has been cited to explain its ability to treat a wide range of skin ailments and inflammation [10]. DE extracts have also been shown to have antimicrobial, anti-sickle cell anemia, and antioxidant properties [11]. Other biochemical research on various components of DE has been conducted. The leaves of DE were shown to have extremely strong antioxidant activity in one study due to their flavonoid concentration [12]. Medicinal plants are thought to be a readily available and potent source of antioxidants because they contain a variety of chemical components that can work individually or in concert to treat disease and promote health [13].

“Bioactive compounds produced by medicinal plants are mostly employed for medical purposes. These substances act on several systems in animals, including humans, and interfere with the metabolism of bacteria that infect them. Pathogenic or symbiotic microorganisms are possible. In any case, medicinal plant bioactive compounds play a critical role in regulating host-microbe interactions in the host's favor. As a result, it is critical to identify bioactive components in plants, as well as isolate, purify, and characterize active substances in crude extracts using

various analytical approaches. The antioxidant, antibacterial, and antipyretic actions of phytochemicals in plants could explain their therapeutic qualities” [14,15]. “Medicinal plants have a promising future since there are around half a million plants on the planet, and the majority of their medicinal properties have yet to be discovered. Their medical properties could be crucial in the treatment of current or future studies” [16]. The goal of this study was to see if acetaminophen affected biochemical parameters linked to hepatotoxicity in Wistar rats, as well as to see if *Dacryodes edulis* had a therapeutic effect on liver toxicity.

MATERIALS AND METHODS

All procedures carried out during this research were done in accordance with the guiding principles of research involving animals as recommended by the Research Ethics Committee of the University of Port Harcourt. Animals were kept in standard metal cages and at normal room temperature.

Procurement of Animal

Twenty (20) male albino rats weighing 150 to 210g were used for this study and were obtained from Animal House of Department of Pharmacology, University of Port Harcourt, River State, Nigeria and acclimatized for 2 weeks. The animals were maintained before and throughout the experiment period in standard cages with access to clean water and food (pellets) *ad libitum* under standard environmental conditions (temperature: $27.0 \pm 1.0^\circ$, relative humidity: 55-65% and 12 hours light/12 hours dark cycle). At the start of the experiment, the animals were randomly distributed into 5 groups of 5 animals each.

Plant collection

The leaves of the plant *Dacryodes edulis* were collected from Chobain Obio/Akpor Local Government Area of Rivers State and identified in the herbarium of the Department of Plant Science and Biotechnology in the University of Port Harcourt by Dr. Chimezie Ekeke of the Department of Plant Science and Biotechnology.

Plant Preparation and Extraction

The leaves of plant *Dacryodes edulis* were washed with clean water in the Biochemistry Laboratory. They were then allowed to air dry for 4 weeks after which the leaves were ground into fine powder using an Electric Blender. 20g of the ground powdered leaves was soaked in a solution containing 200ml of distilled water. The mixture was agitated for 5 minutes after which it was left to stand for 24 hours at room temperature before filtering with a clean Whatman No.1 filters paper. The filtrate was stored in the refrigerator and then 100m/kg, 150mg/kg and 200mg/kg dilutions were prepared from the stock.

Phytochemical Screening of *Dacryodes edulis* Leaves

Harbone's[17] methodologies were used to undertake the qualitative investigation of phytochemical components. The appearance of different colors and the production of precipitates or products in the final solution were used to conduct these phytochemical analyses.

Analysis of Alkaloids: Alkaloids were determined by placing 0.1g of the aqueous extract in a test tube containing 3mL of hydrochloric acid (50 percent V/V). Three drops of Mayer's reagent

were added to the solution, and the formation of a white precipitate showed the presence of alkaloids.

Phenol Analysis: For phenol analysis, 0.1g of the aqueous extract was dissolved in 3mL of ethanol. The solution was treated with 3 drops of iron (III) chloride 10% (V/V), and the presence of phenols was determined by the emergence of a blue-violet tint.

Analysis of Flavonoids: Flavonoids were determined by adding a few drops of 1% NH_3 solution to 0.1g of aqueous extract in a test tube. The presence of flavonoid compounds was suggested by the emergence of a yellow tint.

Analysis of Sterol and triterpenoids: They were determined by dissolving 0.1g of the aqueous extract in 3mL of chloroform. Three milliliters of acetic anhydride were added, and the solution was frozen for three minutes. A drop of strong sulfuric acid was added to the solution. Triterpenoid presence was confirmed by the formation of a red-violated hue, whereas sterol content was indicated by the appearance of blue, green, red, and orange colors in that order.

Analysis of Tannins: Tannins were identified by boiling 0.1g of the aqueous extract in 20mL of distilled water in a test tube and then filtering it. The standard filtration process is utilized here, which includes a conical flask and filter paper. Three drops of 0.1 percent FeCl_2 were added to the filtered samples, and the presence of tannins was determined by looking for a brownish green or blue black tint.

Saponin analysis: Two grams of powdered plant samples were cooked in a water bath with 20mL of distilled water and filtered. In a test tube, 10mL of filtered sample was combined with 5mL distilled water and aggressively shaken to generate a stable, persistent froth. The foam was then combined with three drops of olive oil and examined for the creation of an emulsion, which demonstrates saponin presence.

Experimental Design

Twenty (20) male adult Wistar rats were used and were randomly selected into five groups of 4 rats each. Group 1 served as the positive control, with mean weight of 165g and they were fed with rat pellets and water only. Group 2 served as acetaminophen control with mean weights of 170g and they were fed with rat pellets and water and then treated with 2g/kg acetaminophen only. Group 3 was induced with 2g/kg acetaminophen and treated with 100mg/kg of stock solution of the plant extract in addition to rat pelleted feed and water *ad libitum*, with mean weight of 175g. Group 4 was induced with 2g/kg acetaminophen and treated with 150mg/kg of the plant extract, with mean weight of 175g and Group 5 was induced with 2g/kg acetaminophen and treated with 200mg/kg of the stock solution of the plant extract with mean weight of 140g. Acetaminophen 2g/kg was administered to all the groups except control followed by the plant extract of varying dosages (100mg/kg, 150mg/kg and 200 mg/kg) to all the groups except acetaminophen control group (acetaminophen only) for a period of 14days [18]. Toxicological study of aqueous extract of *Dacryodes edulis* leaves according to Chimaobi *et al.* [19] revealed that the median lethal dose (LD_{50}) was greater than 5000mg/kg body weight. This justifies the use of 100mg/kg, 150mg/kg and 200mg/kg for in this study.

Collection of Blood samples and Organs

After 14 days of treatment, the rats were fasted for 12 hours and anaesthetized with chloroform before they were sacrificed. Blood samples were collected into lithium heparin bottles by direct cardiac puncture while organs were collected into lithium heparin bottles containing formalin. The blood and tissue samples were taken to the chemical pathology laboratory of University of Port Harcourt Teaching Hospital (UPTH), Rivers State, Nigeria for analyses.

Biochemical Assay

Biochemical markers such as Aspartate transaminase (AST), Alanine transaminase (ALT), Alkaline phosphatase (ALP), Creatinine and Urea were determined using Randox Kits. ALT was measured by the monitoring of the concentration of pyruvate hydrazone formed with 2,4-dinitrophenylhydrazine. AST was measured by monitoring the concentration of oxaloacetate hydrazone formed with 2,4-dinitrophenylhydrazine [20]. ALP activity was measured at 37°C as according to Haussament[21]. The absorbance of p-nitrophenol formed from p-nitrophenylphosphate was determined at 405nm and calculation of enzyme unit followed as described by the kit manufacturer. Creatinine in alkaline solution reacts with picric acid to form a coloured complex. The amount of the complex formed is directly proportional to the creatinine concentration. Urea in serum is hydrolyzed to ammonia in the presence of urease. The ammonia was then measured photometrically by Berthelot's reaction.

Method of Data Analysis

Data were analyzed using SPSS version 23.0. All data obtained were expressed as Mean \pm SD. One-way analysis of variance (ANOVA) was used to compare the means between and within the

groups and a p -value <0.05 was considered significant. A Tuckey's post-hoc test was also applied to assess significant differences between groups.

RESULTS

Table 1: Result of Qualitative phytochemical analysis of the aqueous extract of *D. edulis* leaves

Phytochemicals	Qualitative remarks
Alkaloids	+
Phenols	+
Flavonoids	+
Sterols	-
Triterpenoids	+
Tannins	+
Saponins	+

+ = detected; - = not detected

Table 2: Effect of Aqueous leaves extract of *Dacryodes edulis* on Liver Enzymes Biomarkers of Acetaminophen-induced Liver toxicity in Wistar rats

Group	AST (IU/L)	ALT (IU/L)	ALP (IU/L)
Positive Control	10.75±0.50	8.00±0.81	134.6±3.02
ACET Control	51.50±3.41*	47.00±3.82*	255.4±2.46*
100mg/kg DE	40.38±5.12*#	39.25±2.75*#	228.8±4.25*#
150mg/kg DE	35.50±1.29*#	33.75±2.21*#	194.2±5.27*#
200mg/kg DE	29.75±1.70*#	29.25±5.90*#	168.9±4.12*#

Each value represents mean±SD, values marked with (*) differ significantly from positive control (1ml of Water) value (*p<0.05) while those marked with (#) differ significantly from acetaminophen control group (#p<0.05). **ACET** = Acetaminophen, **DE** = *Dacryodes edulis* Extract

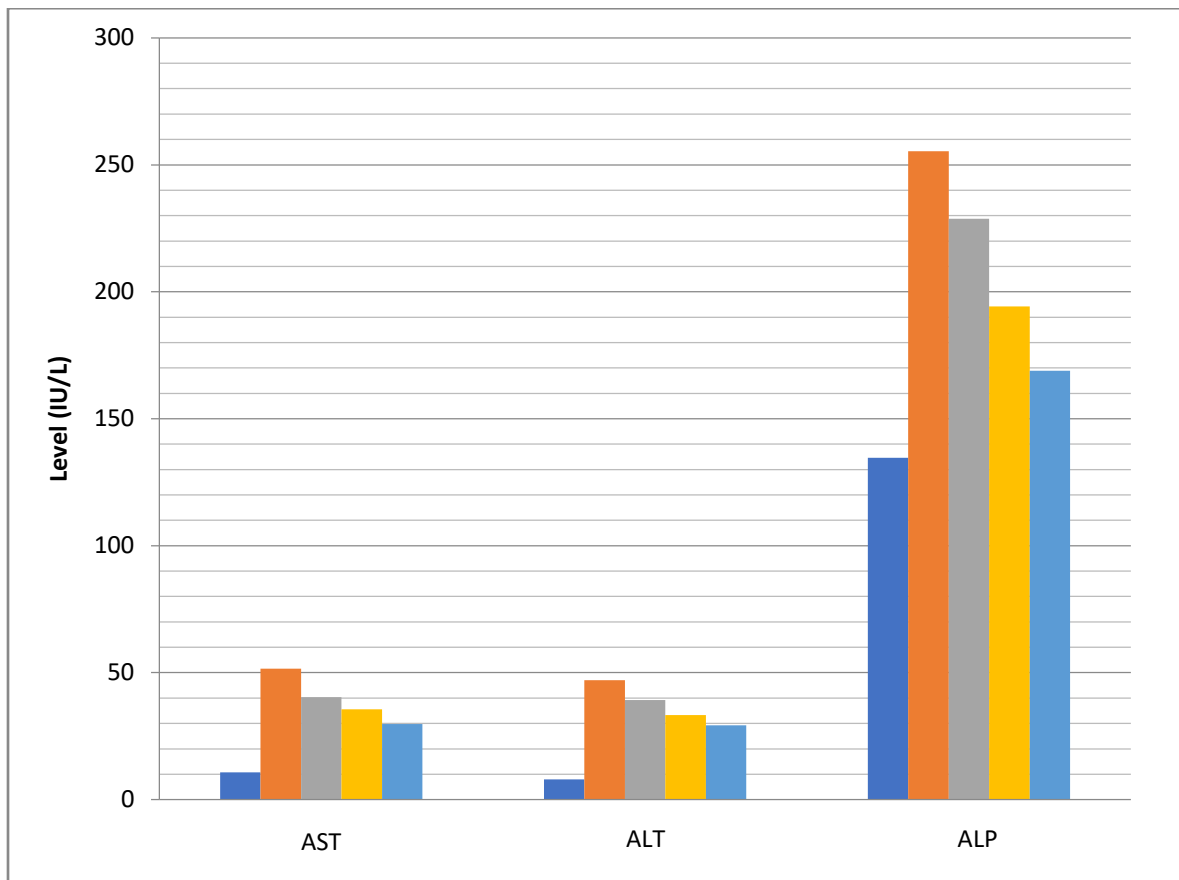


Figure 1: Effect of aqueous leaves extract of *Dacryodes edulis* on AST, ALT, Urea and Creatinine levels in Acetaminophen-induced Liver toxicity in Wistar rats

DISCUSSION

“Plant medicines play important role by their various formulations for the treatment of various diseases. However some have been analyzed and scientifically validated for their potentials.

Here, we designed the experiments to examine the hepatoprotective activity of aqueous leaves extract of *Dacryodes edulis* for its development into safe natural drug candidate” [22].

Acetaminophen is a commonly used antipyretic that is safe at therapeutic amounts but can induce fatal liver damage in humans and animals at higher toxic levels. Acetaminophen is widely consumed as antipyretic drug that is safe in therapeutic doses but can cause fatal hepatic damage in human and animal at higher toxic doses. Acetaminophen toxicity is widely believed to involve

the generation of reactive oxygen species (ROS) oxidative stress resulting from the acetaminophen toxicity which plays a role in liver damage. “Bioactivation of acetaminophen by hepatic cytochrome P-450 leads to formation of a highly reactive and toxic metabolite N-acetyl-p-benzoquinone imine (NAPQI). NAPQI is normally detoxified by conjugation with reduced glutathione (GSH) to form mercapturic acid which is excreted in urine. Toxic overdose of acetaminophen depletes hepatic GSH content so that free NAPQI binds covalently to cellular mitochondrial proteins which suppresses mitochondrial fatty acid β -oxidation and results in massive necrosis and apoptosis of hepatocytes” [23,24]. “An obvious sign of hepatic injury is the leaking of cellular enzymes such as ALT, AST and ALP into plasma due to the disturbance caused in the transport functions of hepatocytes. ALT is more specific to the liver, and it is a better parameter for analyzing hepatic injury. High levels of AST indicate the cellular leakage as well as loss of functional ability of cell membrane in liver. Serum ALP is also related with liver cell damage. High concentration of ALP cause serious hepatic damage in paracetamol treated rats” [25]. “The liver is the major source of most of the serum proteins. Bilirubin is a product of heme within the reticuloendothelia system; its elevation in the blood stream can be adduced to over production, increased hemolysis, decreased conjugation or impaired bilirubin transport.

[26]-Bilirubin is an index that is used to assess the normal functioning of the liver instead of the extent of hepatocellular injury” [26].

The phytochemical screening of aqueous leaves extract of *Dacryodes edulis* revealed the presence of phytochemical constituents such as alkaloids, phenols, flavonoids, triterpenoids, tannins and saponins. Okwu and Nnamdi [10], Ajobesin [11] and Kamgaing *et al.* [27] in their studies also reported that *Dacryodes edulis* to be rich in phytochemical and bioactive constituents such as saponins, alkaloids, tannins, flavonoids, phenolic compounds, carbohydrates, lipids and protein contents and vitamins such as ascorbic acid, niacin, riboflavin and thiamine [10]. The mechanism of hepatoprotection by aqueous leaves extracts of *Dacryodes edulis* is due to the presence of these phytochemical and bioactive constituents. This shows that

leaf extracts can lower ROS, reducing oxidative damage to hepatocytes and increasing the activity of liver antioxidant enzymes, protecting the liver from acetaminophen-induced damage.

~~This suggests that leaf extracts can reduce ROS that may lessen the oxidative damage to the hepatocytes and improve the activities of the liver antioxidant enzymes, thus protecting the liver from acetaminophen induced damage.~~

In the present study, results obtained revealed (as presented in Table 2 and figure 1) that the administration of acetaminophen to group 2 (acetaminophen control) experimental animals resulted to adverse acetaminophen toxicity in the experimental animals. This was indicated by the increase in AST, ALT and ALP levels when compared with the positive control group. *Dacryodes edulis* extract significantly ($p < 0.05$) reduced the blood levels of AST, ALT and ALP when compared with the acetaminophen control. This decrease in levels of AST, ALT and ALP was dose dependent. The reduction in the levels of AST, ALT and ALP proves the protective effect and restoration of the liver integrity which was affected by the lesion caused by

acetaminophen induction. This effect can be traced to the presence of phytochemical constituents which has antioxidants properties in the leaf parts of *Dacryodes edulis*. “The presence of bioactive compounds such as saponins, tannins, alkaloids and flavonoids identified in the plant has been suggested to be responsible for the various uses of *D. edulis* in traditional medicine to treat inflammatory disease” [10]. “In addition, the potential health-related functions of dietary plants were found to include antibiosis, immunostimulation, nervous system action, detoxification, anti-inflammatory, antigout, antioxidant, glycemic and hypolipidemic properties” [28]. This supports the finding of this study as *Dacryodes edulis* was able to reduce toxicity from acetaminophen induction in the liver. The study agrees with the findings of Eidangbe *et al.* [29] who studied the Attenuation of carbon tetrachloride - induced hepatotoxicity by *Dacryodes edulis* seeds ethanolic extract in male Wistar rats and discovered that there were remarkable improvements in serum levels of hepatic function indicators and opined the possible ameliorative potential of *D. edulis* ethanolic seed extract against CCl₄-induced hepatic injury. It also conforms to the study by Orhue *et al.* [30] who carried out “a study on prevention of carbon tetrachloride-induced hepatic steatosis and cellular damage by aqueous extract of *Dacryodes edulis* seeds in Wistar rats and revealed that the extract possesses hepatoprotective properties due to the reduction in the activities of the enzymes alanine transaminase (ALT), aspartate transaminase (AST) and alkaline phosphatase (ALP) in the plasma of the animals treated with the plant extract when compared to the group administered CCl₄ only”.

CONCLUSION

This study has demonstrated the hepatoprotective effect of the leaves of *Dacryodes edulis* (African black pear). It was demonstrated that the administration of the leaves of *Dacryodes edulis* can significantly reduce enzyme biomarkers of liver injury.

Ethical Approval:

All procedures carried out during this research were done in accordance with the guiding principles of research involving animals as recommended by the Research Ethics Committee of the University of Port Harcourt.

REFERENCES

1. Casas – Grajales, S. and Muriel, P. (2015). Antioxidants in Liver health. *World Journal of Gastrointestinal Pharmacology and Therapy*, 6(3): 59-72.
2. Ibrahim, T., Agnihotri, S., & Agnihotri, A.K. (2013). Paracetamol Toxicity-An overview. *Emergency Medicine*, 3: 158.
3. Yoon, E., Babar, A., Choudhary, M., Kutner, M., & Pysopoulos, N. (2016). *Journal Clinical Transplant and Hepatology*, 4(2): 131-142.
4. Hutchinson, J. and J.M. Dalziel (1958). Flora of West Tropical Africa. Vol. 1, Crown Agents for Overseas Government, London, pp: 763
5. Burkill, H.M. (1985). The Useful Plants of West Tropical Africa. Vol. 1, Royal Botanic Gardens, Kew, ISBN: 094764301X, pp: 960
6. Verheij, E.W.M. (2002). *Dacryodes edulis* (G.Don) H.J.Lam. [Internet] Record from PROTA4U. Oyen, L.P.A. & Lemmens, R.H.M.J. (Editors). PROTA (Plant Resources of Tropical Africa / Ressources végétales de l’Afrique tropicale), Wageningen, Netherlands. Available via: <http://www.prota4u.org/search.asp>, Accessed 7th December, 2021.

7. Medenbach de Rooy, J.M. (1994). The biodiversity of African plants. Proceedings of the 14th AETFAT Congress, 22-27 August , Wageningen, Netherlands, Aug. 22-27, Kluwer Academic Publishers, Dordrecht, Netherlands, pp: 684-695
8. Okafor, J.C. (1983). Varietal delimitation in *Dacryodesedulis* (G. Don) H.J. Lam (Burseraceae). *Int. Tree Crops J.*, 2: 255-265
9. Waruhiu, A.N., J. Kengue , A.R. Atangana, Z. Tchoundjeu and R.R.B. Leakey, (2004). Domestication of *Dacryodesedulis*: 2. Phenotypic variation of fruit traits from 200 trees from four populations in the humid lowlands of Cameroon. *J. Food Agric. Environ.*, 2: 340-346.
10. Okwu, D.E. and F.U. Nnamdi, (2008). Evaluation of the chemical composition of *Dacryodesedulis* sp. check for this species in other resources and raphiahookerimann and wendl exudates used in herbal medicine in South Eastern Nigeria. *Afr. J. Tradit. Compl. Altern. Med.*, 5: 194-200
11. Ajibesin, K.K. (2011) *Dacryodesedulis* (G. Don) H. J. Lam: A Review on Its Medicinal, Phytochemical and Economic Properties. *Research Journal of Medicinal Plants*, 5, 32-34.
12. Agbor, G.A., D. Kuate and J.E. Oben (2007). Medicinal plants can be good source of antioxidants: Case study in Cameroon. *Pak. J. Biol. Sci.*, 10: 537-544.
13. Bhatt, I.D, Rawat, S., &Rawal, R.S. (2013). Antioxidants in Medicinal plants. *Biotechnology for Medicinal plants – Micropropagation and Improvement*, pp. 295 – 236
14. Cowman, M.M. (1999). Plant products as antimicrobial agents. *Clinical Microbiology Review*, 12: 564-582.
15. Adesokan, A.A., Yakubu, M.T., Owoyele, B.V., Akanji, M.A., Soladoye, A., &Lawal, O.K. (2008). Effect of administration of aqueous and ethnolic extracts of *Enantiachlorantha* stem bark on brewer's yeast-induced pyresis in rats. *African Journal of Biochemical Research*, 2(7): 165-169.
16. Singh, R. (2015). Medicinal Plants: A Review. *Journal of Plant Sciences*. Special Issue: Medicinal Plants, 3(11): 50-55
17. Harbone, J.B. (1998). *Phytochemical Methods: A Guide to Modern Techniques of Plant Analysis*. Springer Science and Business Media, Berlin, Heidelberg, 3rd Edition.
18. Chimaobi J. Ononamadia, Adamu J. Alhassan, Aminu Ibrahim, Abdullahi A. Imam, Godwin O. Ihegboroa, Alowonle T. Owolarafea, Obiajulu C. Ezeigwe, Mohammed K.

- Atiku, Mohammed S. Sule. Toxicological study of aqueous-methanol solvent fraction of methanol extract of *Dacryodes edulis* leaves. *Toxicology Reports*, 2020, 7, 909-918
19. Olaleye, M.T., Adegboye, O.O. and Akindahunsi, A.A. *Alchornea cordifolia* Extract Protects Wistar Albino Rats against Acetaminophen-Induced Liver Damage. *African Journal of Biotechnology*, 2006, 5, 2439-2445
 20. Ibekwe, S.E., Uwakwe, A.A., & Monanu, M.O. (2007). *In vivo* effects of sodium benzoate on plasma AST and ALP of wistar albino rats. *Scientific Research & Essay*, 2(1): 010-012.
 21. Haussament, TU (1977). Quantitative determination of serum alkaline phosphatase. *Clin. Chem. Acta.*, 35: 271-273.
 22. Abirami, A., Nagarani, G., Siddhuraju, P. (2015). Hepatoprotective effect of leaf extracts from *Citrus hystrix* and *C. maxima* against paracetamol induced liver injury in rats. *Food Science and Human Wellness*. DOI: <http://dx.doi.org/10.1016/j.fshw.2015.02.002>
 23. Chen, C., Krausz, K.W., Shah, Y.M., Idle, J.R., Gonzalez, F.J. *et al.* (2009). Serum metabolomics reveals irreversible inhibition of fatty acid beta-oxidation through the suppression of PPAR alpha activation as a contributing mechanism of acetaminophen-induced hepatotoxicity. *Chem Res Toxicol.*, 22: 699–707.
 24. Bhattacharyya, S., Pence, L., Beger, R.D., Chaudhuri, S., McCullough, S.S., Kan, Y., Simpson, P.M., Hennings, L., Hinson, J.A., James, L.P. *et al.* (2013). Acylcarnitine profiles in acetaminophen toxicity in the mouse: comparison to toxicity, metabolism and regeneration. *Metabolites*, 3: 602-622.
 25. Darbar, S., A. Bhattacharya, S. C S. Darbar, A. Bhattacharya, S. Chattopadhyay, *et al.* (2011). Antihepatoprotective potential of livina, a polyherbal preparation on paracetamol induced hepatotoxicity: a comparison with 395 silymarin. *Asian J Pharm Clin Res* 4(1): 72–77.
 26. Sasidharan, S., Aravindran, S., Latha, L.Y., Vijenthil, R., Saravanan, D., Amutha, S. *et al.* (2010). *In vitro* antioxidant activity and hepatoprotective effects of *lentinula edodes* against paracetamol induced hepatotoxicity. *Molecules*. 15(6) 4478-448
 27. Kamgaing, Marius Tre´sor Wego, Marie Alfrede Mvondo, Sylviane Laure Poualeu Kamani, Ste´phane Minko Essono, and Sylvie Lea Wansi Ngnokam (2020). The Aqueous Extract of *Dacryodes edulis* (Burseraceae) Leaves Inhibits Cell Proliferation Induced by Estradiol

on the Uterus and Vagina of Ovariectomized Female Wistar Rats. *Hindawi, Advances in Pharmacological and Pharmaceutical Sciences*. DOI: <https://doi.org/10.1155/2020/8869281>

28. Johns, T. (2001). Dietary, diversity, global change and human health. Proceedings of the Symposium Managing Biodiversity in Agricultural Ecosystems, Nov. 8-10, Montreal, Canada, pp: 1-11
29. Eidangbe, George O., Ikechukwu O. Obasi, Antoinette C. Okaka, Rachel C. Eidangbe, Olarewaju M. Oluba (2021). Attenuation of Carbon Tetrachloride - Induced Hepatotoxicity by *Dacryodesedulis* Seeds Ethanolic Extract in Male Wistar Rats. *Biointerface Research in Applied Chemistry*; Volume 11, Issue 2: 9490 - 9500 DOI: <https://doi.org/10.33263/BRIAC112.94909500>
30. Orhue, N. E. J., Adaikpoh, M. A., Odude, O. and Iseghohi, S. O. (2015). Prevention of Carbon Tetrachloride-induced Hepatic Steatosis and Cellular Damage by Aqueous Extract of *Dacryodesedulis* Seeds in Wistar Rats. *Bio-Research*, 13: 885 – 888