

Evaluation of ocular findings in vitiligo

Abstract

Vitiligo is a pigmentary disorder of the skin and mucous membranes with world-wide incidence of 0.5-2% of population. Our aim in this cross sectional study of vitiligo was to assess the ocular involvement in this disease. Two hundred patients of clinically diagnosed vitiligo attending vitiligo clinic, dermatology department, Jomhorya hospital, Benghazi-Libya over a period of 6 months were enrolled in this cross sectional study. All patients were exposed to detailed disease history and thorough dermatological examination. Out of the total cases, 100 patients had a standard Ophthalmologic examination in cooperation with ophthalmologist in Benghazi eye hospital. Results of our study showed a slightly higher prevalence of vitiligo in female (male : female ratio 1:2.8), the mean age of onset for males was 22.4 years and for females was 24.8 years and 58.5% of patients develop vitiligo below 20 years of age. Generalized vitiligo was the commonest clinical type of vitiligo (57.5%). The relationship between the duration of the disease and its type was statistically significant ($P < 0.05$), there was also significant relationship between the type of vitiligo and its severity ($P < 0.01$). Sixteen patients (8%) had segmental vitiligo and the face was the common site involved. The lower limbs were the most commonly affected sites of the body (57%). Ocular changes were seen in 40% of patients and specific ocular abnormalities like uveitis, iritis, and iris and retinal pigmentary abnormalities are present in 15% of patients, non-specific ocular abnormalities were present in 33% of patients. There was no statistically significant correlation between specific ocular abnormalities and the disease severity and duration.

Key words : vitiligo, segmental vitiligo, autoimmune, uveitis

Introduction

Vitiligo is a common, acquired autoimmune disorder presented by milky-white macules and patches. It is a relatively common disease and studies have demonstrated an incidence of 0.14% to 8.8% (the likely incidence is between 0.5-2%) (1,2). The disease affects all races and both sexes equally; the higher female prevalence can be attributed to greater concern about a cosmetic defect (1). It appears to be more commonly observed in sun – exposed areas and in darker skin types. About 85% of patients tan well and only 15% sun burn in constitutively normal skin (2,3). Vitiligo may develop at any age; onset has been reported from birth to 81 years of age. Congenital vitiligo is very rare and the peak age of onset was between 10 and 30 years; in 50% of cases, the age of onset fell within the first two decades of life (1, 3, 4). Vitiligo patients normally have no ophthalmologic complaints, but may have iris and retinal pigmentary abnormalities, choroidal abnormalities and iritis (5,6). Uveitis also rarely occurs but visual acuity is normally unaffected (7). The aim of this cross sectional study is to justify some epidemiologic data of vitiligo and to assess the ocular involvement and its relation to the disease severity.

Patients and methods

Comment [PD1]: Include Vogt-Koyanagi Harada Syndrome, melanine

Comment [PD2]: I suggest to mention the Vogt -Koyanagi -Harada syndrome because vitiligo is one of the signs as poliosis (white eyebrush)

Two hundred patients of clinically diagnosed vitiligo of both sexes and different clinical types, attending vitiligo clinic, dermatology department, Jomhorya hospital, Benghazi-Libya over a period of six months. All patients included in this study were exposed to detailed disease history and thorough dermatological examination according to the prepared Performa. Out of 200 patients included in this study, 100 patients had a standard ophthalmologic examination including the visual acuity, examination of the anterior segment of the eye with slit lamp and examination of the ocular fundi by ophthalmoscope in cooperation with ophthalmologist in Benghazi central eye hospital. Statistical analysis was performed using SPSS for Windows (version 0.9). The significance of observed associations and / or differences between variables was tested using Pearson correlation (test of significant two-tailed). A difference was considered to be statistically significant if $P < 0.05$ and $P < 0.01$.

Results

Dermatological findings: Out of 200 vitiligo cases, 53 were males (27%) and 147 (73%) were females, with male to female ratio 1: 2.8. The patient's age ranged from 1-75 years, the mean age being 28.6 years. The mean age of onset for males was 22.4 years and for females was 24.8 years. The earliest age at onset was found at neonatal period (one case) and oldest was 75 years, with mean age of onset 21.2 years, and 58.5% of our patients develop vitiligo below 20 years of age. Female were predominantly involved in all age groups. In 93 patients (46.5%) the duration of the disease was 1-5 years, whereas in 69 patients (34.5%) the duration was >5 years. Ninety one patients (45.5%) showed mild vitiligo, and in 46.5% of patient, the duration of the disease was ranging from 1-5 years, 27% of them showed mild form of the disease (Table -1). There was significant correlation between the duration of the disease and its severity ($P < 0.01$). Vitiligo was predominantly nonsegmental (92%). Generalized vitiligo (57.5%) was the commonest clinical type in our study (Fig.1)(Fig.2) whereas segmental vitiligo was seen in 16 patients (8%)(Fig.3). The relationship between the duration of the disease and its type, was statistically significant ($P < 0.05$), there was also significant relationship between the type of vitiligo and its severity ($P < 0.01$).

Ocular findings: Out of the total vitiligo patients, 100 patients had complete ocular examination, and our results showed that 40 patients (40%) had eye manifestations. Non-specific ocular abnormalities like visual acuity defects, cataract, allergic conjunctivitis, dacryocystitis, and diabetic retinopathy were present in 33 patients (Table-2). Fifteen patients (15%), 13 females and 2 males had specific ocular abnormalities like uveitis, iritis, and iris and retinal pigmentary abnormalities (Fig.2,3). Out of these 15 patients, 7 patients had generalized vitiligo, 7 patients had localized vitiligo and one patient had vitiligo universalis, this difference was statistically non significance ($P > 0.01$). The duration of the disease in patients with specific ocular abnormalities ranged from one month-21 years (mean 6 years). There was no statistically significance correlation between ocular abnormalities and the duration of the disease as 8 patients out of 15 patients having vitiligo for < 5 years and 7 patients for ≥ 5 years had specific ocular abnormalities ($P > 0.01$) (Table-3). Out of 15 patients who had specific ocular abnormalities, only 3 patients had severe vitiligo and 8 patients had moderate vitiligo in which there was no statistically significance correlation between specific ocular abnormalities and the disease severity ($P > 0.01$) (Table 3).

Comment [PD3]: In third person: the results of this research....

Table-1 The relationship between the duration of the disease and its severity

Duration	Severity: No. of patients(%)			
	Mild	Moderate	Severe	Total
Less than 1 year	22 (11%)	14(7%)	2(1%)	38 (19%)
Between 1-5 years	54 (27%)	26 (13%)	13 (6.5%)	93 (46.5%)
More than 5 years	15 (7.5%)	37 (18.5%)	17 (8.5%)	69 (34.5%)
Total	91 (45.5%)	77 (38.5%)	32 (16%)	200 (100%)

..

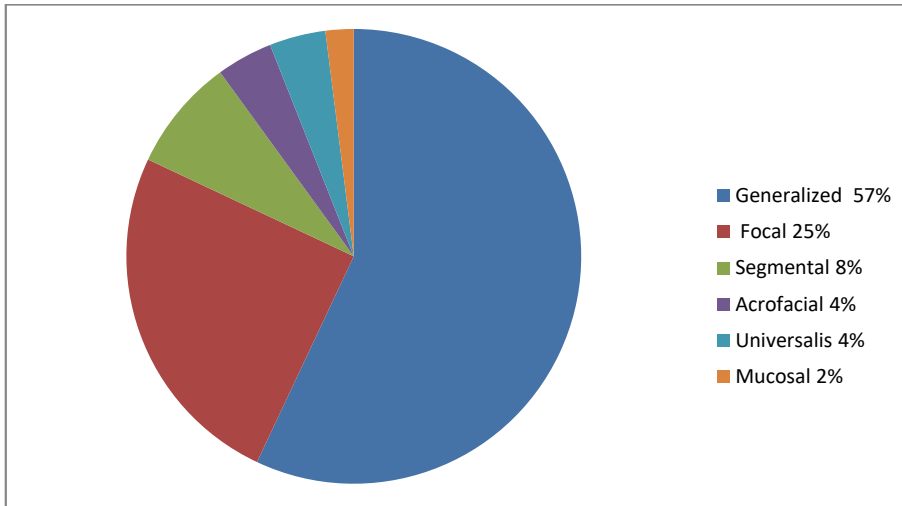


Figure: 1 Clinical types of vitiligo

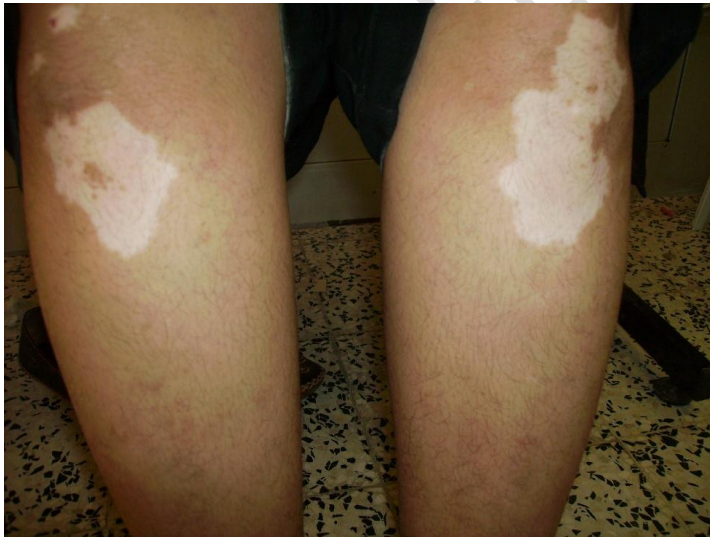

Figure: 2 Generalized vitiligo with involvement of the lower limbs

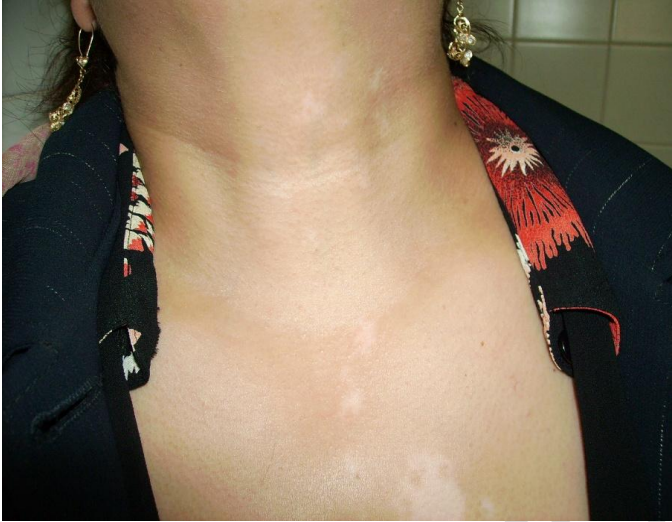

Figure3: Segmental vitiligo

UNDER PEER REVIEW

Table-2: The specific and nonspecific ocular abnormalities observed in 100 patients

Comment [PD4]: Adapt Tables according Vancouver format

The ocular abnormality	No. of patients (%)
Fundal pigmentary changes	12 (12%)
Uveitis	2 (2%)
Retinal detachment	1 (1%)
Iritis	1 (1%)
Chorioretinal degeneration	1 (1%)
Visual acuity defects	26 (26%)
Cataract	8 (8%)
Allergic conjunctivitis	6 (6%)
Diabetic retinopathy	4 (4%)
Dacryocystitis	2 (2%)

Table-3: The duration and severity of the disease in 15 patients with specific ocular abnormalities

Duration	No. of patients	Severity		
		Mild	Moderate	Severe
< 5 years	8 (53.3%)	2 (13.3%)	5 (33.3%)	1(6.7%)
» 5 years	7 (46.7%)	2 (13.3%)	3 (20%)	2 (13.3%)
Total	15 (100%)	4 (26.6%)	8 (53.3%)	3 (20%)

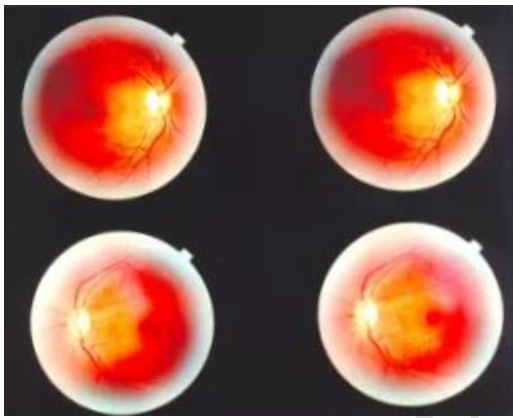



Figure4: Slightly hyperpigmented macula , left eye more than right,

UNDER PEER REVIEW



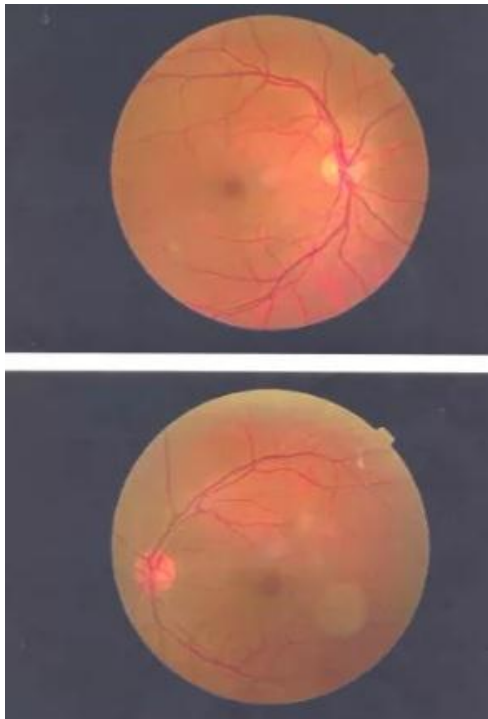


Figure:5 Mild hyperpigmentation at the macula

Discussion

Vitiligo is a pigmentary disease clinically presented by depigmented skin macules and patches due to the chronic and progressive loss of melanocytes from the cutaneous epidermis (1,2, 8). Although the etiology of vitiligo is still obscure, studies have shown a role for both cellular and humoral immunity in the pathogenesis of vitiligo (9). Both sexes are likely affected equally; the female prevalence in some studies can be probably attributed to greater concern about a cosmetic defect. On comparing our clinical observations with previous reports we found a slightly higher prevalence of vitiligo in female (male: female ratio 1: 2.8). Vitiligo may develop at any age; onset has been reported from birth to 81 years. The peak age of onset in all series was between 10 and 30 years; in 50% of cases, the age of onset fell within the first two decades of life (3). The mean age at present was 28.6 years; this is in agreement with previous studies (10,11) where the mean age was 23 years. Lerner observed that nearly 50% of vitiligo developed below 20 years of age (2), while it was slightly higher (58.5%) in our series and much higher (61.9%) in previous study (12), this may reflect cosmetic disfigurement of this age group and parental anxiety leading to early reporting. Vitiligo was predominantly non-segmental in 92% of our patients. Generalized vitiligo (57.5%) was the commonest type, this supports the finding of previous study (10). This indicates that the process of depigmentation (either immune-mediated \ toxic) may occur

simultaneously or subsequently at various unrelated distant sites. Segmental vitiligo is characterized by unilateral macules in a dermatomal or quasidermatomal distribution. This should be considered a special type of vitiligo that has a stable course and is unlikely to be associated with thyroid disease or with other vitiligo-associated diseases. Five percent of adults but more than 20% of children with vitiligo are found to have this pattern. In various studies, from 5 to 28% of patients have been noted to have the segmental pattern. In our study 16 patients (8%) had segmental vitiligo. The most common site of involvement was the face (7 patients). The trigeminal was the most commonly involved dermatome, these findings support the findings of previous study (106). As we can see in our series the mucosa is affected in 31% of patients, this is slightly lower than other study where it was found 59.3% (10). Since melanocytes are distributed not only in the skin but also in the eyes, the mechanism responsible for melanocytes destruction in the skin affect melanocytes at other locations as well. Vitiligo patients normally have no ophthalmologic complaints but may have iris and retinal pigmentary abnormalities. Careful examination has revealed choroidal abnormalities in up to 30 % and evidence of iritis in 5% (13). In our study, specific ocular abnormalities occurred in 15% of vitiligo patients. Many authors reported similar ocular changes in vitiligo patients (11,14). But these ocular findings may be observed in as many as 66% of patients with vitiligo (15,16). In our study these ocular findings include: Fundal pigmentary changes (12%), uveitis (2%), iritis (1%), and Chorioretinal degeneration (1%), this is much less than other studies (17,18). Gopal et al (11) found that 19.8% of generalized vitiligo and 9.8% with localized vitiligo had ocular abnormalities, this difference being statistically significant, they also found that there was no statistically significance correlation between ocular abnormalities and the duration of the disease. In our study 7% of patients with specific ocular abnormalities had generalized vitiligo, 7% with localized vitiligo and 1% with vitiligo universalis. this difference was statistically non significance. In our study there was no statistically significance correlation between ocular abnormalities and the duration and severity of the disease. In present study non specific ocular abnormalities were present in 33 vitiligo patients, while 35 of vitiligo patients in other study had non specific ocular abnormalities (11,18,19).

CONSENT

All patients signed an informed consent form before participating in the study.

ETHICAL APPROVAL

As per international standard or university standard written ethical approval has been collected and preserved by the author(s).

References:

- 1) Ortonne JP, Bahadoran P, Fitzpatrick et.al Hypomelanoses and Hypermelanoses. In: Fitzpatrick's Dermatology in General Medicine. Freedberg IM, Eisen AZ, Wolff K, Austen KF, Goldsmith LA, editors. 6th ed. New York: McGraw Hill; 2003. p. 839-47
- 2) Bergqvist C, Ezzedine K; Vitiligo: A Review ; Dermatology 2020;236:571–5923) Ezzedine K, Grimes PE, Meurant JM, Seneschal J, Léauté-Labrèze C, Ballanger F, et al. Living with vitiligo: results from a national survey indicate differences between skin phototypes. Br J Dermatol. 2015 Aug;173(2):607–9.
- 4) Ortonne J-P, Mosher DB, Fitzpatrick TB, In: Vitiligo and Other Hypomelanoses of Hair and Skin. New York, Plenum, 1983; 129-310.
- 5) Cowan CL Jr, Halder RM, Grimes PE, Chakrabarti SG, Kenney JA Jr. Ocular disturbances in Vitiligo. J Am Acad Dermatol 1986;15:17-24.
- 6) Prabha N, Chhabra N, Kumar A et.al Ocular Abnormalities in Vitiligo Patients: A Cross-Sectional Study; Indian Dermatol Online J. 2019 Nov-Dec; 10(6): 731–734.
- 7) Nordlund JJ, Todes Taylor N, Albert DM et al. The presence of vitiligo and poliosis in patient with uveitis. J Am Acad Dermatol 1981; 4: 528-36.
- 8) Ezzedine K, Eleftheriadou V, Whitton M et.al Vitiligo. Lancet. 2015 Jul;386(9988):74–84.
- 9) Ogg, G.S, Dunbar PR, Romero P, et al.: High frequency of skin-homing melanocyte-specific cytotoxic T lymphocytes in autoimmune vitiligo. J Exp Med 1998; 188: 1203-1208.
- 10) Dave S, Thappa DM, DSouza M. Clinical predictors of outcome in vitiligo. Indian J Dermatol Venereol Leprol 2002;68:323-325
- 11) Gopal K, Rama Rao GR, Kumar YH et.al Vitiligo: A part of a systemic autoimmune process. Indian J Dermatol Venereol Leprol 2007;73:162-165.
- 12) Behl PN, Agarwal A, Srivastava G. Etiopathogenesis of vitiligo : Are we dealing with an environmental disorder ?. Indian J Dermatol Venereol Leprol 1999;65:161-167.
- 13) Cowan CL Jr, Halder RM, Grimes PE et.al; Ocular disturbances in Vitiligo. J Am Acad Dermatol 1986;15:17-24.
- 14) Karadag R, Esmer O, Karadag AS, Bilgili SG, Cakici O, Demircan YT, et al. Evaluation of ocular findings in patients with vitiligo. Int J Dermatol. 2016;55:351–5. [PubMed] [Google Scholar]
- 15) Cieścińska C, Pawlak-Osińska K, Marzec Met al. Prevalence of impaired hearing and vision in patients with vitiligo. Acta Dermatovenerol Croat. 2016;24:20–4.
- 16) Nordlund JJ, Todes Taylor N, Albert DM et al. The presence of vitiligo and poliosis in patient with uveitis. J Am Acad Dermatol 1981; 4: 528-36.

Comment [PD5]: I suggest to include recent bibliography from less than 5 years

17) Shah MK. Ocular abnormalities in childhood vitiligo – When to screen? Indian J Paediatr Dermatol. 2017;18:351–2.

18) Leeson CR, Leeson TS, Paparo AA. Textbook 114. Biswas G, Barbhuiya JN, Biswas MC, Islam MN, Dutta S. Clinical pattern of ocular manifestations of vitiligo. J Indian Med Assoc 2003;101:478-80.

19) Huggins RH, Janusz CA, Schwartz RA. Vitiligo: A sign of systemic disease. Indian J Dermatol Venereol Leprol 2006;72:68-71.

UNDER PEER REVIEW