

## **Familial Primary Open Angle Glaucoma: A Case Report**

### **Abstract**

Primary open-angle glaucoma (POAG), also known as chronic simple glaucoma, is usually an inherited disease. Inheritance is considered multifunctional and polygenic. Glaucoma is the second leading cause of irreversible blindness worldwide, of which POAG is the most common. First degree relatives of POAG patients are at increased risk. A reasonable risk for siblings is four and twice the risk of the normal population for the offspring, although the number of surveys varies.

Case description: We present clinical data from eight family members who complained of progressive decrease in visual acuity and eye ache. Through detailed medical history and ophthalmological examination, the diagnosis of familial POAG was made. The presented patients belong to a common family of 32 members, 22 of whom are affected by POAG. The clinical details of some members are as follows:

Patient 1: A 22-year-old male consulted for headache, dull eye ache and diminution of vision, was diagnosed with POAG in the right eye 4 months ago and in the left eye 2 months ago, had a trabeculectomy of the right eye carried out.

Patient 2: A 25-year-old man with dull eye ache and decreased vision in both eyes and colored halos in the left eye, POAG was diagnosed in both eyes and a trabeculectomy of the right eye was performed 4 years ago. In the examination, fundus showed total glaucomatous optic atrophy in both eyes. Timolol eye drop and Travoprost eye drop were recommended.

Patient 3: 17-year-old woman who was consulted for headache, dull eye ache, deviation of the right eye and diminution of vision in both eyes. She was diagnosed with congenital monocular levator palsy in her right eye 5 years ago and even a ptosis operation was attempted 5 years ago. She was diagnosed with juvenile glaucoma in both eyes 3 years ago and is instilling Dorzox and Combigan eyedrops.

Patient 4: A 45-year-old male who was consulted for headache, dull eye ache and glare in both eyes from 6 months, was diagnosed as POAG and using Dorzox eye drop and Combigan eye drop.

Patient 5: 23 year old man who has dull eye ache in both eye was diagnosed POAG 3 years back. The use of timolol eye drop was recommended. His fundus findings showed glaucomatous optic disc cupping with CDR of 0.7 in both eyes.

Close follow-up care for each patient every 2 weeks was recommended; the refraction error was corrected with a prescription for glasses; Monotherapy or combination therapy with antiglaucoma drugs was recommended for each patient.

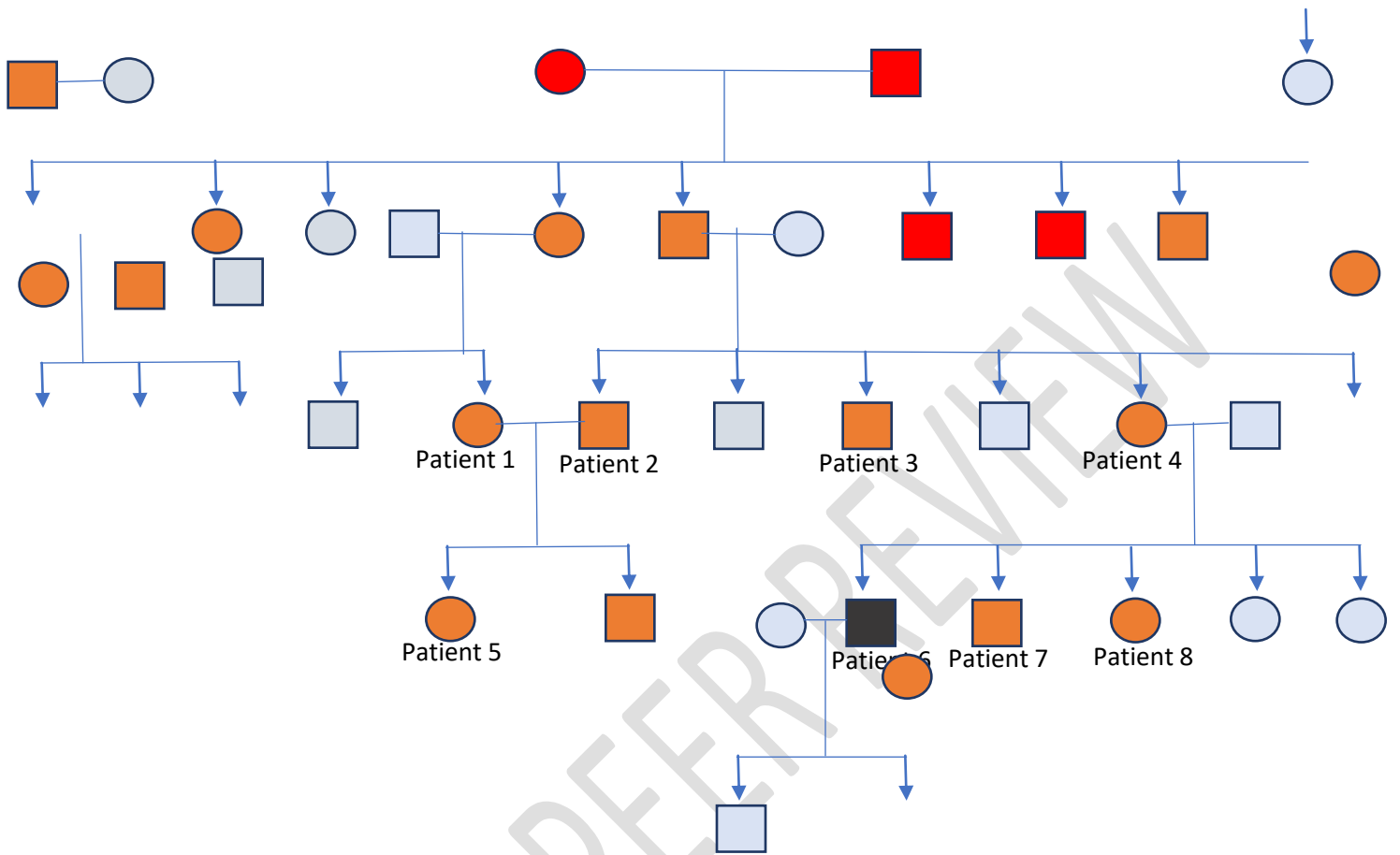
Conclusion: This case report illustrates the stealth nature of POAG and the devastating vision loss it can cause as it progresses; emphasizing on regular and comprehensive eye examinations during its early stage.

## Introduction

According to the studies, glaucoma is the second leading cause of irreversible blindness worldwide, of which POAG accounts for a major three-quarter (74%) of all glaucoma cases [1]. Less than 10% of POAG cases in the general population are caused by specific gene mutations and the remaining cases are polygenic. Quantitative traits related to POAG pathogenesis such as intraocular pressure (IOP), vertical cup/disc ratio (CDR), optic disc area, and central corneal thickness (CCT) are highly heritable, and likely to be influenced at least in part by genes and show substantial variation in human populations.

In this study, we present clinical data of eight family members to CIMS Bilaspur medical college who complained of a progressive decrease in visual acuity and dull eye ache. All eight individuals had comprehensive eye examination including vision acuity testing, slit-lamp bio microscopy, indentation tonometry, gonioscopy and fundus examination after which the diagnosis of familial POAG was made. The presented patients belong to a joint family with a history of consanguineous marriage consisting of five generations of total 32 members, 22 of whom are affected by POAG.

The pedigree chart of the family:



- Male
- Female
- PL Negative
- Affected POAG
- Dead

Total 22 members affected were distributed by the local clinician and ophthalmic assistants, 8 members of second and fourth generation were brought to CIMS Bilaspur C.G., 7 patients of second and fifth generation were taken

to Medical college Raipur C.G. and 7 members of third and fourth generation were taken to Medical college Raigarh C.G.

## Case Reports

Patient 1: A 30 years old woman consulted for constant dull eye ache and seeing of colored halos in both eyes since 6 months, was diagnosed with POAG in both eyes at the age of 17 years, had a history of trabeculectomy of both eyes performed at the age of 17 years and she is instilling eyedrop Dorzolamide with timolol combination since then.

Patient 2: A 45-year-old man who was consulted for headache, dull eye ache and photophobia in both eyes since 6 months, was diagnosed as POAG at age of 25 and is using Dorzolamide eye drop and Brimonidine Tartrate with Timolol combination eye drop since then.

Patient 3: A 22-year-old man consulted for headache, dull eye ache and diminution of vision, was diagnosed with POAG in the right eye 4 months ago and in the left eye 2 months ago, had a trabeculectomy of the right eye carried out.

Patient 4: A 40 years old woman consulted for constant dull eye ache in both eyes, was diagnosed with POAG 17

years back, had trabeculectomy of both eyes 16 years back and is instilling Timolol eyedrop since then.

Patient 5:17-year-old girl who was consulted for headache, dull eye ache, deviation of the right eye and diminution of vision in both eyes. She was diagnosed with congenital ptosis in her right eye 5 years ago and frontalis sling operation was done 5 years ago. She was diagnosed with juvenile glaucoma in both eyes 3 years ago and is instilling Dorzolamide and Brimonidine Tartrate with Timolol combination eyedrops.

Patient 6:A 25-year-old man with dull eye ache and decreased vision in both eyes and colored halos in the left eye, POAG was diagnosed in both eyes and a trabeculectomy of the right eye was performed 4 years ago. Timolol eye drop and Travoprost eye drop were recommended.

Patient 7:23-year-old man who has headache and dull eye ache in both eyes was diagnosed POAG 3 years back. The use of timolol eye drop was recommended.

Patient 8: A 17 years old girl presented with the complain of headache and blurring of vision in both eyes since one year but is not receiving any treatment at present. She was prescribed glasses for the correction of refractive error.

Table 1: Clinical profile of the patients who presented to CIMS, Bilaspur (C.G.)

	Age in years	Visual acuity	BCVA	Right eye (positive finding)	Left eye (positive finding)	Intraocular pressure mmHg	Gonioscopy	Fundus	Probable diagnosis
Patient 1	30	RE – 6/36 LE – 6/24	RE – (-) 0.75/- 0.5/60°, 6/6 LE – 0.5/- 0.5/60°, 6/6	Iridectomy at 12 o'clock, superiorly conjunctival bleb present	Iridectomy at 12 o'clock, superiorly conjunctival bleb present	RE – 17.5 LE – 17.5	(BE) grade 4 in all quadrants	(BE) media clear, cup:disc ratio 0.6, foveal reflex dull, blood vessels appear normal	(BE) POAG
Patient 2	45	RE – 6/9 LE – 6/12	RE – -0.5 DS/10°, 6/6 LE – -0.25/- 0.5/30°, 6/6	Within normal limit	Within normal limit	RE- 17.5 LE- 29.0	(BE) Grade 4 in all quadrants	(BE)- media clear, cup:disc ratio 0.5, neuroretinal rim, foveal reflex dull, blood vessels appear normal	(BE) POAG
Patient 3	22	RE – 4/60 LE – 6/6	RE – no improvement with glasses	Iridectomy at 12 o'clock, superiorly conjunctival bleb present	Within normal limit	RE- 22.4 LE- 17.3	(BE) grade 4 in all quadrants	(RE) – media clear, neuroretinal rim intact, cup:disc ratio 0.6, foveal reflex, blood vessels appear normal (LE) – CDR 0.4	(BE) POAG
Patient 4	40	RE – 6/36 LE – 6/60	No improvement with glasses	Iridectomy at 12 o'clock, superiorly conjunctival bleb present	Iridectomy at 12 o'clock, superiorly conjunctival bleb present	RE – 20.6 LE – 20.6	(BE) grade 4 in all quadrants	(BE) media clear, cup:disc ratio 0.6, peripapillary degeneration, foveal reflex dull, blood vessels appear normal	(BE) POAG
Patient 5	17	RE – 6/24 LE – 6/60	RE- -0.5/- 0.5, 10° (6/6) LE - - 14.0/-2.0, 35° (6/6)	Severe congenital ptosis with poor levator function, rest within normal limit	45 exotropia, Eyeball movement restricted in upward gaze, Rest Within normal limit	RE- 28.0 LE- 30.4	(BE) grade 4 in all quadrants	RE- media clear, cup:disc ratio 0.6, neuroretinal rim intact, foveal reflex present, blood vessels appear	(RE) congenital ptosis (BE) POAG Patient was advised for surgery but the patients parents were not willing for

								normal LE- myopic fundus	the surgery due to poor visual prognosis
Patient 6	25	RE- HM + LE – 6/18	(BE) – no improvement with glasses	Mild conjunctival congestion, Corneal edema present, Iridectomy at 12 o'clock, superiorly conjunctival bleb present	Mild conjunctival congestion, Rest finding within normal limit	RE – 7.1 LE – 18.9	(BE) – grade 4 in all quadra nts	(BE)- media clear, total glaucomatous optic atrophy, blood vessels appear attenuated	(BE) POAG
Patient 7	23	RE – 6/18 LE – 6/12 With pinhole (BE)– 6/12	RE- -0.5 DS, 6/12 LE- no improvement	Conjunctival congestion, Rest findings within normal limit	Conjunctival congestion, Rest findings within normal limit	RE- 25.8 LE- 25.8	(BE) – grade 4 in all quadra nts	(BE) – media clear, Cup :disc ratio 0.5, neuroretinal rim intact, foveal reflex bright, blood vessels appear normal	(BE) POAG
Patient 8	17	RE – 6/12 LE – 6/6	RE- +0.25 DS, 90°, 6/6 LE- no improvement	Within normal limit	Within normal limit	RE- 21.9 LE- 21.9	(BE) – grade 4 in all quadra nts	(BE)- media clear, cup:disc ratio 0.5, neuroretinal rim intact, foveal reflex bright, blood vessels appear normal	(BE) POAG

## Discussion

Prior studies<sup>[2,3,4]</sup> have established that primary open-angle glaucoma is more likely to affect persons with a family history of the disease. A proportion of POAG is known to have a genetic origin as demonstrated by family pedigrees conforming to dominant and recessive modes of

Mendelian inheritance [5,6]. First-degree relatives of POAG patients are at increased risk. A reasonable risk for siblings is four and twice the risk of the normal population for the offspring, although the number of surveys varies.

In our study, there are five generations of 32 members, 22 (18 male and 16 female) in this family. 22 members were affected and out of them eight members presented to us are included in this study. The age at diagnosis among eight patients was between 13 and 35 years ( $26.3 \pm 2.8$  years), which is considered juvenile POAG. All patients accepted timely treatment with high compliance and showed punctuality in their follow up visits. Due to early diagnosis proper treatment could be given at proper time in the form of filtration surgery or medical management as per requirement. On follow up visit examinations no patient showed any progression of glaucomatous changes.

Table 2. Age and sex Predilection of the patients presenting to the medical college

Patient	Age of diagnosis (years)	Sex
1	17	Female
2	25	Male
3	22	Female
4	23	Male
5	15	Male
6	21	Female
7	20	Male

8	16	Female
---	----	--------

Male:Female (4:4 of presenting patients) = 1:1

Table 3. Presenting Complaints

Patient	Mild Headache	Dull Eye ache	Progressiive Diminution of vision
1	+	+	+
2	+	+	+
3	+	+	+
4	+	+	+
5	+	+	+
6	+	+	+
7	+	+	+
8	+	+	+

\*Presence of complaint = (+)

\*Absence of complaint = (-)

Table 4. Number of patients out of 8 presenting patients requiring Trabeculectomy operation

Patient	Age at	OD	OS
---------	--------	----	----

number	which operation was performed		
1	17	Iridectomy at 12 o'clock, superiorly conjunctival bleb present	Iridectomy at 12 o'clock, superiorly conjunctival bleb present
3	22	Iridectomy at 12 o'clock, superiorly conjunctival bleb present	
4	23	Iridectomy at 12 o'clock, superiorly conjunctival bleb present	Iridectomy at 12 o'clock, superiorly conjunctival bleb present
6	25	Iridectomy at 12 o'clock, superiorly conjunctival bleb present	

The genetic traits noted in this familial POAG were:

- 1) Atavism was not present in this family since POAG patients were found in each generation
- 2) The incidence of POAG is equal in both male and female patients
- 3) if any of the parents were affected, their offsprings are were also affected and
- 4) the family had a history of consanguineous marriages.

Inference:

1. Break In the consanguinity is must to decrease the incidence
2. Early and regular ophthalmic screening of upcoming generations, starting from the age of 5 years
3. Regular follow up of the patients

## References

1. Quigley H.A., Broman A.T. The number of people with glaucoma worldwide in 2010 and 2020. *Br. J. Ophthalmology*. 2006; 90:262–267. DOI: 10.1136/bjo.2005.081224. [[PMC free article](#)] [[PubMed](#)] [[CrossRef](#)] [[Google Scholar](#)]
2. Tielsch JM, Katz J, Sommer A, Quigley HA, Javitt JC. Family history and risk of primary open angle glaucoma. The Baltimore Eye Survey. *Arch Ophthalmol*. 1994 Jan;112(1):69–73. [[PubMed](#)] [[Google Scholar](#)]
3. Nemesure B, Leske MC, He Q, Mendell N. Analyses of reported family history of glaucoma: a preliminary investigation. The Barbados Eye Study Group. *Ophthalmic Epidemiol*. 1996 Dec;3(3):135–141. [[PubMed](#)] [[Google Scholar](#)]
4. Leighton DA. Survey of the first-degree relatives of glaucoma patients. *Trans Ophthalmol Soc . UK*. 1976 Apr;96(1):28–32. [[PubMed](#)] [[Google Scholar](#)]
5. Posner A, Schlossman A. Role of inheritance in glaucoma. *Arch Ophthal*. 1949 Feb;41(2):125–150. [[PubMed](#)] [[Google Scholar](#)]
6. Francois J. Genetics and primary open-angle glaucoma. *Am J Ophthalmol*. 1966 Apr;61(4):652–665. [[PubMed](#)] [[Google Scholar](#)]