

## Case study

# Axenfeld-Rieger Syndrome. Case report

### ABSTRACT

**Aims:** To describe a Axenfeld-Rieger Syndrome

**Presentation of Case:** MCL, 7 years old, female, brown, (was brought) is taken to the ophthalmology outpatient clinic of the Hospital Universitário Antônio Pedro, Brazil by her parents, complaining of low visual acuity and malformation of the pupil perceived since birth.

**Discussion:** Axenfeld-Rieger Syndrome is a rare and hereditary disease. Clinically, Axenfeld's anomaly is characterized by the presence of posterior embryotoxon, and there may be adherence of iridian tissue in its periphery. In addition to Rieger's anomaly, posterior embryotoxon is added to iris hypoplasia and iris thickness defects, uveal ectropion and pupillary alterations, such as corectopia. Rieger's syndrome is associated with extraocular changes, of which hypodontia, myicrodontia(microdontia), maxillary hypoplasia, telecanthus, hypertelorism and hypospadias stand out.

**Conclusions:** Therefore, the importance of early diagnosis, follow-up and adequate treatment becomes evident in order to preserve the visual function of patients and thus avoid an unfavorable evolution

Formatted: Font color: Red

Formatted: Font color: Red

Formatted: Font color: Red

Formatted: Font color: Red

*Keywords: Axenfeld Rieger Syndrome; anterior segment dysgenesis; posterior embryotoxon; iris atrophy; secondary glaucoma; Haab striae.*

### 1. INTRODUCTION

Axenfeld-Rieger Syndrome (RAS) is characterized by congenital abnormalities, especially changes in the periphery of the cornea, iris and cameralar sinus, in addition to bone and dental malformations. In some cases, there may be changes in other organs.<sup>1-4</sup>

Some authors divided them into 3 subgroups. Axenfeld Anomaly, limited to anterior segment ophthalmic defects, Rieger Anomaly, in which additional changes occur in the iris, and Rieger Syndrome, ocular anomalies associated with extraocular changes, especially of the teeth, facial bones, and periumbilical skin. However, the term Axenfeld-Rieger syndrome is considered more accurate, as it corresponds better to the combination of symptoms that the syndrome involves.<sup>4,5,6</sup>

Its incidence is 1 in 200,000 live births, with no preference for race or sex.<sup>4</sup>

It is a hereditary disease, inherited in an autosomal dominant manner, with variable expressivity, but high penetrance. The mutation is most often found in the PITX2 gene on chromosome 4 (4q25) or in FOXC1 on chromosome 6 (6p25.3).<sup>1,3,7,8</sup>

Ocular features are bilateral and appear to be caused by abnormal differentiation and migration of neural crest cells during formation of anterior ocular structures. There may be iris hypoplasia, corectopia, polycoria, posterior embryotoxon, and trabecular meshwork abnormalities. About 50% of children with SAR develop glaucoma. The risk is greatest when the peripheral iris is highly inserted into the trabecular meshwork.<sup>7-10</sup>

The non-ocular changes of the syndrome include maxillary hypoplasia, hypodontia or microdontia, auricular malformations, and redundant periumbilical skin. Some congenital heart defects may also be present, such as changes in the atrial septum. Renal alterations and pituitary alterations have also been described.<sup>6-9</sup>

## 2. Case Report

MCL, 7 years old, female, brown, **is taken** to the ophthalmology outpatient clinic of the Hospital Universitário Antônio Pedro, Brazil by her parents, complaining of low visual acuity and malformation of the pupil perceived since birth.

On ophthalmologic examination, visual acuity was 20/25 in both eyes (BE) with better correction.

Biomicroscopy showed an increase in corneal diameter (Figures 1 and 2) in both eyes (14.5mm x 12mm in the right eye and 13mm x 12mm in the left eye), Haab striae, posterior embryotoxon and pupillary defect with corectopia and dysphoria in both eyes (Figures 1, 2 and 3). Intraocular pressure (IOP) of 12/12 mmHg. Fundoscopy revealed an increase in cup/disc ratio in both eyes (0.7 x 0.7 AO) **fields, OCT? retina, macula? Any cardiac, dental anomaly? deafness? IQ/mental retardation?**

Gonioscopy showed a prominent Schwalbe line and lines of iris stroma adhered to the cornea.

The typical changes and presentation led to the diagnostic hypothesis. The patient's parents were then examined, revealing characteristic changes in the father. **Mention about the consanguinity; any other siblings ? what about them?**

The patient remains under regular follow-up to control IOP and preserve the nerve fiber layer.

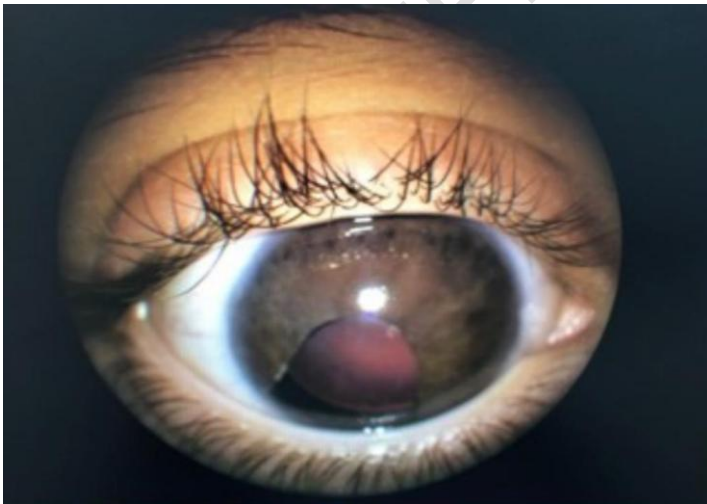


Figure 1 Biomicroscopy showed an increase in corneal diameter

Formatted: Font color: Red

Formatted: Font color: Red

Formatted: Font color: Red

Formatted: Font color: Red

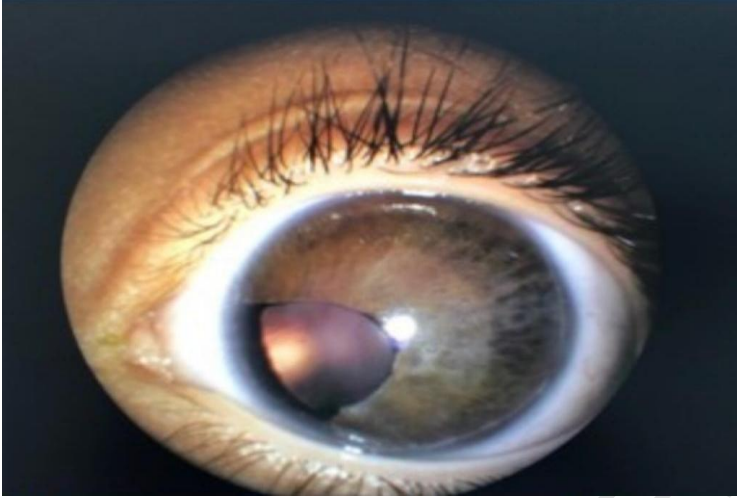


Figure 2 Biomicroscopy showed an increase in corneal diameter

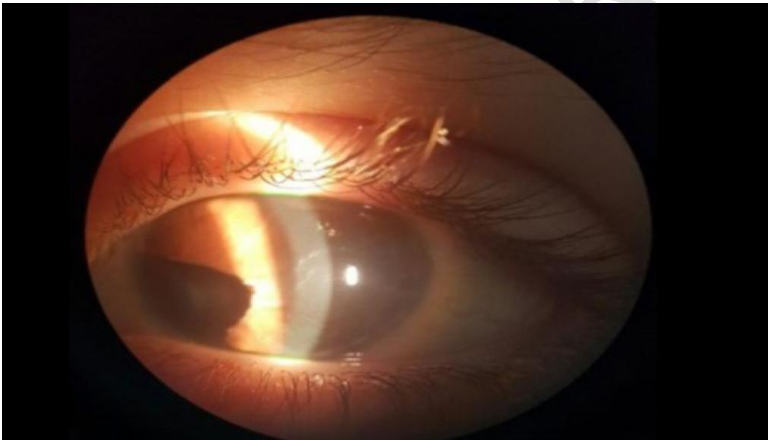


Figure 3 corectopia and dysphoria in both eyes

### 3. Discussion

RAS is a rare and hereditary disease. Clinically, Axenfeld's anomaly is characterized by the presence of posterior embryotoxon, and there may be adherence of iridian tissue in its periphery. In addition to Rieger's anomaly, posterior embryotoxon is added to iris hypoplasia and iris thickness defects, uveal ectropion and pupillary alterations, such as corectopia. Rieger's syndrome is associated with extraocular changes, of which hypodontia, microdontia, maxillary hypoplasia, telecanthus, hypertelorism and hypospadias stand out.<sup>2, 4, 7, 8, 9</sup>

The diagnosis can be suspected from a set of signs and symptoms, as was done in the case reported. The patient's father could be examined, and characteristic changes in the disease were noted, which reinforced the diagnostic hypothesis. Although it is the same mutation, the combination and extent of symptoms varies between different people with the syndrome, even within the same family. Genetic tests can also be used for confirmation.

The main complication is glaucoma, which can manifest during childhood, more commonly towards the end of it. It occurs due to incomplete development of the trabecular meshwork and Schlemm's canal or due to angular closure secondary to synechiae. Glaucoma appears more frequently in patients with central iris alterations and in those with pronounced peripheral anterior insertion of the iris into the trabecular meshwork. When difficult to control, trabeculectomy may be necessary.<sup>1, 8, 10, 11</sup>

### 4. Conclusion

Axenfeld-Rieger Syndrome is a rare disease with major eye complications. It is estimated that about 50% of cases evolve with glaucoma. Of these, some can even progress to amaurosis,<sup>?</sup> especially when the diagnosis is made late.

Therefore, the importance of early diagnosis, follow-up and adequate treatment becomes evident in order to preserve the visual function of patients and thus avoid an unfavorable evolution.

### Consent

All authors declare that 'written informed consent was obtained from the patient (or other approved parties) for publication of this case report and accompanying images. A copy of the written consent is available for review by the Editorial office/Chief Editor/Editorial Board members of this journal.

### Ethical approval

Not applicable

### References

1- Dunbar AC, McIntyre GT, Laverick S, Stevenson B. Axenfeld-Rieger syndrome: a case report. *J Orthod.* 2015;42(4):324-30. doi: 10.1179/1465313315Y.0000000017. Epub 2015 Aug 18. PMID: 26281856.

Formatted: Font color: Accent 6

2. Waldron JM, McNamara C, Hewson AR, McNamara CM. Axenfeld-Rieger syndrome (ARS): A review and case report. *Spec Care Dentist*. 2010 Sep-Oct;30(5):218-22. doi: 10.1111/j.1754-4505.2010.00153.x
3. Seifi M, Walter MA. Axenfeld-Rieger syndrome. *Clin Genet*. 2018 Jun;93(6):1123-1130. doi: 10.1111/cge.13148. Epub 2018 Jan 25. PMID: 28972279.
4. Shields MB, Buckley E, Klintworth GK, Thresher R. Axenfeld-Rieger syndrome. A spectrum of developmental disorders. *Surv Ophthalmol*. 1985;29:387-409.
5. Beneti GC, Barbosa, JC, Faria NM, Francisco FCO, Nogueira LR, Magalhães LL, Resende LS, Ferreira TS. Axenfeld-Rieger syndrome: the importance of early diagnosis and ophthalmologic evaluation. *Rev Med Minas Gerais* 2018;28 (Supl.7): 21-25
6. Sánchez FF, Grima MMD. Insuficiencia mitral moderada progresiva en un niño con síndrome de Axenfeld-Rieger: Importancia del seguimiento cardiológico. *Arch. argent. pediatr*. 2016; 114( 6 ): e417-e420.
7. Bender CA, Koudstaal MJ, van Elswijk JF, Prah C, Wolvius EB. Two cases of axenfeld-rieger syndrome, report of the complex pathology and treatment. *Cleft Palate Craniofac J*. 2014 May;51(3):354-60. doi: 10.1597/12-295. Epub 2013 Jul 25. PMID: 23886080.
8. Cella WP. Rastreamento de mutações nos genes PITX2, FOXC1 e GJA1 em pacientes com síndrome de Axenfeld-Rieger associada a glaucoma. 2005. 171p. Dissertação (mestrado) - Universidade Estadual de Campinas, Faculdade de Ciências Médicas, Campinas, SP.
9. Nascimento NO, Rocha MA, Palma ABO, Oliveira CC, Dias VO. Síndrome de Axenfeld-Rieger: um relato de de caso clínico. Universidade Estadual de Montes Claros - Unimontes Pró-Reitora de Extensão Coordenação Editorial da Revista Intercâmbio
10. Karadag R, Rapuano CJ, Hammersmith MK, Nagra PK. Causes of congenital corneal opacities and their management in a tertiary care center. ORIGINAL ARTICLES • *Arq. Bras. Oftalmol*. 83 (2) • Mar-Apr 2020  
<https://doi.org/10.5935/0004-2749.20200023>
11. González YB, Sánchez TJM, Argones LF, Felipe DL, Diaz IP, Santos LRH. Síndrome Axenfeld-Rieger syndrome associated with glaucoma *Rev. cuba. oftalmol*;25(supl.1):475-482, 2012.