

## Case study

# Congenital Ocular Melanocytosis. Ocular Subtype. Case report.

### ABSTRACT

**Aims:** To describe Congenital Ocular Melanocytosis. Ocular Subtype

**Presentation of Case:** LPC, 7 years old, male, brown, with no previous comorbidities, is taken to the ophthalmology outpatient clinic of the Hospital Universitário Antônio Pedro, Brazil by parents who alleged the presence of bluish-looking lesions in the sclera of the child's right eye since birth.

**Discussion:** Congenital Ocular Melanocytosis is a rare pathology characterized by an increase in the number, size and pigmentation of melanocytes. Its pathophysiological picture is unknown, but it is believed to be due to an alteration in the migration of melanocytes from the neural crest to the epidermis during the embryonic process. This condition can be complicated by glaucoma and uveal melanoma, and gonioscopy is essential in these cases to assess whether there is pigmentation of the trabeculae, so that the propaedeutics of investigation of glaucoma becomes essential in these patients, since 10% of cases can complicate this condition

**Conclusions:** Congenital Ocular Melanocytosis early in life and the importance of monitoring these patients should be emphasized. Comprehensive tests are important for early detection and treatment, in order to improve the prognosis and avoid more severe consequences than what can happen from melanocytosis.

*Keywords: Congenital Ocular Melanocytosis. Pigmented nevus. Ocular Manifestations. Uveal Melanoma. Glaucoma. Nevus of Ota.*

### 1. INTRODUCTION

Angioid Congenital ocular melanocytosis (COM) is a hyperpigmented, localized and unilateral lesion that mainly affects dark-skinned people and oriental descent, being extremely rare in the Caucasian population.<sup>1-3</sup>

Eyelid skin, conjunctiva, posterior pole, and optic disc may be involved. The development of uveal melanoma may be associated, but its relationship is not well established.<sup>1-4</sup>

Blue-gray episcleral or scleral pigmentation and its concomitant non-mobilization relationship with conjunctival tissue is characteristic.<sup>2,4</sup>

It may be associated with iris hyperchromia, iris nipples, fundus hyperchromia, uveal melanoma, especially choroidal melanoma and glaucoma in 10% of cases.<sup>2,4,5</sup>

MOC can be isolated or associated with facial pigmentation, a condition known as oculodermal melanocytosis or Nevus of Ota, characterized by blue or grayish lesions, usually inside the eye and in the periorbital skin region, and may also affect the eyelid and oral region. and perioral.<sup>2,4,6,7</sup>

## 2. Case Report

LPC, 7 years old, male, brown, with no previous comorbidities, is taken to the ophthalmology outpatient clinic of the Hospital Universitário Antônio Pedro, Brazil by parents who alleged the presence of bluish-looking lesions in the sclera of the child's right eye since birth.

They did not present significant morphological changes since their appearance and were not associated with any visual complaint.

On Ophthalmological examination, visual acuity of 20/20 in both eyes.

Biomicroscopy showed lesions with bluish episcleral pigmentation in the right eye (RE) characterized by maintaining its position according to eye movement without affecting the eyelids and their annexes (Figures 1 and 2). In addition, he had heterochromia and iris nipples in the RE (Figure 3).

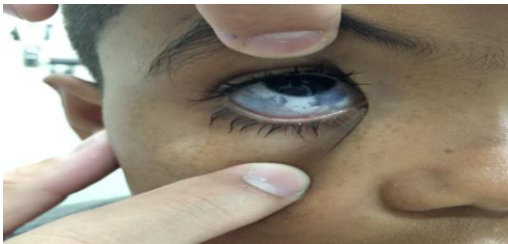

Figure 1 Eye movement without affecting the eyelids

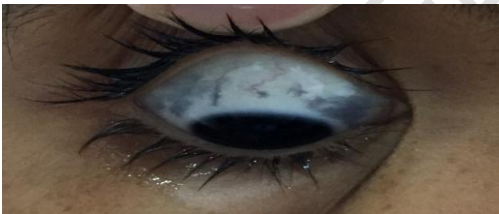

Figure 2 Eye movement without affecting the annexes

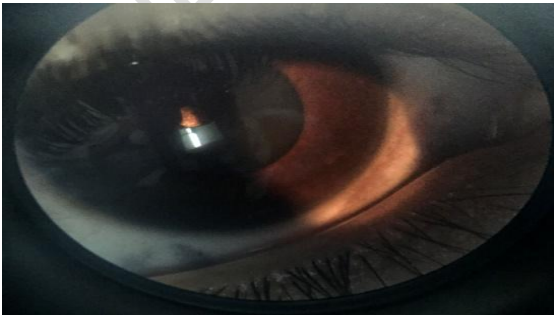

Figure 3 Iris nipples in the RE

The gonioscopy examination revealed hyperpigmentation of the trabeculae in the affected eye (figure 4). Fundoscopy of the RE showed mild retinal hyperpigmentation, more significant in the posterior pole.




Figure 4 hyperpigmentation of the trabeculae

Therefore, it is concluded that the findings found in the patient were compatible with the condition of Congenital Ocular Melanocytosis, ocular subtype. The established conduct was of an expectant nature with regular follow-up for early diagnosis of possible complications not present at the time of consultation.

### 3. Discussion

COM is a rare pathology characterized by an increase in the number, size and pigmentation of melanocytes. Its pathophysiological picture is unknown, but it is believed to be due to an alteration in the migration of melanocytes from the neural crest to the epidermis during the embryonic process.<sup>3,5,6,8</sup>

Lesions may appear at birth and tend to intensify during adolescence,<sup>2,4,7</sup> which suggests that there is a genetic and hormonal influence on the evolutionary process.

It has a higher prevalence in blacks and Asians, being five times more common in females.<sup>4,8</sup> The patient in the present report is male and brown, which emphasizes the importance of the differential diagnosis of hyperpigmented lesions with a blue-gray appearance, even in children who do not fully fit the classic epidemiological profile.

COM is characterized by the presence of hyperpigmented lesions in the eye, especially in the sclera and uvea, which may affect other ocular structures, such as the fundus of the eye and the optic disc.<sup>7,8,9</sup> The patient's lesions are as described in the literature, see their color, location and because the condition is unilateral.

COM has three subtypes: ocular, less prevalent, with about 8% of cases, a condition that fits the profile of the patient in the report, dermal in 30% of cases and, finally, oculodermal or nevus of Ota, being the most prevalent with about 60% of cases.<sup>3,5,7</sup>

This condition can be complicated by glaucoma and uveal melanoma, and gonioscopy is essential in these cases to assess whether there is pigmentation of the trabeculae, so that the propaedeutics of investigation of glaucoma becomes essential in these patients, since 10% of cases can complicate this condition.<sup>5,10-12</sup>

If there is cutaneous involvement of periocular and facial structures, it is called oculodermal melanocytosis or Nevus of Ota. This change may be present in 50% of patients from birth.  
2,7,9,11,12

**Comment [A1]:** Please explain clinical significance in detail.

#### 4. Conclusion

COM is a congenital, unilateral and pigmented lesion that has a clinical diagnosis, requiring early recognition of the condition in order to obtain a correct follow-up in order to avoid eye damage that may have irreversible sequelae, such as glaucoma and uveal melanoma.

The presence of an elevated choroidal mass, even if it is of minimal thickness, must be valued. Subretinal fluid associated with an orange pigmentation composed of lipofuscin should raise suspicion for early-stage choroidal melanoma, optical coherence tomography being essential at this stage.

Recognition of COM early in life and the importance of monitoring these patients should be emphasized. Comprehensive tests are important for early detection and treatment, in order to improve the prognosis and avoid more severe consequences than what can happen from melanocytosis.

**Comment [A2]:** Consider this statement in discussion

#### Consent

All authors declare that written informed consent was obtained from the patient (or other approved parties) for publication of this case report and accompanying images. A copy of the written consent is available for review by the Editorial office/Chief Editor/Editorial Board members of this journal.

#### References

- 1- Que Skt, Weston G, Suchecki J, Ricketts J: Pigmentary disorders of the eyes and skin . Clin Dermatol. 2015, 33:147-58.
- 2- Elston Dm: Melanocytic Neoplasms. Dermatopathology, Second Edition. Elston DM, Ferringer T, Ko CJ, Peckham S, High WA, DiCaudo DJ, Bhuta S (ed): Saunders, Amsterdam; 2014. 105–133.
- 3- Buntinx-Krieg, Talayesa; OUYANG, Jie; CARTWRIGHT, Mont. An orbital malignant melanoma arising in cellular blue nevus in a patient with nevus of Ota. Cureus, v. 8, n. 7, 2016.
- 4- Chien, Jason L. et al. Choroidal nevus: a review of prevalence, features, genetics, risks, and outcomes. Current opinion in ophthalmology, v. 28, n. 3, p. 228-237, 2017.
- 5- Glaser, Tanya; Thomas, Akshay S.; Materin, Miguel A. Successive Uveal Melanomas with Different Gene Expression Profiles in an Eye with Ocular Melanocytosis. Ocular Oncology and Pathology, v. 4, n. 4, p. 236-239, 2018.

6- Hoang, Mai P.; Mihm, Martin C. Conjunctival Melanocytic Lesions. In: Melanocytic Lesions. Springer, New York, NY, 2014. p. 303-328.

7- Zhang, Qi et al. Clinical profile and triggering factors for acquired, bilateral nevus of Ota-like macules. Cutaneous and ocular toxicology, v. 36, n. 4, p. 327-330, 2017.

8- Tarlan, Berçin; Kiratli, Hayyam. Uveal melanoma: current trends in diagnosis and management. Turkish journal of ophthalmology, v. 46, n. 3, p. 123, 2016.

9- Som, P. M.; Laitman, J. T.; Mak, K. Embryology and Anatomy of the Skin, Its Appendages, and Physiologic Changes in the Head and Neck. Neurographics, v. 7, n. 5, p. 390-415, 2017.

10- Shields, Carol L. et al. Association of ocular and oculodermal melanocytosis with the rate of uveal melanoma metastasis: analysis of 7872 consecutive eyes. JAMA ophthalmology, v. 131, n. 8, p. 993-1003, 2013.

11- Sayed-Ahmed, Ibrahim et al. Blue Nevi of the ocular surface: clinical characteristics, pathologic features, and clinical course. Ophthalmology, v. 125, n. 8, p. 1189-1198, 2018.

12- Plateroti, Andrea Maria et al. An update on oculodermal melanocytosis and rare associated conditions. In: Seminars in ophthalmology. Taylor & Francis, 2017. p. 524-528.

UNDER PEER REVIEW