

Study Protocol

Impact Of Hayes Martin Maneuver And Anterograde Dissection On Identification And Preservation Of Marginal Mandibular Nerve During Neck Dissection In Patients With Oral Squamous Cell Carcinoma.

Abstract:

Background: Hayes Martin maneuver (HMM) and Anterograde dissection technique (ADT) were originally described in 1951 as a means of preserving the marginal mandibular nerve (MMN) during level 1B clearance in a neck dissection procedure address the cervical metastasis in patients with oral squamous cell carcinomas.

Objectives: To compare and evaluate the efficacy of HMM and ADT in preservation of MMN using Electromyography of muscles supplied by the nerve ie Mentalis, Depressor labii inferioris and depressor anguli oris, to evaluate muscle function.

Methodology: 20 patients undergoing neck dissection over a period of 6 months grouped were into two groups (10 patients for Hayes Martin manoeuvre and 10 patients for anterograde dissection technique) calculated by purposive sampling method. Postoperative Electromyography and assessment of nerve function using House and Brackmann grading was done on day 5,15 and 30.

Expected Results: HMM proves to be a less time consuming technique than Anterograde dissection by a significant margin considering perifacial node clearance and level 1B clearance. Anterograde dissection technique proved to be more effective than Hayes Martin Maneuver for preservation of MMN as average neuromuscular electrical activity in anterograde dissection cases was higher than the average of HMM cases. Although, no significant statistical difference was found when the neural function was compared on a house and brackmann grading scale

Conclusion: Anterograde dissection technique is technique sensitive, relatively time consuming and requires a higher surgical operator skill. However, provides statistically proven better results in terms of neural electric activity and post-operative functional neural deficit in the operated subjects.

Keywords: Neck Dissection, Marginal mandibular nerve, Hayes martin maneuver, Anterograde dissection, Electromyography, House and Brackmann grading.

Introduction:

Neck dissection has been an established practice in the domain of head and neck surgical oncology. It aims at surgical removal of cervical lymph nodes with associated fibro-fatty tissue and clinically involved (malignant) structures. The practice of neck dissection has seen a paradigm shift over the decades in terms of preservation of structures. Earliest neck dissections performed in the beginning of 20th century included sacrificing the spinal accessory nerve (SAN), sterno-cleido-mastoid muscle (SCM) and Internal Jugular vein (IJV) along with clearance of lymphatics and fibro-fatty tissue. The radical nature of the surgery was associated with its own set of complications and delayed post-operative healing.¹

One such set of complications is associated with iatrogenic injury to the nerves present in the neck encountered during neck dissection viz. The hypoglossal nerve and lingual nerve during level 1B clearance, Vagus and ansa cervicalis during the jugular chain clearance and spinal accessory nerve and the cervical plexus during posterior triangle clearance. Neural morbidity and dysfunction after neck dissection has garnered much attention owing to the “frozen shoulder” shoulder commonly seen after injury to spinal accessory nerve.²

Another nerve at a risk of sustaining injuries is the marginal branch of facial nerve (MMN) during level 1B clearance. The MMN emerges from the tail or antero-inferior surface of the parotid gland. Traverses inferiorly over the submandibular gland, curving superiorly again to cross the facial artery and vein at the anterior border of masseter muscle within the fascia covering the submandibular gland.³ Over the years as neck dissection has evolved, various techniques have emerged for the identification and preservation of MMN during level 1B clearance. Important parameters during a level 1B clearance include clearance of perifacial nodes, clearance of level 1B nodes, excision of submandibular gland with preservation of lingual and hypoglossal nerve and preservation of marginal mandibular nerve^{4,5}.

The Hayes martin maneuver includes ligation of facial artery and vein deep to the fascia of the submandibular gland and its superior retraction to include and thereby preserve the marginal mandibular nerve.⁶ The anterograde dissection technique includes tracing using blunt dissection of the MMN from its origins through the parotid gland substance, where it originates from the cervicofacial trunk after its separation from the pes anserinus, traversing inferiorly to fascia of submandibular gland and then to the inferior border of mandible.⁴

This study aims at comparative evaluation between 2 different techniques used for identification and preservation of MMN viz. Hayes Martin maneuver and Anterograde dissection in terms of post-operative nerve function and time taken for perifacial node clearance.

Objectives: To evaluate and compare the time taken in identification and preservation of marginal mandibular nerve, feasibility of perifacial node clearance and post-operative functional deficit with respect to marginal mandibular nerve in Hayes martin maneuver and anterograde dissection technique.

Methods:

Study design: 20 Patients with oral squamous cell carcinoma where neck dissection was indicated were selected for the study. Patients were divided into two groups (group 1 and group 2) by paper and chit method according to convenience. Group 1 consisted of patients in which tracing of MMN was to be done using Hayes Martin maneuver and group 2 consisted of patients in which tracing of MMN was to be done using anterograde dissection technique.

Follow-up period for each case was 30 days where functional deficit of MMN was calculated using electromyography on post operative day 5-6 when the negative suction drains were removed from the neck and then graded using a house and brackmann grading scale on day 5, 15 and 30 postoperatively.

Setting: The present single-blinded prospective interventional study was conducted on the patients operated for OSCC under the department of Oral and Maxillofacial Surgery, Sharad Pawar Dental College and Hospital, Acharya Vinoba Bhave Rural Hospital, Sawangi (Meghe), Wardha for a duration of 6 months. First case to be enrolled into the study was on date 14/12/2020 and the last case to be enrolled in the study was on date 10/05/2021.

Participants:

20 Patients with OSCC where neck dissection was indicated were selected for the study. Patients were divided into two groups (group 1 and group 2) by paper and chit method.

- Inclusion criteria for patients to be inducted in the study was patients with biopsy proven OSCC where elective neck dissection or therapeutic neck dissection and level 1B clearance with perifacial node clearance is indicated and patients in whom skin over the submandibular or digastric triangle, perioral structures including depressor muscles of lip and skin are not a part of the oncological resection (not involved within the malignant disease clinically).
- Exclusion criteria however, was patients with gross involvement of MMN, tail of parotid gland, gross involvement of perioral structures, depressor muscles supplied by MMN and perioral skin. Radiated or previously operated patients were excluded. Patients who were medically unfit to undergo surgery were excluded. Patients not willing to undergo surgery were excluded.

Variables: Variables into consideration in this study are intra-operative comparative evaluation of time taken to perform a HMM or an anterograde dissection and; intra-operative clinical assessment of perifacial nodal clearance by both techniques and its comparative evaluation.

Post-operative variables include postoperative evaluation of marginal mandibular neural functional deficit using electromyography of perioral muscles supplied by MMN in cases where either HMM or anterograde dissection technique was used and evaluation using a House and Brackmann grading system.

Confounding factors: Damage or mishandling of the MMN during raising a subplatysmal flap, during dissecting the deep layer of cervical fascia over the submandibular gland or during handling of the facial artery or vein can serve as a confounding factor for this study.

Predictors: Gross involvement status of the fibrofatty tissue with cervical lymphadenopathy in association with level 1B, malignant infiltration of perioral structures or muscles supplied by MMN shall serve as a negative predictor factor for this study.

Clinically N0 neck with no gross involvement of fibrofatty tissue at level 1B shall act as a positive predictive factor for the study.

Data sources/ measurement: Time taken for 1B level clearance with perifacial node clearance using both the techniques taking into consideration the handling and preservation of marginal

mandibular nerve to be measured in minutes and seconds format and tabulated. Oncological clearance and safety to be assessed intra-operatively and clinically by meticulous assessment of the digastric triangle and adjacent region.

Post-operatively Neural deficit for MMN to be measured by muscular activity in perioral muscles supplied by MMN via a needle or surface EMG in Microvolts and cross verified by the attending neuro-physician's interpretation and reporting of the EMG graph. Follow up of muscular activity and neural deficit done using house and brackmann grading scale on the subsequent post-operative visits.

Bias: No factors that attribute to a bias were found.

Study size: A total of 20 patients grouped into two groups. (10 patients for Hayes martin manoeuvre and 10 patients for anterograde dissection technique) calculated by purposive sampling method as a part of pilot study.

Quantitative variables:

1. Time taken for 1B level clearance with perifacial node clearance taking into consideration the handling and preservation of marginal mandibular nerve, to be measured in minutes and seconds format.
2. Functional neural deficit of MMN to be measured by needle EMG and tabulated in Microvolts (uV).
3. Post-operative neural deficit to be assessed by House and Brackmann grading system to be noted in grade points.

Statistical methods: Statistical evaluation was done on a sample size of 14 patients by the following statistical modalities:

Time taken was found to be significantly more among patients treated with anterograde dissection when compared using **independent t test as $p > 0.05$** .

Electrical was found to be significantly more among patients treated with anterograde dissection when compared using **independent t test as $p > 0.05$** .

No significant differences were seen in the distribution of house and Brackman grading among two study groups when compared using **Chi square test as $p > 0.05$** .

Expected Results:

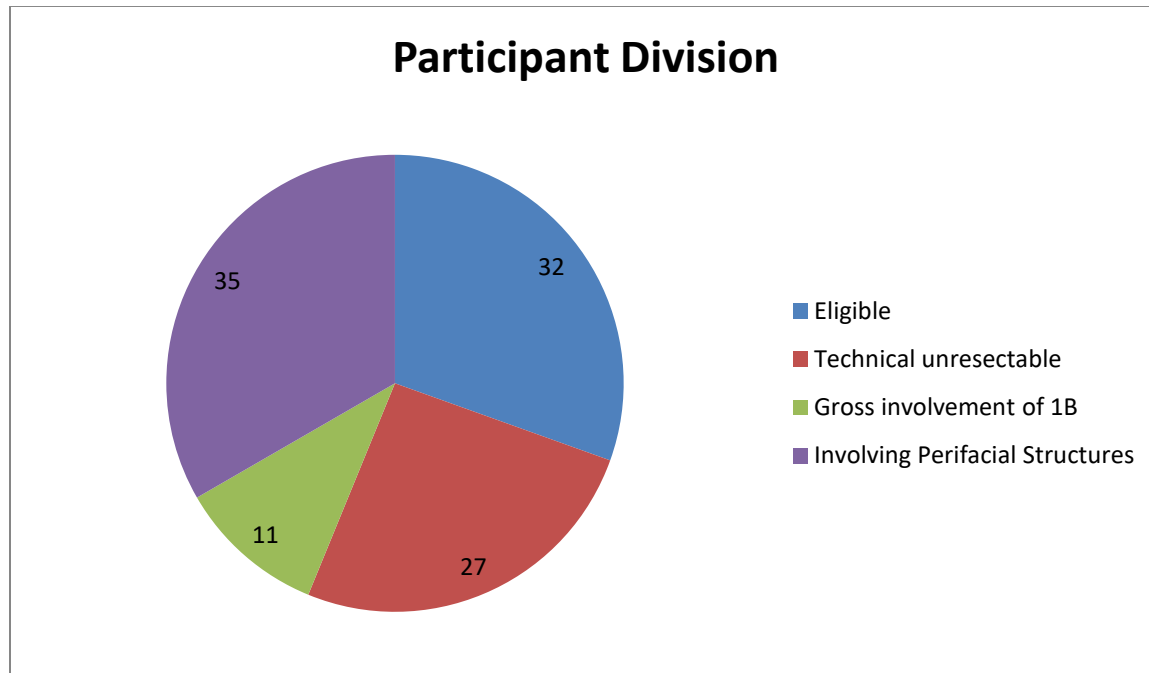
Participants: At the primary stages of study, 105 patients diagnosed with Squamous cell carcinoma of oral cavity reported to the Department of Oral and Maxillofacial Surgery OPD, SPDC, Sawangi (M) from 14/12/2020 to 10/5/2021. At the secondary stage of study 73 patients were excluded as they fit into the exclusion criteria viz

27 patients presented with a stage T4b Disease with technical unresectability who were referred to other centers for curative or palliative intent chemotherapy or radiotherapy or both.

11 patients presented with gross involvement of submandibular gland or fungating 1B nodes with gross involvement of MMN or gross clinical extracapsular extensions.

35 patients presented with gross involvement of perioral structures like involvement of corner of the lip, perioral musculature or perioral skin were excluded.

Out of the eligible 32 patients, 20 patients were then selected for the study using a lottery type chit and paper method according to convenience.



Pic 1. Pie chart showing Participant Division

Descriptive data: Descriptive statistics will be done with the help of frequency, percentage, mean and standard deviation. Final analysis will be done using independent t-test for parameters of time and post operative neural deficit. Chi-square test shall be used for analysis of house and brackmann grading and its analysis.

Main results:

As of date, the expected results are in terms of time taken for 1B with perifacial node clearance in minutes and seconds; neural deficit in terms of microvolts (uV) and Facial nerve weakness in terms of House and Brackmann grading.

Time taken: Time as a quantitative variable was calculated intra-operatively while performing level 1B clearance using a stopwatch with seconds as unit. Out of the sample size of 20 patients as of date, the data of 14 patients viz. 7 patients of each group has been tabulated which is as follows. Average time taken for perifacial node clearance with HMM (7 cases) and perifacial node clearance with anterograde dissection (7 cases) was **7 minutes 40 seconds** and **9 minutes 10 seconds** respectively.

Neural functional deficit: Average spontaneous electrical activity on EMG reporting on HMM group patients and anterograde dissection patients was **45 uV** and **68 uV** respectively in 7 cases per group.

Average of House and Brackmann grades for patients in HMM and anterograde dissection groups were **2.0** and **1.8** with no patients showing a grade 6 dysfunction or palsy.

Tables:

Table 1:

House and Brackmann Grading (With respect to the Marginal Mandibular Branch)	Degree of dysfunction present
Grade 1 : Normal function	
Grade 2 : Slight asymmetry or weakness of mouth movement	
Grade 3 : Moderate Dysfunction : Obvious but no disfiguring weakness	
Grade 4 : Moderately severe dysfunction : Asymmetry at Rest.	
Grade 5 : Severe Dysfunction : Barely Perceptible mouth movements	
Grade 6 : Total Paralysis : No Movement	

Figures:

Figure 1 : Preservation of MMN done with Hayes Martin Manoeuvre

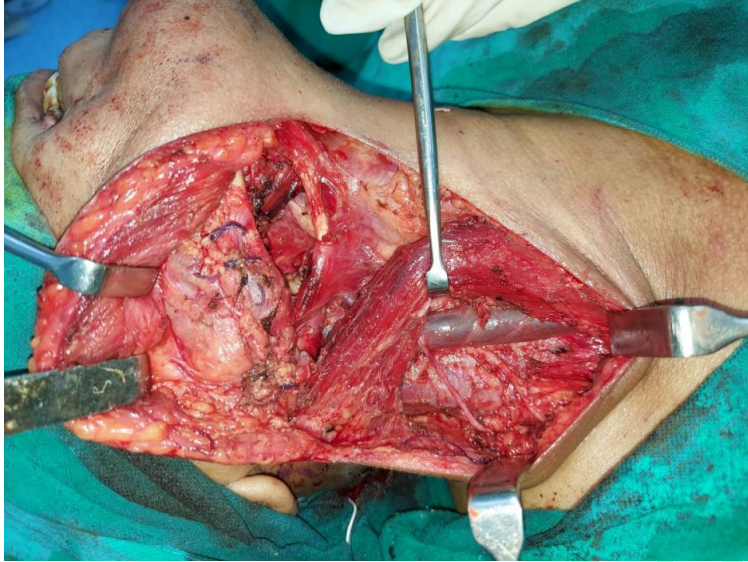


Figure 2 : Preservation of MMN done with Anterograde dissection technique

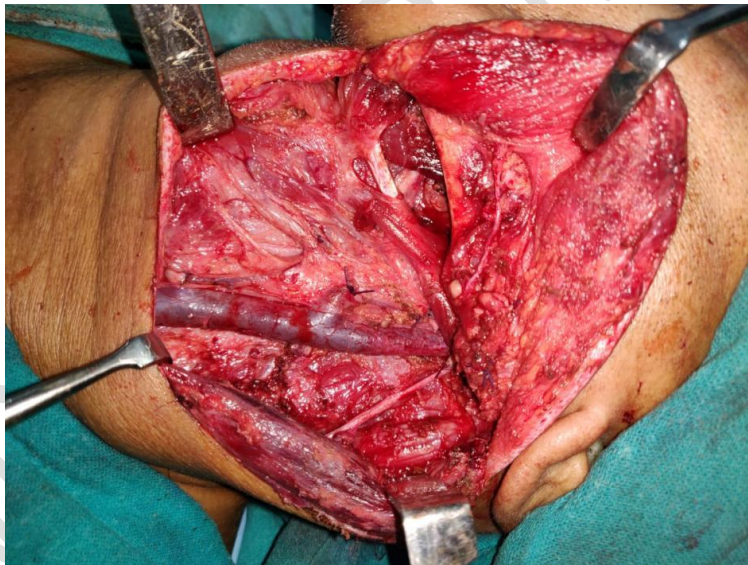
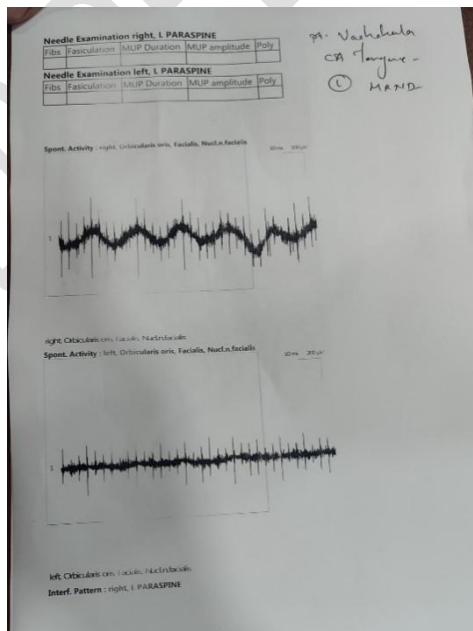


Figure 3 : Surface Electromyography done on patients while smiling and puffing cheeks:

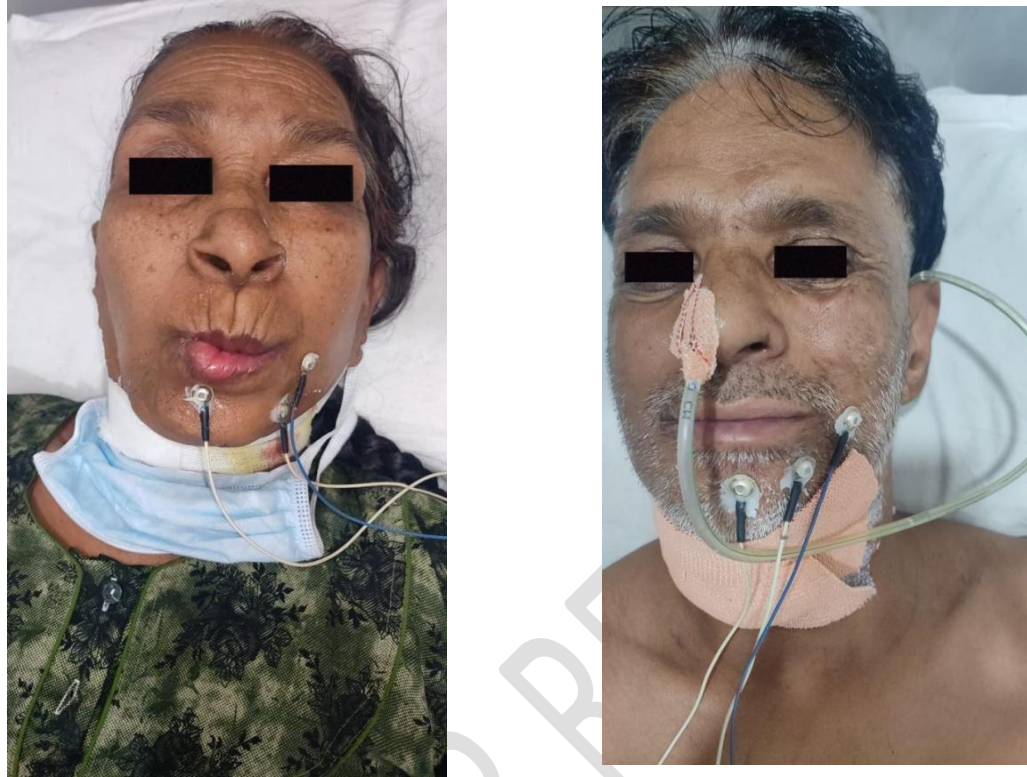

Figure 4 : EMG results conducted on a patient who underwent MRND III of Left side, showing spontaneous electrical activity of muscle supplied by marginal mandibular nerve.



Discussion:

Clear inferences that indicate towards expected results can be drawn from the tabulated main results with respect to time taken, neural deficit and house and Brackman grading are as follows.

HMM proves to be a less time consuming technique than Anterograde dissection by a significant margin considering perifacial node clearance and level 1B clearance with preservation of MMN. The clear reasons being HMM simply includes tracing a part of marginal nerve crossing over the facial vessels within the fascia of submandibular gland, followed by ligation and superior retraction of the vessels which include the nerve. However, ADT is more time consuming owing to the factors that the operator has to trace the entire course of marginal nerve from the origins in parotid substance where it originates from the cervicofacial trunk after its separation from the pes anserinus, traversing inferiorly to fascia of submandibular gland to the inferior border of mandible through the submandibular gland fascia.⁵ A number of related studies were reported⁷⁻¹³.

Electromyography was performed on operated patients on post-operative day 5 when the negative suction drains were removed from the neck. A surface or needle EMG was performed depending on the patient compliance and location of the sutures under aseptic conditions at the department of neurology in the presence of a consultant neurologist and a qualified EMG technician.¹⁴⁻¹⁵

In a comparative evaluation of neural deficit of MMN using electromyography, Anterograde dissection technique proved to be more effective than Hayes Martin Manoeuvre for preservation of MMN as average spontaneous electrical activity on EMG reporting on HMM group patients and anterograde dissection patients was **45 uV** and **68 uV** respectively in 7 cases per group. The handling of nerve was kept to minimal during dissection through the ADT. Atraumatic instruments were put to use viz the vascular tissue forceps, tinotomy dissection scissors and a nerve hook or a nerve loop for the nerve handling. Use of the diathermy of negligible during the ADT.¹⁶

Although, no significant statistical difference was found when the neural function was compared on a house and brackmann grading scale, results indicated that Anterograde dissection technique proves to be positively efficacious than HMM for identification and preservation of MMN during the neck dissection.¹⁷⁻²¹

Limitations: Being a cancer centre in rural India, the self care awareness levels of the patients presenting to us is usually low to borderline ignorant leading to most common clinical staging of T4B with extra-oral fungation, skin involvement or skull base involvement. Hence, majority of cases present with involvement of facial muscles of expression at varying degrees especially depressor labii inferioris, depressor anguli oris and orbicularis oris as lower GB sulcus and alveolus malignancies compose the highest fraction of malignancies presenting to us. The aforementioned cases hence get excluded from the study sample posing as a formidable setback and limitation.

Interpretation: After the statistical analysis of variables from the collected data where the variables were statistically analysed as follows. The intraoperative time taken for both the studies was analysed using an independent t-test. The electromyographical activity was calculated and analysed using an independent t-test. And the house and brackmann grading was analysed using chisquare test. Based on intraoperative time taken for perifacial node clearance, efficacy of perifacial node clearance, electrical activity measured using EMG and House and Brackmann grading during the follow up period it can be inferred that with the exception of time taken for 1B and perifacial node clearance, Anterograde dissection technique has proven to be superior in terms of preservation of marginal mandibular nerve in terms of electrical activity measured by EMG and House and Brackmann grading scale.

Generalisability: The study is headed towards proving that the age old anterograde dissection technique is superior to the established Hayes Martin maneuver technique for identification and preservation of marginal mandibular nerve in terms of post-operative neural deficit and electrical activity.

Conclusion:

In our experience while conducting this study, we infer based on the results and statistical analysis that Hayes Martin maneuver and Anterograde dissection technique are both efficacious technique for identification and preservation of marginal mandibular nerve. Anterograde dissection technique is however technique sensitive, relatively time consuming and requires a higher surgical operator skill but provides statistically proven better results in terms of neural electric activity in the operated subjects.

References:

1. Riffat F, Buchanan MA, Mahrous AK, et al. Oncological safety of the Hayes-Martin maneuver in neck dissections for node-positive oropharyngeal squamous cell carcinoma. *J Laryngol Otol* 2012; 126:1045–1048
2. Tirelli G, Marcuzzo AV. Lymph nodes of the perimandibular area and the hazard of the Hayes Martin maneuver in neck dissection. *Otolaryngol Head Neck Surg* 2018; 159:692–697.
3. P murthy, Alberto Paderno, Balasubramanian, et al. Management of marginal mandibular nerve during and after neck dissection. *Curr Opin Otolaryngol Head Neck Surg* 2019, 27:104–109
4. Batstone MD, Scott B, Lowe D, Rogers SN. Marginal mandibular nerve injury during neck dissection and its impact on patient perception of appearance. *Head Neck* 2009; 31:673–678
5. Dingman RO, Grabb WC. Surgical anatomy of the mandibular ramus of the facial nerve based on the dissection of 100 facial halves. *Plast Reconst Surg* 1962; 29:266–690.
6. Baur DA, Kaiser AC, Leech BN, et al. The marginal mandibular nerve in relation to the inferior border of the mandible. *J Oral Maxillofac Surg* 2014; 72:2221–2226.
7. Gandhi, Rahul, Abhishek Singh Nayyar, Rahul Bhowate, Sweta Gandhi, and Girish Dongerwar. “Color Doppler Ultrasonography in Mapping Oral Squamous Cell Carcinoma.” *MIDDLE EAST JOURNAL OF CANCER* 6, no. 3 (July 2015): 179–87.
8. Agarwal, Priyanka, Minal Chaudhary, Alka Hande, Swati Patil, Madhuri Gawande, and Puneet Agarwal. “Evaluation of Incidence of Skip Metastasis in Patients of Oral Squamous Cell Carcinoma.” *MEDICAL SCIENCE* 8–9, no. 28–35 (June 2014): 53–57.
9. Agarwal, Priyanka, Minal Chaudhary, Swati Patil, Alka Hande, Madhuri Gawande, and Puneet Agarwal. “DIAGNOSTIC ACCURACY OF VARIOUS METHODS TO DETECT LYMPH NODE METASTASES IN ORAL SQUAMOUS CELL CARCINOMA.” *JOURNAL OF EVOLUTION OF MEDICAL AND DENTAL SCIENCES-JEMDS* 3, no. 22 (June 2, 2014): 6003–10. <https://doi.org/10.14260/jemds/2014/2696>.
10. Agni, N. A., G. S. Prasad V, R. M. Borle, S. Shukla, S. Grover, and S. Korde. “Assessment of Perineural Infiltration and Spread of Oral Squamous Cell Carcinoma: A Clinicohistopathologic Study.” *INDIAN JOURNAL OF CANCER* 47, no. 2 (June 2010): 199–205. <https://doi.org/10.4103/0019-509X.63024>.
11. Jaiswal, Shradha G., Amol R. Gadabail, Minal S. Chaudhary, Gagan R. Jaiswal, and Madhuri Gawande. “Correlation of Serum Levels of Vascular Endothelial Growth Factor with TNM

- Staging, Histopathologic Grading, and Surgical Therapy for Oral Squamous Cell Carcinoma.” *QUINTESSENCE INTERNATIONAL* 42, no. 9 (October 2011): 771–79.
12. Dhar R, Singh S, Talwar D, Mohan M, Tripathi SK, Swarnakar R, Trivedi S, Rajagopala S, D'Souza G, Padmanabhan A, Baburao A. Bronchiectasis in India: results from the European multicentre bronchiectasis audit and research collaboration (EMBARC) and respiratory research network of India registry. *The Lancet Global Health*. 2019 Sep 1;7(9):e1269-79.
 13. Prasad N, Bhatt M, Agarwal SK, Kohli HS, Gopalakrishnan N, Fernando E, Sahay M, Rajapurkar M, Chowdhary AR, Rathi M, Jeloka T. The adverse effect of COVID pandemic on the care of patients with kidney diseases in India. *Kidney international reports*. 2020 Sep 1;5(9):1545-50.
 14. Walia IS, Borle RM, Mehendiratta D, Yadav AO. Microbiology and antibiotic sensitivity of head and neck space infections of odontogenic origin. *Journal of maxillofacial and oral surgery*. 2014 Mar 1;13(1):16-21.
 15. Lohe VK, Degwekar SS, Bhowate RR, Kadu RP, Dangore SB. Evaluation of correlation of serum lipid profile in patients with oral cancer and precancer and its association with tobacco abuse. *Journal of oral pathology & medicine*. 2010 Feb;39(2):141-8.
 16. Korde S, Sridharan G, Gadbail A, Poornima V. Nitric oxide and oral cancer: A review. *Oral oncology*. 2012 Jun 1;48(6):475-83.
 17. Gondivkar SM, Gadbail AR. Gorham-Stout syndrome: a rare clinical entity and review of literature. *Oral Surgery, Oral Medicine, Oral Pathology, Oral Radiology, and Endodontology*. 2010 Feb 1;109(2):e41-8.
 18. Gadbail AR, Chaudhary M, Gawande M, Hande A, Sarode S, Tekade SA, Korde S, Zade P, Bhowate R, Borle R, Patil S. Oral squamous cell carcinoma in the background of oral submucous fibrosis is a distinct clinicopathological entity with better prognosis. *Journal of Oral Pathology & Medicine*. 2017 Jul;46(6):448-53.
 19. Gadre PK, Ramanojam S, Patankar A, Gadre KS. Nonvascularized bone grafting for mandibular reconstruction: myth or reality?. *Journal of Craniofacial Surgery*. 2011 Sep 1;22(5):1727-35.
 20. Sorte K, Sune P, Bhake A, Shivkumar VB, Gangane N, Basak A. Quantitative assessment of DNA damage directly in lens epithelial cells from senile cataract patients. *Molecular vision*. 2011;17:1.
 21. Basak S, Rajurkar MN, Mallick SK. Detection of *Blastocystis hominis*: a controversial human pathogen. *Parasitology research*. 2014 Jan;113(1):261-5.