

Original Research Article

**COMPARISON OF PREAURICULAR VERSUS
RETROMANDIBULAR APPROACH IN THE MANAGEMENT OF
MANDIBULAR CONDYLE FRACTURES**

ABSTRACT

Objective: To compare the rate of complications encountered on using different incision to access the fracture site for the open reduction and internal fixation of condylar fractures.

Setting: Department of Oral & Maxillofacial Surgery, Institute of Dentistry, LUMHS

Subject and Methods: A total 64 patients with unilateral condyle fracture were randomly treated into two groups. Thirty two patients in group A were treated with preauricular incision and 32 were treated with Retro mandibular incision. Patients was followed for period of six months for assessment of complications of facial nerve injury, salivary fistula and hypertrophic scar formation.

Results: The average age of the patients was 31.66±9.40 years. Rate of facial nerve palsy was significantly high in group A than group B (18.75% vs. 6.25%; p=0.021) similarly, the rate of salivary fistula and scar formation were also significantly high in group A as compare to groups B (12.5% vs. 1.56% p=0.026) and (14.06% vs. 1.56%;p=0.013) respectively.

Conclusion: The retromandibular approach is more suited for the lower level condylar neck fractures, providing a direct visual field and wide, straight-line access for implant fixation at this region.

Comment [u1]: fractures

Comment [u2]: were

Comment [u3]: upto

Comment [u4]: such as

Comment [u5]: you may also have option of, "more suitable",

Key words: Mandibular condyle, Condylar Fractures, Facial nerve palsy, Scar

Comment [u6]: maybe put in the first(before mandibular condyle)

INTRODUCTION

Fractures of the mandibular condylar process are relatively prevalent amongst lower jaw fractures, accounting for 17.5 % to 50% of all mandibular fractures. Road traffic tragedies, assaults, firearm injuries, industrial accidents, and sports injuries are all prominent causative contributors. Age group of 21 to 30 year old are more frequently involved with male to female ratio 3:1 [1-3]. Condylar fractures are defined as unilateral/bilateral, intracapsular (inside the head of the condyle), extra capsular (high condylar head and neck), sub condylar (low condyle fracture), and displaced. Swelling and pain over the tempomandibular joint area, limited mouth openness, and an anterior open bite are all clinical characteristics. [3, 4].

Comment [u7]: how about, Factors than contributors

Comment [u8]: and fractures with displacement?

Comment [u9]: opening

Comment [u10]: of condylar fractures

Intermaxillary stabilization accompanied by physiotherapy or open reduction by intraoral or extraoral incision can be used to address these injuries. [4] Closed reduction necessitates intermaxillary fixation for various time periods, which can result in complications such as joint discomfort, mandibular deviation, and insufficient ramus vertical height restoration [5]. Surgical treatment comprises fracture reduction and internal fixation by using titanium miniplates and screws, lag screws and krishner's wires [6]. The most commonly used access routes for open reduction and internal fixation are intraoral, extraoral preauricular, submandibular and retro mandibular incision. The intraoral route is less desirable due to limited exposure and trocar usage and dexterity, therefore extra oral route is most commonly selected one. However each of these incisions has varying degrees of complication due to proximity to vital structures namely facial nerve and parotid gland [7].

Comment [u11]: comma

Comment [u12]: the incision(singular after the each..

The preauricular method is the more typically employed for fixing high condylar fractures, although it has its own limits when it comes to managing low condylar fractures and angle exposure. Hinds and Girotti were the first to report the retro mandibular technique. It has a better operating proximity from the skin incisions to the condyle, better accessibility to the posterior edge of the mandible, a less visible facial scarring, and is easier to reduce^[8]. After open reduction of fractures of the condylar process several complications like infection, facial paralysis, salivary fistula, Frey's syndrome, auricotemporal nerve dysfunction and appearance of hypertrophic scar may occur^[9]. Different characteristics must be evaluated in order to determine which form of incision is best for each subject. Aside from the functional conclusion, unique side-effects of various surgical techniques (e.g. facial nerve damage, salivary fistula, visible scars, etc.) as well as patient experience must be taken into account^[10].

Comment [u13]: method

Comment [u14]: limitations

Comment [u15]: use Capital letter

Different study reported the different rate of complications with different techniques for fractures of the mandibular condyle. A study by Henschel J, et al. reported the facial nerve palsy in 25% vs 66.6%, salivary fistula 14.3% vs 0% and scar formation 17.8% vs 33.3% in retromandibular and preauricular group respectively^[10]. A study by Abhinandan Patel KN, et al. compared the different surgical approaches for fractures of the mandibular condyle and reported the facial nerve palsy in 5% vs 20% and scar formation in 10% vs 30% in pre-auricular and sub-mandibular groups respectively^[11].

Comment [u16]: groups

METHODOLOGY

This descriptive cross-sectional study with non probability consecutive sampling was performed at Department of Oral & Maxillofacial Surgery, Institute of Dentistry, LUMHS Jamshoro from August 2020 to July 2021. The sample size calculation was done using the WHO software for "Sample size calculation. By using the proportion of Handschel J, et al. who reported the facial nerve injury in 25% and 66.6% in retromandibular and preauricular group respectively [10], confidential interval 95%, power 90% and drop-out 10%, sample size becomes $n=64$ (32 in each group).

Comment [u17]: delete

- Group A (Preauricular approach) = 32 patients
- Group B (Retromandibular approach) = 32 patients

SAMPLE SELECTION:

INCLUSION CRITERIA:

- Either gender irrespective of caste, religion, socioeconomic status.
- Patient age range from 16 to 50
- Medically fit patients for general anesthesia.
- Unilateral condyle fracture(confirmed on clinical symptoms and 3D computed tomography (CT) scan).

Comment [u18]: better write both the sexes

Comment [u19]: years

EXCLUSION CRITERIA:

- Bilateral condyle fracture.
- Immunocompromised patient.
- Patient medically unfit for surgery under general anesthesia.
- Pregnant patient.

Comment [u20]: fractures

DATA COLLECTION PROCEDURE: This research comprised patients who met the inclusion requirements and were referred to the Outpatient Department (OPD) or the Emergency Department (ED). Every participant or attendant signed a documented permission form. On the Proforma, participant information such as name, age, gender, and hospital registration numbers were entered. After receiving clearance from the Ethical Review Committee, the study was carried out. Clinical assessment, orthopantomography (OPG), and P.A view of face were used to diagnose a mandibular condyle fracture.

Comment [u21]: in a consent document

Comment [u22]: sex

The patient gave his or her informed assent to the surgery. Utilizing the lottery approach, individuals were divided into two groups: A and B. Group A was provided for open reduction and internal stabilization of low condylar fractures, and the fracture was reduced and repaired with miniplates when adequate occlusion was achieved. Open reduction and internal fixation with miniplates were performed on group B using a retro-mandibular incision. Post operatively, patients of both the group will have regular follow up checkup at 1, 3 and 6 months.

Comment [u23]: consent

Comment [u24]: I think they were followed up

PROCEDURE: The patient was recommended to go to the hospital and was maintained nil per oral for 6 hours the day before procedure. The general anaesthesia permission was collected simultaneously on the day of operation by hospital staff. Before beginning surgery, the normal universal method for draping and preparation was followed. Procedure was carried out with lidocaine 2% with adrenaline 1:80000(max: 7.5 mg/ml) at the incision site. For group A (preauricular incision) an oblique incision is made through the tissues near the root of zygoma to enter the joint capsule and expose the condylar fracture. For group B (Retro mandibular incision) an incision was given 1.5 to 2 cm below the lower border of mandible, if possible employing the natural skin creases. Skin and platysma incised, ligating facial artery and vein. After incising pterygomasseteric sling the dissection continued superiorly to expose condyle fracture. Reduction is done using miniplates osteosynthesis and closure done with resorbable suture followed by proline 3.0. Patient was remained hemodynamically stable and was shifted to recovery room. Patients were followed for period of six months for assessment of complications of facial nerve injury, salivary fistula and hypertrophic scar formation.

Comment [u25]: surgical

Comment [u26]: maintained

DATA ANALYSIS PROCEDURE:

The Data was analyzed by statistical software package SPSS version 20.0. Mean and standard deviation was calculated for quantitative variables like age (years) and duration of fracture (days). Frequency and percentages was computed for qualitative variables like gender, age in groups, socioeconomic status, and residence, duration of fracture, etiology, diagnosis and post-operative complications including facial nerve

palsy, salivary fistula and scar formation. Complications were compared between groups by using chi-square test.

Effect modifier like gender, age in groups, socioeconomic status, and residence, duration of fracture, etiology and diagnosis was controlled by stratification by applying chi-square test and taking p value ≤ 0.05 as significant.

Comment [u27]: clinically

RESULTS

A total 64 patients with unilateral condyle fracture were randomly treated into two groups. Thirty two patients in group A were treated with preauricular incision and 32 were treated with Retro mandibular incision. The average age of the patients was 31.66 ± 9.40 years and average duration of fracture was 5.06 ± 0.99 days. Mean age and duration of fracture are also reported in Table 1. There were 45(70.3%) patients male and 19(29.7%) were female. Gender distribution according to groups is shown in figure 1.

Comment [u28]: male patients

Fall were the commonest etiology of fracture as presented in figure 2. There were 18(28.15) cases diagnosis by clinically and 46(71.9%) were proved by radio graphically as shown in figure 3.

Comment [u29]: Falls

Comparisons of rate of complications between groups are presented in Table 2. Rate of facial nerve palsy was significantly high in group A than group B (18.75% vs. 6.25%; $p=0.021$) similarly rate of salivary fistula and scar formation were also significantly high in group A as compare to groups B (12.5% vs. 1.56% $p=0.026$) and (14.06% vs. 1.56%; $p=0.013$) respectively.

TABLE 1

DESCRIPTIVE STATISTICS OF AGE AND DURATION OF FRACTURE

Variables	Group A [n=32]		Group B [n=32]	
	Mean	Std. Deviation	Mean	Std. Deviation
Age (Years)	30.38	7.95	32.94	10.63
Duration of Fracture (days)	5.22	0.83	4.91	1.12

FIGURE 1
GENDER DISTRIBUTION OF THE PATIENTS

n=64

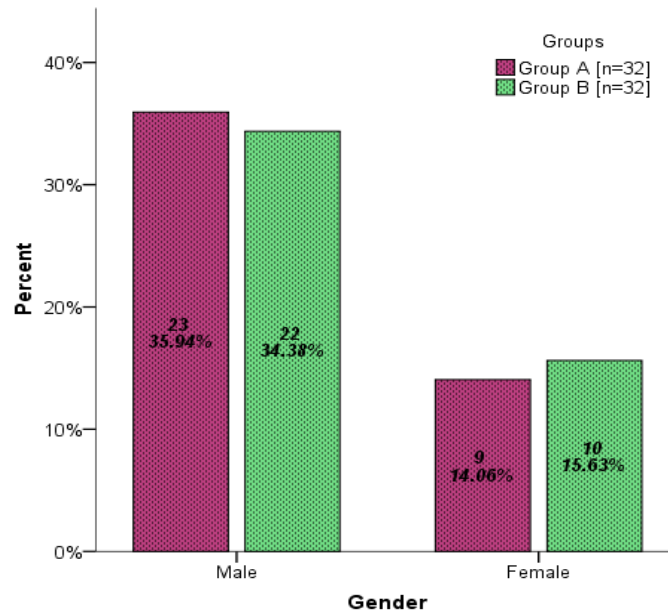


FIGURE 2
ETIOLOGY OF THE PATIENTS

n=64

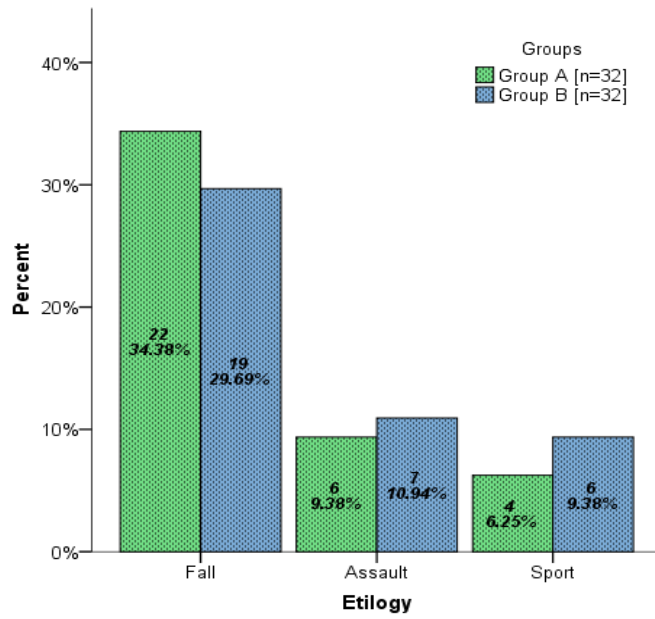


FIGURE 3
DIAGNOSIS OF THE PATIENTS
n=64

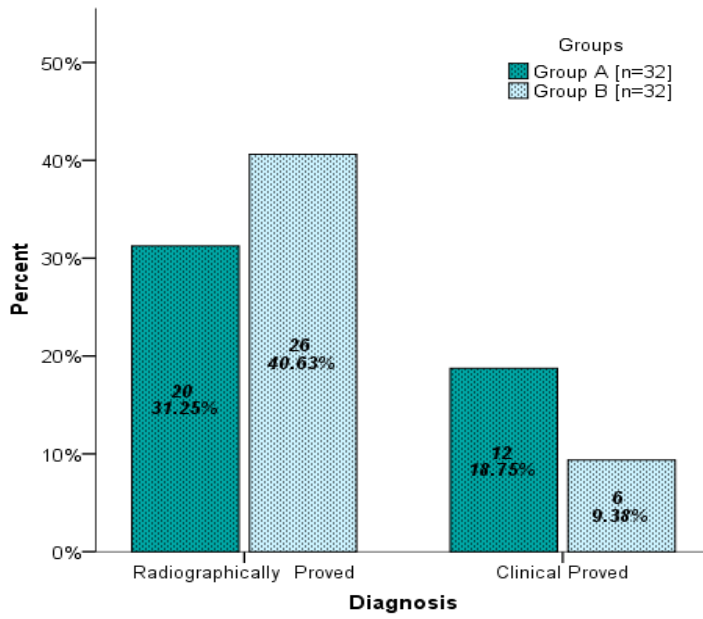


TABLE 2

COMPARISON OF RATE OF COMPLICATION BETWEEN GROUPS

Comment [u30]: The

Complications	Group A [n=32]		Group B [n=32]		P-Value
	Count	%	Count	%	
Facial Nerve Palsy	12	18.75%	4	6.25%	0.021
Salivary Fistula	8	12.50%	1	1.56%	0.026
Scar Formation	9	14.06%%	1	1.56%	0.013

DISCUSSION

The commonest frequent jaw fracture is a mandibular fracture.^[12] The more frequent mandibular traumas are mandibular condylar fractures, which occur in 18% to 57 % of adults and 24 % to 72 % of infants.^[13,14,15] Males are especially likely to suffer mandible fractures, and typical culprits of traumatic face injury comprise car crashes, assault, sports-related harm, falls, and workplace mishaps.^[13, 15, 16]

Comment [u31]: This maybe deleted

Comment [u32]: This may be deleted

Comment [u33]: Removed comma

Comment [u34]: Replace with fracture

Nonetheless, the best way to repair mandibular condylar breaks is yet up for debate.^[17,18] Apart for individuals with bilaterally condylar fractures, involving displacement or mild to extensive unilateral displacement with a dislocated condylar neck, there is no widespread agreement on the clinical considerations for ORIF and CR.^[19,20] Some supporters of conservative therapy point to the safety of CR, particularly in terms of averting surgical consequences, while others urge surgery for a faster return to functioning.^[21] Many investigations have shown that the two procedures provide similar leads, while others have found that ORIF leads in more flexibility, a reduced prevalence of malocclusion, and faster function resumption.^[21,22] According to Kotrashetti et al, an identical number of research endorse ORIF and CR.^[78] ORIF, on the other hand, is significantly logistically difficult and is linked to specific postoperative problems.^[21] In terms of mobility, malocclusion, discomfort, and chin deviation on mouth opening, latest meta-analyses support ORIF above CR, however ORIF is linked to a greater likelihood of infection.^[17]

Comment [u35]: Please define the ORIF and CR= open fixation and internal fixation and closed reduction first than start using the short forms

Comment [u36]: has

In this study the average age of the patients was 31.66 ± 9.40 years and average duration of fracture was 5.06 ± 0.99 days. A comparable outcome has also been recorded. When contrasted to a research by Newman et al, where the average age for condylar fractures was around 17 and 32 years, the mean age for all three categories was around 30-35 years. ^[23, 24]

Comment [u37]: Where? You need to link with the following sentences/findings

Males made up 70.3 % of the overall instances in this research, demonstrating that men are the primary labour class in our culture. This backs up the numbers from Badar and Hassan, which show a male-dominated population. ^[25,26] In contrast, Zachariades et al. observed no substantial disparity amongst males and females in a review analysis of 466 condylar fracture patients. ^[27] This is due to the reality that many women work outside in certain industries, exposing them to greater craniomaxillofacial fractures.

In our study rate of facial nerve palsy, of salivary fistula and scar formation was significantly high in group A (preauricular incision) than group B (Retro mandibular incision). Different study reported the different rate of complications with different techniques for fractures of the mandibular condyle. A study by Handschel J, et al. reported the facial nerve palsy in 25% vs 66.6%, salivary fistula 14.3% vs 0% and scar formation 17.8% vs 33.3% in retromandibular and preauricular group respectively ^[10]. A study by Abhinandan Patel KN, et al. compared the different surgical strategies for fractures of the mandibular condyle and reported the facial nerve palsy in 5% vs 20% and scar formation in 10% vs 30% in pre-auricular and sub-mandibular group respectively ^[11].

The incidences of complications documented in this analysis are within expected levels. The percentage of people who suffer from facial nerve damage varies between 0 and 21 %. The submandibular method was increasingly prevalent (20 percent). This might be due to the subcutaneous dissection in the submandibular technique, which crosses the marginal mandibular nerve profoundly, as opposed to the superficially traversing in the transparotid approach. ^[28] The pre-auricular method yielded the weakest results (5 percent). In compared to the preauricular category, submandibular and transparotid techniques had the most unfavorable scarring. Because the pre auricular incision is hidden in the pre auricular crease, it is not visible. Wound infection was higher (20%) in the submandibular group, comparing to 10% and 5% in the preauricular and transparotid groups, correspondingly. Owing to the greater proximity from the fracture site, the submandibular route necessitates a longer incision, greater exposing, and deeper tunnelling to approach the subcondylar region.

In a multicenter randomised clinical trial, Eckelt and coworkers reported better outcomes for ORIF of dislocated cracks (including the intraoral, submandibular, retromandibular, and preauricular approaches), whilst Marker and coworkers favored the CR strategy after reviewing 348 patients retrospectively. ^[29,30] Throckmorton et al. observed no meaningful variation among CR and ORIF in terms of "standard parameters (length and excursive ranges) of masticatory functioning" in a retrospective analysis of 81 individuals with subcondylar and condylar neck breaks. ^[31] Regrettably, the degree of dislocation/displacement was not documented in either study. After doing a clinical analysis (applying the preauricular technique), Landes and companions ^[32] came to the conclusion that closed therapy should be favored, While Neff et al^[33]

promote ORIF, the quantity of fractures considered in Landes et al (n = 17) research was substantially smaller than in Neff et al (n = 130), reducing the relevant significance of the earlier analysis. Generally, the level of impairment one year following therapy was unsatisfactory, but consistent with previous studies that employed the Helkimo index.^[34] Because the Helkimo dysfunction index aggregates a variety of functional factors, it can detect functional deficiencies early. Furthermore, the functional effect is only hazily identified in several cases.

UNDER PEER REVIEW

CONCLUSION

In our study Retro mandibular incision complications was low as compare to preauricular in the management of mandibular condyle fractures. Depending upon the level of the condylar fractures, a preauricular approach is ideal for the condylar head and high condylar neck fractures, providing direct and easy visualization to the region, for retrieval and repositioning of the medially displaced and dislocated proximal fracture fragment. The retromandibular approach is more suited for the lower level condylar neck fractures, providing a direct visual field and wide, straight-line access for implant fixation at this region.

REFERENCES

1. Jain P, Rathee M. Mandible Body Fracture. [Updated 2020 Jan 14]. In: StatPearls [Internet]. Treasure Island (FL): StatPearls Publishing; 2020 Jan-.
2. Yuen HW, Mazzoni T. Mandible Fracture. [Updated 2019 Oct 30]. In: StatPearls [Internet]. Treasure Island (FL): StatPearls Publishing; 2020 Jan-.
3. Shakya S, Zhang X, Liu L. Key points in surgical management of mandibular condylar fractures. *Chin J Traumatol.* 2020;23(2):63-70.
4. Pandey S, Roychoudhury A, Bhutia O, Singhal M, Sagar S, Pandey RM. Study of the pattern of maxillofacial fractures seen at a tertiary care hospital in north India. *J Maxillofacial Oral Surg.* 2015;14(1):32-39.
5. Tripathi GM, Sharma D, Dixit S, Bhat S, Yadav LS, Sharma RJ. Retromandibular approach for subcondylar fractures: a prospective study. *Int J Med Dent Sci.* 2018 Jan;7(1):1637-41.
6. Rao E, Naveen S, Rao RC, Kollabathula K, Srirambhatla M, Gandham S. Principle of Lag-Screw fixation in mandibular trauma. *Journal of International Society of Preventive & Community Dentistry.* 2019 May;9(3):282-9.
7. Balasubramanian S, Panneerselvam E, Gopi G, Prabhu Nakkeeran K, Rajendra Sharma A, et al. Comparison of two incisions for open reduction and internal fixation of

mandibular body fractures: A randomized controlled clinical trial evaluating the surgical outcome. *Chin J Traumatol*. 2019;22(1):34-40.

8. Mohan AP, Jeevan Kumar KA, Venkatesh V, Pavan Kumar B, Patil K. Comparison of preauricular approach versus retromandibular approach in management of condylar fractures. *J Maxillofac Oral Surg*. 2012 Dec;11(4):435-41.

9. Bayat M, Parvin M, Meybodi AA. Mandibular subcondylar fractures: a review on treatment strategies. *Electron Physician*. 2016 Oct;8(10):3144-9.

10. Handschel J, Rüggeberg T, Depprich R, Schwarz F, Meyer U, Kübler NR, et al. Comparison of various approaches for the treatment of fractures of the mandibular condylar process. *J Cranio Maxillofacial Surg*. 2012 Dec 1;40(8):e397-401.

11. Abhinandan Patel KN, Girish G, Sneha TR. Comparison of three surgical approaches for fractures of the mandibular condyle. *J Oral Surg Oral Med Oral Pathol Oral Radiol*. 2019;5(2):30-2.

12. Monnazzi MS, Gabrielli MAC, Gabrielli MFR. Treatment of mandibular condyle fractures. A 20-year review. *Dent Traumatol* 2017;33:175–80.

13. Shiju M, Rastogi S, Gupta P. Fractures of the mandibular condyle— open versus closed—a treatment dilemma. *J Craniomaxillofac Surg* 2015;43:448–51.

14. Rastogi S, Sharma S, Kumar S. Fracture of mandibular condyle—to open or not to open: an attempt to settle the controversy. *Oral Surg Oral Med Oral Pathol Oral Radiol* 2015;119:608–13.

15. Deleyiannis FW-B, Vecchione L, Martin B. Open reduction and internal fixation of dislocated condylar fractures in children: long-term clinical and radiologic outcomes. *Ann Plast Surg* 2006;57:495–501.

16. Pena IJr, Roberts LE, Guy WM. The cost and inpatient burden of treating mandible fractures: a nationwide inpatient sample database analysis. *Otolaryngol Head Neck Surg* 2014;151:591–8.
17. Liu Y, Bai N, Song G. Open versus closed treatment of unilateral moderately displaced mandibular condylar fractures: a meta-analysis of randomized controlled trials. *Oral Surg Oral Med Oral Pathol Oral Radiol* 2013;116:169–73.
18. Singh V, Bhagol A, Goel M. Outcomes of open versus closed treatment of mandibular subcondylar fractures: a prospective randomized study. *J Oral Maxillofac Surg* 2010;68:1304–9.
19. Snyder SK, Cunningham LLJr. The biology of open versus closed treatment of condylar fractures. *Atlas Oral Maxillofac Surg Clin North Am* 2017;25:35–46.
20. Kanno T, Sukegawa S, Tatsumi H. Does a retromandibular transparotid approach for the open treatment of condylar fractures result in facial nerve injury? *J Oral Maxillofac Surg* 2016;74:2019–32
21. Kotrashetti SM, Lingaraj JB, Khurana V. A comparative study of closed versus open reduction and internal fixation (using retromandibular approach) in the management of subcondylar fracture. *Oral Surg Oral Med Oral Pathol Oral Radiol* 2013;115:e7–11.
22. Ouyang D, Gu XM, Lei DL. Open reduction and rigid internal fixation of dislocated condylar fractures: a long-term follow-up of 25 patients. *Chin J Dent Res* 2011;14:147–50
23. Kuang SJ, He YQ, Zheng YH, Zhang ZG. Open reduction and internal fixation of mandibular condylar fractures. *Medicine* 2019;98:37

24. Steed MB. Where are the advancements in the management of mandibular condylar process fractures? *Atlas Oral Maxillofac Surg Clin North Am* 2017;25:ixdoi: 10.1016/j.cxom.2016.12.001.
25. Badar MA, Syed SA. Etiology of Mandibular Condylar Fractures; A Study From Tertiary Care Hospital of Lahore. *PODJ* 2014; 34(1):42-45.
26. Hassan SG, Shams S, Rehman M, Kumar S, Hamid S. Mandibular condyle fractures; a 2 years study at liaquat university hospital. *Professional Med J* 2016;23(6):705-708.
27. Zachariades N, Mezitis M, Mourouzis C, Papadakis D, Spanou A. Fractures of the mandibular condyle: a review of 466 cases. Literature review, reflections on treatment and proposals. *J Cranio-Maxillofac Surg.* 2006;34(7):421-32
28. Imai T, Fujita Y, Motoki A, Takaoka H, Kanesaki T, Ota Y, et al. Surgical approaches for condylar fractures related to facial nerve injury: deep versus superficial dissection. *Int J Oral Maxillofac Surg* 2019;1:1-5.
29. Eckelt U, Schneider M, Erasmus F, Gerlach KL, Kuhlisch E, Loukota R, et al. Open versus closed treatment of fractures of the mandibular condylar process-a prospective randomized multi-centre study. *J Craniomaxillofac Surg.* 2006; 34(5): 306-14.
30. Marker P, Nielsen A, Bastian HL. Fractures of the mandibular condyle. Part 2: results of treatment of 348 patients. *Br J Oral Maxillofac Surg.* 2000;38(5): 422-426.
31. Throckmorton GS, Ellis 3rd E, Hayasaki H. Masticatory motion after surgical or nonsurgical treatment for unilateral fractures of the mandibular condylar process. *J Oral Maxillofac Surg.* 2004; 62(2): 127e138.

32. Landes CA, Day K, Lipphardt R, Sader R: Closed versus open operative treatment of nondisplaced diacapitular (Class VI) fractures. *J Oral Maxillofac Surg.* 2008; 66(8): 1586-94.
33. Neff A, Kolk A, Neff F, Horch HH. Surgical vs. conservative therapy of diacapitular and high condylar fractures with dislocation. A comparison between MRI and axiography. *Mund Kiefer Gesichtschir.* 2002; 6(2): 66e73.
34. Hlawitschka M, Eckelt U. Assessment of patients treated for intracapsular fractures of the mandibular condyle by closed techniques. *J Oral Maxillofac Surg.* 2002 60(7): 784-791.

UNDER PEER REVIEW