

## Benign Paroxysmal Postural Vertigo (BPPV): A review

### Abstract –

**Background**– Benign paroxysmal postural vertigo is considered as the most frequent cause of vertigo worldwide because of which various times patient suffers the most dreaded complication which is not just because of vertigo but is due to the loss of balance during activities (such as driving and crossing the road, even while climbing up the stairs) and which is often misdiagnosed as a neurologic condition which further worsens the prognosis. This can be avoided by a simple OPD based maneuver (series of movements) as a diagnostic procedure in most of cases. Once diagnosed another series of movements (maneuver) can be performed to afford symptomatic relief.

**Objective**– To create a complete systematic review of the prevalent reason of dizziness i.e. benign paroxysmal postural vertigo (BPPV) along with its historic background, diagnostic modality (associated with various mannuvers). Also alternative methods of management considering their success rate and prognosis associated with precautions and primary measures (I.e. prevention or decrease of risk factors, precautions) and even to educate the patient about the disease.

**Methodology**– This article is reviewed from data taken from various articles found on various search engines like Google Scholars, PubMed, Research Gate along with the data taken from various books of the respective topics. Also the data searched from various search engines using the terms like BPPV, Vertigo, VOR, Dix - Hallpike Maneuver, Posterior Semicircular Canal, Superior Semicircular Canal.

**Conclusion** – BPPV is a simple disorder which can be misdiagnosed if the history is not taken properly or examination is not done correctly, it can severely affect the patients day to day activity and can be a very problematic condition if the attack is precipitated while activities like driving, crossing road, or even climbing, which can lead to dreaded complications. Henceforth it is a great topic of concern to resolve this disease which can be usually resolved by a simple OPD based management. AND can bring a great difference in the patient's life for GOOD.

**Keywords** - BPPV, Vertigo, VOR, Dix Hallpike Maneuver, Superior Semicircular Canal, Posterior Semicircular Canal, Benign paroxysmal positional vertigo

Comment [oa1]: Remove space

Comment [oa2]: maneuver

Comment [oa3]: Remove "of", it's redundant

Comment [oa4]: maneuver

Comment [oa5]: Remove the extra space

Comment [oa6]: Improperly placed punctuation mark

Comment [oa7]: maneuver

Comment [oa8]: A comma is missing after "also"

Comment [oa9]: "their"

Comment [oa10]: Remove a space

Comment [oa11]: "This"

Comment [oa12]: "on"

Comment [oa13]: A comma is missing after "Also"

Comment [oa14]: Remove the extra space

Comment [oa15]: That can

Comment [oa16]: This phrase could be changed to "driving or crossing the road"

Comment [oa17]: Remove the extra space after "climbing"

Comment [oa18]: "and"

Comment [oa19]: manoeuvre

**Introduction** - The most frequent peripheral vertigo is benign paroxysmal positional vertigo (BPPV) (1). **Dix along with hallpick** had discovered the diagnostic test which **is** till now is in use and even **considered** as the primary test for diagnosis of Benign paroxysmal postural **vertigo**. After this discovery, it was hypothesized that the disease was manifested due to detachment of otoconia. This could occur in any of the semicircular canals (2). Benign Paroxysmal Positional Vertigo (BPPV) is a disease **which is** characterized by short bouts of dizziness which may be about 35-45 seconds **long**, These bouts are **a** result of changes in **movement of head** in relation to gravitational force. It does not seem to be associated with hearing loss or ringing of ear (3). Dizziness, lightheadedness, disequilibrium, **and** regurgitation, retching, paleness, and sweating are the most common clinical signs of BPPV (4).

**Comment [oa20]:** Dix with Hallpick

**Comment [oa21]:** "considered"

**Comment [oa22]:** Remove extra space

**Comment [oa23]:** Change to "that is "

**Comment [oa24]:** Remove extra space

**Comment [oa25]:** Consider changing this to "as"

**Comment [oa26]:** "the movement of the head"

**Methodology** - This article is reviewed from data taken from various articles found on various search engines and to maintain the authenticity some of **data is** also taken from various books as a **refrenee**. few search engines from where the data **has** been taken are as follows, Google Scholar, PubMed and scopus. Along with this **the** references from various literature are also inculcated while reviewing **the** this article. **Along** with these **resources** various books of similar topics have also been reviewed

**Comment [oa27]:** "the data were"

**Comment [oa28]:** "reference"

**Comment [oa29]:** "had"

**Comment [oa30]:** Improper space

**Comment [oa31]:** A comma is missing

**Comment [oa32]:** "the" before this word

**Comment [oa33]:** Remove extra space

**Comment [oa34]:** remove extra space

**Comment [oa35]:** "the" before this word

**Anatomy**-there are two labyrinths in **inner** ear in which the labyrinth which is membranous one contains endolymph and the second one which is osseous or bony **labyrinth contains** perilymph along **with** **otic** capsule of bone that is enclosing the bony part of **inner** ear have all been examined(5). The vestibular receptors' perception and conversion of motion stimuli, as well as unimpaired postural control and intact visual acuity, are all required for spatial orientation. "Vertigo," "dizziness," and "imbalance" are all symptoms of disturbances in these three sensory systems. The function of peripheral receptors, particularly the three semicircular canals, plays a minor role. Symptoms of abnormalities in these three sensory systems include vertigo, dizziness, and imbalance. The three semicircular canals, in particular, play a small role in peripheral receptor function. Receptors of the Peripheral vestibular system can be tested by modern lateral-specific testing approaches. Head Impulse Test (HIT) (**now a days have** gained **popularity and** rean upper hand as a testing approach) and video HIT (are used to analyze the function of semicircular canals, along with the caloric test.(6)

**Comment [oa36]:** "nowadays"

**Comment [oa37]:** "has"

**Comment [oa38]:** Remove extra space

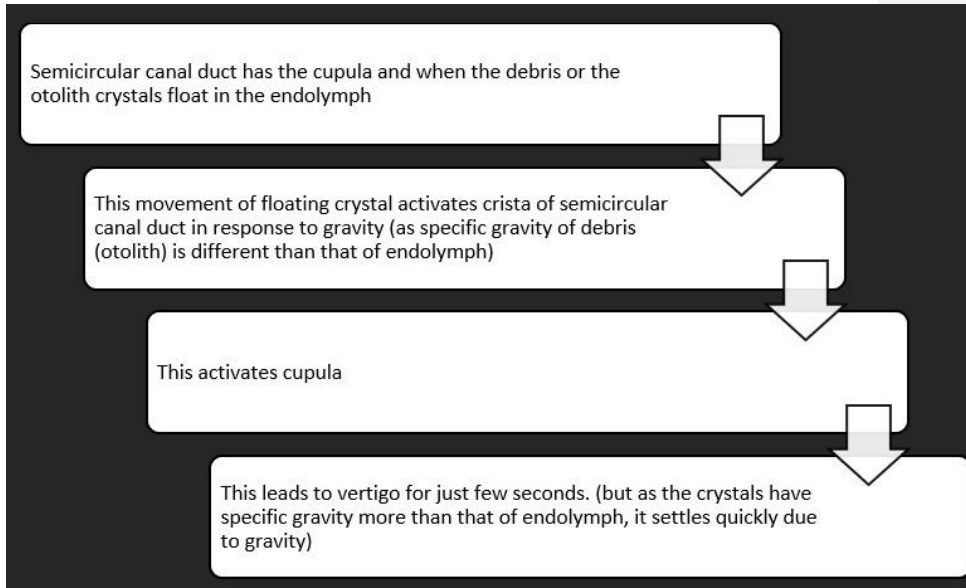
**Physiology** - **As the** cupula has the same specific gravity as **the** that of endolymph (represented by **steinhausen's** phenomenological equation) (7), Because the density difference between the cupula and the endolymph is as little as 10<sup>-4</sup> gram per cubic centimeter, the semicircular canal ducts detect rotational acceleration and are unaffected by gravity, they do not disrupt the cupula when it moves with gravity (8).

**Comment [oa39]:** Remove extra space

**Comment [oa40]:** "Steinhausen's"

**Pathophysiology** - (9), (10), (11)

Flow chart 1. Pathophysiology



**Normal Vor** -The vestibulo-ocular reflex (VOR) keeps the line of sight in space stable during head movements by shifting the eyes in the opposite direction of the head. The **non central** afferent apparatus (which can be considered as a series of motion detectors, mainly the semicircular canals and **otolith crystals along with** superior semicircular canal) , central component (which is **basically** used for processing the information brought the afferent system) along with efferent output mechanism, forms the most basic components of visual ocular reflex ( the eye muscles )While the semicircular canals detect head rotation via angular acceleration, the otolith organs detect the linear acceleration. The linear acceleration helps in detecting not only the head translation but ~~it~~ also helps in proprioception of **head** with respect to gravitational force. The semicircular canals are set up in **push and pull** pattern. In this pattern, the two canals which are co-planar such as the horizontal and the lateral **canal** that are present on each side cooperating with the **other** .If one section of the angular head is activated, the other is repressed, and vice versa. Whenever the head is at the state of rest ( that is when the position of **head** is stable ) at that time normally there is the **pulsatile release** from the sensory apparatus, which maintains the equilibrium between similar (horizontal) canals and when the head moves there is a change in the impulse rate between the semicircular canal pairs which then correlates the velocity of the movement of **head** (that is during rotation ) this is further assumed **as one of** the experimental findings ,that even **from** stimulating single semicircular canal precipitates a slow phase eye motion that spins the sphere in the plane of stimulated canal through the vestibular ocular reflex ( that is VOR) (12) .

**Risk Factors -**

- Aging(13)
- Migraine(14),(15)

**Comment [oa41]:** "non-central"

**Comment [oa42]:** remove extra space

**Comment [oa43]:** "with"

**Comment [oa44]:** Remove this, it's redundant

**Comment [oa45]:** "the"

**Comment [oa46]:** "a push-and-pull"

**Comment [oa47]:** "canals"

**Comment [oa48]:** Remove the extra space

**Comment [oa49]:** "the head"

**Comment [oa50]:** Remove the extra space

**Comment [oa51]:** "the"

**Comment [oa52]:** Remove the extra space

**Comment [oa53]:** "of"

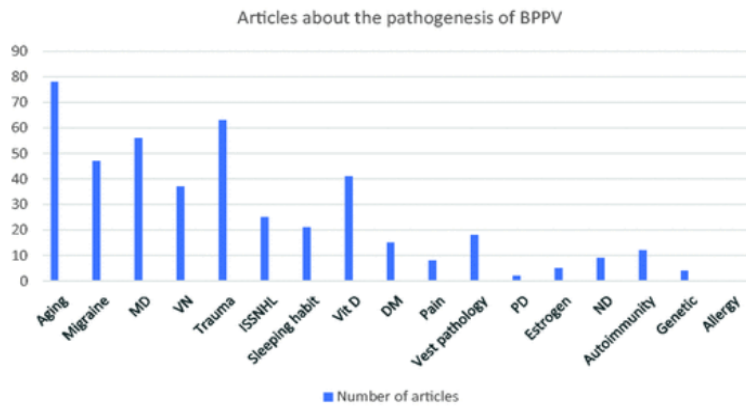
**Comment [oa54]:** remove the extra spaces

**Comment [oa55]:** ??????

**Comment [oa56]:** You may need to recheck this statement because the meaning is not clear

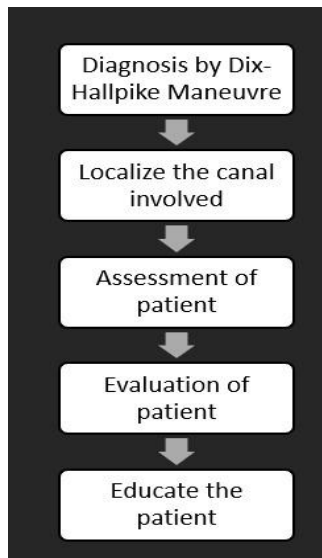
- Trauma(16)
- Meniere’s Disease (17)
- Vestibular Neuritis(15) , (19)
- Idiopathic Sudden Sensorineural Hearing Loss(20)
- Vitamin D Deficiency(21),
- Pigment Disorder(22) , (23)
- Allergy,
- Autoimmunity(24) (25)
- Diabetes Mellitus (26) (27)
- Genetic Prevalance (28),
- Estrogen Levels(29)
- Neurological Disorder (30)

The Chart Given Below Shows The Prevalences(31).



**Figure 1.** Distribution of articles focusing on the pathogenesis of BPPV. BPPV, benign paroxysmal positional vertigo; MD, Meniere’s disease; VN, vestibular neuronitis; ISSHL, idiopathic sudden sensorineural hearing loss; Vit D, vitamin D deficiency; PD, pigmentation disorder; ND, neurological disorder.

**Flow chart 2. Management** - Statements of Action Clinicians should follow the update group's



firm recommendations. 1) Diagnosis is said to be posterior canal BPPV if conducting Dix Hallpike produces dizziness with rotational upbeat nystagmus. The procedure for Dix Hallpike involves transferring the patient to a supine posture, while his head is turned to 45 degree to one side and the neck is kept in extended position at 20 degree with the diseased ear down, and 2) perform a canalith repositioning operation on patients with posterior canal BPPV, or send them to a clinician who is capable of doing the job. Now, Once the canalith repositioning procedure is done for treatment of posterior canal BPPV, the guideline strongly advised against post procedural postural constraints..

The update group gave suggestions for the clinician to consider-1) If the deceased has a associated past complaints consistent with benign paroxysmal positional vertigo and the Dix-Hallpike maneuver ( which is also a diagnostic test of benign paroxysmal postural vertigo) shows an involuntary movement of eye in the naso - temporal axis or even if any involuntary movement of eyes are absent, conduct Pagnini Mcclure maneuver (also known as supine roll test, a test done generally for the screening of benign paroxysmal postural vertigo involving horizontal semicircular canal), or consider the help of a registered medical practitioner, the one who is able to conduct, a supine roll test to screen for lateral SCC benign paroxysmal postural vertigo ; 2) distinguish benign paroxysmal postural vertigo from rest of the causes of lack of balance ,vertigo and dizziness or consider a professional who can.; 3) now examine the deceased , with benign paroxysmal postural vertigo , for characteristics which can change the line of diagnosis along with way to deal with the condition along with the line of treatment ,these features can be as follows , reduced movements and equilibrium , problems from higher centers ( that is any type of disturbance in central nervous system) , stress ,family support and a higher prevalence of trauma ; 4) Following the treatment (OPD based management that is maneuver or any proper treatment that can be either pharmacological or surgical) in the initial months patients are usually asked to come after specific durations for follow ups ,so that the symptoms

**Comment [oa57]:** Remove the extra spaces

**Comment [oa58]:** "degrees"

**Comment [oa59]:** Remove extra space

**Comment [oa60]:** "an extended position at 20degrees"

**Comment [oa61]:** Remove the extra spaces

**Comment [oa62]:** "post-procedural

**Comment [oa63]:** "patient"

**Comment [oa64]:** Remove the extra spaces

**Comment [oa65]:** Remove the extra space

**Comment [oa66]:** "manoeuvre"

**Comment [oa67]:** "the" before this word

**Comment [oa68]:** "manoeuvre"

**Comment [oa69]:** Remove the extra space

**Comment [oa70]:** Consider changing this to "can"

**Comment [oa71]:** remove the extra space

**Comment [oa72]:** Paroxysmal

**Comment [oa73]:** Remove the extra spaces

**Comment [oa74]:** ?????

or any kind of remissions, if any can be documented .5) and if the patient is still showing any persistent signs and symptoms in consistency with benign paroxysmal postural vertigo with or without any central or non central ( that is peripheral )disorder , 6) we have to decide futher line of management and along with this we also have to make patient aware of the effect of benign paroxysmal postural vertigo on their life style along with precautionary measures , modifications to be made ,risks or chances of recurrences along with the need and importance of regular and timely follow ups and also one has to mention the consequences of avoiding or delaying the regular and timely visits .

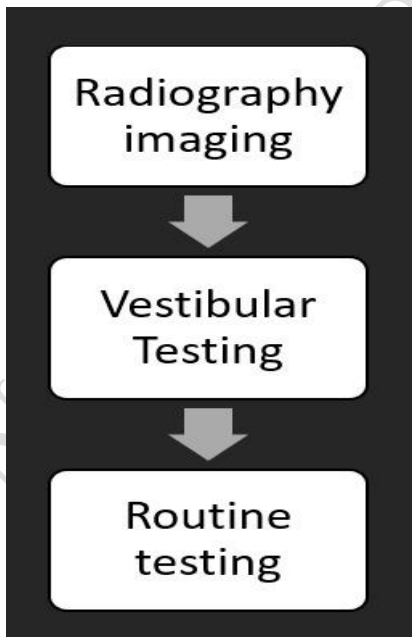
**- The update was advised against:**

1) performing some of the radiological imaging on a deceased ,the one who satisfies all the diagnostic criteria for posterior Benign paroxysmal positional vertigo. Also make sure (rule out ) that he patient should not have any additional signs or symptoms which are not consistent with the diagnosis that warrant radiographic imaging.

2) prescribing suppressants such as antihistamines and benzodiazepines to patients of BPPV who do not have any additional signs or symptoms that are not consistent with BPPV which may indicate further testing (32) .

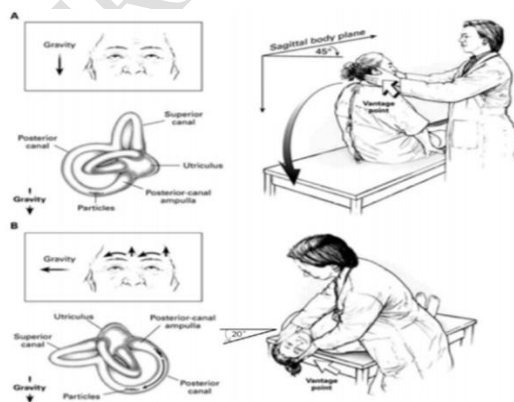
- Comment [oa75]: Remove a space
- Comment [oa76]: Remove space
- Comment [oa77]: A comma should be after this word
- Comment [oa78]: "the"
- Comment [oa79]: "warrants"

**Flow chart 3. Diagnosis-**



The most frequent and most cause cause of peripheral ~~ev~~vertigo is benign paroxysmal positional vertigo (BPPV), which mainly affects the posterior and/or lateral semicircular canals. The classical feature of BPPV ~~in short~~ is dizziness of rotational nature along ~~re~~with positional to and fro movement of the eyes i.e. nystagmus. This is generally seen due to specific head postures or movement of head with respect to cogravitational force. The Dix Hallpike maneuver causes rotational to and from ~~movement~~ of the eyes in patients with posterior SCC involving benign ~~paroxysmal~~ positional vertigo. The supine roll test ~~causal~~ nasal-temporal to and fro movement of eye which may be geotropic or apogeotropic in person suffering from lateral SCC benign paroxysmal positional vertigo. Canalolithiasis, which consists of otoconial debris which ~~are!~~ freely floating within the watery fluid in the membranous labyrinth of the inner ear (also known as endolymph ) of a semicircular canal, or can be due to cupulolithiasis, which consists of otoconial debris adhered to the cupula, is assumed as the pathophysiology of BPPV (1) .

**OPD Based Management -** The Dix Hallpike maneuver is contemplated to be the standard test for the detection of the posterior canal Benign paroxysmal positional vertigo. The ~~dix~~ Hallpike maneuver is considered to be the most important diagnostic criterion to check the eligibility for enrolling in clinical trials. There seems to be no alternative to Dix Hallpike maneuver as the external gold standard. This has ~~lead~~ to very few sensitivity and specificity statistics. Even though it is considered to be the gold standard, it is fallible. The accuracy may depend on various factors, such as whether the clinician is a specialist or not. According to the article by Lopez-Escamez et al, the Dix Hallpike ~~manemuver~~ is said to ~~havea~~ sensitivity of 82% while specificity ~~was resulted as~~ 71 per cent among ~~specialty~~ doctors in patients of posterior canal Benign paroxysmal positional vertigo. Hanley and O'Dowd found that positive Dix Hallpike ~~have~~ an 83 per cent predictive value and a 52 per cent NVP ( negative predictive value ) for the detection of BPPV. This indicates that a negative Dix Hallpike does not necessarily rule out BPPV. For a more accurate diagnosis, it may be helpful to conduct Dix Hallpike maneuver at a separate visit to reassess the outcome. This helps in avoiding a false negative (that is to decrease the chances of error ) result. Factors ~~which~~ can affect the sensitivity and specificity (accuracy ) of Dix Hallpike are: the pace of the head deviation ( movements ) during the test, diurnal variation ( that is the time of the day), the occipital plane angle, during the maneuver. Dix Hallpike can also be



**Figure 1.** Diagrammatic representation of performance of the Dix-Hallpike maneuver for the diagnosis of posterior canal benign paroxysmal positional vertigo (BPPV). In panel A, the examiner stands at the patient's right side and rotates the patient's head 45° to the right to align the right posterior semicircular canal with the sagittal plane of the body. In panel B, the examiner moves the patient, whose eyes are open, from the seated to the supine right-ear-down position and then extends the patient's neck 20° so that the chin is pointed slightly upward. The latency, duration, and direction of nystagmus, if present, and the latency and duration of vertigo, if present, should be noted. The arrows in the inset depict the direction of nystagmus in patients with typical BPPV. A presumed location in the labyrinth of the free-floating debris thought to cause the disorder is also shown. From *New England Journal of Medicine*, Furman JM, Case SR: "Benign Paroxysmal Positional Vertigo," 341:1590-1596. Copyright © 1999 Massachusetts Medical Society. Adapted and reprinted with permission from Massachusetts Medical Society.

- Comment [oa80]: Remove space
- Comment [oa81]: Move spaces
- Comment [oa82]: vertigo
- Comment [oa83]: Consider removing this phrase
- Comment [oa84]: Remove space
- Comment [oa85]: "with"
- Comment [oa86]: "the" should be before this word
- Comment [oa87]: Consider replacing this phrase with "in relation to"
- Comment [oa88]: "gravitational"
- Comment [oa89]: manoeuvre
- Comment [oa90]: "to-and-fro"
- Comment [oa91]: "movement"
- Comment [oa92]: Remove space
- Comment [oa93]: "paroxysmal"
- Comment [oa94]: causes
- Comment [oa95]: Consider changing this sentence to "the supine roll test that causes nasal-temporal to-and-fro movement of the eyes which may be geographic or apogeotropic; especially in persons suffering from lateral SCC benign paroxysmal vertigo"
- Comment [oa96]: Remove space
- Comment [oa97]: "is"
- Comment [oa98]: Remove spaces
- Comment [oa99]: Remove space
- Comment [oa100]: Remove space
- Comment [oa101]: manoeuvre
- Comment [oa102]: Remove space
- Comment [oa103]: Dix
- Comment [oa104]: Manoeuvre
- Comment [oa105]: "the" should be before th [...]
- Comment [oa106]: Manoeuvre
- Comment [oa107]: led
- Comment [oa108]: Manoeuvre
- Comment [oa109]: "have a"
- Comment [oa110]: Consider replacing with [...]
- Comment [oa111]: "speciality"
- Comment [oa112]: "with"
- Comment [oa113]: "the" should be before th [...]
- Comment [oa114]: manoeuvre
- Comment [oa115]: Consider replacing with [...]
- Comment [oa116]: Manoeuvre
- Comment [oa117]: Remove space

conducted bilaterally to give an idea **which** of the ears (or both) is damaged. This may be helpful if the diagnosis is not evident after conducting the test the first time. Dix Hallpike **maneuver** can be positive **in** both sides respectively but seen only in a limited percentage of cases. Bilaterally positive Dix Hallpike (series of movement) is interpreted such that each ear simultaneously will **be in the reliant position** elicits the correspondingly appropriate nystagmus. **Diagram of respective maneuver is given below** (32),(33) .

**Comment [oa118]:** "about" should be before this word

**Comment [oa119]:** Manoeuvre

**Comment [oa120]:** on

**Comment [oa121]:** Remove spaces

**Comment [oa122]:** "the respective manoeuvre"

**Adverse Effects of Maneuver-** Repositioning **maneuvers** have **little** negative consequences. The one most feared risk of neck extension is vertebral artery damage, so patients with vascular problems should exercise extreme caution. Prolonged autonomic dysfunction and imbalance may develop in a small fraction of individuals after PRM.(34).

**Comment [oa123]:** manoeuvres

**Comment [oa124]:** Consider replacing with "few"

**Surgery-** Generally, surgery is reserved for the most awful instances that are highly recurrent, and before a physician chooses surgery, he must rule out any other BPPV DDs. A person can choose between two surgical approaches: singular neurectomy or posterior semicircular canal occlusion.

In which SINGULAR NURECTOMY-- made popular by GARECK It's a BPPV-specific treatment designed to go into the single canal and transect the post. ampullary nerve, which only innervates the posterior semicircular canal ampulla. This operation entails elevating a tympanomeatal flap and drilling inferior to the round window to access the unique canal, although it has a higher chance of damaging both the ampulla and the vestibule, which can cause severe vertigo if harmed.

GACEK's initial findings showed success with complete vertigo resolution in the majority of patients (91.7%), but (7.3%) showed **sensorineural** hearing loss, which was addressed with this modality.(35)

**Comment [oa125]:** "a" should be before this word

Posterior Semicircular Canal Occlusion- Parnes And McClure Development The goal of the surgery was to obstruct the posterior canals membranous duct, which would prevent endolymph from flowing into the cupula, effectively fixing it. The fixed cupula would be unresponsive to both angular acceleration force and stimulation due to **free floating** particles in the endolymph or fixed copular deposits. The surgery is usually carried out under general anesthesia.(36)

**Comment [oa126]:** "free-floating"

**Atypical Bppv** -lateral Canal CRPs used for the posterior canal type are frequently ineffective against BPPV. There are, however, **a number of** other repositioning **maneuvers** that can be used to transfer the otoliths from the horizontal semicircular canal to the utricle and saccule. The Lempert (barbecue roll) move is one of the most prevalent, In the Lempert, the particles are realigned via a series of steps at the end of which the patient has rolled complete 360° (37-47) .

**Comment [oa127]:** Consider replacing with "several"

**Comment [oa128]:** manoeuvres

**Vestibular Rehabilitation** - Vestibular rehabilitation promotes **stability** of eye movements during head movements. This results in **improved** connection between vestibular and ocular systems during head movement. It also expands static and dynamic balance and posture. Goals of vestibular rehabilitation: dynamic balance along with static balance and posture should be increased through improving the visual-vestibular connection. quality of life should be improved. Symptoms of dizziness and anxiety should be relieved (3).

**Comment [oa129]:** "the" should be before this word

**Comment [oa130]:** "an" should be before this word

**DIFFERENTIAL DIAGNOSIS – differential diagnosis can be classified into 3 major categories given as follows – Haematological**

## -Neurological and

ss -Others (38).

Hematological	Neurological	Other
<ul style="list-style-type: none"><li>• Brainstem or cerebellar hemorrhage</li><li>• Vertebrobasilar insufficiency</li><li>• Vertebral artery dissection</li><li>• Brainstem or cerebellar infarction</li></ul>	<ul style="list-style-type: none"><li>• Vestibular neuritis</li><li>• Labyrinthitis</li><li>• Brainstem encephalitis</li></ul>	<ul style="list-style-type: none"><li>• traumatic vestibulopathy</li><li>• Cerebellopontine angle neoplasm</li><li>• vestibular migraine</li><li>• herpes zoster oticus</li><li>• decompression sickness</li></ul>

### Conclusion\_

After all this data BPPV (Benign Paroxysmal Positional vertigo ) can be considered as a most common cause of vertigo as compared to other cause of the vertigo .with various pathogenesis including, dislocation of otolith, Abnormal stimulation of membrane, aging , Meniers disease, pain, SNHL, Diabetes mellitus,etc . And which(BPPV) can be treated with a simple OPD based maneuver (DIX-HALLPIKE) ,if diagnosed accurately and timely ,this inconvenient and troublesome disorder can be treated in no time allowing the patient to resume his/her daily activity only with, some precaution and education about the disease.

Comment [oa131]: Remove spaces

Comment [oa132]: causes

Comment [oa133]: ageing

Comment [oa134]: "Meniere's"

Comment [oa135]: Manoeuvre

Comment [oa136]: Consider replacing with "on time"

### COMPETING INTERESTS DISCLAIMER:

Authors have declared that no competing interests exist. The products used for this research are commonly and predominantly use products in our area of research and country. There is absolutely no conflict of interest between the authors and producers of the products because we do not intend to use these products as an avenue for any litigation but for the advancement of knowledge. Also, the research was not funded by the producing company rather it was funded by personal efforts of the authors.

Comment [oa137]: "used"

## References:

1. Imai T, Takeda N, Ikezono T, Shigeno K, Asai M, Watanabe Y, et al. Classification, diagnostic criteria and management of benign paroxysmal positional vertigo. *Auris Nasus Larynx*. 2017 Feb;44(1):1–6.
2. (PDF) Benign Paroxysmal Positional Vertigo (BPPV): History, Pathophysiology, Office Treatment and Future Directions. ResearchGate [Internet]. [cited 2021 Aug 8]; Available from: [https://www.researchgate.net/publication/51539836\\_Benign\\_Paroxysmal\\_Positional\\_Vertigo\\_BPPV\\_History\\_Pathophysiology\\_Office\\_Treatment\\_and\\_Future\\_Directions](https://www.researchgate.net/publication/51539836_Benign_Paroxysmal_Positional_Vertigo_BPPV_History_Pathophysiology_Office_Treatment_and_Future_Directions)
3. Bressi F, Vella P, Casale M, Moffa A, Sabatino L, Lopez MA, et al. Vestibular rehabilitation in benign paroxysmal positional vertigo: Reality or fiction? *Int J Immunopathol Pharmacol*. 2017 Jun;30(2):113–22.
4. Salvinelli F, Firrisi L, Casale M, Trivelli M, D'Ascanio L, Lamanna F, et al. Benign paroxysmal positional vertigo: diagnosis and treatment. *Clin Ter*. 2004 Sep;155(9):395–400.
5. Donaldson JA. Normal anatomy of the inner ear. *Otolaryngol Clin North Am*. 1975 Jun;8(2):267–9.
6. Walther LE, Hörmann K, Bloching M, Blödw A. [Receptor function of the semicircular canals: Part 1: anatomy, physiology, diagnosis and normal findings]. *HNO*. 2012 Jan;60(1):75–87; quiz 88.
7. Kondrachuk AV, Sirenko SP, Boyle R. Effect of difference of cupula and endolymph densities on the dynamics of semicircular canal. *Journal of Vestibular Research*. 2008 Jan 1;18(2–3):69–88.
8. Kondrachuk A, Boyle R. The Density Difference of Cupula and Endolymph Changes the Mechanics of Semicircular Canals. *Microgravity Science and Technology - MICROGRAVITY SCI TECHNOL*. 2011 Nov 1;23.
9. Parnes LS, McClure JA. Free-floating endolymph particles: a new operative finding during posterior semicircular canal occlusion. *Laryngoscope*. 1992 Sep;102(9):988–92.
10. Schuknecht HF. Cupulolithiasis. *Arch Otolaryngol*. 1969 Dec;90(6):765–78.
11. Welling DB, Parnes LS, O'Brien B, Bakaletz LO, Brackmann DE, Hinojosa R. Particulate matter in the posterior semicircular canal. *Laryngoscope*. 1997 Jan;107(1):90–4.
12. Fetter M. Vestibulo-Ocular Reflex. *Neuro-Ophthalmology*. 2007;40:35–51.
13. Fujimoto C, Kawahara T, Kinoshita M, Kikkawa YS, Sugawara K, Yagi M, et al. Aging Is a Risk Factor for Utricular Dysfunction in Idiopathic Benign Paroxysmal Positional Vertigo. *Front Neurol*. 2018 Dec 3;9:1049.

14. Teixido M, Baker A, Isildak H. Migraine and benign paroxysmal positional vertigo: a single-institution review. *The Journal of Laryngology & Otology*. 2017 Jun;131(6):508–13.
15. Chu C-H, Liu C-J, Lin L-Y, Chen T-J, Wang S-J. Migraine is associated with an increased risk for benign paroxysmal positional vertigo: a nationwide population-based study. *J Headache Pain*. 2015 Jul 4;16:62.
16. Pisani V, Mazzone S, Di Mauro R, Giacomini PG, Di Girolamo S. A survey of the nature of trauma of post-traumatic benign paroxysmal positional vertigo. *International Journal of Audiology*. 2015 May 4;54(5):329–33.
17. Mikael Karlberg KH Nicole Quickert, Janet Hinson, G Michael Halmagyi. What Inner Ear Diseases Cause Benign Paroxysmal Positional Vertigo? *Acta Oto-Laryngologica*. 2000 Jan 1;120(3):380–5.
18. Mandalà M, Santoro GP, Awrey J, Nuti D. Vestibular neuritis: recurrence and incidence of secondary benign paroxysmal positional vertigo. *Acta Oto-Laryngologica*. 2010 May 1;130(5):565–7.
19. Zapala DA, Shapiro SA, Lundy LB, Leming DT. Simultaneous Acute Superior Nerve Neurolabyrinthitis and Benign Paroxysmal Positional Vertigo. *J Am Acad Audiol*. 2006 Jul;17(7):481–6.
20. Clinical analysis of patients with idiopathic sudden sensorineural hearing loss and benign paroxysmal positional vertigo: *Acta Oto-Laryngologica*: Vol 133, No 5 [Internet]. [cited 2021 Aug 17]. Available from: <https://www.tandfonline.com/doi/abs/10.3109/00016489.2012.754996>
21. Parham K, Leonard G, Feinn RS, Lafreniere D, Kenny AM. Prospective clinical investigation of the relationship between idiopathic benign paroxysmal positional vertigo and bone turnover: A pilot study. *The Laryngoscope*. 2013 Nov;123(11):2834–9.
22. Moellmann G, Klein-Angerer S, Scollay DA, Nordlund JJ, Lerner AB. Extracellular Granular Material and Degeneration of Keratinocytes in the Normally Pigmented Epidermis of Patients with Vitiligo. *Journal of Investigative Dermatology*. 1982 Nov 1;79(5):321–30.
23. Gill SS, Salt AN. Quantitative differences in endolymphatic calcium and endocochlear potential between pigmented and albino guinea pigs. *Hearing Research*. 1997 Nov 1;113(1):191–7.
24. Giant Cell Arteritis: A New Association with Benign Paroxysmal Positional Vertigo - Amor- Dorado - 2004 - *The Laryngoscope* - Wiley Online Library [Internet]. [cited 2021 Aug 17]. Available from: <https://onlinelibrary.wiley.com/doi/abs/10.1097/00005537-200408000-00020>
25. Sari K, Yildirim T, Borekci H, Akin I, Aydin R, Ozkiris M. The relationship between benign paroxysmal positional vertigo and thyroid autoimmunity. *Acta Oto-Laryngologica*. 2015 Aug 3;135(8):754–7.

26. Yoda S, Cureoglu S, Yildirim-Baylan M, Morita N, Fukushima H, Harada T, et al. Association between Type 1 Diabetes Mellitus and Deposits in the Semicircular Canals. *Otolaryngol Head Neck Surg*. 2011 Sep 1;145(3):458–62.
27. Webster G, Sens PM, Salmito MC, Cavalcante JDR, Santos PRB dos, Silva ALM da, et al. Hyperinsulinemia and hyperglycemia: risk factors for recurrence of benign paroxysmal positional vertigo ☆☆☆. *Braz j otorhinolaryngol*. 2015 Aug;81:347–51.
28. Gizzi MS, Peddareddygar LR, Grewal RP. A familial form of benign paroxysmal positional vertigo maps to chromosome 15. *International Journal of Neuroscience*. 2015 Aug 3;125(8):593–6.
29. Yang L, Xu Y, Zhang Y, Vijayakumar S, Jones SM, Lundberg Y (Yesha) W. Mechanism Underlying the Effects of Estrogen Deficiency on Otoconia. *J Assoc Res Otolaryngol*. 2018 Aug;19(4):353–62.
30. Benign paroxysmal positioning vertigo in multiple sclerosis: diagnosis, pathophysiology and therapeutic techniques.
31. Yetiser S. Review of the pathology underlying benign paroxysmal positional vertigo. *J Int Med Res*. 2020 Apr 1;48(4):0300060519892370.
32. Bhattacharyya N, Gubbels SP, Schwartz SR, Edlow JA, El-Kashlan H, Fife T, et al. Clinical Practice Guideline: Benign Paroxysmal Positional Vertigo (Update). *Otolaryngol Head Neck Surg*. 2017 Mar;156(3\_suppl):S1–47.
33. Furman JM, Cass SP. Benign Paroxysmal Positional Vertigo [Internet]. <http://dx.doi.org/10.1056/NEJM199911183412107>. Massachusetts Medical Society; 2008 [cited 2021 Aug 17]. Available from: <https://www.nejm.org/doi/10.1056/NEJM199911183412107>
34. Stefano AD. *Textbook of Vertigo: Diagnosis and Management*. JP Medical Ltd; 2013. 288 p.
35. Gacek RR. Technique and results of singular neurectomy for the management of benign paroxysmal positional vertigo. *Acta Otolaryngol*. 1995 Mar;115(2):154–7.
36. Parnes LS, McClure JA. Posterior semicircular canal occlusion for intractable benign paroxysmal positional vertigo. *Ann Otol Rhinol Laryngol*. 1990 May;99(5 Pt 1):330–4.
37. Clinical practice guideline: benign paroxysmal positional vertigo. [Internet]. [cited 2021 Aug 14]. Available from: <https://reference.medscape.com/medline/abstract/18973840>
38. Palmeri R, Kumar A. Benign Paroxysmal Positional Vertigo. In: *StatPearls* [Internet]. Treasure Island (FL): StatPearls Publishing; 2021 [cited 2021 Aug 8]. Available from: <http://www.ncbi.nlm.nih.gov/books/NBK470308/>
39. Jain, Shraddha, Shyam Jungade, Aditya Ranjan, Pragya Singh, Arjun Panicker, Chandraveer Singh, and Prajakta Bhalerao. "Revisiting 'Meniere's Disease' as 'Cervicogenic Endolymphatic Hydrops'"

and Other Vestibular and Cervicogenic Vertigo as 'Spectrum of Same Disease': A Novel Concept." INDIAN JOURNAL OF OTOLARYNGOLOGY AND HEAD & NECK SURGERY, n.d. <https://doi.org/10.1007/s12070-020-01974-y>.

40. Acharya, Sourya, Samarth Shukla, Amol Andhale, Akhilesh Annadatha, and Yash Gupte. "Neuroleptic Malignant Syndrome (NMS) after Treatment with Metoclopramide - A Rare Case Report." JOURNAL OF EVOLUTION OF MEDICAL AND DENTAL SCIENCES-JEMDS 9, no. 41 (October 12, 2020): 3065–66. <https://doi.org/10.14260/jemds/2020/671>.
41. Andhale, Amol, Sourya Acharya, and Samarth Shukla. "Primary Systemic Amyloidosis with Peripheral and Autonomic Neuropathy Presenting as Recurrent Presyncope: A Case Report." MEDICAL SCIENCE 24, no. 104 (August 2020): 1818–21.
42. Ankar, Ruchira Shrikant, and Seema Singh. "Chemotherapy Induced Peripheral Neuropathy - A Review." JOURNAL OF EVOLUTION OF MEDICAL AND DENTAL SCIENCES-JEMDS 9, no. 42 (October 19, 2020): 3147–51. <https://doi.org/10.14260/jemds/2020/689>.
43. Aradhey, Parag, Anand Bakre, Sunil Kumar, and Sourya Acharya. "Clinical Profile of Uremic Polyneuropathy in Chronic Kidney Disease Patients." MEDICAL SCIENCE 24, no. 102 (April 2020): 945–51.
44. Behere, Prakash B., Aniruddh P. Behere, and Debolina Chowdhury. "Rise in Cases of Alcohol Withdrawal Following Lockdown in Dry District of Wardha." JOURNAL OF NEUROSCIENCES IN RURAL PRACTICE 11, no. 03 (July 2020): 478–80. <https://doi.org/10.1055/s-0040-1712554>.
45. Behere, Prakash B., Amit B. Nagdive, Aniruddh P. Behere, Richa Yadav, and Rouchelle Fernandes. "Innovation in Community Psychiatry for the Delivery of Mental Health Services: The Sawangi Model." JOURNAL OF NEUROSCIENCES IN RURAL PRACTICE 11, no. 04 (October 2020): 593–96. <https://doi.org/10.1055/s-0040-1715543>.
46. Birelliwari, Aachal, Vrushali Athawale, Angela Kapoor, and Waqar M. Naqvi. "Early Gait Training Program and Proprioceptive Neuromuscular Facilitation in the Patient with Post Debridement Amputation - A Rare Case Report." MEDICAL SCIENCE 24, no. 105 (October 2020): 3421–26.
47. Chaturvedi, Anuj, Amrutha Garikapati, Charan Singh Bagga, Abhishek Chande, and Sunil Kumar. "Temporal Lobe Epilepsy: A Rare Post Chicken Pox Neurological Sequel." MEDICAL SCIENCE 24, no. 103 (June 2020): 1596–99.