

CASE REPORT

CYSTICERCOSIS OF CHEEK - A RARE SITE

ABSTRACT:

Cysticercosis caused by *Taenia solium* is a helminthic infection. It usually resides in animals and humans to complete their life cycle and causes the disease within it. Cysticercosis in humans is acquired by ingestion of *Taenia solium* eggs. It is caused due to improper sanitation, ingestion of faeces infected with larvae of cysticercus by pigs, improper vaccination of pigs and ingestion of raw or uncooked pork and meat by the humans. Most commonly it involves the brain, heart, liver, muscles, lungs and the peritoneal cavity. When there is involvement of the mouth, frequently occurring sites include the tongue, buccal mucosa and rarely floor of mouth. Likewise, most commonly, the skeletal muscle involvement is noted.

Cysticercosis can be diagnosed by radiological and pathological investigations. Radiologically, the lesion of the involved site can be seen on USG and MRI of the affected area. Pathologically, the biopsy done of the affected area shows the inhabited cysticercus along with its causative changes in the tissue like edema, congestion and infiltration of Inflammatory infiltrates. Being a parasitic infestation, eosinophilic infiltrating around the membrane of cysticercus is commonly noted in the biopsy. Here we present a case report, of occurrence of Cysticercosis in the muscles of cheek, a site with rare occurrence.

Comment [HC1]: Spelling error - cheek

KEYWORDS: Cysticercosis, cheek, *Taenia solium*.

INTRODUCTION:

Taenia solium (a helminth), causing the parasitic infection in the tissues, is usually named as Cysticercosis. Its larval stage, metacestode, is the main causative agent which may progressively grow upto 8 meters in length in its adult stage and further leading to its invasion into the tissues of human and pig.¹ It is posing a major public health issue in developing countries like India, Indonesia, China, Africa and Peru due to the scarcity in in proper sanitation hygiene. Cysticercosis majorly manifest via ingestion of Undercooked food, contaminated food and water or adulterated eatable substances containing eggs of tapeworm from the human faeces.² Involving most frequently, the brain, muscles, heart, liver, lungs and peritoneal cavity, intraoral involvement still an uncommon occurrence. In an involvement of mouth, it usually affects the tongue, labial or buccal mucosa and in rare situations, the floor of mouth. Muscles of the cheeks involvement is hardly mentioned anywhere in the literature. We have stressed the necessity of extensive knowledge on histological examination in the diagnosis of cysticercosis of cheek in this case report.³

CASE REPORT:

A 27 years old male presented with the complaint of swelling right cheek past 2 months which was associated with pain, since 17 days. Swelling was slow in commencement and progression,

with no increase or reduction in size, and it was accompanied by dull agonising pain that was eased with medication. There had been no previous tooth discomfort or fever. He ate a varied diet and had no history of unusual practices like cigarette or tobacco smoking.

Physical examination shows a solitary hard nodular, palpable enlargement measuring 2 cm in the right cheek, along with inflammation. The diagnosis differentiable includes parotid sialolithiasis, lymphadenitis, salivary abscess and tumors of mesenchyme. Ultrasonographically, the lesion was suggested as infective or granulomatous lesion.

Grossly, the tissue received was multiple. Whitish cystic tissue pieces from the right cheek, approximately measuring 1.5 x 1 x 1 cm.

Microscopically, it presented as a skeletal muscle along with fibrofatty tissue piece. Adherent to it was a cystic cavity which was lined by inflammatory cells like macrophages, lymphocytes and plasma cells were seen creating a chronic granulomatous reaction surrounding it. Within the cystic cavity, scolex with hooklets, and suckers of the larvae were seen. These larvae composed of duct like invaginations. Its body wall showed a myxoid matrix. All of these features suggested of granulomatous lesion due to parasitic infestation.

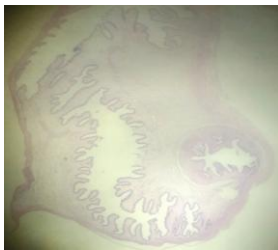


Fig 1: Shows a complete Cysticercus parasite seen on scanner, in histopathology.

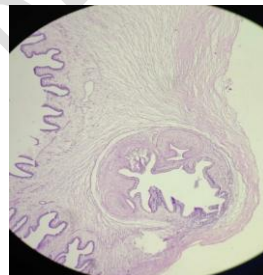


Fig 2: Shows foldings of the membrane, scolices of Cysticercus parasite seen on 10x in histopathology.

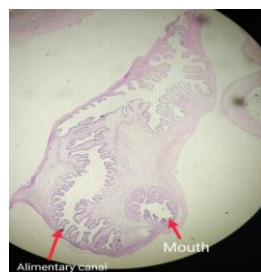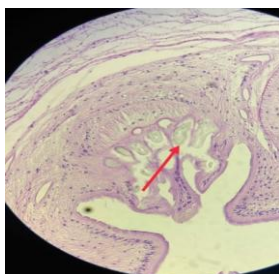


Fig 3: Shows hooklets of Cysticercus parasite seen on 40x in histopathology.

Fig 4: Shows mouth and alimentary canal of the Cysticercus parasite seen on scanner, in histopathology.

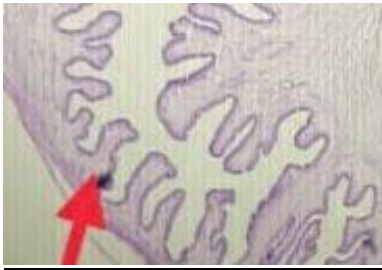


Fig 5 Shows the double layered, Duct like invaginations, eosinophilic membrane seen in high power view.

DISCUSSION:

Infection with the larval stage of the parasite *Taenia solium* causes cysticercosis. Cysticercosis is contracted by feco-oral contamination with *Taenia solium* eggs from tapeworm carriers. Cysticercosis can therefore be contracted by vegetarians and those who do not consume pork. Water, wind, insects, and other non-direct sources of infection have a minor role in illness transmission.¹⁻³ Many countries of the world, including China, Southeast Asia, India, Sub-Saharan Africa, and Latin America, are dealing with the disease as a major public health issue. Because of immigration from endemic areas, it has become a 'global problem', even in industrialised countries. The third decade was the most commonly afflicted (32%) followed by the fourth. Humans are the only ultimate host since sexual lifecycle of taenia takes place only in humans, but pigs, dogs, cats and sheep are its intermediaries as they bear its larvae. Foods not

Comment [HC2]: ??? affected

cooked completely causes the growth of larvae.⁴⁻⁶ Ingestion of such food leads to manifestation of such disease. Such outer wall of these ingested larvae gets destroyed by the enzymes of stomach and ejects out the head of the tapeworm. This newly formed head of the tapeworm enters and attaches itself onto the intestinal mucosa and develops into an adult worm in 5-12 weeks.⁵ Stool culture done shows the presence of eggs and its proglottids. Since the shells of the eggs are thick enough, it doesn't get disrupted for months and gets embedded within the soil. Now ingestion of these eggs by pigs or humans causes the breakage of such eggs by the enzymes of stomach.^{6,7} This leads to the release of oncospheres which penetrates into intestinal mucosa. It further spreads via mesenteric venules all over in the body, later on reaching the eye, muscles, buccal mucosa, brain and other body sites. Cysticercosis is more common in striated muscles of the neck, tongue, and trunk.

Cysticercus usually take place in voluntary muscles. In muscles, it causes an inflammatory reaction in the form of redness, edema and pain, clinically, manifesting in the form of either fever and myalgia. It can also manifest like a mass or like a pseudotumor or like an abscess. Sometimes, it also causes swelling in the involved muscle and later on leading to atrophy and scarring of the affected muscle. In majority of the cases, cysticercus remains asymptomatic and calcify within the involved site.^{3, 4, 5}

The diagnostic modalities for cysticercosis are both radiological and pathological and serological.

Radiological investigations are ultrasonographic scans and MRI. Pathological investigations for diagnosis are by both FNAC and Biopsy. Sonography shows various patterns like cysticercus cyst with with surrounding inflammation or any fluid collection in the pericystic areas along with calcification. Cysticercus on sonography presents as a well-defined, round to oval lesion with an eccentric scolex showing echogenicity.⁴⁻⁷ Other investigations can be serological tests. It includes enzyme linked immunoelectrotransfer blot (EITB) assay. EITB is a serum test, where antibodies specific of cysticercosis reacts with the glycoprotein antigens from the larval cysts of *Taenia solium*. Another test, ELISA can be done on CSF fluid. These serological tests uncommonly used for the diagnoses of cysticercosis due to other diagnostic

Comment [HC3]: Two times "with"

In this case report, Cysticercosis was diagnosed on biopsy showing cystic cavitation filled with larvae. The larvae had paired suckers along with its scolex and hooklets. Larva was histomorphologically seen as multiple, back to back connected, double layered, duct like invaginations. The stroma was myxoid, consisting of granulomatous inflammatory reaction showing lymphocytes and eosinophils.⁶⁻¹⁰

This disease can be prevented by improving sanitation practices, proper cooking and freezing of pork and meat before its consumption. This is done for ceasing the life cycle of cysticercus larvae if at all present within it. Other preventions include the properly managing the pigs by vaccinating them so as to stop the cysticercus to grow within it. The pigs should be separated from human faeces by inhabiting them in a closed piggeries.^{6,7,11}

CONCLUSION:

With a proper clinical history, a possibility of cysticercosis can be considered. Clinically, signs and symptoms along with a proper palpative examination of any swelling might help towards the direction of its diagnosis. It can further be supported by radiological investigations and

diagnostic cytopathologic and histopathologic modalities. A clear cut evidence can be gained by a microscopic visualization of cysticercus or its larval forms. Usually, seen at the common sites, it can uncommonly but can be seen in the muscles of cheek.

REFERENCES:

1. García HH, Gonzalez AE, Evans CA, Gilman RH, Cysticercosis Working Group in Peru. *Taenia solium* cysticercosis. *The lancet*. 2003 Aug 16;362(9383):547-56.
2. Zammarchi L, Strohmeyer M, Bartalesi F, Bruno E, Muñoz J, Buonfrate D, Nicoletti A, García HH, Pozio E, Bartoloni A, COHEMI Project Study Group. Epidemiology and management of cysticercosis and *Taenia solium* taeniasis in Europe, systematic review 1990–2011. *PloS one*. 2013 Jul 29;8(7):e69537
3. Kimura-Hayama ET, Higuera JA, Corona-Cedillo R, Chávez-Macías L, Perochena A, Quiroz-Rojas LY, Rodríguez-Carbajal J, Criales JL. Neurocysticercosis: radiologic-pathologic correlation. *Radiographics*. 2010 Oct;30(6):1705-19.
4. Ooi WW, Wijemanne S, Thomas CB, Quezado M, Brown CR, Nash TE. A calcified *Taenia solium* granuloma associated with recurrent perilesional edema causing refractory seizures: histopathological features. *The American journal of tropical medicine and hygiene*. 2011 Sep 1;85(3):460.
5. Singh S, Chhabra S, Aggarwal G, Kalra R, Duhan A, Sen R. Oral cysticercosis—a rare presentation. *Asian Pacific journal of tropical medicine*. 2011 Jul 1;4(7):587-8.
6. Coral-Almeida M, Gabriël S, Abatih EN, Praet N, Benitez W, Dorny P. *Taenia solium* human cysticercosis: a systematic review of sero-epidemiological data from endemic zones around the world. *PLoS neglected tropical diseases*. 2015 Jul 6;9(7):e0003919.
7. Laranjo-González M, Devleeschauwer B, Trevisan C, Allepuz A, Sotiraki S, Abraham A, Afonso MB, Blocher J, Cardoso L, Da Costa JM, Dorny P. Epidemiology of taeniosis/cysticercosis in Europe, a systematic review: Western Europe. *Parasites & vectors*. 2017 Dec;10(1):1-4.
8. Hathi, Deep, Ayush Somani, Anusha Gupta, and Sourya Acharya. “Neurocysticercosis Presenting as Complex Partial Seizures.” *JOURNAL OF EVOLUTION OF MEDICAL AND DENTAL SCIENCES-JEMDS* 9, no. 13 (March 30, 2020): 1116–18. <https://doi.org/10.14260/jemds/2020/241>.
9. Kshirsagar, Pooja Chandrakant, Neema Acharya, Sourya Acharya, and Amardeep Tembhare. “Seizures in Pregnancy- A Rare Case of Neurocysticercosis Mimicking Eclampsia.” *JOURNAL OF EVOLUTION OF MEDICAL AND DENTAL SCIENCES-JEMDS* 9, no. 12 (March 23, 2020): 1012–14. <https://doi.org/10.14260/jemds/2020/217>.
10. Gondivkar SM, Indurkar A, Degwekar S, Bhowate R. Evaluation of gustatory function in patients with diabetes mellitus type 2. *Oral Surgery, Oral Medicine, Oral Pathology, Oral Radiology, and Endodontology*. 2009 Dec 1;108(6):876-80.
11. Agrawal A, Timothy J, Cincu R, Agarwal T, Waghmare LB. Bradycardia in neurosurgery. *Clinical neurology and neurosurgery*. 2008 Apr 1;110(4):321-7.