

# Oral manifestations of COVID-19 in adult patients: Systematic Review.

## ABSTRACT

**Introduction:** It is currently considered that patients with COVID-19 may present certain common oral lesions of the oral cavity; However, in medically compromised patients such as diabetics, hypertensive individuals, those suffering from obesity or heart disease there is an increased risk of developing ulcers, recurrent blisters on the palatal mucosa, burning sensation, dry mouth (xerostomia) and reduced saliva production, due to alteration of the mucosal barrier in the respiratory tract, thus presenting a broad differential diagnosis in the evolution of the disease. **Objective:** The objective was to identify the oral manifestations of COVID-19 in adult patients. **Data:** A database registry of n = 1956 was established, of which 100 studies were selected for this review, distributed **as follow**: 36% from Europe, 26% from Asia, 26% from South America and 12% from North America. **Sources:** An extensive electronic research was carried out in the databases: PubMed, Scopus, Epistemonikos, Web of Science, Springer, Lilacs, Latindex, Redalyc, Bireme, Scielo.org and the reports of the World Health Organization and the Pan-American Health Organization. **Study selection:** The research strategy was based on Medical Subject Heading terms, along with Health Sciences Descriptors. Certain descriptors were amplified for the Elsevier COVID-19 oral disease database and resources. **Conclusion:** Dysgeusia would be one of the initial oral manifestations of the COVID-19. Health workers would have a new resource for the early diagnosis of asymptomatic patients or those in initial stages of COVID-19, through the effective collaboration between the team from the Critical Care Unit and the Dentistry Service.

*Keywords: Oral manifestations; SARS-COV-2; COVID-19; Stomatognathic Diseases; Coronavirus disease 2019.*

## 1. INTRODUCTION

At the end of 2019, a disease of little-known etiology and with symptoms similar to pneumonia in its severe form was observed in the town of Wuhan-China. In March 2020 the disease was already declared as a Global Public Health Emergency by the World Health Organization (WHO,) and was called COVID-19 (for its acronym in English).<sup>1,2,3</sup>

The SARS-CoV-2 was identified as the agent responsible for the disease. It is a virus made up of a single RNA chain that binds to the receptor of the target cell through protein S, which facilitates its entry and, since this receptor is located in the epithelial cells of the tongue, respiratory tract, oral mucosa and salivary glands, transmission occurs by vertical contact of respiratory droplets (aerosols) that are expelled when breathing, speaking, laughing, coughing or sneezing at distances less than 1.5 meters, and when interacting with inanimate objects that are contaminated by such aerosols. The main clinical manifestations of the

disease are: fever, dry cough, respiratory distress, generalized myalgias and dyspnea. However, drowsiness, diarrhea, confusion and hemoptysis may also occur. High affinity of the virus for angiotensin-converting enzyme 2 (ACE2) has been observed, being it responsible for the disease due to the imbalance of the oral microbiota and the destruction of the neurons of the olfactory nucleus, giving way to the colonization of opportunistic infections that present as main symptoms the loss of smell and taste alteration (ageusia, hypogeusia, dysgeusia). It is estimated that these conditions occur before respiratory symptoms due to the high expression of ACE2 on the back of the tongue; and thus, people with higher expression of ACE2 are more susceptible to COVID-19.<sup>3,4,5,6,7,8,9</sup>

Literature states that certain patients with COVID-19 present oral lesions such as ulcers, blisters that are recurrent on the palatal mucosa, a burning sensation, dry mouth (xerostomia), and reduced saliva production. Clinical studies reported that patients with reduced saliva production have a higher risk of developing the infection, and in patients suffering from xerostomia the barrier function of the mucosa in the respiratory tract is altered, facilitating the bacterial colonization. In the same way, periodontitis, whether moderate or severe, that is not treated in time, could progress to more severe cases of COVID-19.<sup>10,11,12</sup> It is of clinical importance to incorporate the evaluation of the oral signs and symptoms of patients diagnosed with the infection, and so to try to assess if the oral diseases are part of the infection or if they correspond to other pathological entities that directly affect the patient with COVID-19. For this reason, the objective of this Systematic Review was to analyze the oral manifestations of COVID-19 in adult patients, since to date no evidence has been recorded to clarify whether these oral manifestations are a consequence of COVID-19 infection or if they are the result of certain medical compromises that afflict the patients at that time or if they are due to adverse reactions to the treatments administered to treat the infection.<sup>13,14</sup>

## 2. METHOD

### 2.1 DESIGN

Given the exploratory approach and the breadth of the lack of evidence to clarify whether these oral manifestations are a consequence of COVID-19 infection, a Systematic Review has been carried out that has a protocol published in OSF (Open Science Framework).<sup>15</sup>

### 2.2 SEARCH STRATEGY

The Systematic Review was carried out by means of an extensive electronic search in the databases: PubMed, Scopus, Epistemonikos, Web of Science, Springer, Lilacs, Latindex, Redalyc, Bireme, Scielo.org and the reports of the World Organization of the Health and the Pan-American Health Organization (WHO / PAHO), not establishing language or research type limits; but establishing as a time limit for the search of the information from the year 2020 to March of 2021.

From the research question, the search strategy was based on Medical Subject Heading (MeSH) terms and in the Health Sciences Descriptors (DeCs) terms. Controlled and indexed descriptors were used for each one of the databases of this Systematic Review, joining them with Boolean operators. Certain descriptors were amplified for the Elsevier COVID-19 oral manifestations database and resources, carrying out a references review based on the first literature of interest. **Table 1** shows the search strategy in which the links of the websites can be found.

For this research, the literature of observational and epidemiological studies, clinical trials, reviews, letters to the editor, and WHO / PAHO documents and reports on oral manifestations in adults who have been infected by COVID-19 were included. On the other hand, the literature on COVID-19 related to oral cancer, cardiorespiratory arrest, biosafety protocols for COVID-19, clinical manifestations of different organs, and oral diseases due to COVID-19 in children were excluded; duplicated articles and those whose full text was not obtained or the authors could not be contacted were also excluded.

The studies selection was carried out with a direct approach to the research question and according to the inclusion and exclusion criteria. First the titles, then the abstracts, and finally the full articles were analyzed to determine relevance and conclusions in order to have a better eligibility criterion. The selected articles and reports were classified as included, excluded and uncertain. The included and uncertain studies underwent additional screening in the Rayyan online software, so the discrepancies in the selection of titles, abstracts and full texts were resolved. The Systematic Review was performed according to the PRISMA-ScR criteria or guidelines.<sup>15</sup>

UNDER PEER REVIEW

### 3. RESULTS AND DISCUSSION

For this research, a database registry was established: being 861 articles from PubMed, Scopus 93, Epistemonikos 23, Web of Science 208, Springer 486, Lilacs 216, Latindex 50, Redalyc 5, Bireme 4, Scielo.org 6, (WHO/PAHO) 4, establishing a total of  $n = 1956$  studies. A first screening was carried out, leaving 500 articles; after this screening, the duplicate bibliography was eliminated, leaving 448 references for the extraction of the title, abstract and full text. After evaluating all registries, 346 studies that did not meet the eligibility criteria were excluded, resulting in 100 studies suitable for this review.

The flow diagram according to the **PRISMA-ScR** model reflects the process of search and selection of articles based on the inclusion, exclusion and duplicate criteria. The studies that were incorporated for this research were distributed worldwide so that 36% was carried out in Europe, 26% in Asia, 26% in South America, and 12% in North America. In addition, 32 studies were letters to the editor, 18 reviews, 10 review articles, 4 systematic reviews, 5 case reports, 4 original articles, 3 critical reviews, 3 short communications, 2 correspondences and only 1 was from an editorial, discoveries, current article, original research, case report history, human observational study, discussion report, rapid communication, research report, understanding the disease, case series, research article, current view, bibliographic review, short paper, rhinology, World Organization of the Health, scoping review and research letters. The selected and evaluated studies were published in English and Spanish between January 2020 and March 2021 (**Figure 1, Figure 2, Table 2**).

Based on the review carried out, it is possible to mention that regardless of sex, there was a similarity between oral manifestations and skin lesions in terms of their prevalence being close and describing 1.8% to 20.4% in patients with COVID-19, consequently, erythema multiforme was present as a cutaneous and oral manifestation,<sup>18,23,89,90</sup> therefore the identification of COVID-19 could help physicians during the clinical diagnosis in the initial stage of the disease.<sup>72</sup>

Corchuelo J et al., mention that the presence of petechiae in the skin and oral mucosa could be related to thrombocytopenia due to infection by SARS-CoV-2,<sup>43</sup> but it has not been evidenced since there are patients **whom** take ibuprofen, causing the inhibition of platelet function<sup>37,44</sup> and with this, certain clinical manifestations together with histological findings include the possibility that the oral cavity may present alterations from primary or secondary to vascular or hematological damage caused by COVID-19.<sup>43</sup>

In this way, in cases of COVID-19 it has been observed that lymphocytopenia causes the over-activation of T cells, manifesting an increase in Th17 (or T helper 17 lymphocytes, which are the T lymphocytes (in charge of the elimination of pathogens, fungi and microbacteria) and increasing the cytotoxicity of TCD8 cells (cytotoxic, activated by cells that are infected by viruses), these characteristics decrease the immune response and expose perfectly healthy individuals and predispose them to complications that have been associated **to** the lower respiratory tract.<sup>52</sup>

Saliva is a unique body fluid secreted by the salivary glands<sup>98</sup> that has various functions such as: lubrication, initiation of swallowing, immunity, among others.<sup>48</sup> Several studies state the hypothesis that the SARS-CoV-2 genome could be found in saliva, without showing sufficient evidence of its presence in the nasopharynx<sup>16,20,50,63,76,80,86,98</sup> because the virus strains have been detected in saliva up to 29 days after being infected.<sup>19</sup> Consequently, it would lead to a risk of transmission of the infection, causing the partial deterioration of the oral tissues, requiring a new vision regarding the clinical prevention, diagnosis and treatment of the coronavirus disease.<sup>24</sup>

The expression of ACE2 in human tissues and its connection with the spread of the virus through its different ways of infection, this being direct and indirect of certain salivary fluids or secretions of the respiratory tracts or the mucous membranes (oral, nasal or ocular)<sup>6,33,77,78</sup> entering only cells that express ACE2.<sup>75</sup>

ACE2 has been perceived as the main receptor of the host cells of SARS-CoV-2<sup>7,26,40,57,63</sup> allowing entry and causing the final infection, for which it is mentioned that the cells that express ACE2 could act as **a target cells** being susceptible to infection by COVID-19,<sup>7,12,65,75</sup> the expression of ACE2 has been found in a greater proportion in the tongue than in the oral and gingival tissues,<sup>7,8,66,77</sup> as a result the oral cavity is considered as a potential and high risk route of infection by the disease.<sup>7,30,37,63</sup> Other studies also mention that this is a neurotropic and mucotropic virus that affects the function of the salivary glands, the sense of taste, smell and the integrity of the oral mucosa; in consequence it would alter the oral microbiota,<sup>65</sup> its entry, reproduction, dissemination and pathogenicity when presenting in patients with a depressed immune system. Subsequently it initiates an inflammatory reaction in organs and tissues related to the mucosa of the tongue and salivary glands, since people with a higher expression of ACE2 would be prone to the COVID-19,<sup>42,48,56,58,62,64,68,71,84</sup> it is presumed that oral symptoms could be considered as initial symptoms of the infection.<sup>24</sup>

Certain parameters have been predisposed to determine an inaugural symptom within the oral cavity when having COVID-19 such as: appearance, etiology, prognosis and prevalence<sup>3</sup> since the oral mucosa is the first line of barrier against toxins, microorganisms and trauma.<sup>85</sup>

Patients affected by COVID-19 present systemic complications, standing out: hypertension, diabetes mellitus, obesity and cardiovascular diseases, therefore the patient has a greater predisposition to suffer oral lesions.<sup>30,31,32,33,44,48,54,56,59,61,68,70,78,80,81,85,88,92</sup> Some drugs, such as antihypertensive drugs, act as ACE2 inhibitors, causing its increase, so SARS-CoV-2, by binding to the host cell membrane through ACE2, causes a greater risk of infection<sup>51,80</sup> The average age ranges from 19 to 88 years (excluding children), presenting as secondary manifestations related to the immunological condition of the patient.<sup>40</sup> Oral cavity lesions may be due to opportunistic infections or adverse reactions to the treatment of COVID-19.<sup>42,47</sup>

**The interaction between SARS-CoV-2 and ACE2 alter** the function of oral keratinocytes and together with the epithelial lining of the ducts of the salivary glands cause painful oral ulcers,<sup>33,36</sup> which have been observed more frequently in COVID-19 patients;<sup>88</sup> however, there are numerous viruses that compromise the immune system and also increase susceptibility to a wide range of opportunistic viral and fungal infections in the oral cavity,<sup>16,18,46,48,52,55,85,91,99</sup> appearing in a period of two to seven days after getting the infection,<sup>53</sup> showing an herpetiform appearance, with irregular margins, with a non-hemorrhagic red background, with a higher prevalence in the hard palate and oral mucosa, some being painless and others painful of medium intensity.<sup>18,23,27,30,31,33,34,37,53,55</sup> Regarding its size, it ranges between **1 to 5** mm, being similar to herpes,<sup>53</sup> and for its treatment topical medications are used, such as: lidocaine, dexamethasone and tetracycline, with the aim of the elimination or remission of symptoms in a period from 3 to 21 days, altogether with a correct oral hygiene. This is a key issue in critically ill patients and it has been demonstrated that the use of "commercial products used for oral hygiene" would be less recommended precisely because they alter the physical-chemical composition and microbiota of saliva.<sup>30,31,32,40,53,100,101</sup> Since the exact cause of ulcers / blisters is unknown and some authors consider that they are the direct result of COVID-19 infection, others consider them as secondary aphthous ulcers related to mental stress and / or infections caused by opportunistic pathogens due to the change in immunity related to the virus.<sup>92</sup>

The presence of multiple reddish macules of different sizes that are scattered throughout the hard palate, tongue and lips **have** also been observed, being completely evident at the third week of a complete remission.<sup>27,55</sup>

It has been described that patients with COVID-19 present various alterations, firstly dysgeusia, later hypogeusia, and to a lesser extent ageusia, together with olfactory alterations, hyposmia or anosmia; the only manifestations of COVID-19 infection often presented without concomitant nasopharyngeal symptoms in 95% of the cases<sup>14,26,29,36,37,39,40,41,43,44,48,49,51,54,57,59,60,61,66,67,68,70,71,73,74,78,80,82,83,84,91,92,94,96,99</sup> and without differences between both genders being observed. In addition, appearing in an early period of the infection, between the second and sixth day after the onset of the first symptom related to COVID-19, they even appear before patients are hospitalized, rapidly worsening.<sup>17,18,29,33,60,71,78</sup> These epithelial and neural disorders could be associated with the direct action of the virus, since patients by referring only dysgeusia or ageusia and the absence of any olfactory disorder could be considered as initial symptoms of the oral manifestations of the COVID-19<sup>26,40,67</sup> it is therefore of vital importance to evaluate the presence of xerostomia (hyposalivation) or other chemosensory alterations due to the potential invasive and neutrophic properties of the SARS-CoV- 2,<sup>26,37,44,45,49,52,61,67,82,83</sup> which could result in a serious respiratory infection since the decrease in salivary secretion alters the surface of the oral mucosa and the respiratory tract as a physical barrier, improving the viral colonization pathway and causing the reduction of many antiviral proteins, by reducing their half-life.<sup>40,41,45,48,60,71</sup>

The oral and periodontal microbiome, together with inadequate and insufficient oral hygiene, are a risk factor for developing complications from COVID-19, given that the periodontal pocket is considered a possible reservoir for SARS-CoV-2 and other viruses which can migrate systemically through the periodontal capillary epithelium by replicating and mixing with saliva.<sup>35,38,49,69,84</sup>

Gum's inflammation could be a starting point for a systemic inflammatory reaction, being IL6 responsible for altering gas exchange at the capillary alveolus unit level, contributing to respiratory insufficiency and fibrosis; however, low IL6 levels could protect patients with COVID-19.<sup>87</sup>

Periodontitis is a non-infectious chronic inflammatory disease and more prevalent than appearing at the same time with dental **caries**. These two oral diseases present an imbalance of pathogenic bacteria in the oral cavity. COVID-19 and bacterial load could trigger complications such as pneumonia and lead to sepsis; for this reason, the degree of oral health and periodontitis cause comorbidities with a high risk of complications of the COVID-19 causing an imbalance in the oral microbiota and increasing the risk of periodontal disease, being involved in systemic inflammation, bacteremia, pneumonia and even the death of patients.<sup>21,28,38,49,87,97</sup> Published studies refer to the fact that the reduction or eradication of periodontal disease reduces the risk of contracting pneumonia.

Different types of therapies have been described that include the use of mouthwashes, but the vast majority of authors recommend 12% chlorhexidine mouthwash (twice a day for 10 days) or tetracycline, thus preventing secondary infections and waiting for the decrease of oral lesions in (7-15 days),<sup>18,28,36,37,42,43,44,53,66,79</sup> The topical application of corticosteroids for mouth ulcers has also been mentioned, with a remission of the same in 10 days. Similarly, temporary oral pigmented lesions have been reported due to the use of hydroxychloroquine in COVID-19 patients; however, its use is NOT recommended at any stage of the COVID-19.<sup>36,66</sup>

More studies alongside with clinical and histological investigations are needed to be able to interpret that **the main responsible of the oral manifestations** is in fact SARS-CoV217 or other viral infections, including an imbalance in the microbiota caused by drugs or conditions of immune deterioration may be due to changes in the state of psychological stress and lack of sleep of the patient, or to inadequate oral hygiene<sup>23,24,32,36,50,94,95</sup> that could aggravate their state, causing an over-activation of the immune response, leading to immune depletion; however, although the emotional part is just as important as the physical, it is considered very difficult to show that stress and sleep disturbances alter the immune system. It is probably true but very difficult to demonstrate the quantification of stress in the physical responses of individuals.<sup>22,25,29,32</sup>

Until now, it **hasn't** been possible to fully demonstrate whether the oral manifestations presented by patients are due to the COVID-19, so the need to carry out this Systematic Review arises and to systematically map the investigations carried out in this area. In such a way, the possible existence of oral manifestations caused by this infection is evident, which in this present time has caused devastating effects in the world.

The virus strains have been detected in saliva up to 29 days after being infected,<sup>19</sup> therefore the risk of transmitting the infection is high. Chen L **et al agrees** with Pedrosa M et al, when mentioning that saliva could be a viable means of diagnosis for critically ill patients since it could be collected without any invasive procedure.<sup>24,48</sup> Brand T et al. indicate that the oral manifestations appeared concomitant with the loss of taste and smell perceptions.<sup>33</sup> Therefore, Chen C **et al** mention that the COVID-19 could be a special neuropathy that can cause permanent damage to human health.<sup>68</sup>

Biadsee A et al, indicate that there is a certain relationship between nasal congestion and olfactory dysfunction, but they did not find a relationship with anosmia.<sup>29</sup> Different from Lechien J et al, mention that the patient being infected with the coronavirus would be associated with anosmia.<sup>60</sup> Both olfactory and taste disorders are the only manifestations of the COVID-19 infection present, often without symptoms in 95%, appearing in the early period of infection. Amorim Santos J et al, mention that the mean duration of taste disorders is 15 days, for a subsequent complete recovery of olfactory functions,<sup>40</sup> while Vaira L et al, together with Meini S et al, agree that it is not possible to determine whether there will be a complete recovery of olfactory and taste functions or how long the recovery will take.<sup>57,74</sup>

The immune dysregulation caused by the COVID-19 leads to a deterioration in systemic health, inciting a prolonged immune imbalance and causing late secondary oral lesions.<sup>32</sup> Wiley John et al. state that stress could play a significant role in the appearance of oral lesions, but a cause-effect relationship between COVID-19 infection and the appearance of oral lesions could not be established; however, the frequency of appearance of oral lesions also **develop** in immunocompromised patients, for example HIV (human immunodeficiency virus).<sup>36</sup>

Al-Khatib A et al. indicate that oral ulcers or blisters are not manifestations of the COVID-19, in addition, oral ulcers and vesicular bullous lesions are not manifestations of COVID-19 or SARS-CoV-2<sup>39</sup> infections, so Abanoub R et al. point out that oral ulcers can be a direct manifestation of SAR-CoV-2 infection or a co-infection due to immune dysregulation.<sup>53</sup> Concluding Ciccarese G et al, that oral lesions are due to coronavirus disease COVID -19 and that represent a sign of life-threatening risk.<sup>31</sup>

Ather A et al agree with Bastani P et al when mentioning that the viral load of COVID-19 in human saliva is high, so the use of mouthwash would only reduce the microbial load in the mouth and does not have the power to eliminate it completely.<sup>20,88</sup> Therefore, Suárez S et al.

State that the National Health Commission of the Chinese Government indicated that 0.12% chlorhexidine that is commonly used as mouthwash in practice is not effective for SARS-CoV-2, being that the COVID-19 is susceptible to oxidation, suggesting a mouth rinse with 1% hydrogen peroxide or 2% povidone iodine;<sup>79</sup> Similarly, Cuthbertson **et al** agree with Arabi YM et al. by stating that it should not be associated "Good oral care" with regular use of oral chlorhexidine in the Critical Care Unit since the friction of this antiseptic solution on the surfaces of the oral cavity could produce cytotoxic consequences that include mucosal lesions, acute respiratory distress syndrome and increased blood pressure. For that reason, it is recommended that adequate oral care includes oral hydration, lip moisturization and correct tooth brushing to mechanically remove the biofilm and supragingival and infra-gingival bacterial plaque.<sup>100,101</sup>

#### 4. CONCLUSION

The review carried out expresses that SARS-CoV-2 could be found in saliva, since it is a body fluid that fulfills multiple biological functions and would act as a route for the transmission of the infection, which would lead to the deterioration of oral tissues. Oral manifestations are more common in medically compromised patients, such as diabetic, hypertensive **patientes**, obese or heart disease patients, being these conditions related to the intake of certain drugs, such as antihypertensives that act as ACE2 inhibitors, causing its increase, and along with it an increased risk of infection. Based on the symptoms expressed by COVID-19, dysgeusia is one of the findings that could be considered as the first recognized oral manifestation of the disease; furthermore, the presence of xerostomia or other chemosensory alterations could trigger a severe respiratory infection. Oral ulcers on the hard palate and oral mucosa have also been observed more frequently, manifesting within a period of two to seven days after getting the infection, presenting a herpetiform appearance with irregular margins, a non-hemorrhagic red background, some being painless and others of medium intensity. Given the remarkable scientific evidence published around the world about oral manifestations found in patients with the COVID-19, the authors conclude that health personnel at all levels of care should perform an examination before any clinical procedure thorough examination of the oral cavity for the rapid diagnosis of asymptomatic patients or in early stages of the disease; on the other hand, in patients diagnosed with the COVID-19, the examination of the oral cavity should be performed every 6 hours, thoroughly describing the oral manifestations present, in order to establish a sequence of lesions in the evolution of the disease.

The health and hygiene of the oral cavity is considered key in the critical patient with an endotracheal tube, since it greatly reduces the development of ventilator-associated pneumonia (VAP); therefore, the authors recommend hydration and moistening of the soft tissues of the oral cavity at least once every six hours with "saline solution". In addition, it's proposed to control oral hygiene by means of mechanical removal (tooth brushing) of the biofilm and supra and subgingival bacterial plaque using electric brushes (rotating) and toothpaste containing 1450 parts per million (ppm) of fluoride with short movements in the anterior-posterior direction for about 2 minutes. Another valid alternative (except for the use of chlorhexidine) would be the dragging of gauze soaked in saline serum, passing through the mucous membranes and soft tissues of the oral cavity, in addition to aspirating the contaminated pharyngeal lake.

**"Finally, there should be an effective collaboration between the professionals who make up the team of the Critical Care Unit (doctors, nurses, assistants and support staff) and the Dentistry Service, because the correct care of oral hygiene requires a higher understanding of the pathophysiology of the stomatognathic system, oral microbiology and biological behavior of the biofilm".**

## CONSENT (WHERE EVER APPLICABLE)

Not applicable

## ETHICAL APPROVAL

The **AUTHORS** have obtained all the necessary ethical approval from the Institutional Committee of the Catholic University of Cuenca, which stipulates that: In a session of the Bioethics Committee on November 3, 2020, the aforementioned protocol was analyzed, determining the following:

This work maintains conceptual and methodological coherence in each of the sections. It is well written and meets the elements as research projects. The Bioethics Committee conceptualizes that the risk of the review is "NO RISK" and grants the ENDORSEMENT to the topic: "*Oral manifestations of COVID-19 in adult patients. Systematic review*"

## COMPETING INTERESTS DISCLAIMER:

Authors have declared that no competing interests exist. The products used for this research are commonly and predominantly use products in our area of research and country. There is absolutely no conflict of interest between the authors and producers of the products because we do not intend to use these products as an avenue for any litigation but for the advancement of knowledge. Also, the research was not funded by the producing company rather it was funded by personal efforts of the authors.

## REFERENCES

1. World Health Organization. Advice for the public about rumors about the new coronavirus (2019-nCoV). Available at: <https://www.who.int/es/emergencies/diseases/novel-coronavirus-2019/advice-for-public/myth-busters>
2. Cascella M, Rajnik M, Cuomo A, Dulebohn S, Di Napoli R. Features, Evaluation, and Treatment of Coronavirus Stat Pearls Publishing-2020. Available at: [https://www.ncbi.nlm.nih.gov/books/NBK554776/#\\_ncbi\\_dlg\\_citbx\\_NBK554776](https://www.ncbi.nlm.nih.gov/books/NBK554776/#_ncbi_dlg_citbx_NBK554776)
3. Meng L, Hua F, Bian Z. Coronavirus disease 2019 (COVID-19): Emerging and future challenges for dental and oral medicine. J Dent Res. 2020;99(5):481–7. Available at: <https://doi.org/10.1177/0022034520914246>
4. Trilla A. One world, one health: the epidemic due to the new coronavirus COVID-19. Med Clin (Barc). 2020;154(5):175. Available at: DOI:10.1016/j.medcli.2020.02.002
5. Aguilar Salas VM, Febres EVB. Attitude to COVID-19 in routine dental practice. Rev Medical Sciences Pinar del Río. 2020;24(3). Available at: [http://scielo.sld.cu/scielo.php?script=sci\\_arttext&pid=S1561-31942020000300019](http://scielo.sld.cu/scielo.php?script=sci_arttext&pid=S1561-31942020000300019)

6. Peng X, Xu X, Li Y, Cheng L, Zhou X, Ren B. Transmission routes of 2019-nCoV and controls in dental practice. *Int J Oral Sci.* 2020;12(1):1–6. Available at: <https://doi.org/10.1038/s41368-020-0075-9>

7. Xu H, Zhong L, Deng J, Peng J, Dan H, Zeng X, et al. High expression of ACE2 receptor of 2019-nCoV on the epithelial cells of oral mucosa. *Int J Oral Sci.* 2020;12(1):1–5. Available at: <https://doi.org/10.1038/s41368-020-0074-x>

8. Nemeth-Kohanszky ME, Matus-Abásolo CP, Carrasco-Soto RR. Oral Manifestations of COVID-19 Infection. *Int J Odontostomatol.* 2020;14(4):555–60. Available at: [http://www.ijodontostomatology.com/wp-content/uploads/2020/08/2020\\_v14n4\\_018.pdf](http://www.ijodontostomatology.com/wp-content/uploads/2020/08/2020_v14n4_018.pdf)

9. Aguilera-Galaviz L, Gaitán-Fonseca C, Bermúdez-Jiménez C. Patient management in dental care and staff biosecurity during the SARS-CoV-2 (COVID-19) coronavirus outbreak. *Rev la Asoc Dent Mex.* 2020; 77 (2): 88–95. Available at: <https://dx.doi.org/10.35366/93101>

10. Ramírez-Velásquez M, Medina-Sotomayor P, Macas ÁAM. Coronavirus disease 2019 (COVID-19) and its impact on dental practice: a review. *Odontol Sanmarquina.* 23 (2): 139–46. Available at: <https://revistasinvestigacion.unmsm.edu.pe/index.php/odont/article/view/17758>

11. Gomez JLM. COVID-19 and its importance in dental care: literature review and update. *Odontol sanmarquina.* 2020; 23 (3): 261–70. Available at: <https://revistasinvestigacion.unmsm.edu.pe/index.php/odont/article/view/18130>

DOI:<https://doi.org/10.15381/os.v23i3.18130>

12. Cornejo-Ovalle M, Espinoza-Santander I. COVID-19 and oral statements. *Int J Odontostomatol.* 2020; 14 (4): 538–9. Available at: [http://www.ijodontostomatology.com/wp-content/uploads/2020/06/2020\\_v14n4\\_014.pdf](http://www.ijodontostomatology.com/wp-content/uploads/2020/06/2020_v14n4_014.pdf)

13. Sigua-Rodríguez EA, Bernal-Pérez JL, Lanata-Flores AG, Sánchez-Romero C, Rodríguez-Chessa J, Haidar ZS, et al. COVID-19 and Dentistry: a Review of the Recommendations and Perspectives for Latin America. *Int J Odontostomatol.* 2020; 14 (3): 299–309. Available at: [https://scielo.conicyt.cl/scielo.php?script=sci\\_arttext&pid=S0718-381X2020000300299](https://scielo.conicyt.cl/scielo.php?script=sci_arttext&pid=S0718-381X2020000300299)

14. Chaux-Bodard AG, Deneuve S, Desoutter A. Oral manifestation of Covid-19 as an inaugural symptom? *J Oral Med Oral Surg.* 2020; 26 (2): 18. Available at: <https://doi.org/10.1051/mbcb/2020011>

15. Andrea C. Tricco,, Erin Lillie, , Wasifa Zarin, , Kelly K. O'Brien, , Heather Colquhoun, , Danielle Levac, et al PRISMA Extension for Scoping Reviews (PRISMA-ScR): Checklist and Explanation. *Intern Med.* 2018 Oct 2;169(7):467-473. doi: 10.7326/M18-0850.

16. Abu- Hammad S, Dar- Odeh N, Abu- Hammad O. SARS- CoV- 2 and oral ulcers: A causative agent or a predisposing factor? *Oral Dis.* 2020 Available at: <https://doi.org/10.1111/odi.13498>

17. Abanoub R, Marwa G. Comment on: Oral Manifestation of COVID-19 as an inaugural symptom? *J Oral Med Oral Surg.* 2020;26(2):19. Available at: <https://doi.org/10.1051/mbcb/2020020>

18. Sousa FACG, Paradella TC. Considerations on oral manifestations of COVID- 19. *J Med Virol.* 2021;93(2):667–8. Available at: <https://doi.org/10.1002/jmv.26451>
19. Sabino-Silva R, Jardim ACG, Siqueira WL. Coronavirus COVID-19 impacts to dentistry and potential salivary diagnosis. *Clin Oral Investig.* 2020;24(4):1619–21. Available at: <https://link.springer.com/article/10.1007/s00784-020-03248-x>
20. Ather A, Patel B, Ruparel NB, Diogenes A, Hargreaves KM. Coronavirus disease 19 (COVID-19): implications for clinical dental care. *J Endod.* 2020;46(5):584–95. Available at: <https://doi.org/10.1016/j.joen.2020.03.008>
21. Sampson V, Kamona N, Sampson A. Could there be a link between oral hygiene and the severity of SARS-CoV-2 infections? *Br Dent J.* 2020;228(12):971–5. Available at: <https://doi.org/10.1038/s41415-020-1747-8>
22. Riad A, Klugar M, Krsek M. COVID- 19- Related Oral Manifestations: Early Disease Features? *Oral Dis.* 2020. Available at: <https://doi.org/10.1111/odi.13516>
23. Rocha AL, de Souza AF, Resende RG. Current evidence on possible oral manifestations of SARS - CoV - 2 infection. *Oral Dis.* 2020; Available at: <https://doi.org/10.1111/odi.13517>
24. Chen L, Zhao J, Peng J, Li X, Deng X, Geng Z, et al. Detection of 2019-nCoV in saliva and characterization of oral symptoms in COVID-19 patients. 2020; Available at: <https://dx.doi.org/10.2139/ssrn.3556665>
25. Guo Y, Yuan C, Wei C. Emergency measures for acute oral mucosa diseases during the outbreak of COVID-19. *Oral Dis.* 2020. Available at: <https://doi.org/10.1111/odi.13350>
26. Vinayachandran D, Balasubramanian S. Is gustatory impairment the first report of an oral manifestation in COVID-19? *Oral Dis.* 2020; Available in: <https://doi.org/10.1111/odi.13371>
27. Soares CD, de Carvalho RA, de Carvalho KA, de Carvalho MGF, de Almeida OP. Letter to Editor: Oral lesions in a patient with Covid-19. *Med Oral Patol Oral Cir Bucal.* 2020;25(4): e563. Available at doi: 10.4317/medoral.24044
28. Patel J, Woolley J. Necrotizing periodontal disease: Oral manifestation of COVID- 19. *Oral Dis.* 2020; Available at: <https://doi.org/10.1111/odi.13462>
29. Biadsee A, Biadsee A, Kassem F, Dagan O, Masarwa S, Ormianer Z. <? covid19?> Olfactory and Oral Manifestations of COVID-19: Sex-Related Symptoms—A Potential Pathway to Early Diagnosis. *Otolaryngol Neck Surg.* 2020;163(4):722–8. Available at: <https://doi.org/10.1177/0194599820934380>
30. Ansari R, Gheitani M, Heidari F, Heidari F. Oral cavity lesions as a manifestation of the novel virus (COVID- 19). *Oral Dis.* 2020; Available at: <https://doi.org/10.1111/odi.13465>
31. Ciccarese G, Drago F, Boatti M, Porro A, Muzic SI, Parodi A. Oral erosions and petechiae during SARS - CoV - 2 infection. *J Med Virol.* 2021; 93 (1): 129–32. Available in: <https://doi.org/10.1002/jmv.26221>
32. Bezerra TM, Feitosa SG, Carneiro DTO, Costa FWG, Pires FR, Pereira KMA. Oral lesions in COVID-19 infection: Is long-term follow-up important in the affected patients? *Oral Dis.* 2020; Available at: <https://doi.org/10.1111/odi.13705>

33. Brandão TB, Gueiros LA, Melo TS, Prado-Ribeiro AC, Nesrallah ACFA, Prado GVB, et al. Oral lesions in patients with SARS-CoV-2 infection: could the oral cavity be a target organ? *Oral Surg Oral Med Oral Pathol Oral Radiol.* 2021; 131 (2): e45–51. Available at: <https://doi.org/10.1016/j.oooo.2020.07.014>
34. Chaux-Bodard AG, Deneuve S, Desoutter A. Oral manifestation of Covid-19 as an inaugural symptom? *J Oral Med Oral Surg.* 2020; 26 (2): 18. Available at: <https://doi.org/10.1051/mbcb/2020011>
35. Di Spirito F, Pelella S, Argentino S, Sisalli L, Sbordone L. Oral manifestations and the role of the oral healthcare workers in COVID-19. *Oral Dis.* 2020; Available at: <https://doi.org/10.1111/odi.13688>
36. Al - Khatib A. Oral manifestations in COVID - 19 patients. *Oral Dis.* 2020; Available at: <https://doi.org/10.1111/odi.13555>
37. Díaz Rodríguez M, Jimenez Romera A, Villarroel M. Oral manifestations associated with COVID-19. *Oral Dis.* 2020; Available at: <https://doi.org/10.1016/j.ijid.2020.08.071>
38. Corchuelo J, Ulloa FC. Oral manifestations in a patient with a history of asymptomatic COVID-19: Case report. *Int J Infect Dis.* 2020; 100: 154–7. Available at: <https://doi.org/10.1111/odi.13463>
39. Scallop AR. Oral manifestations in coronavirus disease 2019 (COVID-19). *Oral Dis.* 2020; Available at: <https://doi.org/10.1111/odi.13477>
40. Amorim dos Santos J, Normando AGC, Carvalho da Silva RL, Acevedo AC, De Luca Canto G, Sugaya N, et al. Oral manifestations in patients with COVID-19: a living systematic review. *J Dent Res.* 2021;100(2):141–54. Available at: <https://doi.org/10.1177/0022034520957289>
41. Petrescu N, Lucaciu O, Roman A. Oral mucosa lesions in COVID- 19. *Oral Dis.* 2020; Available at: <https://doi.org/10.1111/odi.13499>
42. Dos Santos JA, Normando AGC, da Silva RLC, De Paula RM, Cembranel AC, Santos-Silva AR, et al. Oral mucosal lesions in a COVID-19 patient: ¿New signs or secondary manifestations? *Int J Infect Dis.* 2020; 97:326–8. Available at: <https://doi.org/10.1016/j.ijid.2020.06.012>
43. Cruz Tapia RO, Peraza Labrador AJ, Guimaraes DM, Matos Valdez LH. Oral mucosal lesions in patients with SARS- CoV- 2 infection. Report of four cases. Are they a true sign of COVID- 19 disease? *Spec Care Dent.* 2020;40(6):555–60. Available at: <https://doi.org/10.1111/scd.12520>
44. Tomo S, Miyahara GI, Simonato LE. Oral mucositis in a SARS- CoV- 2- infected patient: Secondary or truly associated condition? *Oral Dis.* 2020; Available at: <https://doi.org/10.1111/odi.13570>
45. Fini MB. Oral saliva and CVID-19. *Oral Oncol.* 2020;104821. Available at: <https://doi.org/10.1016/j.oraloncology.2020.104821>

46. Halboub E, Al-Maweri SA, Alanazi RH, Qaid NM, Abdulrab S. Orofacial manifestations of COVID-19: a brief review of the published literature. *Braz Oral Res.* 2020;34. Available at: <http://dx.doi.org/10.1590/1807-3107bor-2020.vol34.0124>
47. Ponce JB, Tjioe KC. Overlapping findings or oral manifestations in new SARS- CoV- 2 infection. *Oral Dis.* 2020; Available at: <https://doi.org/10.1111/odi.13478>
48. Pedrosa S, Sipert CR, Nogueira FN. Salivary Glands, Saliva and Oral Findings in COVID-19 Infection. *Pesqui Bras Odontopediatria Clin Integr.* 2020; 20:104. Available at: <http://revista.uepb.edu.br/index.php/pboci/article/view/5646>
49. Sinjari B, D'Ardes D, Santilli M, Rexhepi I, D'Addazio G, Di Carlo P, et al. SARS-CoV-2 and Oral Manifestation: An Observational, Human Study. *J Clin Med.* 2020; 9 (10): 3218. Available in: <https://doi.org/10.3390/jcm9103218>
50. Ibekwe TS, Fasunla AJ, Orimadegun AE. Systematic review and meta-analysis of smell and taste disorders in COVID-19. *OTO open.* 2020; 4 (3): 2473974X20957975. Available in: <https://doi.org/10.1177/2473974X20957975>
51. Aziz M, Perisetti A, Lee-Smith WM, Gajendran M, Bansal P, Goyal H. Taste changes (Dysgeusia) in COVID-19: a systematic review and meta-analysis. *Gastroenterology.* 2020; 159 (3): 1132–3. Available in: <https://doi.org/10.1053/j.gastro.2020.05.003>
52. Dzedzic A, Wojtyczka R. The impact of coronavirus infectious disease 19 (COVID-19) on oral health. *Oral Dis.* 2020; Available in: <https://doi.org/10.1111/odi.13359>
53. Riad A, Kassem I, Hockova B, Badrah M, Klugar M. Tongue ulcers associated with SARS-CoV-2 infection: A case series. *Oral Dis.* 2020; Available at doi: 10.1111/odi.13635
54. Herrera D, Serrano J, Roldán S, Sanz M. Is the oral cavity relevant in SARS-CoV-2 pandemic? *Clin Oral Investig.* 2020;24(8):2925–30. Available at: <https://doi.org/10.1007/s00784-020-03413-2>
55. Rocha BA, Souto GR, Grossmann S de MC, de Aguiar MCF, de Andrade BAB, Romañach MJ, et al. Viral enanthema in oral mucosa: a possible diagnostic challenge in the COVID- 19 pandemic. *Oral Dis.* 2020; Available at: <https://doi.org/10.1111/odi.13473>
56. Fini MB. What dentists need to know about COVID-19. *Oral Oncol.* 2020;104741. Available at: <https://doi.org/10.1016/j.oraloncology.2020.104741>
57. Vaira LA, Salzano G, Deiana G, De Riu G. Anosmia and ageusia: common findings in COVID- 19 patients. *Laryngoscope.* 2020; Available at: 10.1002/lary.28692
58. Wang Z, Yang B, Li Q, Wen L, Zhang R. Clinical features of 69 cases with coronavirus disease 2019 in Wuhan, China. *Clin Infect Dis.* 2020;71(15):769–77. Available at: <https://doi.org/10.1093/cid/ciaa272>
59. Jimenez- Cauhe J, Ortega- Quijano D, Carretero- Barrio I, Suarez- Valle A, Saceda- Corralo D, Moreno- Garcia del Real C, et al. Erythema multiforme- like eruption in patients with COVID- 19 infection: clinical and histological findings. *Clin Exp Dermatol.* 2020;45(7):892–5. Available at: <https://doi.org/10.1111/ced.14281>

60. Lechien JR, Chiesa-Estomba CM, De Siati DR, Horoi M, Le Bon SD, Rodriguez A, et al. Olfactory and gustatory dysfunctions as a clinical presentation of mild-to-moderate forms of the coronavirus disease (COVID-19): a multicenter European study. *Eur Arch Oto-Rhino-Laryngology*. 2020;277(8):2251–61. Available at: <https://doi.org/10.1007/s00405-020-05965-1>
61. Salehi M, Ahmadikia K, Mahmoudi S, Kalantari S, Jamalimoghadamsiahkali S, Izadi A, et al. Oropharyngeal candidiasis in hospitalised COVID-19 patients from Iran: Species identification and antifungal susceptibility pattern. *Mycoses*. 2020;63(8):771–8. Available at: <https://doi.org/10.1111/myc.13137>
62. Gupta S, Mohindra R, Chauhan PK, Singla V, Goyal K, Sahni V, et al. SARS-CoV-2 detection in gingival crevicular fluid. *J Dent Res*. 2020;0022034520970536. Available at: <https://doi.org/10.1177/0022034520970536>
63. Zhao Y, Zhao Z, Wang Y, Zhou Y, Ma Y, Zuo W. Single-cell RNA expression profiling of ACE2, the receptor of SARS-CoV-2. *Am J Respir Crit Care Med*. 2020;202(5):756–9. Available at: <https://doi.org/10.1164/rccm.202001-0179LE>
64. Zou X, Chen K, Zou J, Han P, Hao J, Han Z. Single-cell RNA-seq data analysis on the receptor ACE2 expression reveals the potential risk of different human organs vulnerable to 2019-nCoV infection. *Front Med*. 2020;1–8. Available at: <https://doi.org/10.1007/s11684-020-0754-0>
65. Zhang H, Penninger JM, Li Y, Zhong N, Slutsky AS. Angiotensin-converting enzyme 2 (ACE2) as a SARS-CoV-2 receptor: molecular mechanisms and potential therapeutic target. *Intensive Care Med*. 2020;46(4):586–90. Available at: <https://link.springer.com/article/10.1007/s00134-020-05985-9>
66. Sinadinos A, Shelswell J. Oral ulceration and blistering in patients with COVID-19. *Evid Based Dent*. 2020;21(2):49. Available at: <https://www.nature.com/articles/s41432-020-0100-z>
67. Maciel PP, Martelli Júnior H, Martelli DRB, Machado RA, Andrade PV de, Perez DE da C, et al. Covid-19 pandemic: Oral repercussions and its possible impact on oral health. *Pesqui Bras Odontopediatria Clin Integr*. 2020;20. Available at: <https://doi.org/10.1590/pboci.2020.135>
68. Fantozzi PJ, Pampena E, Di Vanna D, Pellegrino E, Corbi D, Mammucari S, et al. Xerostomia, gustatory and olfactory dysfunctions in patients with COVID-19. *Am J Otolaryngol*. 2020;41(6):102721. Available at: <https://doi.org/10.1016/j.amjoto.2020.102721>
69. Badran Z, Gaudin A, Struillou X, Amador G, Soueidan A. Periodontal pockets: A potential reservoir for SARS-CoV-2? *Med Hypotheses*. 2020; 143:109907. Available at: <https://doi.org/10.1016/j.mehy.2020.109907>
70. Nouchi A, Chastang J, Miyara M, Lejeune J, Soares A, Ibanez G, et al. Prevalence of hyposmia and hypogeusia in 390 COVID-19 hospitalized patients and outpatients: a cross-sectional study. *Eur J Clin Microbiol Infect Dis*. 2020;1–7. Available at: <https://link.springer.com/article/10.1007/s10096-020-04056-7>

71. Chen C, Chen M, Cheng C, Chi Y, Hu Z, Liu Y, et al. A special symptom of olfactory dysfunction in coronavirus disease 2019: report of three cases. *J Neurovirol.* 2020; 26:456–8. Available at: <https://link.springer.com/article/10.1007%2Fs13365-020-00849-w>
72. Serafini A, Kurotschka PK, Bertolani M, Riccomi S. An itchy erythematous papular skin rash as a possible early sign of COVID-19: a case report. *J Med Case Rep.* 2020;14(1):1–7. Available at: <https://jmedicalcasereports.biomedcentral.com/articles/10.1186/s13256-020-02538-y>
73. Nanda A, Vura NVRK, Gravenstein S. COVID-19 in older adults. *Aging Clin Exp Res.* 2020; 32:1199–202. Available at: <https://link.springer.com/article/10.1007%2Fs40520-020-01581-5>
74. Meini S, Suardi LR, Busoni M, Roberts AT, Fortini A. Olfactory and gustatory dysfunctions in 100 patients hospitalized for COVID-19: sex differences and recovery time in real-life. *Eur Arch oto-rhino-laryngology.* 2020; 277:3519–23. Available at: <https://doi.org/10.1007/s00405-020-06102-8>
75. Ni W, Yang X, Yang D, Bao J, Li R, Xiao Y, et al. Role of angiotensin-converting enzyme 2 (ACE2) in COVID-19. *Crit Care.* 2020;24(1):1–10. Available at: <https://doi.org/10.1186/s13054-020-03120-0>
76. Wu J, Deng W, Li S, Yang X. Advances in research on ACE2 as a receptor for 2019-nCoV. *Cell Mol Life Sci.* 2020;1–14. Available at: <https://link.springer.com/article/10.1007/s00018-020-03611-x>
77. Quincho-Rosales DA, Castro-Rodríguez Y, Grados-Pomarino S. Considerations on dental care in Peru during the COVID-19 pandemic. *Cuban Journal of Stomatology,* 2020; 57 (3). Available at: [http://scielo.sld.cu/scielo.php?script=sci\\_arttext&pid=S0034-75072020000300005&lng=es](http://scielo.sld.cu/scielo.php?script=sci_arttext&pid=S0034-75072020000300005&lng=es).
78. da Silva Moura JF, Moura KS, da Silva Pereira R, Marinho RRB. COVID-19: A odontologia frente à pandemia. *Brazilian J Heal Rev.* 2020;3(4):7276–85. Available at: <https://doi.org/10.34119/bjhrv3n4-006>
79. Salgado SS, Campuzano R, Vidale MD, Cisneros EG, Miniello TG. Recomendaciones para prevención y control de infecciones por SARS-CoV-2 en odontología. *Rev Odontol.* 2020;22(2):5–32. Available at: <https://doi.org/10.29166/odontologia.vol22.n2.2020-5-32>
80. Dar Odeh N, Babkair H, Abu-Hammad S, Borzangy S, Abu-Hammad A, Abu-Hammad O. COVID-19: present and future challenges for dental practice. *Int J Environ Res Public Health.* 2020;17(9):3151. Available at: <https://doi.org/10.3390/ijerph17093151>
81. Tang K, Wang Y, Zhang H, Zheng Q, Fang R, Sun Q. Cutaneous manifestations of the Coronavirus Disease 2019 (COVID- 19): A brief review. *Dermatol Ther.* 2020;33(4): e13528. Available at: <https://doi.org/10.1111/dth.13528>
82. Riad A, Gad A, Hockova B, Klugar M. Oral candidiasis in non- severe COVID- 19 patients: call for antibiotic stewardship. *Oral Surg.* 2020; Available at: <https://doi.org/10.1111/ors.12561>

83. Iranmanesh B, Khalili M, Amiri R, Zartab H, Aflatoonian M. Oral manifestations of COVID- 19 disease: A review article. *Dermatol Ther.* 2021;34(1): e14578. Available at: <https://doi.org/10.1111/dth.14578>

84. Glavina A, Biočina- Lukenda D, Mravak- Stipetić M, Markeljević J. Oral symptoms and lesions in SARS- CoV- 2 positive patient. *Oral Dis.* 2020; Available at: <https://dx.doi.org/10.1111%2Fodi.13596>

85. Troeltzsch M, Berndt R, Troeltzsch M. Is the oral cavity a reservoir for prolonged SARS-CoV-2 shedding? *Med Hypotheses.* 2021; 146:110419. Available at: <https://doi.org/10.1016/j.jaad.2020.11.034>

86. Bemquerer LM, de Arruda JAA, Soares MPD, Mesquita RA, Silva TA. The oral cavity cannot be forgotten in the COVID-19 era: Is there a connection between dermatologic and oral manifestations? *J Am Acad Dermatol.* 2021;84(3): e143–5. Available at: <https://doi.org/10.7326/M20-6569>

87. Bastos ML, Perlman-Arrow S, Menzies D, Campbell JR. The Sensitivity and Costs of Testing for SARS-CoV-2 Infection With Saliva Versus Nasopharyngeal Swabs: A Systematic Review and Meta-analysis. *Ann Intern Med.* 2021. Available at: <https://doi.org/10.7326/M20-6569>

88. Marouf N, Cai W, Said KN, Daas H, Diab H, Chinta VR, et al. Association between periodontitis and severity of COVID- 19 infection: A case–control study. *J Clin Periodontol.* 2021; Available at: <https://doi.org/10.1186/s13643-020-01574-5>

89. Bastani P, Mohammadpour M, Ghanbarzadegan A, Kapellas K, Do LG. Global concerns of dental and oral health workers during COVID-19 outbreak: a scope study on the concerns and the coping strategies. *Syst Rev.* 2021;10(1):1–9. Available at: <https://doi.org/10.3389/fmed.2020.571214>

90. La Rosa GRM, Libra M, De Pasquale R, Ferlito S, Pedullà E. Association of Viral Infections With Oral Cavity Lesions: Role of SARS-CoV-2 Infection. *Front Med.* 2021; 7:1059. Available at: <https://doi.org/10.3390/jcm10040581>

91. Hocková B, Riad A, Valky J, Šulajová Z, Stebel A, Slávik R, et al. Oral Complications of ICU Patients with COVID-19: Case-Series and Review of Two Hundred Ten Cases. *J Clin Med.* 2021;10(4):581. Available at: <https://doi.org/10.3390/jcm10040581>

92. Fonseca Orcina B, da Silva Santos PS, ORCINA BF, SANTOS PSS. Oral Manifestation COVID-19 and the Rapid Resolution of Symptoms Post-Phtalox Treatment: a Case Series. *Int J Odontostomat.* 2021;15(1):67–70. Available at: 10.4103/jfmpc.jfmpc\_1605\_20

93. Singh G, Priya H, Mishra D, Kumar H, Monga N, Kumari K. Oral manifestations and dental practice recommendations during COVID-19 pandemic. *J Fam Med Prim Care.* 2021;10(1):102. Available at: <https://doi.org/10.1111/dth.14578>

94. Rochefort J, Chaux AG. Oral mucosal lesions and Covid-19: symptoms and/or complication? *J Oral Med Oral Surg.* 2021;27(2):23. Available at:

<https://doi.org/10.1051/mbcb/2021002>

95. Riad A, Issa J, Chuchmova V, Slezakova S, Gomaa E, Pokorna A, et al. Oral ulcers of COVID-19 patients: a scoping review protocol. medRxiv. 2021; Available at: <https://doi.org/10.1101/2021.01.22.21250326>
96. Nuno- Gonzalez A, Martin- Carrillo P, Magaletsky K, Martin Rios MD, Herranz Mañas C, Artigas Almazan J, et al. Prevalence of mucocutaneous manifestations in 666 patients with COVID- 19 in a field hospital in Spain: oral and palmoplantar findings. Br J Dermatol. 2020; Available at: <https://doi.org/10.1111/bjd.19564>
97. Gofur NRP. Impact of SARS-CoV-2 on periodontal tissue manifestation. J Int Oral Heal. 2020;12(8):90. Available at: [10.4103/jioh.jioh\\_205\\_20](https://doi.org/10.4103/jioh.jioh_205_20)
98. Li Y, Ren B, Peng X, Hu T, Li J, Gong T, et al. Saliva is a non- negligible factor in the spread of COVID- 19. Mol Oral Microbiol. 2020;35(4):141–5. Available at: <https://doi.org/10.1111/omi.12289>
99. Favia G, Tempesta A, Barile G, Brienza N, Capodiferro S, Vestito MC, et al. Covid-19 Symptomatic Patients with Oral Lesions: Clinical and Histopathological Study on 123 Cases of the University Hospital Policlinic of Bari with a Purpose of a New Classification. J Clin Med. 2021;10(4):757. Available at: <https://doi.org/10.3390/jcm10040757>
100. Arabi YM, Fowler R, Hayden FG. Critical care management of adults with community-acquired severe respiratory viral infection. Intensive Care Med. 2020;46(2):315–28. Available at: <https://doi.org/10.1007/s00134-020-05943-5>
101. Cuthbertson BH, Dale CM. Less daily oral hygiene is more in the ICU: yes. Intensive Care Med. 2020;1–3. Available at: <https://doi.org/10.1007/s00134-020-06021-6>

## ANNEXES

*Table 1.* Search Strategy.

<i>Search strategy.</i>	<i>Database collection keywords or descriptors</i>
PubMed	((("severe acute respiratory syndrome coronavirus 2"[Supplementary Concept] OR "severe acute respiratory syndrome coronavirus 2"[All Fields] OR "SARS-COV-2"[All Fields] OR "SARS-COV-2"[Title] OR "COVID-19"[Title] OR "covid 19 virus infection"[Title/Abstract] OR "coronavirus disease 2019"[Title/Abstract]) AND "oral manifestations"[Title/Abstract] OR "oral symptoms"[Title/Abstract] OR ("Mouth"[Title/Abstract] AND "tooth diseases"[Title/Abstract]) OR (Oral lesions "[Title/Abstract] OR (Oral mucosal lesions"[Title/Abstract)
Scopus	(oral AND clinical AND manifestations OR oral AND manifestations OR tooth AND diseasesANDofANDsars-cov-2ORcovid-19)
Epistemonikos	(title:(covid-19) OR abstract:(covid-19)) OR (title:(SARS-CoV-2) OR abstract:(SARS-CoV-2)) OR (title:(Coronavirus Disease 2019) OR abstract:(Coronavirus Disease 2019)) AND (title:(oral symptoms) OR abstract:(oral symptoms)) OR (title:(oral diseases) OR abstract:(oral diseases)) OR (title:(Oral Manifestations) OR abstract:(Oral Manifestations))
Web of Science	TITLE:(oral manifestations OR oral clinical manifestations OR tooth diseases AND COVID-19) Time period: Year to date. Índices: SCI-EXPANDED, SSCI, A&HCI, ESCI.
	TÍTULO:(oral manifestations OR oral clinical manifestations OR tooth diseases AND COVID-19) Período de tiempo: Año hasta la fecha. Índices: SCI-EXPANDED, SSCI, A&HCI, ESCI.
Springer	'oral manifestations OR tooth diseases OR oral clinical manifestations AND COVID-19 OR SARS-COV-2 '
Lilacs	abstract:(covid-19)) OR (title:(SARS-CoV-2) OR abstract:(SARS-CoV-2)) AND (title:(oral%20manifestations) OR abstract:(oral manifestations))

*Source. self-made.*

**Table 2.** Descriptive characteristics of the included studies (n = 100)

<i>Artículo</i>	<i>Main author and year of publication</i>	<i>Country</i>	<i>Type of study</i>
Advice for the public about rumors about the new coronavirus (2019-nCoV).	World Health Organization	Europe	Short communication
Features, Evaluation, and Treatment of Coronavirus	Cascella M, 2020	Italy	Review
Un mundo, una salud: la epidemia por el nuevo coronavirus COVID-19.	Trilla A. 2020	Barcelona, Spain	Editorial
Attitude to COVID-19 in routine dental practice.	Aguilar Salas VM, 2020	Arequipa, Peru	Current article in the social, humanities and pedagogical sciences
Transmission routes of 2019-nCoV and controls in dental practice.	Peng X, 2020	China	Review article
High expression of ACE2 receptor of 2019-nCoV on the epithelial cells of oral mucosa.	Xu H, 2020	China	Review
Oral Manifestations of COVID-19 Infection.	Nemeth-Kohanszky ME, 2020	Santiago, Chile	Review
Patient management in dental care and staff biosecurity during the SARS-CoV-2 (COVID-19) coronavirus outbreak.	Aguilera-Galaviz L 2020	Zacatecas, Mexico	Review article
Coronavirus disease 2019 (COVID-19) and its impact on dental practice: a review.	Ramírez-Velásquez M, 2020	Ecuador	Review article
COVID-19 and its importance in dental care: literature review and update.	Gómez JLM. 2020	Lima, Peru	Review article
COVID-19 y manifestaciones orales.	Cornejo-Ovalle M, 2020	Chile	Letter to the publisher
COVID-19 y la Odontología: una Revisión de las Recomendaciones y Perspectivas para Latinoamérica.	Sigua-Rodríguez EA, 2020	Colombia	Review
Oral manifestation of Covid-19 as an inaugural symptom?	Chaux-Bodard A-G, 2020	France	Letter to the publisher
SARS-CoV-2 and oral ulcers: A causative agent or a predisposing factor?	Abu-Hammad S, 2020	Amman, Jordanian	Letter to the publisher
Comment on: Oral Manifestation of	Abanoub R,	Czech Republic /	Letter to the

COVID-19 as an inaugural symptom?	2020	Egypt	publisher
Considerations on oral manifestations of COVID-19.	Cervantes FA, 2020	Brazil	Letter to the publisher
Coronavirus COVID-19 impacts to dentistry and potential salivary diagnosis.	Sabino-Silva R, 2020	Canada	Letter to the publisher
COVID-19-Related Oral Manifestations: Early Disease	Riad A, 2020	Czech Republic / Egypt	Letter to the publisher
Current evidence on possible oral manifestations of SARS-CoV-2 infection.	Rocha AL, 2020	Brazil	Letter to the publisher
Is gustatory impairment the first report of an oral manifestation in COVID-19?	Vinayachandran D, 2020	India	Letter to the publisher
Letter to Editor: Oral lesions in a patient with Covid-19.	Soares CD, 2020	Brazil	Letter to the publisher
Necrotizing periodontal disease: Oral manifestation of COVID-19.	Patel J, 2020	Kingdom United	Letter to the publisher
Oral cavity lesions as a manifestation of the novel virus (COVID-19).	Ansari R, 2020	Iran	Letter to the publisher
Oral erosions and petechiae during SARS-CoV-2 infection.	Ciccarese G, 2020	Italy	Letter to the publisher
Oral lesions in COVID-19 infection: Is long-term follow-up important in the affected patients?	Bezerra TM, 2020	Brazil	Letter to the publisher
Oral manifestation of Covid-19 as an inaugural symptom?	Chaux-Bodard A-G, 2020	France	Letter to the publisher
Oral manifestations and the role of the oral healthcare workers in COVID-19.	Di Spirito F, 2020	Italy	Letter to the publisher
Oral manifestations associated with COVID-19.	Díaz Rodríguez M, 2020	Madrid, Spain	Letter to the publisher
Oral manifestations in coronavirus disease 2019 (COVID-19).	Vieira AR, 2020	EE. UU	Letter to the publisher
Oral manifestations in patients with COVID-19: a living systematic review.	Amorim dos Santos J, 2020	Brazil	Live systematic review
Oral mucosa lesions in COVID-19.	Petrescu N, 2020	Romania	Letter to the publisher
Oral mucositis in a SARS-CoV-2-infected patient: Secondary or truly associated condition?	Tomo S, 2020	Brazil	Letter to the publisher
Coronavirus disease 19 (COVID-19): implications for clinical dental care	Ather A, 2020	San Antonio, Texas	Review article
Could there be a link between oral hygiene and the severity of SARS-	Sampson V, 2020	London, United Kingdom	Review

CoV-2 infections?			
Detection of 2019-nCoV in Saliva and Characterization of Oral Symptoms in COVID-19 Patients	Chen L, 2020	China	Original article
Emergency measures for acute oral mucosa diseases during the outbreak of COVID-19	Guo Y, 2020	China	Letter to the publisher
Olfactory and Oral Manifestations of COVID-19: Sex-Related Symptoms— A Potential Pathway to Early Diagnosis	Biadsee A, 2020	Israel	Original research
Oral lesions in patients with SARS-CoV-2 infection: could the oral cavity be a target organ?	Brandão TB, 2020	Brazil	Case report
Oral manifestations in a patient with a history of asymptomatic COVID-19: Case report	Corchuelo J, 2020	Colombia	Case report
Oral manifestations in COVID-19 patients	Al-Khatib A, 2020	Jordan	Letter to the publisher
Oral mucosal lesions in a COVID-19 patient: New signs or secondary manifestations?	Dos Santos JA, 2020	Brazil	Case report
Oral mucosal lesions in patients with SARS-CoV-2 infection. Report of four cases. Are they a true sign of COVID-19 disease?	Cruz Tapia RO, 2020	Mexico	Case report
Oral saliva and COVID-19	Fini MB. 2020	EE. UU	Review
Orofacial manifestations of COVID-19: a brief review of the published literature	Halboub E, 2020	Brazil	Critical review
Overlapping findings or oral manifestations in new SARS-CoV-2 infection	Ponce JB, 2020	Brazil	Letter to the publisher
SARS-CoV-2 and Oral Manifestation: An Observational, Human Study	Sinjari B, 2020	Italy	Observation study in humans
Salivary Glands, Saliva and Oral Findings in COVID-19 Infection	Pedrosa S, 2020	Brazil	Critical review
Systematic Review and Meta-analysis of Smell and Taste Disorders in COVID-19	Ibekwe TS, 2020	Abuja/Nigeria	Systematic review/Meta-analysis
Taste Changes (Dysgeusia) in COVID-19: A systematic review and meta-analysis.	Aziz M, 2020	EE. UU	Systematic review / Meta-analysis
Is the oral cavity relevant in SARS-CoV-2 pandemic?	Herrera D, 2020	Madrid, Spain	Discussion report

The impact of coronavirus infectious disease 19 (COVID-19) on oral health	Dziedzic A, 2020	Polonia	Short communication
Tongue ulcers associated with SARS-CoV-2 infection: A case series	Riad A, 2020	Czech Republic / Egypt	Letter to the publisher
Viral enanthema in oral mucosa: A possible diagnostic challenge in the COVID-19 pandemic	Rocha BA, 2020	Brazil	Letter to the publisher
What dentists need to know about COVID-19	Fini MB. 2020	EE. UU	Review
Anosmia and Ageusia: Common Findings in COVID-19 Patients	Vaira LA, 2020	Italy	Fast communication
Clinical Features of 69 Cases with Coronavirus Disease 2019 in Wuhan, China	Wang Z, 2020	China	Review
Coronavirus Disease 2019 (COVID-19): Emerging and Future Challenges for Dental and Oral Medicine	Meng L, 2020	China	Discoverie
Erythema multiforme-like eruption in patients with COVID-19 infection: clinical and histological findings	Jimenez-Cauhe J, 2020	Madrid, Spain	Correspondence
SARS-CoV-2 Detection in Gingival Crevicular Fluid	Gupta S, 2020	India	Investigation Reports: Biologists
Angiotensin-converting enzyme 2 (ACE2) as a SARS-CoV-2 receptor: molecular mechanisms and potential therapeutic target	Zhang H, 2020	Canada	Understanding the disease
Oropharyngeal candidiasis in hospitalized COVID-19 patients from Iran: Species identification and antifungal susceptibility pattern	Salehi M, 2020	Iran	Original article
Single-Cell RNA Expression Profiling of ACE2, the Receptor of SARS-CoV-2	Zhao Y, 2020	China	Correspondence
Oral ulceration and blistering in patients with COVID-19	Sinadinos A, 2020	United Kingdom	Number of cases
COVID-19 Pandemic: Oral Repercussions and its Possible Impact on Oral Health	Maciel PP, 2020	Brazil	Critical review
Xerostomia, gustatory and olfactory dysfunctions in patients with COVID-19	Fantozzi PJ, 2020	Italy	Review

Periodontal pockets: A potential reservoir for SARS-CoV-2?	Badran Z, 2020	France	Review
Olfactory and gustatory dysfunctions as a clinical presentation of mild to moderate forms of the coronavirus disease (COVID19): a multicenter European study	Lechien JR, 2020	France	Review
Single-cell RNA-seq data analysis on the receptor ACE2 expression reveals the potential risk of different human organs vulnerable to 2019-nCoV infection.	Zou X, 2020	China	Investigation article
Prevalence of hyposmia and hypogeusia in 390 COVID-19 hospitalized patients and outpatients: a cross-sectional study	Nouchi A, 2020	France	Original article
A special symptom of olfactory dysfunction in coronavirus disease 2019: report of three cases	Chen C, 2020	China	Case report
An itchy erythematous popular skin rash as a possible early sign of COVID-19: a case report	Serafini A, 2020	Italy	Case report
COVID-19 in older adults	Nanda A, 2020	EE. UU	Short communication
Olfactory and gustatory dysfunctions in 100 patients hospitalized for COVID-19: sex differences and recovery time in real-life	Meini S, 2020	Italy	Short communication
Role of angiotensin-converting enzyme 2 (ACE2) in COVID-19	Ni W, 2020	China	Review
Advances in research on ACE2 as a receptor for 2019-nCoV	Wu J, 2020	China	Review
Considerations on dental care in Peru during the COVID-19 pandemic	Quincho-Rosales DA, 2020	Peru	Current vision
COVID-19: A odontology in front that's pandemic / COVID-19: Dentistry in the face of the pandemic	da Silva Moura JF, 2020	Brazil	Review
Recommendations for prevention and control of SARS-CoV-2 infections in dentistry	Salgado SS, 2020	Brazil	Bibliographic review
Olfactory and gustatory dysfunctions as a clinical presentation of mild-to-moderate forms of the coronavirus disease (COVID-19): a multicenter	Lechien JR, 2020	France	Rhinology

European study.			
COVID-19: present and future challenges for dental practice.	Dar Odeh N, 2020	Jordan	Review
Cutaneous manifestations of the Coronavirus Disease 2019 (COVID-19): A brief review.	Tang K, 2020	China	Short paper
Oral candidiasis in non-severe COVID-19 patients: call for antibiotic stewardship.	Riad A, 2020	Egypt	Letter to the publisher
Oral manifestations of COVID-19 disease: A review article.	Iranmanesh B, 2021	Iran	Review article
Oral symptoms and lesions in SARS-CoV-2 positive patient.	Glavina A, 2020	Croatia	Letter to the publisher
Is the oral cavity a reservoir for prolonged SARS-CoV-2 shedding?	Troeltzsch M, 2021	Ansbach, Germany	Review
The oral cavity cannot be forgotten in the COVID-19 era: Is there a connection between dermatologic and oral manifestations?	Bemquerer LM, 2021	Brazil	Letter to the publisher
The Sensitivity and Costs of Testing for SARS-CoV-2 Infection With Saliva Versus Nasopharyngeal Swabs: A Systematic Review and Meta-analysis.	Bastos ML, 2021	Canada	Systematic review / Meta-analysis
Association between periodontitis and severity of COVID-19 infection: A case-control study.	Marouf N, 2021	Madrid, Spain	Original article
Global concerns of dental and oral health workers during COVID-19 outbreak: a scope study on the concerns and the coping strategies.	Bastani P, 2021	Iran	Systematic review
Association of Viral Infections With Oral Cavity Lesions: Role of SARS-CoV-2 Infection.	La Rosa GRM, 2021	Italy	Review article
Oral Complications of ICU Patients with COVID-19: Case-Series and Review of Two Hundred Ten Cases.	Hocková B, 2021	Slovakia	Review
Oral Manifestation COVID-19 and the Rapid Resolution of Symptoms Post-Phtalox Treatment: a Case Series.	Fonseca Orcina B, 2021	Brazil	Letter to the publisher
Oral manifestations and dental practice recommendations during COVID-19 pandemic.	Singh G, 2021	India	Review article
Oral ulcers of COVID-19 patients: a scoping review protocol.	Riad A, 2021	Czech Republic	Scoping Review
Oral mucosal lesions and Covid-19: symptoms and/or complication?	Rocheftort J, 2021	France	Letter to the publisher
Prevalence of mucocutaneous	Nuno-Gonzalez	Madrid, Spain	Research letter

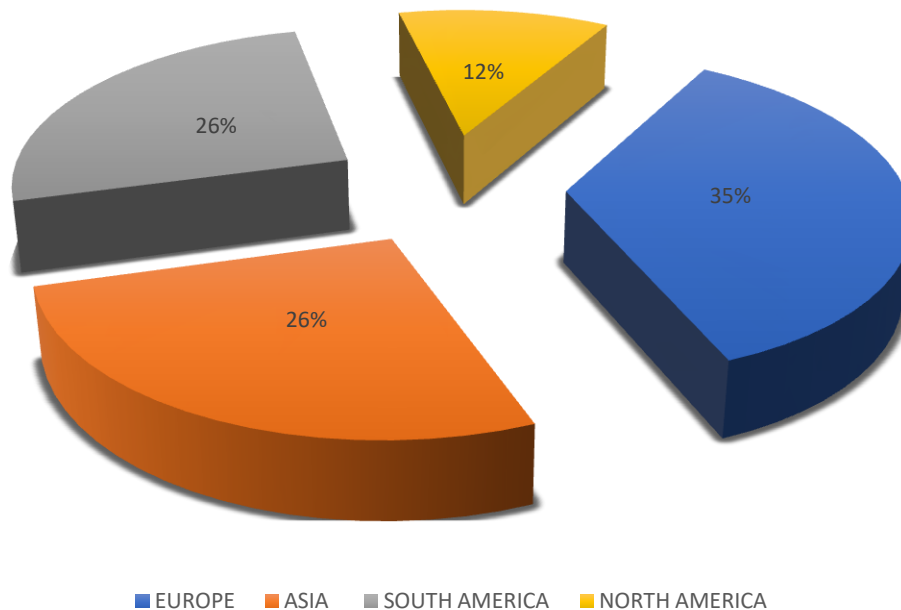
manifestations in 666 patients with COVID-19 in a field hospital in Spain: oral and palmoplantar findings.	A, 2020		
Impact of SARS-CoV-2 on periodontal tissue manifestation.	Gofur NRP, 2020	Indonesia	Review article
Saliva is a non-negligible factor in the spread of COVID-19.	Li Y, 2020	China	Review article
Covid-19 Symptomatic Patients with Oral Lesions: Clinical and Histopathological Study on 123 Cases of the University Hospital Policlinic of Bari with a Purpose of a New Classification.	Favia G, 2021	Italy	Review
Critical care management of adults with community-acquired severe respiratory viral infection.	Arabi YM, 2020	Saudi Arabia	Letter to the publisher
Less daily oral hygiene is more in the ICU: yes.	Cuthbertson BH, 2020	Toronto, Canada	Letter to the publisher

*Source. made.*

*self-*

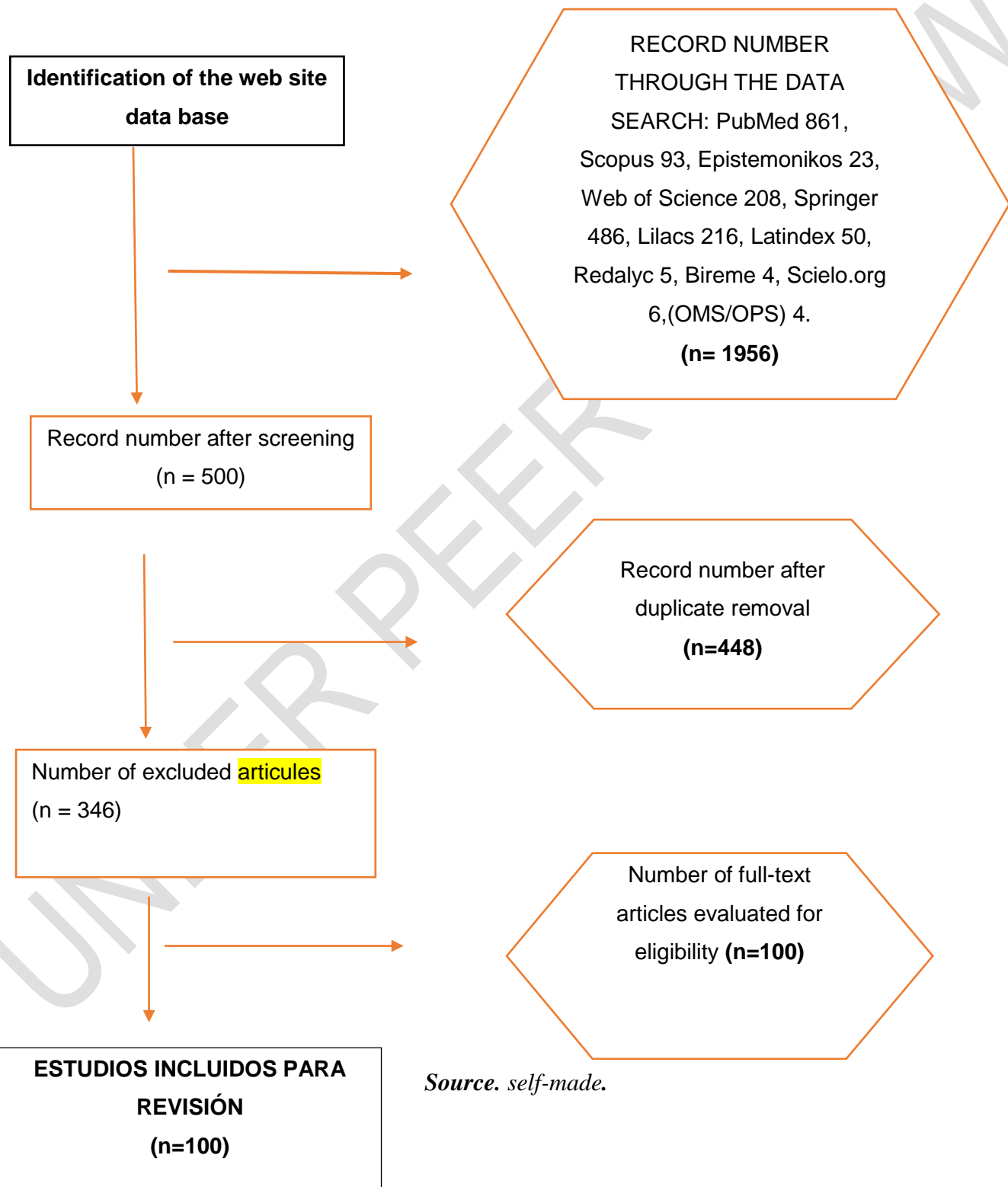
Figure  
**Fig. 1:** Studies incorporated at

*world level*



*Source. self-made.*

Figure 2. Flowchart of the article search and screening process



UNDER PEER REVIEW