

## **Review Article**

### **A Rare Entity of Desmoid Tumour**

#### **Abstract**

Desmoid tumours is a rare monoclonal, fibrotic boom which is characterized by means of way of a variable and conventional scientific course. Desmoids are invasive and related with a excessive close by **recurrence** rate, do no longer have cancerous activity. Desmoids **aare** identified with the useful resource **of changes occures of**  $\beta$ -catenin gene A.P.C..

Many troubles regarding the appropriate cure of victims with desmoid tumours **rema** debateful still, surgical cure is the clinical way, without if **mutiplying** and related with large extent attribute loss.

Therefore, the software of a multifunctional examination with multimodality therapy sorts the foundation of care for these patients. Waiting possibly be the most fabulous administration in some asymptomatic patients (**composition of above paras**)

Patients with desmoids positioned at the mesentery or in the head and neck area ought to showcase life-threatening troubles and choose greater aggressive therapy. This evaluation **articles** describes cure preferences and administration techniques for **the** sufferers with desmoid tumours with a middle of interest on advanced disease.

Postoperative radiotherapy reduces the nearby recurrence rate, in situations of worried surgical margins. Because of the heterogeneity of the biological behaviour of desmoids, including prolonged periods of constant ailment or spontaneous regression, therapy desires to be individualized to optimize nearby tumour manipulate**ion** and retain patients' exceptional (**expectations**) of life.

Desmoids are hence an outstanding uncommon tumour thing. Desmoids manifest between the age of 15 and 60 years, but in **unique at some factor(composition)** of late puberty,along with the top age 30 yrs. **2 different kinds of desimoid tumours are shows: except spreading desmoid tumour oocarnce, there is a high-quality relaion of desimoids(spelling and composition)**.It can be related to the potential of purpose persistent liver tissue damage and contamination that is accompanied with the beneficial aid of liver

**resuscitation** . **Meiotically lively liver cells, covered thru a** other environment, is most probable susceptible to **hereditary** stability is lost and most cancers development

Keywords: Beta catenin, Tumour markers, Fibrosis,

## Introduction

---

Clonality in tumours may be examined on girls which are hereditary for unique X-linked pointers due to the fact of random X inactivation effects in all women having parts from 20 cellular values . So, often timemany girls will be having each group of enzymes however informs of life threatening in a single marker is expressed. (**composition of para**)

the encoding of B protein seems the disturb normal increase use of contaminated hepatocytes via turning on for a number of some vital genes. **Hex** again motives suppress the tumour suppressor gene ie p53.[1]the consequences in B leading to liver cell carcinoma. Desmoids are invasive and related with a excessive close by **recurrence rate**, do no longer have cancerous activity. Desmoids **aare** identified with the useful resource of **changes occurs** of  $\beta$ -catenin gene A.P.C.[2]

**empty space????**

The time period desmoid tumour explains a fibrotic growth disease.

In its biological behaviour is categorised into

1. Nonharmful fibrotic tissue growth
2. sarcoma

Desmoid tumours with respect to WHO are described as “clonal fibrotic growths that origin in a inner hard cells and are characterised with the resource of infiltrative boom and a regional revival as an incapacity to spread ”[3] Desmoid tumours per chance have an effect on all sites, which include the arms legs , abdomins etc. Just 9% of spreading **desimoid** tumours is inside the **abdomin**, 70% of sufferers by hereditary **adematous** polyposis

(H.A.P.)-related **desimoid** tumours enhance intraabdominal condition. An **occarance** is clean cell cancers and about 1.12% every cancerous.

Desmoids are hence an outstanding uncommon tumour thing. Desmoids manifest between the age of 15 and 60 years, but in unique at **some factor?** of late puberty, along with the top age 30 yrs. 2 different kinds of **desimoid** tumours are shows: except spreading desmoid tumour **occarance**, there is a high-quality **relaion of desimoids** and AP. [4]

Comment [gk1]:

Low grade fibro myxoid sarcoma may be reliably marked out by means of detection of unique translocations which involve FUS-CREB3L2 gene. Gardner **fibrenoma** is a uncommon neoplasm in men and women having diseases in the intestinal **cocci** gene, A.P.C., in the greater arm of chromosome 5 thick take place on the same places. [5]

Primary therapy or victims having domestically **dissected desimoid** tumours stays surgical division. The remark would possibly a choice from a band of people. The increase sample of the tumours is very severe, tumour capsule are absent. [6] Due to the **bourders** in the tumours is tough to Difficult inside the tumour from wounds and cells, the R0 intersection is no longer continually plausible and **adjecent** radiaton is consequently regularly utilized following the cancer procedures.

Desmoids, on the other hand, has a **hugh** regional revival fee post surgical technique or radiaton or showcase very fast proliferation, **bas can oftentimes** take a multiple **repeattions**, many focus doses and consequently is now not amenable to recovery surgical therapy. DNA restore function and by the means of using inhibiting **cell cell(repeat words)** cycle checkpoints activated with the resource of DNA damage These make contributions to increased possibilities of most cancers through potential of capability of HTLV-1. [7]

In this situation, pharmacotherapy is frequently used **fto** cause ailment progression.

Some differential assessment of intra-abdominal fibrosis consists gastrointestinal stromal tumour , solitary fibrosis tumour (SFT), inflammatory myofibroblast tumour (I.M.T.), sclerosing mesenteritis, and retroperitoneal fibrosis (**maybe necrotic [Orimond condition brackets]**and side effect to some capsules or an hidden cancer , like a lymph tumour). nowadays the presence of **abdomin** based **desimoid**s with GSTs were once shown The **distinguishible** prognosis in desmoid-kind of fibrosis of large,in fibrotic cancers in tone of the **extremis** and relative fibrotic and myofibroblast figures for example nodular fasciitis and also hyper - trophic marks and keloids in other places.[8] The remark would possibly a choice from a band of people.

The most important intention was to keep the persons 's style of living , **the is scattred by** means of the function loss and suffering prompted with means of using growth disease. Clinical **techniquesfor** remedy of external or internal desmoid tumours consists of

1. With out hormonal therapy
2. Nonsteroidal anti-inflammatory capsules
3. standard chemotherapy procedures

It has no longer but been feasible to set up an splendid remedy procedure of these condition. on the other hand many comparison of victims with desmoid tumours is maintained, and remedy strategies per chance consist of surgical procedures and **radiaactive** and antigrowth therapy.[9]the following evaluate describes attainable therapy alternatives and **handeling** strategies for sufferers of **desimoid** tumours, also **center** of interest on highest quality conditon.

### **Clinical Characteristics**

One of the scientific route in desmoid tumours are strange and heterogeneous, characterised no longer solely by tumour growth, growth, and disorder progression however additionally through stabilization and even sudden **occarance**. Due to the **bourders in** the tumours ais tough to **Difficult** inside the tumour from wounds and cells , the R0 intersection is no longer continually plausible and **adjecent radiaton** is consequently regularly utilized following the cancer procedures. [10]

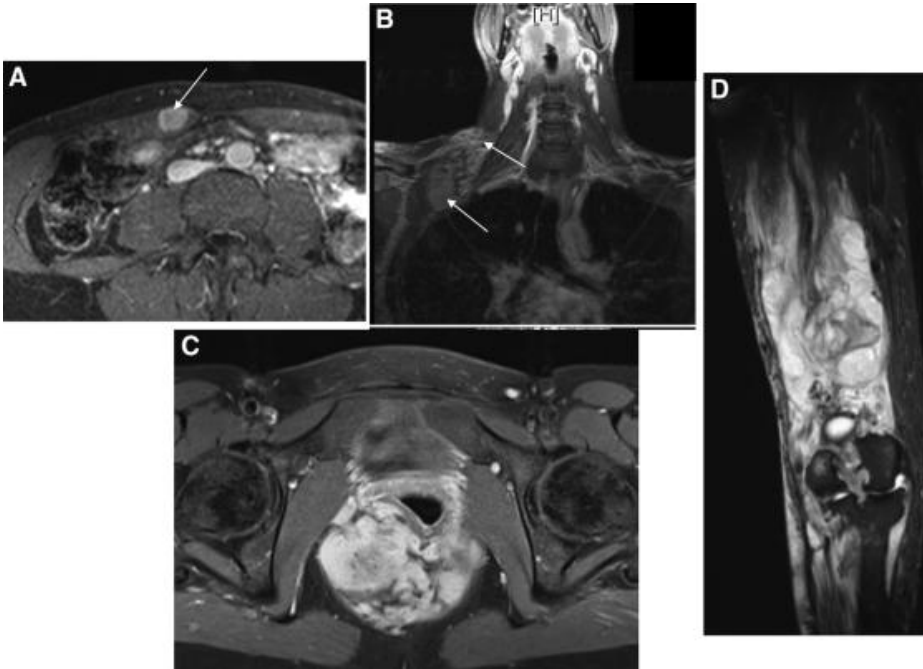


Fig. 1

- (A) Pregnancy-related **desmoid located in Rectus abdominis muscle**
- (B) Multiple external **desmoid achieving above the leg to the popliteal depression** in the person struggling from with a predisposing condition
- (C) Desmoid seen in lower pelvis, preventing vaginal delivery
- (D) External, desmoid located cranium and cervical vertebrae place down to the superior chest wall and plexus of brachial.

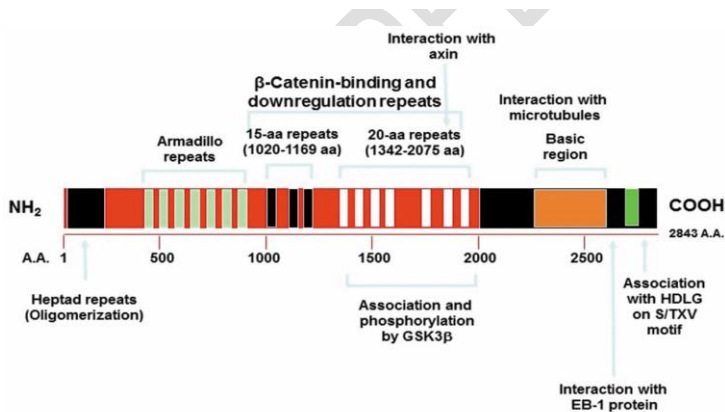
Segregation seen in undifferentiated cancerous tumour: At times, several **tumourss** like plastic cancer, lymphoma, melanoma, sarcoma are hard to **diferentiate** with regular H n E marking due to the fact of bad differentiation. So, immunochemical reactants may assist the diagnosis

example

- **Occarance** of cytokeratin factors to epithelial cancer.
- **occurrence in Desmin** if precise for muscle cell origin.
- **occurrence of WBC** usual Antigen factors of lymph node tumours

2. . Searching of place of starting place of cancerous tumours: marker are available that are factor of the entry of tumours located in the biological sample in the metastasis. Eg. consist in prostate cancer and cancer of the thyroid.[11]

1. Prognostic or clinical significance Estrogen or **estrediol** site detection is clinical fee in breast cancers. Positive marked breast cancers are inclined to anti-estrogen therapy. Congruently, over-use in erb-B2 gene signs to the terrible diagnosis



## **Fig. 2 Pathogenesis**

### **HTLV-1**

the RNA cancerous virus that is transferred through way of RBCs and plasma , **tranfusion** and breast feeding. There is enchantment of CD4 T cells . HTLV-1 consists of a protien TAX. A AtX gene Q leads to

1. **Tranlation** in human genes concerned in growth or segregation in B-tissus (F.O.S., Interleukin two genes)
2. **hereditary** weakness with the useful resource of inhibiting DNA restore function and by the means of using inhibiting **cell cell** cycle checkpoints activated with the resource of DNA damage These make contributions to increased possibilities of most cancers through potential of capability of HTLV-1 .

### **H.C.V .**

Heepatitis C virus is additionally highly related from an improvement of hepatocellular cancer. it canbe related to the potential of purpose persistent liver tissue damage and contamination that is accompanied with the beneficial aid of liver **resusitation** . Meiotically lively liver cells, covered thru a other environment, is most probable susceptible to hereditary stability is lost and most cancers development(**change the composition**)

### **HBV**

the encoding of B protein seems the disturb normal increase use of contaminated hepatocytes via turning on for a number of some vital genes. Hex again motives suppress the tumour suppressor gene ie p53.the consequences in B leading to liver cell carcinoma.

### **Differential Diagnosis**

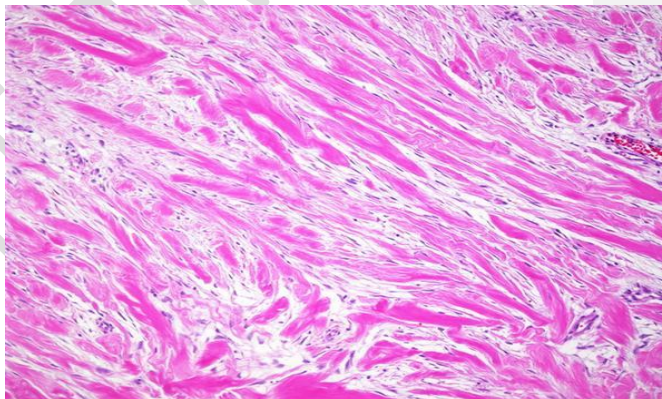
**The distinguishible prognosis in desmoid-kind of fibrosis of large,in fibrotic cancers in tone of the extremis** and relative fibrotic and myofibroblast figures for example nodular fasciitis and also hyper - trophic marks and keloids in other places. The remark would

possibly a choice from a band of people. The increase sample of the tumours is very severe ,  
tumour capsule are absent . Due to **the bourders** in the tumours **ais tough to Difficult**  
**inside** the tumour from wounds and cells , the R0 intersection is no longer continually  
plausible and **adjacent radiaton** is consequently regularly utilized following the cancer  
procedures.

### Extra Abdominal Fibromatosis

Fibrotic sarcoma is positive result seen of  $\beta$ -catenin staining , but is normally greater  
cellular, has greater cases of atypia, also the spindle cells exhibit a herring- bone like  
pattern.

Low grade fibro myxoid sarcoma  
may be reliably marked out by means  
of detection of unique translocations  
which involve FUS-CREB3L2 gene.  
Gardner **fibrenoma** is a uncommon  
neoplasm in men and women having  
diseases in the intestinal cocci gene,  
A.P.C.,in the greater arm of  
chromosome 5 **thich take place on**  
**the same pplaces**. There is a greater



chance of fibrosis in the cases of the tropical area in the people staying in the humid and  
moist atmosphere. The stromal cells, like these of desimoid tumours, the transcriptional role  
of  $\beta$ -catenin is considered crucial. The  $\beta$ -catenin phosphorylation is mediated by means of a  
component of the protein encoded by using exon three of CTNB1, the gene encoding  $\beta$ -  
catenin.

Fig. 3. Abdominal Fibromatosis

Both lesions exhibit nuclear expression of  $\beta$ -catenin in a massive percentage . In contrast to desmoid-type **fibrenoma , Gardner fibrenoma** indicates much less cellularity and a larger amount of collagen, and the spindle cells categorical CD34.

Low-grade fibro myxoid sarcoma presents more small and fragile **orgeneIII usually have the typical structure of curvilinear vessel walls.  $\beta$ -catnin resuly is positivly** in thirty per cent people. radioactive -related morbidity and mistakes, radioactive treatment must be avoided in cases of negative tumour margins, except for patients with large desmoids with difficulty **continueinf cases** of revival According to decreased use of limited therapeutic trails, mainly very debate regarding the **(full stop missing)**appropriate administration of systemic therapy for advanced disease. Medical therapy, consisting antihormonal therapy and also NSAIDs, looks to be useful with relative harness.



#### Intra-Abdominal Fibrosis

Some differential assessment of intra-abdominal fibrosis consists gastrointestinal stromal tumour , solitary fibrosis tumour (SFT), inflammatory myofibroblast tumour (I.M.T.), sclerosing mesenteritis, and retroperitoneal fibrosis (maybe necrotic [Orimond condition]and side effect to some capsules or an hidden cancer , like a lymph tumour).

Desmoid tumours with respect to WHO are described as “clonal fibrotic growths that origin in a inner hard cells and are characterised with the resource of infiltrative boom and a regional revival as an incapacity to spread ” Desmoid tumours per chance have an effect on all sites, which include the arms legs , **abdomins** etc. Just 9% of spreading **desimoid** tumours **is inside the abdomen**, 70% of sufferers by **hereditary adematous polyposis (.H.A.P.)-related desimoid tumours enhance intraabdominal condition. An occurance** is clean cell cancers and about 1.12% every cancerous.

nowadays the presence of **abdomin based desimoids** with GSTs were once shown

### Function Of Beta-Catenin

The molecule  $\beta$ -catenin is given two roles **cutaneous** cells, living as small sticking molecule or additionally phase in the translation tools in the nucleus. The stromal cells, like these of **desimoid tumours**, the transcriptional role of  $\beta$ -catenin is considered crucial. The  $\beta$ -catenin phosphorylation is mediated by means of a component of the protein encoded by using exon three of CTNB1, the gene encoding  $\beta$ -catenin.

Surgery is usually has been the clinical way for main respectable, **small size desimid tumour peoples** . **on the other hand due the changes of the therapeutic doses also the importannce of place of disease, theuse and application of therapeutics procedures has been intently** discussed.

On some patients, in co-existence in germline and somatic changes A.P.C.of the **desimoid** tumours have presented. Changes of RAAS genes and p53 gene are typically not observed **in deismoids**, for this reason inactivation of each copies in the A.P.C. PROTIEN is concerned on some improvement **of desimoid tumours**.

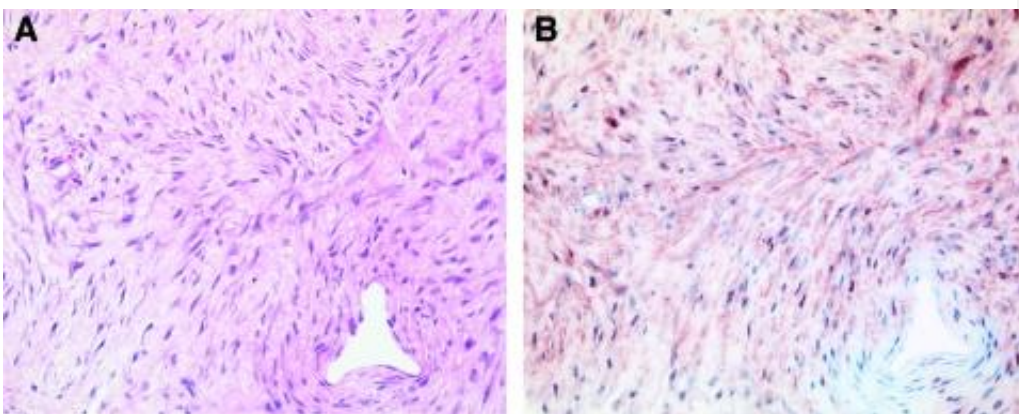


Fig. 4. Histopathology

## Therapy methods

Surgery is usually has been the clinical way for main respectable, small **size desimoid** tumour peoples . on the other hand due the changes of the therapeutic doses also the **importance of place of disease, theuse and application of therapeutics procedures has been intently discussed.The use of the micro condioton of tumour boundries is greaterly complicated . Few big alternative researches found that microscopically positive margins were clearer of a largeer recurence speed.**

No data is found from any company testings “**tumour-rectomy**” having approval **boundry cuts in seroius tumour removal targeted for R0 divison . hepatocellular cancer. it canbe** related to the potential of purpose persistent liver tissue damage and contamination that is accompanied with the beneficial aid of liver **resusitation** . Meiotically lively liver cells, covered thru a other environment, is most probable susceptible to **heriditary** stability is lost and most cancers development

## Radiotherapy

The Radiotherapy was applied in the controlled conditions post surgery and in the local conditions and for extra-abdominal tumours.

Patients with positive margins after surgery, the relapse rate dropped from 70% to 15% when radiation therapy was added after operation. The result was noted for both primary and recurrent **desimoids** tumours

## Therapy Methods for Advance Stages

Antihormonal therapy in therapy of **desmoid** tumours is made over findings **of reallnatyre** of the condition . Certain observations, for example, higher incidences of desmoids during and after pregnancy and reports of spontaneous tumour regression after menopause, form the basis for antihormonal therapy. Studies have shown that virtually all desmoid tumours express nuclear estrogen site- $\beta$ , but only a small subset of patients respond to antihormonal therapies.

The use NSAIDs for excessive fibrosis **usalyy applied on the surprising observation of toital decrease of one desi moid tumour in the breastbone of the person having indo-methacin** of radioactive –caused disease. Desmoid tumours is a rare monoclonal, fibrotic boom which is characterized by means of way of a variable and conventional scientific course. Desmoids are invasive and related with a excessive close by **recurrnce rate, do no longer have cancerous activity. Desmoids aare identified with the useful resource of changes occures of  $\beta$ -catenin gene A.P.C..Due to cob play a part in the detction of desimoid** tumours, therapy with NSAIDs that inhibit COX perhaps be effective. Moreover, NSAIDs shows on the  $\beta$ -catnin process

Locoregional chemotherapy in a way of different leg or arm perfusion is other way of overall chemotherapy in patients with limb desmoids, which is particularly interesting if one considers that desmoid tumours **unusal form of cancer . Methphalan and treptophan** tumour **apoptiosis gene -ais engaged as clinical agents along withtotal reactive forms of almost 70 . Alternately , intratumoural more vessesl** disappears on more transfer rather rapidly; however, it perhaps take several weeks to months until a partial or complete response formed . This technique looks to be very helpful for patients with small progressive or extreme **tumours notused** to operations.

## Summarization

**Desimoid tumour are a unusual and hereditary** disease which for sure requires personal therapy to **decrease therisk for small tumour** .

Targets for personalized therapy **must consists decreasing mortality** and loss of function and preserving patient life. Several things in the correct therapy of patients with desmoid tumours remain **debateful on the other hand adequate surgical dissection from negative boundries is the treatment of favor** except when surgery is mutilating and related with major loss of function or major morbidity. With people having , after operation chemo therapy is indicated and greatly decreases the small rate.[12-13]

Due to radioactive -related morbidity and mistakes, radioactive treatment must be avoided in cases of negative tumour margins, except for patients with large desmoids with difficulty **continueinf** cases of revival. According to decreased use of limited therapeutic trails, mainly very debate regarding the appropriate administration of systemic therapy for advanced disease. Medical therapy, consisting antihormonal therapy and also NSAIDs, looks to be useful with relative harness.

#### Conclusion

Desmoid tumours is a rare monoclonal, fibrotic boom which is characterized by means of way of a variable and conventional scientific course. Desmoids are invasive and related with a excessive close by **recurrence rate, do no longer have cancerous activity.**Several things in the correct therapy of patients with desmoid tumours remain **debateful** on the other hand adequate surgical dissection from negative **boundries is the treatment of favor** except when surgery is mutilating and related with major loss of function or major morbidity.

#### **COMPETING INTERESTS DISCLAIMER:**

Authors have declared that no competing interests exist. The products used for this research are commonly and predominantly use products in our area of research and country. There is absolutely no conflict of interest between the authors and producers of the products because we do not intend to use these products as an avenue for any litigation but for the advancement of knowledge. Also, the research was not funded by the producing company rather it was funded by personal efforts of the authors.

#### REFERENCES

1. Biermann JS. Desmoid tumourss. Curr Treat

Options Oncol. 2000;1:262-266. [PubMed]

2. Seegenschmiedt MH German **(space is empty)**

Cooperative Group on Radiotherapy for  
Nonharmful Diseases. Radiation therapy for  
aggressive fibromatosis (desmoid tumours):  
Results of a national Patterns of Care Study.  
Int J Radiat Oncol Biol Phys. 2005;61:882–891.  
[PubMed]

3. Bertario L, Russo A, Sala P, et al. **(space empty)**

Hereditary Colorectal Tumours Registry.  
Multiple approaches to the exploration of  
genotype-phenotype correlations in familial  
adenomatous polyposis. J Clin Oncol.  
2003;21:1698–1707. [PubMed]

4. Clark SK, Phillips RK. Desmoids in familial **space empty**

adenomatous polyposis. Br J Surg.  
1996;83:1494-1504.

5. Janinis J, Patriki M, Vini L, et al. The pharmacological treatment of aggressive  
fibromatosis: A systematic review. Ann Oncol. 2003;14:181–190.

6. Pignatti G, Barbanti-Bròdano G, Ferrari D, et al. Extraabdominal desmoid tumor. A study  
of 83 cases. Clin Orthop Relat Res. 2000;(375):207–213.

7. Knudsen AL, Bülow S. Desmoid tumour in familial adenomatous polyposis. A review of literature. *Fam Cancer*. 2001;1:111–119. [
8. Casali PG, Blay JY ESMO/CONTICANET/EUROBONET Consensus Panel of Experts. Soft tissue sarcomas: ESMO clinical practice guidelines for diagnosis, treatment and follow-up. *Ann Oncol*. 2010;21(suppl 5):v198–v203.
9. Okuno S. The enigma of desmoid tumors. *Curr Treat Options Oncol*. 2006;7:438–443. [
10. Stoeckle E, Coindre JM, Longy M, et al. A critical analysis of treatment strategies in desmoid tumours: A review of a series of 106 cases. *Eur J Surg Oncol*. 2009;35:129–134.
11. Carlson JW, Fletcher CD. Immunohistochemistry for beta-catenin in the differential diagnosis of spindle cell lesions: Analysis of a series and review of the literature. *Histopathology*. 2007;51:509–514.
12. Jaiswal NK, Kediya A, Makrande J. Desmoid Tumour - A Rare Entity. **JOURNAL OF EVOLUTION OF MEDICAL AND DENTAL SCIENCES-JEMDS**. 2021 Jan 18;10(3):170–2.
13. Varma AD, Dhande RP, Pattabiraman S. Abdominal Wall Desmoid Tumour Diagnosis on CT Scan-A Case Report. **JOURNAL OF EVOLUTION OF MEDICAL AND DENTAL SCIENCES-JEMDS(??? All capitals)**. 2021 Jan 18;10(3):153–5.