

Study Protocol

Comparison of The Effect of Triclosan Coated Polyglactin Sutures and Plain Polyglactin Sutures On Post-operative Healing In Patients Undergoing Surgical Removal Of Mandibular Third Molar (MTM)

Abstract:

Background- Surgical site infection (SSI) has been ruled out as having the highest prevalence among infections associated with avoidable health care. The application of coatings and other treatments to medical devices to avoid bacterial colonisation has gotten a lot of press recently. Bacterial growth should be prevented rather than treated because once bacteria have formed a habitat, they form a biofilm that prevents antibiotics from penetrating the infection site. As a result, it would be necessary to incorporate an antimicrobial agent into medical devices.

Objectives- The study's main goal is to see how successful, Triclosan Coated polyglactin suture as a wound closure agent in terms of surgical site infection after surgery, bacterial colonization, trismus and pain over the plain conventional one.

Methodology- Two groups (Group-I & Group-II) with 15 individuals as subjects are considered for the study model. Systemically healthy individual with presence of mandibular third molar (MTM) with similar difficulty index, depth of, and relationship with ramus will be included in the study sample. Wound closure would be achieved by using antimicrobial triclosan-impregnated 3-0 polyglactin sutures for closing the surgical site using simple interrupted sutures (Group-I) and plain 3-0 polyglactin sutures for closing the surgical using simple interrupted sutures (Group-II), respectively. Post-operatively measurement of surgical site infection, bacterial colonization, trismus and pain will be done.

Expected Results- Polyglactin sutures coated with triclosan for closure of wound after MTM surgery, will be successful in minimising post-operative surgical site infection, bacterial colonization, trismus and pain.

Conclusion- Use of polyglactin sutures coated with triclosan, aids in the prevention of one of the most prevalent postoperative conditions, surgical site infection (SSI) and to reduce bacterial colonization, trismus and pain. The surgeon's and the patient's need for a positive cosmetic outcome postoperatively is hampered if a postoperative surgical site infection develops, which one can be overcome by their usage.

Keywords- Triclosan Coated Polyglactin Suture, Third Molar, Surgical Site Infection, Plain Polyglactin Suture.

Introduction:

Mandibular third molar impactions are prevalent worldwide and frequently encountered in daily clinical practice.¹ Irrespective of its status of impaction, complete or partial, it has been well acknowledged that these ~~are~~ may be associated with several complications, including, regional pain, pericoronitis, distal caries, odontogenic abscess, trismus, cysts and tumors. So, early removal of these teeth to prevent complications is a widely accepted practice. The surgical retrieval of an impacted mandibular third molar, produces a significant degree of insult to the investing soft tissue and bony structures surrounding the tooth resulting in significant inflammatory reaction.² Consequently, it is associated with local sequelae and complications, like, pain, oedema, trismus and wound infection³ that adversely effects physical, psychological and functional wellbeing that bear direct repercussions over patient's quality of life.

Postoperative infection rate after impacted third molars (I3M) extraction is around 5%.⁴ SSIs are multifactorial in nature and related to patient characteristics such as age, gender, comorbidities such as diabetes, and immunosuppression all play a role. Many patient factors cannot be optimized, so the emphasis of research has been on surgical procedures. Suture material is one of these variables.⁵⁻⁷ As the suture material passes through the skin, bacteria colonise it, triggering SSIs by forming a biofilm, which produces resistance to antimicrobial agents and the host's immune system.^{8,9} There's a higher risk of an SSI once the biofilm is formed. Bacterial pathogens can colonize monofilament and braided sutures¹⁰⁻¹² for which, extensive work has been conducted on coating suture material with antimicrobials, including silver, since the 1950s.^{13,14}

Bacterial adhesion and proliferation should be limited with sutures used in oral surgery. Various permanent and temporary bacterial flora can be distinguished, the quantity of which is influenced by a variety of endogenous and exogenous influences among the bacteria responsible for both oral cavity physiology and pathology.^{15,16}

Triclosan (polychlorophenoxyphenol) is a bacteriostatic antiseptic ingredient has been used in toothpaste and soap for many years for its antiseptic properties and has a well-established safety profile.¹⁶ Triclosan has been approved by "the US Food and Drug Administration" in 2002 to coat the following sutures: "braided Vicryl Plus, Monocryl Plus, and PDS Plus". Triclosan works as a bactericide by targeting the cytoplasm of bacteria and cell membrane at higher concentrations.¹⁷ By binding to "enoyl-acylreductase (ENR)", a product of the "Fab I gene, and inhibiting fatty acid synthesis", many non-sporulating gram-positive and gram-negative bacterial species are inhibited at low concentrations.¹⁸⁻²⁰ "Irgacare MP", agents having a wide array of antiseptic properties that has been shown to be effective against these putative pathogens without causing resistance, it is the active ingredient in "coated polyglactin 910 suture with triclosan".²¹⁻²³

This study aims to see the efficacy of "triclosan-coated polyglactin braided sutures" to prevent surgical site infection. The hypothesis states that usage of triclosan coated polyglactin sutures reduces post-operative complications such as surgical site infection, bacterial colonization, erythema, trismus and pain after surgical extraction of mandibular third molar(MTM).

Objectives:

- 1) "To Evaluate the efficacy of triclosan coated polyglactin sutures in terms of postoperative pain, healing, surgical site infection and bacterial colonization around suture material in patients undergoing surgical removal of mandibular third molar".
- 2) "To Evaluate the efficacy of plain polyglactin sutures in terms of postoperative pain, healing, surgical site infection and bacterial colonization around suture material in patients undergoing surgical removal of mandibular third molar".
- 3) "To Compare the efficacy of triclosan coated polyglactin sutures vs plain polyglactin sutures in terms of postoperative pain, healing, surgical site infection and bacterial colonization around suture material in patients undergoing surgical removal of mandibular third molar".

Study setting:

Study Design: Prospective, Randomized control, double blind, and parallel arm study model

Eligibility criteria:

Inclusion Criteria:

- 1) Patients with ASA Grade I status
- 2) Patients between 16-50 years of age undergoing surgical removal of mandibular third molars.
- 3) Patients who understand the pain scale and respond immediately.

Exclusion criteria:

- 1) Patients with systemic diseases such as HTN, DM, blood dyscrasias, immuno-compromised status.
- 2) Patients who have history of antibiotics, for any head and neck infections or upper respiratory tract infections (penicillin/cephalosporin) over a period of 2–3 weeks.
- 3) Patients who have previously been allergic to triclosan, beta-lactams, or cephalosporins.
- 4) Patients taking aspirin, NSAIDs, hormones, or cytotoxic medications, which can impact the course of the study and the healing of the surgical site.
- 5) Patients with poor oral hygiene and chronic smokers, chronic alcoholism
- 6) Pregnant and breast-feeding mothers.
- 7) Presence of any chronic facial pain on the side of intervention.
- 8) Radiologic evidence of Inferior alveolar canal approximation.
- 9) Patients lost to follow-up.

Methodology:

~~The This study design would be~~ a prospective randomized, controlled, double-blind, parallel arm study model for randomized control trials, evaluating 30 systemically healthy subjects with the presence of at least one mesio-angular or horizontal or vertically oriented MTM with similar difficulty index, depth of, and relationship with ramus will be included in the study sample. A detailed clinical evaluation using a proforma (Annexure III) tailor made to suit the needs of the study will be performed. All the subjects recruited in the study will be explained in detail about the study protocol, the material used, the possible adverse effects of the interventions and a written informed consent will be obtained (Annexure II).

The preoperative measurement such as, measurement of maximum inter-incisal mouth opening would be done using a vernier's caliper by an independent observer and compared to the values measured on POD 3rd and 7th. Study population would be randomized equally (n=15) into two different groups (group I & group II) using computer generated table of random numbers.

The neural blockade of the "inferior alveolar nerve(IAN), lingual nerve and the buccal nerve" ~~will be ere~~ performed with 2.5 ml solution of 2% Lignocaine mixed with 1:80,000 Adrenaline using the classical technique. Following subjective and objective confirmation of successful neural blockade, the surgical extraction of mandibular third molars will be done by giving Ward I incision in all patients. A sharp periosteal elevator ~~will be as~~ used to reflect full thickness buccal mucoperiosteal flap and osteotomy with odontotomy using bur and handpiece. Following tooth removal, curettage of the socket and irrigation ~~will was be~~ done and after achieving the haemostasis, wound closure would be achieved by using antimicrobial triclosan-impregnated 3-0 polyglactin sutures for closure of the surgical site in a simple interrupted fashion, study(Group-I) and 3-0 plain polyglactin sutures for surgical site closure using simple interrupted suturing technique for control(Group-II), respectively.

Three interrupted sutures ~~will was be~~ secured across the incision line, first suture will be placed just distal to the second molar followed by the other two sutures placed distally to the first one over the surgical site to close the incision line in both the groups secured by using surgeon's knot. Postoperatively, all the subjects would be prescribed Cap. Amoxicillin 500 mg thrice daily for five days, Tab. Aceclofenac 100 mg twice daily for five days and Tab. Pan 40mg once daily for five days.

On 7th Post- Operative day, One stitch from each operated side of one linear centimeter ~~will be as~~ removed in every patient. Each suture sample, obtained and analysed in a microbiology laboratory using three agar plates (Blood agar, Nutrient agar, and MacConkey's agar). For aerobic bacteria to culture, one plate of each sample will be "incubated for 24-48 h at 37°C under aerobic conditions".

A colony counter is used to count the colonies and measure the number of colony-forming units(CFUs), after the incubation time. The variations in bacterial colonisation between the two forms of suture material will be measured on POD 7th, and identification will be based on their morphological characteristics.

Incidence of wound infection and erythema is measured by the appearance of purulent discharge in the extraction socket, whether or not it is accompanied by pain or swelling, will be assessed on POD 3rd & 7th using Landry Healing index.

Measurement of mouth opening is taken before and after surgery using a vernier caliper and assessed on 3rd & 7th day postoperatively.

Post-operative pain will be evaluated post-operatively on POD 3rd & 7th by using a "Visual Analogue Scale (VAS)". On a 10-point scale, patients are asked to rate their pain severity. Six faces with smiles will be shown on the scale.

Outcomes:

During the course of the procedure the following parameters will be assessed:

- Incidence of wound infection and erythema
- Bacterial count by assessing colony forming bacteria on various Agar medias
- Post-Operative Pain and trismus Measurement

- The emergence of infection during the study period is the primary efficacy indicator.
- The secondary outcome measures the post-operative pain and trismus.

1)Incidence of wound infection and Erythema: -

Appearance of purulent discharge in the extraction socket, whether or not it is accompanied by pain or swelling, will be assessed on POD 3rd & 7th using Landry Healing index.

(Table-1)

Healing index by Landry et al.

Healing index score	Clinical findings
Very poor	Tissue color: $\geq 50\%$ of gingiva red Response to palpation: Bleeding Granulation tissue: Present Incision margin: Not epithelialized, with loss of epithelium beyond incision margin Suppuration: Present
Poor	Tissue color: $\geq 50\%$ of gingiva red, Response to palpation: Bleeding Granulation tissue: Present Incision margin: Not epithelialized, with connective tissue exposed.
Good	Tissue colour: $\geq 25\%$ and $< 50\%$ of gingiva red, Response to palpation: No bleeding Granulation tissue: None
Very Good	Tissue colour: $< 25\%$ of gingiva red, Response to palpation: No bleeding Granulation tissue: None
Excellent	Tissue colour: All tissue pink, Response to palpation: No bleeding Granulation tissue: None, Incision margin: No connective tissue exposed

2)Bacterial Colonization:

A colony counter is used to count the colonies and to measure the number of colony-forming units (CFUs), after the incubation period. The variations in bacterial colonization between the two forms of suture material will be measured on POD 7th, and identification will be based on their morphological characteristics.

- Mean counts of the isolated bacterial species in both suture materials 7 days after the surgery.

BACTERIA(DAY7)	TRICLOSAN COATED POLYGLATIN SUTURE	PLAIN POLYGLATIN SUTURE	REDUCTION %
Streptococcus viridans			
Actinomyces odontolyticus			
Staphylococcus coagulase Neg.			
Citrobacter freundii complex			
Prevotella disiens			
Neisseria spp.			

3) Post-Operative Severity of Trismus-

Measurement of mouth opening is taken before and after surgery using a vernier caliper and assessed on 3rd & 7th day postoperatively.

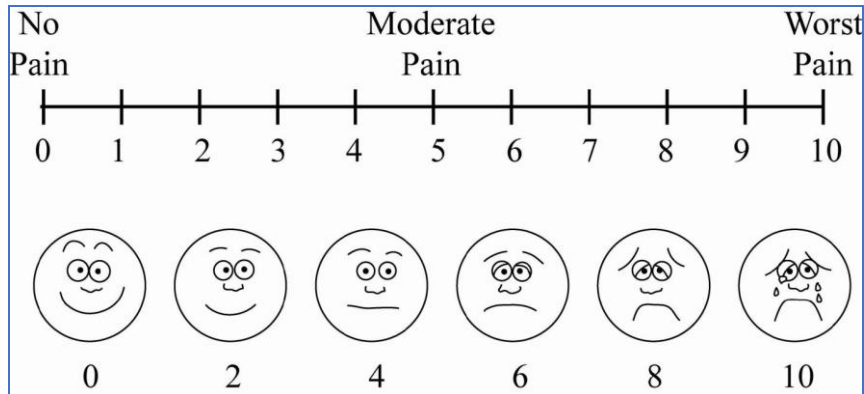
BEFORE SURGERY	AFTER SURGERY Evaluation on POD 3 rd	AFTER SURGERY Evaluation on POD 7 th

4) Post-Operative Pain Measurement- Evaluated on 3rd & 7th day post-operatively, using a “Visual Analogue Scale (VAS)”. On a 10-point scale, patients are asked to rate their pain severity. Six faces with smiles will be shown on the scale.

- 0(No pain).
- 2-3(Mild pain).
- 4-6(Moderate pain).
- 7-9(Severe pain) to score.
- 10(Very Severe excruciating pain).

0(No pain).	
2-3(Mild pain).	
4-6(Moderate pain).	
7-9(Severe pain) to score	
10(Very Severe excruciating pain)	

If the patient is experiencing pain, then he/she can take analgesic and time will be recorded accordingly.



Participant timeline:

Study duration: October 2020 to May 2022

“The study is scheduled to be conducted at “Department of Oral and Maxillofacial Surgery”, “Sharad Pawar Dental College and Hospital Sawangi” (Meghe), Wardha.

Statistical Analysis :

“Statistical analysis will be done by using descriptive and inferential statistics using chi-square test, Student’s paired and unpaired t test, software used in the analysis will be SPSS 24.0 version and Graph Pad Prism 7.0 version and $p < 0.05$ will be considered as level of significance”.

Methods: Assignment of interventions (for controlled trials):

Allocation: Study population would be randomized equally ($n=15$) into two different groups (group I & group II) using computer generated table of random numbers.

Implementation: Independent observer

Blinding (masking): Double- blind study (trial participants and data analysts).

Data collection, management, and analysis methods:

Data collection methods: Patients reporting to OPD of Oral and Maxillofacial Surgery department, Sharad Pawar Dental College, Sawangi(M).

Ethics and dissemination:

“The study is approved from institutional ethical committee, Sharad Pawar Dental College, [Ref. No- DMIMS(DU)/IEC/2020-21/97].”

Declaration:

“The study procedure described in the study would be conducted in accordance with the ethical standards of the institutional research committee and with the 1964 Helsinki declaration and its later amendments or comparable ethical standards.”

Expected Outcomes/Results: Polyglactin sutures coated with triclosan for closure of wound after MTM surgery, will be successful in minimising post-operative surgical site infection, bacterial colonization, trismus and pain.

Discussion:

In everyday clinical dental practice, impacted third molars (LI3M) are common^{24,25}. Clinically, these manifest as pain, swelling, trismus, and bleeding. It has a negative impact on an individual's physical, psychological, and practical well-being, as well as direct consequences for postoperative quality of life.^{26,27} HENRI R. FORD et al Conducted a study to “Coated polyglactin 910 suture with triclosan” was recently developed to imbibe the parent suture, “coated polyglactin 910, with antibacterial” action against the most common pathogens that cause wound infections (SSI). The secondary endpoints included, specific intraoperative suture handling procedures and wound healing measurements. The suture handling procedures were” (1) easy passage through tissue; (2) first-throw knot holding; (3) smoothness of knot tie-downs ; (4) Security of knot; (5) surgical handling of sutures ; (6) surgeon's hand; (7) Suture memory; and (8) fraying of sutures”²⁸⁻³⁰. Measurement of wound healing included the following: Infection, edema, erythema, skin temperature, seroma, suture sinus, and inflammation are also signs of healing. Wound healing characteristics were comparable for both sutures except for pain on POD 1st. They speculate that by inhibiting bacterial invasion of the suture, the polyglactin 910 suture with triclosan reduced discomfort, which may be a sign of “subclinical” infection. Manisha Aggarwal et al Conducted a study which showed surgical site infection (SSI) having the highest prevalence of infections linked to avoidable health care. Surgery for perforation peritonitis carries an exceptionally high risk of SSI. Triclosan-coated sutures gradually release triclosan, an antibacterial agent that prevents bacterial invasion of the suture and wound site, thus preventing SSI. Fifty patients with perforation peritonitis undergoing surgery were randomized in two groups. The signs and symptoms of wound infection, i.e. swelling, erythema, warmth, discharge and wound dehiscence were significantly less in Triclosan coated (TC) group (p=0.01) though the difference in pain at wound site was insignificant in both the groups. The incidence of surgical site infection (p=0.000156) and consequent hospital stay (p=0.0466) was significantly low in the TC group. Triclosan coated suture undoubtedly aids in the prevention of one of the most suspected postoperative risks, including surgical site infection, which not only increases the patient's morbidity but also has long-term consequences.

WITOLD BOJAR et al evaluated the bactericidal properties of the triclosan coated materials by conducting a research with a aim of identifying the microbes brooding on the “triclosan coated polyglycolic–acid braided suture material” used intra orally. The materials were mounted on the media inoculated with micro-organisms retrieved with the patients in the first visit. The sutures were first rinsed in normal saline solution for 24 hours in the second visit. After 48 hours, growth inhibition zones were assessed. The number of colonies and microbe organisms isolated from triclosan-coated and uncoated material did not vary significantly. Streptococci growth inhibition was only detected with unrinsed triclosan-coated content and did not reach 2 mm. Only the control strain E. coli ATCC 25922 had a greater zone of inhibition of up to 20 mm for both unrinsed and rinsed content. In the absence of proven variations in colonisation and bactericidal properties between triclosan-coated sutures and normal multifilament sutures, the surgeon's preference for suture material should be simplicity over bacterial adherence.

Conclusion:

Use of “polyglactin sutures coated with triclosan”, aids in the prevention of one of the most prevalent postoperative conditions, surgical site infection (SSI) and to reduce bacterial colonization, trismus and pain. The surgeon's and the patient's need for a positive cosmetic outcome postoperatively is hampered if a postoperative surgical site infection develops, which one can be overcome by their usage.

References:

1. Magill SS, Edwards JR, Bamberg W, et al. Multistate point prevalence survey of health care-associated infections. *N Engl J Med* 2014;370:1198–208.
2. Mattavelli I, Rebori P, Doglietto G, et al. Multi-Center randomized controlled trial on the effect of triclosan-coated sutures on surgical site infection after colorectal surgery. *Surg Infect* 2015;16:226–35.
3. Leaper DJ. Surgical-Site infection. *Br J Surg* 2010;97:1601–2.
4. Hranjec T, Swenson BR, Sawyer RG. Surgical site infection prevention: how we do it. *Surg Infect* 2010;11:289–94.
5. Diener MK, Knebel P, Kieser M, et al. Effectiveness of triclosan-coated PDS plus versus uncoated PDS II sutures for prevention of surgical site infection after abdominal wall closure: the randomised controlled PROUD trial. *Lancet* 2014;384:142–52.
6. Neumayer L, Hosokawa P, Itani K, et al. Multivariable predictors of postoperative surgical site infection after general and vascular surgery: results from the patient safety in surgery study. *J Am Coll Surg* 2007;204:1178–87.
7. Malone DL, Genuit T, Tracy JK, et al. Surgical site infections: reanalysis of risk factors. *J Surg Res* 2002;103:89–95.
8. Cheadle WG. Risk factors for surgical site infection. *Surg Infect* 2006;7(Suppl 1):s7–11.
9. Gristina AG, Price JL, Hobgood CD, et al. Bacterial colonization of percutaneous sutures. *Surgery* 1985;98:12–19.
10. Chang WK, Srinivasa S, Morton R, et al. Triclosan-impregnated sutures to decrease surgical site infections: systematic review and meta-analysis of randomized trials. *Ann Surg* 2012;255:854–9.
11. Kathju S, Nistico L, Hall-Stoodley L, et al. Chronic surgical site infection due to suture-associated polymicrobial biofilm. *Surg Infect* 2009;10:457–61.
12. Kathju S, Nistico L, Lasko L-A, et al. Bacterial biofilm on monofilament suture and porcine xenograft after inguinal herniorrhaphy. *FEMS Immunol Med Microbiol* 2010;59:405–9.
13. Kathju S, Nistico L, Tower I, et al. Bacterial biofilms on implanted suture material are a cause of surgical site infection. *Surg Infect* 2014;15:592–600.
14. Darouiche RO, Meade R, Mansouri M, et al. In vivo efficacy of antimicrobial-coated fabric from prosthetic heart valve sewing rings. *J Heart Valve Dis* 1998;7:639–46.
15. Blaker JJ, Nazhat SN, Boccaccini AR. Development and characterisation of silver-doped bioactive glass-coated sutures for tissue engineering and wound healing applications. *Biomaterials* 2004;25:1319–29.
16. Ford HR, Jones P, Gaines B, Reblock K, Simpkins DL. Intraoperative handling and wound healing: controlled clinical trial comparing coated Vicryl (R) Plus antibacterial

- suture (coated polyglactin 910 suture with triclosan)with Vicryl (R) suture (coated polyglactin 910 suture). *Surg Infect* 2005, 6, 3, 313–321.
17. Triclosan-Coated Sutures in Oral Surgery. Available from: https://www.researchgate.net/publication/234072699_Triclosan-Coated_Sutures_in_Oral_Surgery [accessed Mar 05 2021].
 18. Kurtz S, Ong K, Lau E, et al. Projections of primary and revision hip and knee arthroplasty in the United States from 2005 to 2030. *J Bone Joint Surg Am* 2007;89:780–5.
 19. Sala-Pérez S, López-Ramírez M, Quinteros-Borgarello M, et al. Antibacterial suture vs silk for the surgical removal of impacted lower third molars. A randomized clinical study. *Med Oral Patol Oral Cir Bucal* 2016; 21: e95–102.
 20. Bamber AI, Neal TJ. An assessment of triclosan susceptibility in methicillin-resistant and methicillin-sensitive *Staphylococcus aureus*. *J Hosp Infect* 1999; 41: 107–109.
 21. Zafar AB, Butler RC, Reese DJ, et al. Use of 0.3% triclosan (Bacti-Stat) to eradicate an outbreak of methicillin-resistant *Staphylococcus aureus* in a neonatal nursery. *Am J Infect Control* 1995; 23: 200–208.
 22. Webster J, Faoagali JL, Cartwright D. Elimination of methicillin-resistant *Staphylococcus aureus* from a neonatal intensive care unit after hand washing with triclosan. *J Paediatr Child Health* 1994; 30: 59–64.
 23. McMurry LM, Levy SB. Triclosan targets lipid synthesis. *Nature*. 1998;394:531–32.
 24. Levy CW, Roujeinikova A, Sedelnikova S, et al. Molecularbasis of Triclosan activity. *Nature*. 1999;398:383–84.
 25. Rothenburger S, Spangler D, Bhende S, et al. In-vitro antimicrobial evaluation of coated Vicryl Plus antibacterialsutures (coated Polyglactin 910 with Triclosan) using zone of inhibition assay. *Surg Infect* 2002; 3: S79–S87.
 26. Patil C, Jadhav A, K R, Bhola N, Borle RM, Mishra A. "Piezosurgery vs bur in impacted mandibular third molar surgery: Evaluation of postoperative sequelae". *J Oral Biol Craniofac Res*. 2019;9(3):259-262. doi:10.1016/j.jobcr.2019.06.007
 27. Reddy KV, Jadhav A, Bhola N, Mishra A, Dakshinkar P. Is 0.75% ropivacaine more efficacious than 2% lignocaine with 1:80,000 epinephrine for IANB in surgical extraction of impacted lower third molar? *Oral Maxillofac Surg*. 2019 Jun;23(2):225-231. doi: 10.1007/s10006-019-00779-w. Epub 2019 May 14. PMID: 31089895.
 28. Khan, Imran, Rajshekhar Halli, Pushkar Gadre, and Kiran S. Gadre. "Correlation of Panoramic Radiographs and Spiral CT Scan in the Preoperative Assessment of Intimacy of the Inferior Alveolar Canal to Impacted Mandibular Third Molars." *JOURNAL OF CRANIOFACIAL SURGERY* 22, no. 2 (March 2011): 566–70. <https://doi.org/10.1097/SCS.0b013e3182077ac4>.
 29. Oswal, Shrenik, Rajiv Borle, Nitin Bhola, Anendd Jadhav, Sanidhya Surana, and Rajesh Oswal. "Surgical Staples: A Superior Alternative to Sutures for Skin Closure After Neck Dissection-A Single-Blinded Prospective Randomized Clinical Study." *JOURNAL OF ORAL AND MAXILLOFACIAL SURGERY* 75, no. 12 (December 2017). <https://doi.org/10.1016/j.joms.2017.08.004>.
 30. Dakshinkar, P., R. Borle, N. Bhola, and A. Mishra. "Comparison of Poliglecaprone 25 (Monofilament) and Polyglactin 910 (Multifilament) Suture Material in Terms of Soft Tissue Healing of Surgical Wound after Cleft Alveolar Bone Grafting." *European Journal of Molecular and Clinical Medicine* 7, no. 2 (2020): 2091–97.

UNDER PEER REVIEW