

Root Canal Morphology of Mandibular First Premolars Using Radiography (In Vitro)

ABSTRACT

OBJECTIVE:

The purpose of this study was to use radiography to document the Root Canal morphology of the first mandibular premolars.

Introduction:

The occurrence of one root canal in the mandibular 1st premolar cannot be presumed constantly. The inconsistency in canal morphology of root canal comprises the figure & form of the canal as well as pathways of the canals.

MATERIAL AND METHODS:

The experiment was carried out in the LUMHS Operative Dentistry. Two hundred extracted permanent mandibular first premolars which fulfill all the inclusion criteria were obtained from collected from LUMHS Jamshoro/Hyderabad and surrounding private dentistry clinics of Hyderabad city. Teeth were cleared from all debris, attached soft tissues and calculus and were stored in 10% formalin solution. The length of each tooth was taken from the tip of the crown to the apex of the root. However, the dental examination of an extracted tooth was carried out from

all surfaces i.e buccal, lingual and proximal. Some root concavities and grooves were observed, as well as bifurcation or apical curvature.

RESULTS:

Comparison between two groups showed that in group A 189 (94.5%) teeth have 1 canal and 11 (5.5%) 2 canals and 186 (93%) showed 1 orifice and 14 (7%) 2 orifices on buccal surface Radiograph while in Group B Mesial Surface Radiograph showed 182 (91%) teeth have 1 canal and 18 (9%) have 2 canals and 179 (89.5%) showed orifice and 21 (12.5%) have 2 orifices.

CONCLUSION:

In the population of the city of Jamshoro, peak variants were observed of four root canals in the mandibular 1st premolar. It is to make root canal therapy successfully it has been determined that careful searching for function canal in lower 1st molar.

KEYWORDS: Mandibular 1st Premolar, Root Canal, Radiograph, Root Development

INTRODUCTION

A careful study and legitimate information of tooth morphology, life structures of roots and root canal framework, precise radio realistic assessment and continuous varieties from ordinary geometry are pivotal for the fruitful aftereffects of endodontic treatment(1, 2)

Neglecting to recognize the progressions from typical(3)i.e. neglecting to recognize the additional canal and by abandoning it untreated, the achievement of endodontic treatment gets to be traded off so creating mistakes inappropriate determination and treatment arranging.

Assortment in a number of roots, canals and apical foramina alongside changes in age, sexual orientation and ethnic contrasts are additionally considered included roots and root canal framework(4).

Slowey was of conclusion that the mandibular first premolar demonstrates a low achievement rate since this tooth may introduce the best trouble of all teeth(5).A study on radiographic premise done by Zillach and Dowson reported that 23.1% of mandibular first premolars demonstrated a few canals(6). Slowey in 1974 expressed that clinically extra canals might be found under the distal part of the pulp chamber yet are at some point discovered radiographically(7).As per Hoen and Pink the rate of untreated tooth canals or tooth roots that required retreatment was 42%(8). Lu TY and Yang in an investigation of 82 extricated mandibular first premolar teeth from various Chinese populations found that 54 % of teeth demonstrated a single canal, 22 % indicated two canals and 18% showed C-canals(9).

The investigation of mandibular first premolar teeth introduces an assortment of components. In the greater part of cases, a solitary canal is available however at times assortment in a number of roots and canals might be found which makes mistakes in endodontic treatment(10). The clinician ought to be surely understood the arrangement of pulp space of tooth that is to be dealt with by assessing buccolingual and mesiodistal radiography(11).So before the endodontic treatment is performed the investigation of the unique geometry of roots and root canal alongside the varieties is imperative and obligatory.

The motivation behind this study was to decide the exactness of radiographic assessment of root canal variety in mandibular 1st premolars in vitro in the neighborhood populace.

MATERIAL AND METHODS

SETTING:

This study was carried out in the Operative / Endodontic Department, LUMHSJamshoro

DURATION OF STUDY:

06 months after **acceptance of the synopsis.**

SAMPLE SIZE:

Using the WHO open resource calculator version of by KC LUN & PETER from the National University of Singapore, 200 teeth permanent mandibular first premolars were included.

STUDY DESIGN:

Observational study

SAMPLING TECHNIQUE:

Consecutive sampling has been applied non-probably.

SAMPLE SELECTION:

Inclusion Criteria:

Permanent mandibular first premolars with intact pulp chamber extracted for:

- Orthodontic treatment.
- Periodontal diseases.
- Periapical diseases.
- Extreme mobility

Exclusion Criteria:

- Grossly decayed or carious teeth.
- Fractured teeth (Teeth which has its external morphology)
- Teeth with has an incomplete formation of root
- Teeth consisting of full coverage restoration
- Root canal-treated teeth.

DATA COLLECTION:

200 extracted permanent mandibular first premolars falling in inclusion criteria were gathered at the maxillofacial Department Liaquat University hospital. No information was enrolled together about the purpose of extraction for all ages or gender. Teeth were cleared from all fragments, attached soft tissue and calculus were stored in 10% formalin solution.

The length of each tooth was taken from the tip of the crown to the apex of the root. There was careful examination of the buccal, lingual and proximal surface of each tooth. Some root concavities and grooves were observed, as well as bifurcation or apical curvature. Then the following steps were taken:

- Access cavities will be prepared with a diamond round bur 0.5mm in high-speed handpiece.
- Oval shape access cavity was prepared that was extended buccally to the tip of buccal cusp lingually upto lingual cusp inclination.
- 2.5 % of sodium hypochlorite solution was used to irrigate the pulp chamber
- The main canal was located with No. 10 K-file and the second canal was also be tried to locate/attempt with No. 8 or No. 10 file.

- The canals were prepared upto 25 No files and radiographs were taken from the buccolingual and proximal side after keeping files in each canal.
- Root canal morphology according to classification was noted in proforma.

DATA ANALYSIS:

Data was collected and analysis was done by SPSS Version 19, and Descriptive statistics were calculated in respect of mean (\pm SD). Whereas categorical variables were also computed frequency and percentages as appropriate. An appropriate chi-square test was implemented to verify the relationship for morphology identification if the frequency noticed to be less than five was added to the same Fisher Test. Finally, a p-value of less than 0.05 has been taken as Significance.

RESULTS

Out of 200 extracted teeth, 184 teeth shows 1 Canal and 1 orifice, 5 teeth 1 canal 2 orifices, 9 teeth 2 canal 2 orifices and 2 teeth 2 canals 1 orifice on buccal radiograph (**Table 1**). While on Mesial radiograph 176 teeth shows 1 canal 1 orifice, 6 teeth 1 canal and 2 orifices, 15 teeth 2 canal 2 orifices and 3 teeth shows 2 canal 1 orifice (**Table 2**). Comparison between both groups shows in Group-A 189 (94.5%) teeth have 1 Canal and 11 (5.5%) 2 Canals and 186 (93%) shows 1 orifice and 14(7%) 2 orifices on Buccal surface radiograph while in Group-B Mesial surface radiograph shows 182 (91%) have 1 canal and 18 (9%) have 2 canals and 179(89.5%) shows 1 orifice and 21(10.5%) 2 orifices. (**Table-3&4**).

TABLE-1

**NUMBER OF CANAL AND ORIFICES WITH BUCCAL SURFACE
RADIOGRAPH**

(n=200)

Group-A: Number of roots & Canals with Buccal surface radiograph		
No. of Teeth	No. of Canal	No. of Orifices
184 (92%)	1	1
5 (2.5%)	1	2
9(4.5%)	2	2
2(1%)	2	1

TABLE-2**NUMBER OF CANAL AND ORIFICES WITH MESIAL SURFACE RADIOGRAPH**

Group-B: Number of roots& Canals with Mesial surface Radiograph		
No. of Teeth	Canal	Orifices
176(88%)	1	1
6(3%)	1	2
15(7.5%)	2	2
3(1.5%)	2	1

TABLE-3**COMPARIONS OF NUMBER OF CANALS BETWEEN BOTH GROUPS OF THE STUDY PARTICIPANT**

No. of Canal	Group-A (Buccal radiograph)	Group-B (MesialRadiograph)
1 Canal	189 (94.5%)	182 (91%)
2 Canal	11 (5.5%)	18 (9%)

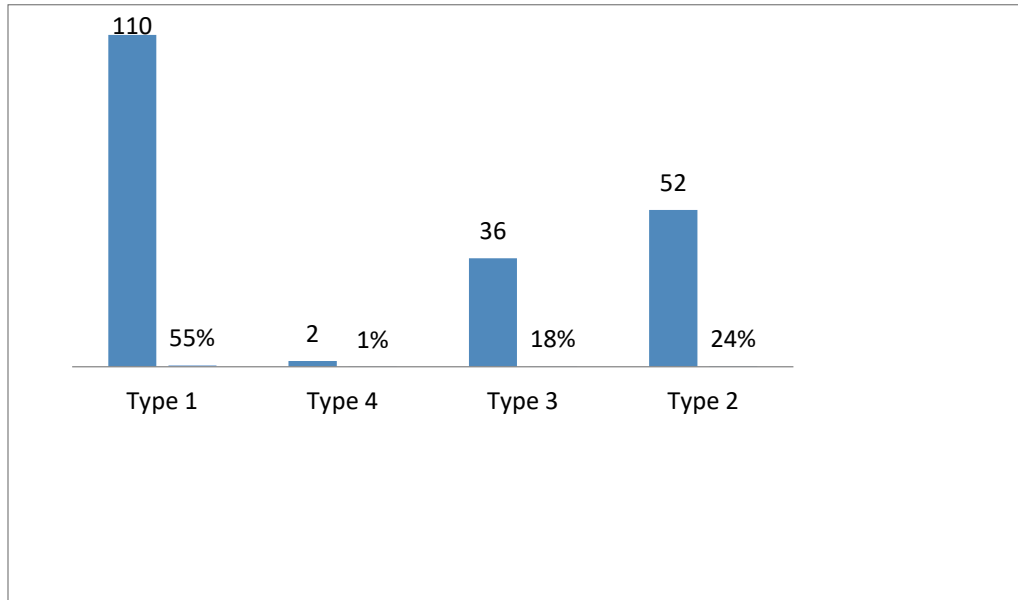
TABLE-4

COMPARISONS OF NUMBER OF ORIFICES BETWEEN BOTH GROUPS OF THE STUDY PARTICIPANT

No. of Orifices	Group-A (Buccal radiograph)	Group-B (MesialRadiograph)
1 Orifces	186 (93%)	179 (89.5%)
2 Orifices	14 (7%)	21 (10.5%)

FIGURE-1

WEINE'S CANAL MORPHOLOGY CLASSIFICATION



UNDER PEER REVIEW

DISCUSSION

The nearness of solitary transitional teeth between the molar & canine especially so in the mandibular 1st premolar can't remain accepted dependably. Inconsistency in vessel morphology of the point at which something begins the teeth were existence the numeral and state of the canal and additionally paths of the canal Mandibular premolars have been made responsible for multiplex anatomical divergence, causing them to be a standout amongst most problematic teeth to oversee in Endodontics. A few elements add to varieties seen in the root canals and roots that incorporate ethnicity and sex(12), in their anthropological survey, depicted the extra foundation of mandibular 1st premolars as Tome's root, which demonstrated a higher rate of exceeding Twenty Five Percent among conventional sub-Saharan African and Australians populaces. Opposingly, Western Eurasian American Arctic, Jomon, and New Guinea populaces had a less frequency of extra root (0% - 10%). This kind of anthropological information may give significant data with respect to the probability of an extra establish in mandibular premolars of particular race-related populaces. Consequently, the component of hereditary qualities ought to likewise not be under-evaluated in deciding anatomic varieties of human teeth. Various strategies have been utilized for concentrating on root canal life structures, including replication systems(13), ground segments(14), clearing procedures(15), and radiography(16).

Contrasts in the strategy for examination and information presentation could likewise add to a wrong impression of the rate of variable life systems. A radiograph is generally assessed for canal assessment before endodontic treatment. Be that as it may, canal preoccupation or sudden vanishing of the radiolucent canal couldn't be watched dependably on the radiograph.¹³⁵ Many past studies demonstrated a few strategies, for example, cross section¹³⁵ radiography¹³⁴ direct

perception with microscope(16) Presentation: Successful endodontic treatment is subject to immaculate information of ordinary root canal life systems and varieties as of the standard.

At that point, every one of the teeth was beautified at the bond lacquer intersection & resected opposite to their extensive tomahawks into 3 equivalent areas & recolored by fuscine. Computerized photos of the root surfaces were captured cross-sectionally at 40 amplification and reviewed.

For each premolar, the root canal design kinds were independently mined by radiographs and cross-sectional photographs. Careful information of the root canals life systems of teeth is crucial for the treatment of root canal and arrangements after Procedure. Minor Differences from the first straight root way can bring about a strategy

Just 7 out of 25 teeth (Twenty-Eight percent) consisting of 2 canals in cross separating showed 2 canals in MD radiographs, and MD radiography was Twenty-Eight percent capable in identifying premolars consisting of more than one canal Contrasted and cross segmented..What's more,What's more, the morphological kind of the root canals was not visible enough in BL X-Ray(16, 17).

Because the most common tooth upon which root canal therapy is done in the mandibular 1st molar which is also of great interest to endodontics. There have been a large number of studies conducted on mandibular 1st molar e.g Root canal morphology(18), Radix entomolaris(19), Middle distal canal(20) and mandibular first molar with three distal canals(21).

A study was conducted in the Taiwan population in China on the configuration of the root canals in the mandibular 1st molar on 100 lower whose roots have been treated 46% of the samples had canals number four and almost 10 out of 5 had distal roots which were extracted(22).The finding

of this analysis is similar to the study been done presently even though in this analysis how surgeon carried out root canal therapy. Whereas veteran clinicians performed the analysis in the other study. Joseh et al(23) and a number of other authors used computed tomography to perform the same analysis in the sample of teeth of the Indian population and in Vitro study. From the finding of the study, it was found that a large number of mandibular 1st molar (84.4%) had three roots canals morphology of 125 1st molars mandibular that has been extracted. From the study, it has been found that the assurance of 4th canals in mandibular 1st molars is relatively very low (13.52%) respectively. In contrast to our population, Wasti & co-authors carried out the study of root canals systems in the south Asian Pakistan population dealing with mandibular permanent molar teeth. Wasti(24) and others used a sample of 30 mandibular of 1st molars in their study from the finding it was determined that almost half 4-canals the accuracy of the 4th canals is similar to the occurrence in the current study but there is a difference in the size of a sample and the experience of the clinicians' Al Nazhan(25) performed a similar study on a subsection of the Saudi Arabi population using 251 roots canals as a sample that is been treated for permanent mandibular 1st molars. From the study, it was found that 58% had four canals and 42% had three root canals now 4th canals' accuracy is larger as compared to the present study group 40% respectively.

In a Chinese population Zillichand Dowson ' the prevalence of mandibular 1st premolars consisting of two or more channels increased from 13.7 percent among Chinese people to 46%(26).

The reason for this research was to evaluate the root trench life systems of mandibular 1st premolars among the Iranian populace on the grounds that ethnic and/or local inclinations

facilitate a lot inside the anatomical variety of this tooth furthermore In Iran this type of data was deficient.

One of the research showed, Four hundred and one teeth had been diaphanized to detect the design of multiplex root canal systems in a three-dimensional structure. We picked the portrayal of Vertucci(12) to bunch the arrangement of root waterway course of action of mandibular 1st premolar, results showed Type 1 [269 out of 401 teeth (967.08 percent)] was the most continuous anatomic arrangement. The most notable recurrence of Type 1 in the Colombian population is almost the same as those in an Indian population (72 percent and 70 percent)(27)and Caucasian populace(12) individually.Type 5 was found to be consistent in recorded outcomes in a (24 percent) second recurrence of Type 5 in 84 teeth (21.11 percent). Type 5 is associated with the reported findings of Type 5 second recurrence in the white population (24%) of 84 teeth (21.11%). Type 4 has been found in 4.27% of total samples i.e. 17 teeth that are uncommon in numerous articles, Vertucci 1.5% and Velmurugan 10%(23).

Type 3 has been observed among 3.77%, the same as Velmurugan (3%) and Vertucci (4%) reported.Type 7 was hardly 1.5%, and Vertucci and Velmurugan did not report this type. Type 8 in 5 teeth (1.26%) was available. This type is compared to Vertucci's (0.5 percent) studies. Type 6 was found in (1.01 percent) four teeth. Just 1 tooth (0.25%) was detected as Type 2(12, 23, 27).As to anatomical varieties, we have seen that there were anatomical variations of 152 teeth.The col-sidelong canals among 106 teeth (69.74 percent) were most incessant,Apical delta followed in thirty four teeth (22.32 percent) followed immediately by Apical delta in thirty-four teeth (22.32%), intermittent Canals in Twenty Three teeth (15.13 percent), between canal in Twenty Three teeth (15.13 percent), andThe canal was less common in Thirteen (13) teeth (8.55 percent), Horizontal channel in Eleventeeth (7.24 percent) and Two teeth (1.32 Percent) in the reticular canal. One and only tooth(0.66 percent) has shown a frill canal, which is quite compatible with the authors reported earlier(28, 29).

This research was designed to explore both radiography and cross-sectional approaches in Iranian Populace to scrutinize root canal life structures of mandibular 1st premolars.

Techniques: 200 Human mandibular premolar separated teeth were utilized. X-

Rays have been captured for each premolar in buccolingual as well as mesiodistal bearings. At that point,

at the bond lacquer intersection, each of the teeth is embellished and resected in three equal places opposite their long tomahawks and recolored with fuscine

Cross-sectional root surfaces were photographed digitally after that reviewed at an amplitude of

40. For each premolar, Root canal design Types were stop-minded independently through cross-sectional photographs and Radiographs.Careful knowledge about the teeth' root canal life processes is important for the treatment of root canal and post-room arrangement. Minor Differences from the first straight root way may bring about strategy. Just 7 out of 25 teeth (Twenty-Eight percent) consisting of 2 canals in cross separating showed 2 canals in MD

radiographs, and MD radiography was Twenty-Eight percent capable of identifying premolars consisting of more than one canal. Contrast and cross segmented. What's more, root canal morphology kind was not very obvious in BL radiographs. In this way, stupendous root canal life systems of mandibular 1st premolars may stow away on standard Direct or even measured radiography in clinical circumstances(13, 25).

For corroborative results in these cases, winding figured tomography (SCT) sweep was proposed in a tridimensional way. The tooth which is included is engaged and their morphology is divulged in 0.5-mm thick hub, sagittal transverse and segments, along with three-dimensional remade photos utilizing delicate dental materials. In this manner, SCT would have the capacity to introduce varying morphological compositions and interrelationships of root canals(14). In the current study, increased occurrence of type 5 teeth in the cross-segmentation of teeth with two canals relative to that of past examinations(15). As shown by this study's after-effects, 88.5% of the first mandibular premolars had a solitary canal. In no less than one cross-area of their roots, the remaining 11.5 percent indicated two canals. The checked teeth that had 2 canals in cross-areas had 5 root canal layouts For Instance: Type 2, Type 3, Type 4, Type 5 and C - form arrangements. Just 5.99% percent of premolars display 2 canals with 3 canals designs i.e: Type 2, Type 3 and Type 5 in the MD radio diagrams.

The achievement of root canal treatment is subject to a careful comprehension of typical root canals life systems and additionally varieties from the standard. Appropriate cleaning, molding, and how root canal framework is obturated tridimensionally relies upon understanding that how to use these data(30, 31). According to Pink and Hoen, the frequency of missing canals or establishes in teeth required for the retreat was 42 percent. Mandibular premolar teeth tend to drift out as exceptional from the regular anatomy. A vast variety of these teeth' root waterway life

processes makes them the toughest to administer fruitful endodontic medications. In different studies, there was more than one canal with a higher incidence of mandibular 1st premolars. The occurrence, area, and morphology of the teeth frameworks of the root canals may change in different racial or provincial populations(16, 17, 31, 32).

CONCLUSION

In the population of the city of Jamshoro, there is a high relevance of variation in root canals morphology in the mandibular 1st premolar. It is to make root canal therapy successfully it has been determined that careful searching for function canal in lower 1st premolar.

REFERENCES

1. Trope M, Elfenbein L, Tronstad L. Mandibular premolars with more than one root canal in different race groups. *J Endod.* 1986 Aug;12(8):343-5.
2. Frank J, Vertucci. **Root canal morphology and its relationship to endodontic procedures.** *Endodontic Topics.* 2005 March;10(1)
3. Poorni S, Karumaran CS, Indira R. Mandibular first premolar with two roots and three canals. *Aust Endod J.* 2010 Apr;36(1):32-4.
4. Cleghorn BM, Christie WH, Dong CC. The root and root canal morphology of the human mandibular first premolar: A literature review. *J Endod.* 2007 May;33(5):509-16.
5. Slowey RR. Root canal anatomy. road map to successful endodontics. *Dent Clin North Am.* 1979 Oct;23(4):555-73.
6. Zillich R, Dowson J. Root canal morphology of mandibular first and second premolars. *Oral Surg Oral Med Oral Pathol.* 1973 Nov;36(5):738-44.
7. Slowey RR. Radiographic aids in the detection of extra root canals. *Oral Surg Oral Med Oral Pathol.* 1974 May;37(5):762-72.
8. Hoen MM, Pink FE. Contemporary endodontic retreatments: An analysis based on clinical treatment findings. *J Endod.* 2002 Dec;28(12):834-6.
9. Lu TY, Yang SF, Pai SF. Complicated root canal morphology of mandibular first premolar in a chinese population using the cross section method. *J Endod.* 2006 Oct;32(10):932-6.
10. Jain A, Bahuguna R. Root canal morphology of mandibular first premolar in a gujarati population - an in vitro study. *Dent Res J (Isfahan).* 2011 Summer;8(3):118-22.
11. Khedmat S, Assadian H, Saravani AA. Root canal morphology of the mandibular first premolars in an iranian population using cross-sections and radiography. *J Endod.* 2010 Feb;36(2):214-7.
12. Vertucci FJ. Root canal anatomy of the human permanent teeth. *Oral Surg Oral Med Oral Pathol.* 1984 Nov;58(5):589-99.
13. Gulabivala K, Opananon A, Ng YL, Alavi A. Root and canal morphology of thai mandibular molars. *Int Endod J.* 2002 Jan;35(1):56-62.
14. Davis SR, Brayton SM, Goldman M. The morphology of the prepared root canal: A study utilizing injectable silicone. *Oral Surg Oral Med Oral Pathol.* 1972 Oct;34(4):642-8.

15. Robertson D, Leeb IJ, McKee M, Brewer E. A clearing technique for the study of root canal systems. *J Endod.* 1980 Jan;6(1):421-4.
16. Ahmed HA, Abu-bakr NH, Yahia NA, Ibrahim YE. Root and canal morphology of permanent mandibular molars in a sudanese population. *Int Endod J.* 2007 Oct;40(10):766-71.
17. Chen YC, Lee YY, Pai SF, Yang SF. The morphologic characteristics of the distolingual roots of mandibular first molars in a taiwanese population. *J Endod.* 2009 May;35(5):643-5.
18. Gulabivala K, Aung TH, Alavi A, Ng YL. Root and canal morphology of burmese mandibular molars. *Int Endod J.* 2001 Jul;34(5):359-70.
19. De Moor RJ, Deroose CA, Calberson FL. The radix entomolaris in mandibular first molars: An endodontic challenge. *Int Endod J.* 2004 Nov;37(11):789-99.
20. Kottoor J, Sudha R, Velmurugan N. Middle distal canal of the mandibular first molar: A case report and literature review. *Int Endod J.* 2010 Aug;43(8):714-22.
21. Jain S. Mandibular first molar with three distal canals. *J Conserv Dent.* 2011 Oct;14(4):438-9.
22. Chen G, Yao H, Tong C. Investigation of the root canal configuration of mandibular first molars in a taiwan chinese population. *Int Endod J.* 2009 Nov;42(11):1044-9.
23. Reuben J, Velmurugan N, Kandaswamy D. The evaluation of root canal morphology of the mandibular first molar in an indian population using spiral computed tomography scan: An in vitro study. *J Endod.* 2008 Feb;34(2):212-5.
24. Wasti F, Shearer AC, Wilson NH. Root canal systems of the mandibular and maxillary first permanent molar teeth of south asian pakistanis. *Int Endod J.* 2001 Jun;34(4):263-6.
25. al-Nazhan S. Incidence of four canals in root-canal-treated mandibular first molars in a saudi arabian sub-population. *Int Endod J.* 1999 Jan;32(1):49-52.
26. Zillich R, Dowson J. Root canal morphology of mandibular first and second premolars. *Oral Surg Oral Med Oral Pathol.* 1973 Nov;36(5):738-44.
27. Gupta A, Duhan J, Wadhwa J. Prevalence of three rooted permanent mandibular first molars in haryana (north indian) population. *Contemp Clin Dent.* 2017 Jan-Mar;8(1):38-41.
28. Zaatar EI, al Anizi SA, al Duwairi Y. A study of the dental pulp cavity of mandibular first permanent molars in the kuwaiti population. *J Endod.* 1998 Feb;24(2):125-7.
29. de Pablo OV, Estevez R, Peix Sanchez M, Heilborn C, Cohenca N. Root anatomy and canal configuration of the permanent mandibular first molar: A systematic review. *J Endod.* 2010 Dec;36(12):1919-31.

30. Hasselgren G, Nellestam P, Bynum-Hasselgren RM. Teeth with transparent roots--an improved teaching aid for preclinical endodontics. *J Endod.* 1987 Mar;13(3):126-7.

31. Caliskan MK, Pehlivan Y, Sepetcioglu F, Turkun M, Tuncer SS. Root canal morphology of human permanent teeth in a turkish population. *J Endod.* 1995 Apr;21(4):200-4.

32. Al-Qudah AA, Awawdeh LA. Root and canal morphology of mandibular first and second molar teeth in a jordanian population. *Int Endod J.* 2009 Sep;42(9):775-84.

UNDER PEER REVIEW