

Review Article

Review of Medical and Surgical Management of Chronic Anal Fissure

Abstract:

To determine which treatment modality has the best outcome for chronic anal fissures in terms of pain relief, healing of fissure and recurrence. The main symptoms are pain while passage of stools which is acute in primary fissures but often persists in case of longstanding fissures causing significant discomfort to the patient. The management of anal fissure has progressed immensely in the last decade due to better understanding of its pathophysiology. The main aim of the treatment is to reduce the spasm of the internal anal sphincter thereby reducing the anal canal pressure. Conservative approach consists of topical nitrates, ~~calcium channel blockers~~ and calcium channel blockers. It is often preferred over the surgical alternatives as it is not invasive. Surgeries for chronic anal fissure include anal dilatation, posterior mid-line sphincterotomy, lateral internal sphincterotomy, fissurectomy, sphincterolysis and advancement flap repair. This narrative review article aims to review all the existing as well as newer complex modalities that are available for the management of chronic anal fissures. Currently, the initial management of fissures is pharmacological therapy with topical nitroglycerin or diltiazem or botulinum toxin A injection. The next line of treatment is surgical that is lateral internal sphincterotomy. Non-surgical therapy often proves to be ineffective in providing relief and healing, frequently culminating in recurrence of fissures. On the other hand, surgical therapy has post operative drawbacks like intestinal incontinence which are commonly gas, loose stool or rarely hard stool. There is inadequate data on the latest modalities of treatment like fissurotomy, sphincterolysis, flap procedures, etc. So they may be considered only when conventional therapy fails to provide relief.

Keywords: Chronic anal fissure, Lateral internal sphincterotomy, diltiazem, nitroglycerin, botulinum toxin A

Background:

Anal fissure is an ischemic ulcer in the longitudinal axis of the lower anal canal. It occurs most commonly in the posterior midline, maybe seen in the anterior midline ~~as well~~ (in females). Spasm and contracture of the internal anal sphincter has a principal role in the pathogenesis of this condition[1,2,3]. A fissure which doesn't heal in 3 months can be termed as chronic[1]. The symptoms include extreme pain during and after bowel movements, rectal bleeding and constipation. as pPatients hesitate to pass stools due to pain - further aggravating the symptoms [1]. The incidence is more in young and working age group adults which renders the treatment issue highly relevant[2].

Objective:

This article aims to review the various treatment modalities available for management of chronic anal fissures.

Discussion:

Anal fissures are the result of increased internal anal sphincter tone. Acute anal fissures usually heal spontaneously within 6 weeks. Over the years there have been many alterations in the hypotheses aiming to understand the pathophysiology of chronic anal fissures. The earliest theory proposed trauma as a cause due to the passage of hard stools, however this only explained acute fissures and their progression to chronic fissures still remained unaccounted for[4]. The persistence of anal fissures was subsequently explained by two other factors – constant presence of anal sphincter hypertonia and ischemia preventing healing of fissures[3,4]. The distal anal canal (posterior commissure) has been demonstrated to have a deficient blood supply and is found to be the most common site for fissures[3,4].

-Healing is more difficult in cases of chronic fissures. The goals of medical management are targeted, consisting of:

- 1) Removal of the underlying pathology responsible for development of the fissure - by allaying the constipation and straining and averting anal trauma[4],
- 2) Relaxing the internal anal sphincter to increase the blood flow and allow better healing - can be achieved by various available therapies[4]
- 3) Providing symptomatic relief[3,4].

Most of the fissures usually resolve without surgical intervention. Healing is more prolonged in chronic fissures [4]. Surgical interventions for definitive management are considered when conservative therapy fails to provide relief. Surgeries are aimed at reducing the pressure of the anal canal and decreasing the tone of the internal anal sphincter-[1,2,3,4].

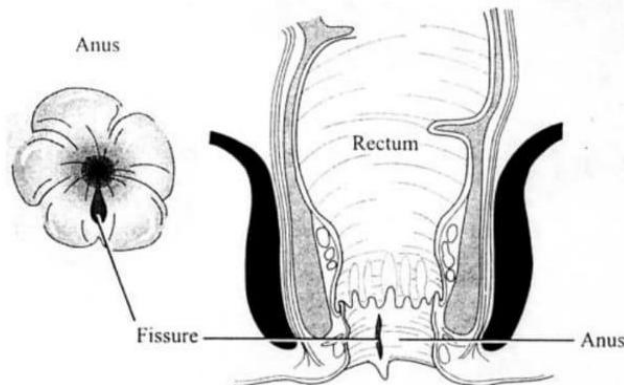


Figure 1: Chronic posterior anal fissure showing proximal extent below the dentate line and a sentinel pile.[1]

MEDICAL MANAGEMENT

The conservative treatment consists of:

- 1) High fiber diet or fiber supplements -

A randomized control trial showed that consumption of 10_g of unprocessed bran fiber daily along with warm sitz baths for 15 minutes daily after passing bowel movements gave quicker symptomatic relief and improved healing at 3 weeks as opposed to 2% lignocaine ointment or 2% hydrocortisone cream[4]. Dietary fiber is only shown to be effective only when consumed before stools are formed. ~~It~~ However, it plays little to no role in relieving pre-existing constipation[5].

2) Sitz baths -

-They help by improving hygiene, reducing pain and relieving the anal sphincter spasm. Various RCTs have shown that sitz baths have no compelling role in providing symptomatic relief to the patient nor does it play a role in accelerating wound healing[6,7]. However, sitz baths have shown to improve patient satisfaction. There are few reported side effects like perianal skin rash[6]. No other severe complications have been reported. Thus, there is no strong proof to back the role of sitz baths for treatment of anal fissures although it may be used for patient satisfaction[6,7].

3) Topical nitrates -

Nitrates are a group of compounds that release NO which is a vascular smooth muscle relaxant[1,8]. NO acts through production of cGMP. cGMP has various intracellular actions - one of which is the relaxation of smooth muscles[1]. GTN (Glyceryl trinitrate) which is readily absorbed cutaneously is applied as a 0.2% paste to the perianal skin. It has been demonstrated to increase the anodermal blood flow and reduce the mean anal resting pressure[1,4]. The most prevalent negative effect of GTN medication is headache, which typically leads to treatment noncompliance[1,4]. Although the healing rates are low, effective symptomatic relief is achieved. It should also be noted that the treatment may take up to eight weeks to be effective[1,4,8].

4) Calcium Channel Blockers -

Topical and local calcium channel blockers have the same mechanism of action as nitrates. They are also reportedly not associated with headaches[1,4,8]. Topical diltiazem application has been shown to have good efficacy in healing fissures with minimal side effects[1,4,8]. The main side effect observed with calcium channel blockers is itching but it seldom leads to discontinuation of treatment[4]. It can thus be considered as an effective conservative treatment alternative.

5) Botulinum toxin

It is an exotoxin released by the *C. botulinum* bacterium[1,4]. When injected locally, the toxin attaches itself to the nerve terminals located at the presynaptic neuromuscular junction, stopping acetylcholine release and causing short lasting muscle paralysis[1,4]. The exact role of BT injection in the anal fissure therapy protocol is unknown[1,4]. The transitory nature of the procedure makes it desirable to patients concerned about the chances for future incontinence, as well as individuals with significant levels of anxiety who are unable to consent to lateral internal sphincterotomy[4]. Pain was reportedly alleviated in 24 hours and healing of fissures was observed in 12 weeks [1].

The BT injection can be done safely in the office, or it can be done as an outpatient treatment under anesthesia[4]. Although this has not been rigorously studied, proponents of doing this technique as an outpatient surgery suggest that including fissure debridement in the process may

Formatted: Font: Italic

improve healing[4]. It is however important to note that the effects of this procedure wear off in three months and if the causative factors have not been addressed by then, a high chance of recurrence is seen [4].

The summary of outcomes and recurrence rates of different pharmacological agents is listed below[9] -

Table 1. Literature survey

UNDER PEER REVIEW

S/N	Reference	Details of study	Outcomes	Remarks
1	Lund et al 1997 Double armed, prospective, randomized	0.2% GTN vs placebo 80 patients	Within 8 weeks, GTN had a 68 percent recovery rate. Healing rate of placebo: 8% In the GTN group, recurrences were 7.9%. GTN treatment for a further 6 weeks was successful.	
2	Kennedy et al 1999 Double armed, prospective, randomized, placebo-controlled	0.2% GTN vs placebo 43 patients	Healing rate of 46% in the GTN group, 16 percent healing rate in the placebo group.	Statistically noteworthy.
3	Altomare et al 2000 Double armed, prospective, randomized	0.2% GTN vs placebo 132 patients	GTN had a healing rate of 49.2 percent. Placebo had a healing rate of 51.7%. The GTN group showed a recurrence of 19%.	GTN's superiority against placebo could not be demonstrated.
4	Scholefield et al 2003 Four armed, prospective, randomized	0.1% GTN vs 0.2% GTN vs 0.4% GTN vs placebo 200 patients	Intention-to-treat analysis: Placebo-37.5% healing rate 0.1% GTN-46.9% healing rate 0.2% GTN-40.4% healing rate 0.4% GTN-54.1% healing rate	The inclusion of acute fissures may have contributed to the high healing rates of placebo. Owing to the small sample size, the 0.2 percent GTN had the lowest healing rate.
5	Kocher et al 2002 Double armed, prospective, randomized	61 patients received 0.2 percent GTN vs. 2 percent Diltiazem cream.	GTN-25/29 (86.2%) patients showed improvement or recovered. Patients who had diltiazem healed or improved 24 of 31 times (77.4%).	
6	Knight et al 2001 Single arm, non-randomized	71 patients received 2% Diltiazem cream for longstanding anal fissures.	Within 16 weeks, 59 of 66 patients (89.4%) had healed. On follow-up, 7/59 (11.8%) of patients had persistence.	

7	Carapeti et al 2002 Two separate pilot studies	2002 pilot	30 individuals received 2% Diltiazem cream vs. bethanechol gel of 0.1% concentration.	Diltiazem was effective in 67 percent Bethanechol provided relief in 60 percent.
8	Jonas et al Single prospective, randomized	2002 arm, non-	2 percent topical diltiazem for fissures resistant to GTN therapy in 39 patients	67 percent relief rate with diltiazem Healing rate of Bethanechol is 60%.
9	Maria et al Double prospective, randomized	1998 arm,	20 units of botulinum toxin injection vs saline for thirty patients	At two months, Botulinum toxin-eleven out of fifteen (73.3 percent) patients were healed. After an additional 25 units, the remaining four patients (26.7 percent) healed. At 2 months, 12 of the saline patients had healed. In the botulinum group, there were no recurrences.
10	Lindsey et al Single prospective, randomized	2003 arm, non-	Botulinum toxin 20 units injection for persistent anal fissures following an initial 8-week treatment with 0.2 percent GTN 40 patients	Healing is complete in 43% of cases. With symptom remission, only 12% of people are still unhealed. With symptom relief, 18% of people are still unhealed. 27 percent of patients are still unhealed, with no signs of recovery. A total of 27% received surgery at some point.

11	Brisinda et al 1999 Dual arm, prospective randomized, non-controlled	Botulinum toxin A injection of 20 units vs GTN 0.2 percent for 8 weeks. failure to achieve relief after 8 weeks treatment was offered from another arm for fifty patients.	Botulinum toxin– healing of fissures seen in 96 percent after 2 mo. With GTN therapy - 60 percent got relief after 2 mo.	Statistically noteworthy
12	Jones et al 2006 Dual arm, prospective randomized, non-controlled	Injection of 25 units if botulinum toxin along with 0.2 percent GTN vs only botulinum toxin 25 units in 30 patients	At 8 weeks, Botulinum toxin and GTN-47 had completely healed the wound. Botulinum toxin alone is responsible for 27% of full recovery. By 6 months, Botulinum toxin and GTN-27 therapy failure had reached 27 percent. By 6 months, botulinum toxin alone had a 47 percent treatment failure rate	Statistically noteworthy. not
13	Garrido et al 2007 Single arm, prospective, non-randomized	Gonyautoxin 100 units injection 23 patients	18 out of 23 patients got relief in 7 days 3/23-healed in 12 d 2/23 patients-healed in 2 weeks	

UNDE

SURGICAL MANAGEMENT

Despite the availability of non-surgical treatments, surgery is still an effective and popular treatment for persistent anal fissures. It doesn't only provides immediate clinical relief, but it also cures the fissure in up to 95% of patients. Anal dilatation, posterior mid-line sphincterotomy, lateral internal sphincterotomy, fissurectomy, and advancement flap repair are the commonly employed surgical procedures. Postoperative incontinence is a concern associated with all surgical procedures.

1) Anal Dilatation

One of the first devised methods for the management of anal fissures was anal dilatation[1,4,9]. The technique varies, but it usually entails inserting four fingers into the anal canal and straining the sphincters for two to four minutes[1,4,9]. This procedure has been reported to heal up to 90% of fissures, but recurrence has been documented in 2.2 percent–56.5 percent of cases[1,4,9]. The dangers of incontinence have not been properly recognized until recently. The likelihood of incontinence after an anal stretch is substantially higher than after other treatment methods, with more than 50% of patients reporting continence impairment[4]. As seen on endoanal ultrasonography, incontinence is caused by sphincter disruption caused by anal strain[4]. Other methods for standardizing anal dilation or reducing trauma have not been broadly accepted. Because of these potential risks and the availability of better treatment modalities, anal dilatation as a management modality for anal fissures has now been deemed redundant[1,4,9].

2) Lateral Internal Sphincterotomy

Boyer proposed sphincterotomy as a treatment modality for anal fissures for the first time in 1818. To treat persistent anal fissures, a variety of surgical methods (fissurectomy, anal dilatation, posterior and lateral sphincterotomy, and advanced flap) have been used[1,4,8,9-12]. Medication that lowers the internal anal sphincter tone can successfully reduce anal pressure, allowing in the recovery of chronic fissures. Unfortunately, this effect is reversible, and if the problem reappears, the medicine should be stopped, even if the fissure has healed completely. Sphincterotomy is the most efficient and successful way of management in individuals with chronic anal fissures as opposed to other surgical and pharmacological treatment options[1,4,9,10,11,12-16].

A radial incision in the anoderm is made laterally to expose the internal sphincter muscle fibers during a lateral internal sphincterotomy[1,4,8,12]. The distal four-fifths of the internal anal sphincter muscle are then sharply divided with a scalpel or scissors under direct observation. The wound may be left open or closed primarily. The spasms associated with anal fissures are eased by partially splitting the internal anal sphincter. This promotes blood flow to the ischemic anal ulcer, which promotes healing. LIS provides the best results, accompanied by a positive rate of over 90%, but there is a possibility of fecal incontinence that must be considered. Infection, abscess, fistula, and hematoma are occasionally seen complications after LIS[1,4,9,11,12,13]. In spite of the high success rate of fissure recovery post sphincterotomy, between 1.6 and 6% of patients will experience recurrence. Inadequate sphincterotomy is the leading cause of recurrence. Sphincterotomy can be performed again in such instances.

3) Fissurectomy

Fissurectomy is the surgical removal of an anal fissure[4,9,13]. It is a procedure that involves removal of the anal fissure edges, curetting or excision of the fissure base, and maybe removal of sentinel skin tags and anal polyps to allow the anal fissure to heal[4,9,13]. Scissors and diathermy are two methods for excising the fissure that have been documented[4]. Some approaches support primary defect closure, whereas others advocate healing by secondary intention[4,9].

4) Flap anoplasty

Chronic anal fissures are also treated using flap anoplasty surgeries[4,9]. A local flap is created to cover the fissure defect in these treatments. Flap procedures are particularly beneficial in patients with normal anal pressures or in fissures owing to obstetric trauma, where there is commonly concomitant internal sphincter disruption, because they spare the disruption of the internal anal sphincter[4,9].

5) Sphincterolysis

Anal spasm in patients suffering ~~with~~ ~~from~~ persistent anal fissures can be addressed by closed manipulation of the fibers of the internal anal sphincter. This technique is known as sphincterolysis. Ecchymosis, hematoma, and a submucous abscess were among the significant consequences. Within four weeks, the majority of the patients were completely healed. Thus, for the management of chronic anal fissure, manipulation of the internal anal sphincter fibers is a simple, safe, and effective approach.[15]

NEWER INNOVATIONS

1) Posterior perineal support device

The usage of a device that supports the posterior perineum placed into a toilet seat to promote the healing rates of longstanding anal fissures was investigated in a recent study[4,9]. This posterior perineal support device is believed to counteract the posterior anal sphincter complex and mucosa's preferential overstretching, making defecation easier and less traumatizing[4,9].

2) Gonyautoxin injection

Gonyautoxin is the newest pharmacological therapy to hit the market, and the preliminary results are promising, with a 100 percent recovery rate in just two weeks and no instances of incontinence[4,9]. Gonyautoxin acts by binding to voltage-gated sodium channels on excitable cells in a dose-dependent reversible manner, resulting in a blocking of neuronal transmission[10-15]. The effects are reversible and transient, and the mechanism is comparable to that of Botulinum toxin[4,9]. As a result, this does not fix the underlying issue of Botulinum toxin injection recurrence. Gonyautoxin, on the other hand, may help heal fissures in ways that have yet to be found[16-22].

CONCLUSION

Anal fissures are a very common pathology of the anorectal region with a high incidence in the working age group adults. It is associated with extreme pain and has a high morbidity resulting in poor quality of life and often disability. Medical management includes high fiber diet, sitz baths, topical CCB, or topical nitrates. The treatment of primary anal fissures is usually done in stages, with first-line medical therapy lasting up to 6–8 weeks. Though often preferred due to its noninvasive nature, it has a high recurrence rate and unsatisfactory relief of symptoms. As the

statistics above demonstrate, no single standard pharmaceutical therapy has consistently demonstrated to be preferable to others. When conservative treatment fails, BT injection, which has few side effects and a high cure rate, may be tried. The limited lateral internal sphincterotomy is the best amongst surgical intervention, with no difference between open and closed procedures. If all other pharmacological therapies have failed or have been stopped due to problems, lateral internal sphincterotomy should be considered. The internal anal sphincter is separated up to the apex of the fissure, which helps in decreasing anal incontinence. Fecal incontinence caused by a restricted lateral internal sphincterotomy is rare and usually only lasts a few days.

The following is a brief summary of the treatment algorithm for chronic anal fissures [9] -

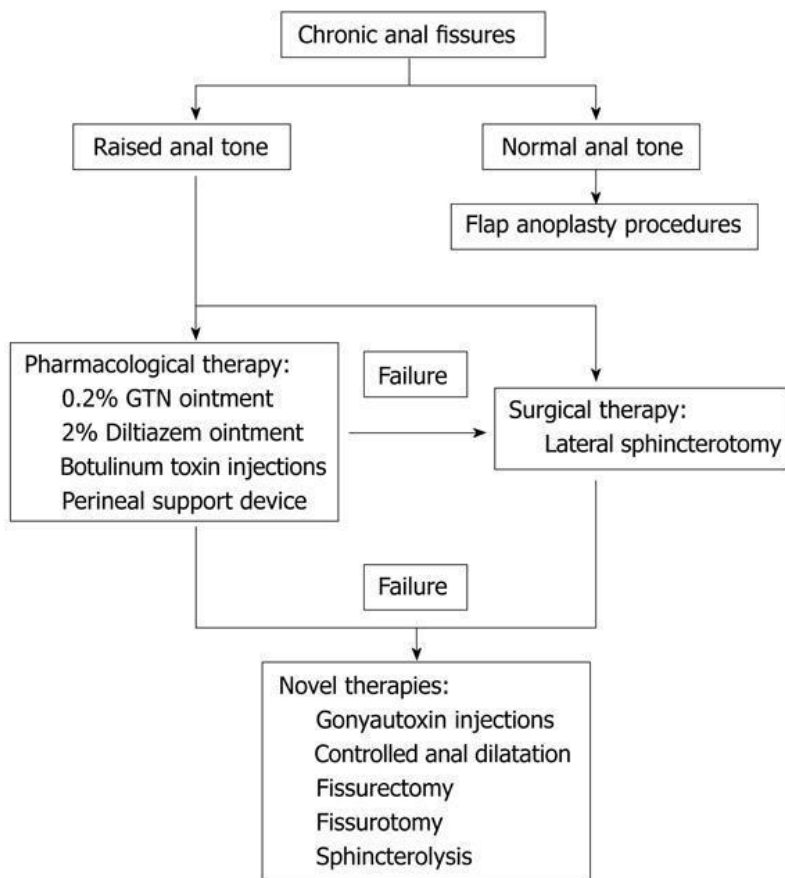


Fig. 1. treatment algorithm for chronic anal fissures

REFERENCES:

- 1) Garner J, McFall M, Edwards D. The Medical and Surgical Management of Chronic Anal Fissure [Internet]. ResearchGate. 2002 [cited 10 October 2021]. Available from: https://www.researchgate.net/publication/11003051_The_Medical_And_Surgical_Management_Of_Chronic_Anal_Fissure
- 2) Frolov S. Complex Treatment of a Chronic Anal Fissure. Case Medical Research [Internet]. 2019 [cited 7 September 2021]. Available from: <https://clinicaltrials.gov/ct2/show/NCT03855046>
- 3) STEELE S, MADOFF R. Systematic review: the treatment of anal fissure. Alimentary Pharmacology and Therapeutics [Internet]. 2006 [cited 26 November 2021];24(2):247-257. Available from: <https://onlinelibrary.wiley.com/doi/10.1111/j.1365-2036.2006.02990.x>
- 4) Shashidharan M, Beaty J. Anal Fissure. Clinics in Colon and Rectal Surgery [Internet]. 2016 [cited 22 October 2021];29(01):030-037. Available from: <https://www.ncbi.nlm.nih.gov/pmc/articles/PMC4755763/>
- 5) Ho K. Stopping or reducing dietary fiber intake reduces constipation and its associated symptoms. World Journal of Gastroenterology [Internet]. 2012 [cited 15 September 2021];18(33):4593. Available from: <https://www.wjgnet.com/1007-9327/full/v18/i33/4593.htm>
- 6) Gupta P. RANDOMIZED, CONTROLLED STUDY COMPARING SITZ-BATH AND NO-SITZ-BATH TREATMENTS IN PATIENTS WITH ACUTE ANAL FISSURES. ANZ Journal of Surgery [Internet]. 2006 [cited 2 October 2021];76(8):718-721. Available from: <https://onlinelibrary.wiley.com/doi/abs/10.1111/j.1445-2197.2006.03838.x>
- 7) LANG D, THO P, ANG E. Effectiveness of the Sitz bath in managing adult patients with anorectal disorders. Japan Journal of Nursing Science [Internet]. 2011 [cited 16 October 2021];8(2):115-128. Available from: <https://pubmed.ncbi.nlm.nih.gov/22117576/>
- 8) MR M, P H. Chronic Anal Fissure: A Comparative Study of Medical Treatment Versus Surgical Sphincterotomy [Internet]. PubMed. 2021 [cited 10 September 2021]. Available from: <https://pubmed.ncbi.nlm.nih.gov/27424014/>
- 9) Poh A. Innovations in chronic anal fissure treatment: A systematic review. World Journal of Gastrointestinal Surgery [Internet]. 2010 [cited 10 September 2021];2(7):231. Available from: <https://www.wjgnet.com/1948-9366/full/v2/i7/231.htm>
- 10) Collins E, Lund J. A review of chronic anal fissure management. Techniques in Coloproctology [Internet]. 2007 [cited 14 September 2021];11(3):209-223. Available from: <https://pubmed.ncbi.nlm.nih.gov/17676270/>
- 11) Gandomkar H, Zeinoddini A, Heidari R, Amoli H. Partial Lateral Internal Sphincterotomy versus Combined Botulinum Toxin A Injection and Topical Diltiazem in the Treatment of Chronic Anal Fissure. Diseases of the Colon & Rectum [Internet]. 2015 [cited 8 October 2021];58(2):228-234. Available from: <https://pubmed.ncbi.nlm.nih.gov/25585082/>
- 12) Schlichtemeier S, Engel A. Anal fissure. Australian Prescriber [Internet]. 2016 [cited 9 October 2021];39(1):14-17. Available from: <https://www.ncbi.nlm.nih.gov/pmc/articles/PMC4816871/>
- 13) Sritharan H, Ashok Kumar N, Syed Ibrahim M. Management of chronic anal fissures: a narrative review. International Surgery Journal [Internet]. 2020 [cited 26 November 2021];7(4):1327. Available from: <https://www.ijurgery.com/index.php/ij/article/view/5768>

- 14) T A, N A, F G, E K, H G, K A et al. Comparative efficacy of medical treatment versus surgical sphincterotomy in the treatment of chronic anal fissure [Internet]. ResearchGate. 2020 [cited 20 October 2021]. Available from: https://www.researchgate.net/publication/340447365_Comparative_efficacy_of_medical_treatment_vs_surgical_sphincterotomy_in_the_treatment_of_chronic_anal_fissure
- 15) PJ G. Closed anal sphincter manipulation technique for chronic anal fissure [Internet]. PubMed. 2008 [cited 10 September 2021]. Available from: <https://www.ncbi.nlm.nih.gov/pubmed/18792671>
- 16) Salih A. Chronic anal fissures: Open lateral internal sphincterotomy result; a case series study. *Annals of Medicine and Surgery* [Internet]. 2017 [cited 22 September 2021];15:56-58. Available from: <https://www.sciencedirect.com/science/article/pii/S204908011730033X?via%3Dihub>
- 17) Bhojraj, Nandini, and Gaurav Sawarkar. "The Effect of Panchagavya Formulations in the Case of CA Rectum." *INTERNATIONAL JOURNAL OF AYURVEDIC MEDICINE* 11, no. 3 (September 2020): 572–74.
- 18) Thomas, Sophia, and Arvind Bhake. "Expression of K-Ras, P53 and Ki-67 in Precancerous and Cancerous Lesions of Colorectum." *JOURNAL OF EVOLUTION OF MEDICAL AND DENTAL SCIENCES-JEMDS* 9, no. 32 (August 10, 2020): 2261–65. <https://doi.org/10.14260/jemds/2020/490>.
- 19) Yeola, Meenakshi Eknath, and Aditya Prabhalkarrao Borgaonkar. "Passage of Gangrenous Small Bowel Per Rectum Following Superior Mesenteric Vessel Thrombosis." *JOURNAL OF CLINICAL AND DIAGNOSTIC RESEARCH* 13, no. 12 (December 2019). <https://doi.org/10.7860/JCDR/2019/42828.13381>.
- 20) Raja, Kolluru Karthik, Shilpa Gaidhane, Sharad Bhagwanrao Sonawane, Nazli Khatib, and Yash Gupte. "Atrial Fibrillation Presenting with Acute Abdomen in an Elderly Patient - A Case Report." *JOURNAL OF EVOLUTION OF MEDICAL AND DENTAL SCIENCES-JEMDS* 9, no. 40 (October 5, 2020): 3019–21. <https://doi.org/10.14260/jemds/2020/661>.
- 21) Shinde R, Dighe S, Shinde S. A rare case of triple vessel disease of abdomen. *MEDICAL SCIENCE*. 2021 Jan;25(107):101–5.
- 22) Mahawar R, Chandak S, Yeola M. A Prospective Study on Clinico-Radiological Correlation and Conservative Management of Non-Traumatic Acute Abdomen at a Tertiary Care Centre. *JOURNAL OF PHARMACEUTICAL RESEARCH INTERNATIONAL*. 2021;33(32B):119–24.