

Case report

PERTROCHANTERIC FRACTURE NECK OF THE FEMUR PRESENTING AS AVASCULAR NECROSIS WITH GAIT ABNORMALITY - A CASE REPORT.

ABSTRACT

The pertrochanteric femoral fracture is a highly common kind of femoral fracture. It is generally the consequence of a fall. A high-energy mechanism, such as a motor vehicle accident, is more likely to cause Pertrochanteric fractures in **young individuals**. A 45-year-old man had a history of a bike crash that resulted in a pertrochanteric fracture of the right hip, for which he was operated. The patient arrived with right hip discomfort and edema after surgery and was referred for physiotherapy. Avascular necrosis of the femoral head is a pathological condition that occurs when the blood supply to the bone is cut off, and it is a common consequence of fractures, dislocations, and other injuries.

Key Words: Fractures, edema, avascular necrosis, blood supply.

INTRODUCTION:

Avascular necrosis of the femoral head is followed by a reduction in blood supply to bone tissue. If the condition is not addressed, it worsens over time. The inferior metaphyseal and lateral epiphyseal vessels are the two basic types of vessels that nourish the femoral head's perimeter. Common reason of femoral head avascular necrosis is damage to the lateral epiphyseal arteries. This consequence is more common in intracapsular hip fractures than extracapsular hip fractures. If the condition is not addressed, it will worsen over time, eventually leading to femoral head collapse and severe arthritis. Non-traumatic occurrences such as steroid therapy, excessive

alcohol use, blood coagulation difficulties, and any other intimacy that results in inadequate blood flow to the femoral head in youth population can induce avascular necrosis. In this report, we present a case of a petrochanteric fracture patient who developed femoral head avascular necrosis two years after surgery[1].

CASE REPORT:

Due to an unintentional fall off his bike, a 45-year-old man reported to the casualty with severe right hip pain and difficulty to walk. A typical emergency antero-posterior radiograph (Fig. 1) revealed an Evans type II petrochanteric fracture of the right hip [2]. The patient was operated on with a dynamic interlocking trochanteric gamma nail (Fig. 2). Neither the procedure nor the recovery were marred by problems. The patient was able to walk unaided after three months of the operation. On radiographs, the right hip fracture had healed after six months (Fig. 3). With no recent trauma, the patient exhibited minor pain and limited joint mobility two years following the operation[2]. Despite the fact that the gamma nail was in a satisfactory position, we concluded that the reason of the discomfort was sensitivity to the implant. The recovery went smoothly, only slight limitations in hip mobility and a decrease in pain. After the implant was removed, the patient was monitored and given conservative therapy to prevent further damage to the right hip and allow it to heal.

Comment [U1]: It should be replaced with image and numbered as presented in the imagery.

CLINICAL FINDING :

A proper informed consent was taken from the patient. Patient was conscious and well oriented to time, place and person. Patient was

In supine position. On examination , temperature was normal , pulse was 76 beats per minute pulse, respiratory rate was 21 beats per minute and blood pressure was 120/80 mmHg.

The patient was alert and aware of time, location, and person. The patient was lying down in a supine position. The temperature was normal, the pulse was 76 beats per minute, the respiration rate was 21 beats per minute, and the blood pressure was 120/80 mmHg on physical examination.

Pain assessment was done on Visual analog scale and the score was 7/10 . On inspection, patients right leg was affected due to road traffic accident , there was a scar mark present at anterior aspect of the hip joint and range of motion was affected due to pain. There was stiffness present at the hip joint and patient had difficulty in walking and ascending of stairs.

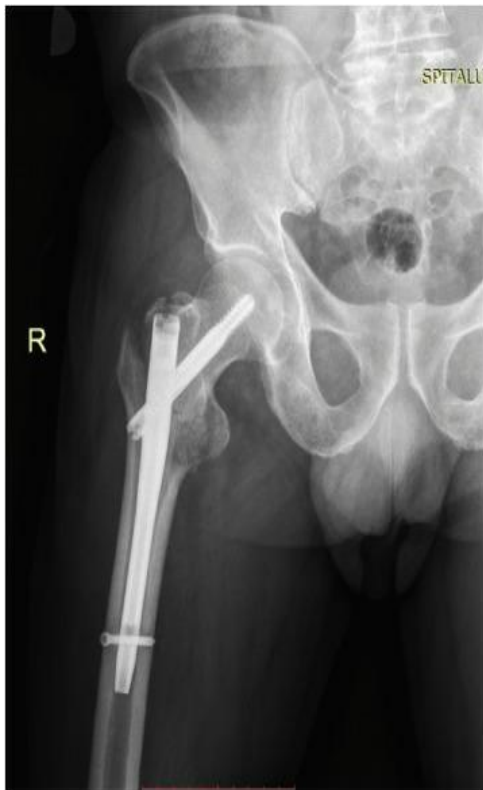

Image 1. X-ray image of hip joint

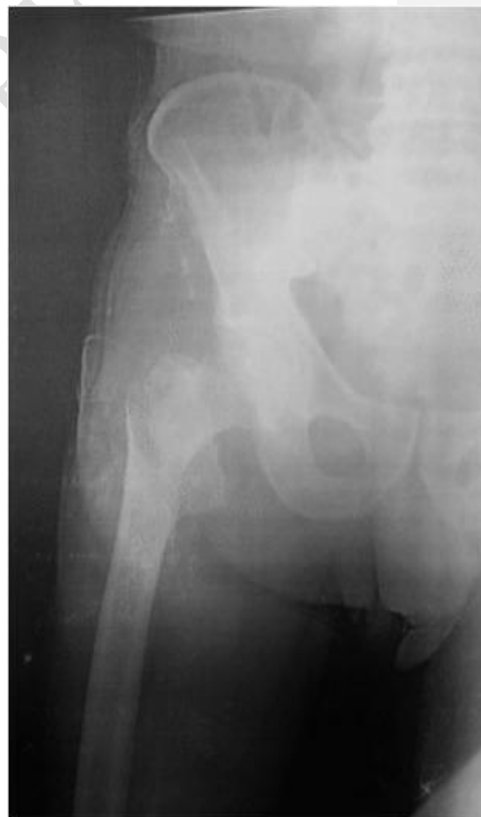

Image 2. Xray image in supine position

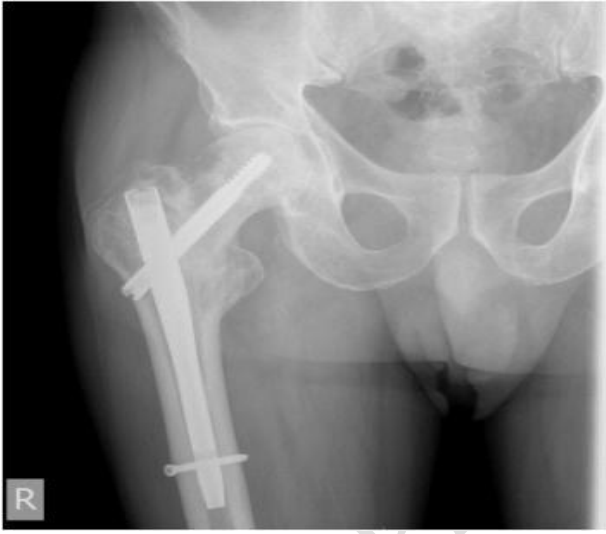

Image 3. X-ray image 2

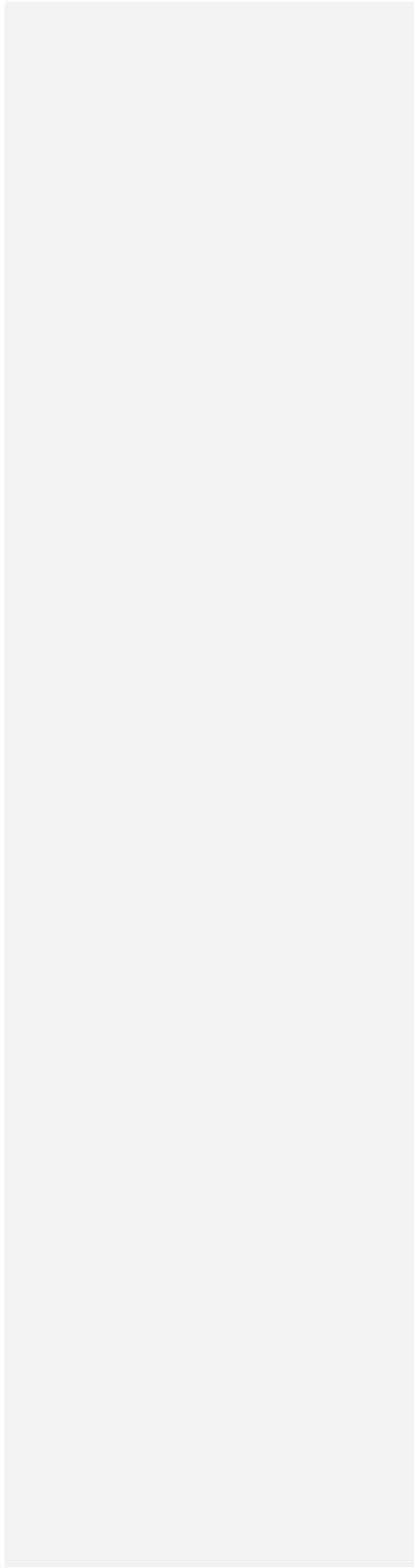

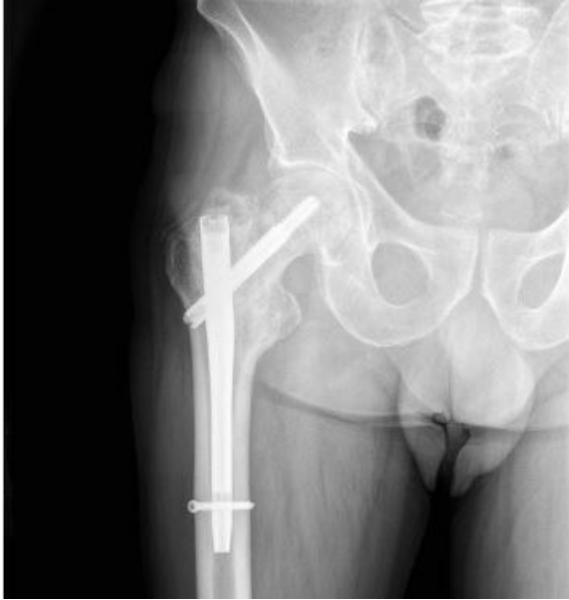


Image 4. Xray image 3

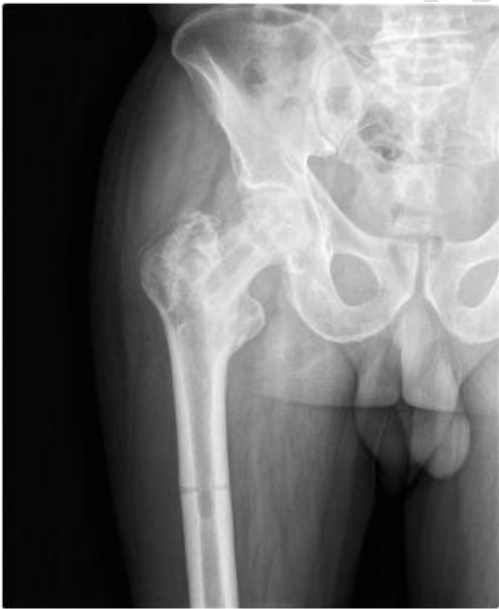

Image 5. X-ray image 4

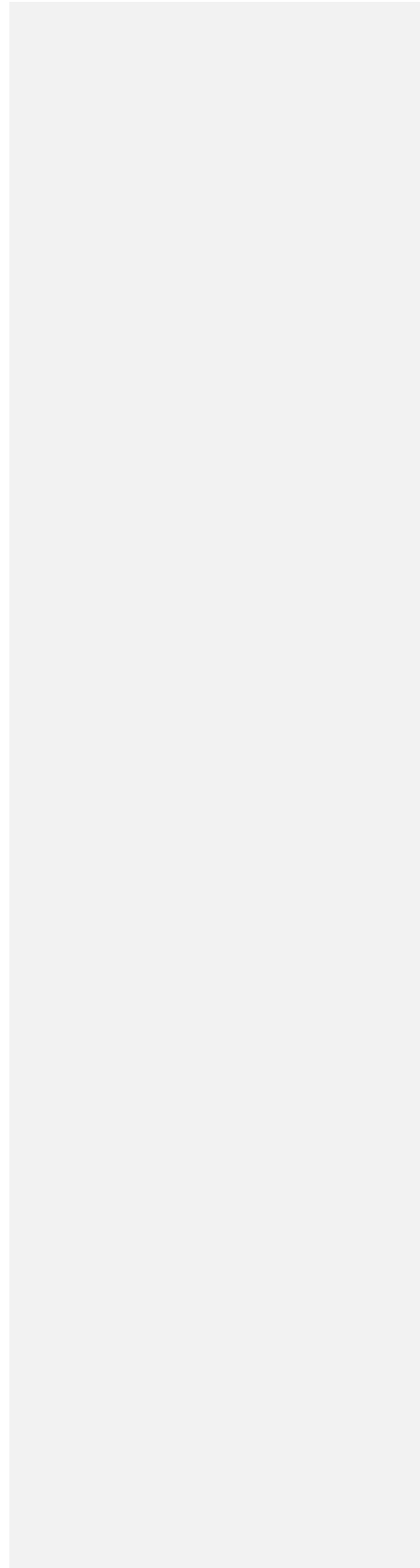

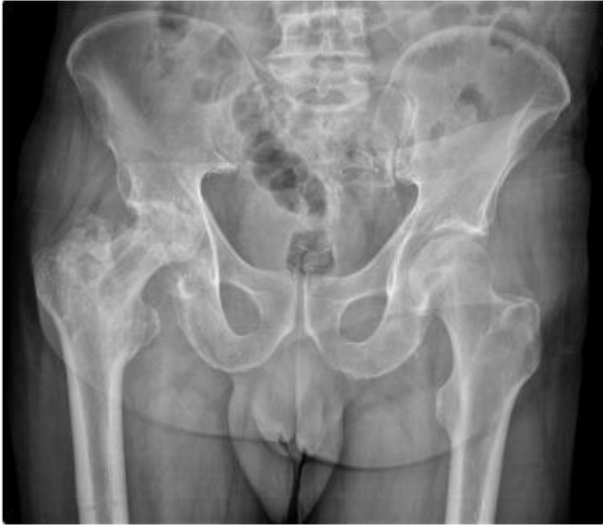


Image 6.X-ray image 5

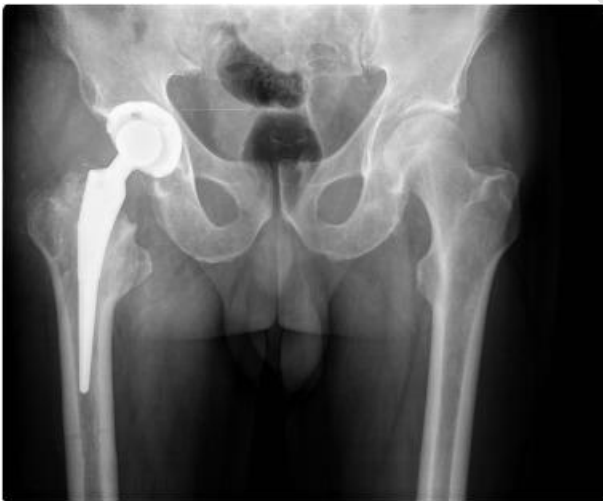

Image 7. X-ray image 6

Physiotherapy Management :

Non-weight-bearing phase : After the surgery exercises to the ankle and foot were given ,along with isometrics to the quadriceps and hamstrings were begun.

After reduction of pain isometrics to the glutes were started.

Gentle mobilization in the form of relaxed passive movement was initiated gradually and then worked up to the maximal pain-free range.

Isometrics with longer holds helps in minimising the muscle atrophy. After regaining a good range of motion isotonic exercises were started including all movements of the hip joint and then progressed to isokinetic exercises.

Weight - bearing-phase : Weight bearing was taught in standing with axillary crutches and walker. Gradually weight transfers on one leg were taught .

Four point crutch walking was initiated to minimize weight on the hip joints.

After reduction of pain one crutch was discarded. The exercise programme was also progressed to improve strength and endurance of the muscles at the hip and knee joints. Proper gait training was given , after an acceptable gait and balance achieved by the patient ambulation was progressed to a single cane without compromising the pattern of gait.

Adequate independence in functional activities is regained by 12-16 weeks post surgery.

Table 1. Range of motion assessment pre physiotherapy rehabilitation

Exercise protocol	Duration and Frequency	Rationale
-------------------	------------------------	-----------

Joint	Right		Left	
	Active	Passive	Active	Passive
Hip Flexion	Unable to perform	0-30	0-90	0-100
Extension	Unable to perform	0-10	0-15	0-18
Abduction	0-10	0-30	0-35	0-40
Adduction	10-0	0-15	0-25	0-30
Knee Flexion	Unable to perform	25-0	0-130	0-135
Extension	Unable to perform	25-0	130-0	135-0
Ankle plantar flexion	0-40	0-45	0-50	0-50
Dorsiflexion	0-5	0-10	0-10	0-10

	Phase A: non- weight-bearing phase	
Ankle toe movements	10 repetitions 3 times a day	To prevent pedal oedema
Isometrics to quadriceps, hamstrings and glutes	10 repetitions with 5 sec hold for 3 times a day	To minimize muscle atrophy and maintain contractility of the muscle
Strengthening exercises to hip, knee and ankle	10 repetitions with 5 sec hold for 3 times a day	To improve muscle strength and endurance

	Phase B : weight bearing phase	
Ambulation with walker	For 10 mins 3 times a day	To improve patients functional independence and pulmonary circulation

Joint	Active	Passive
Hip Flexion	0-80	0-90
Extension	0-15	0-18
Abduction	0-45	0-50
Adduction	0-20	0-25
Knee Flexion	0-45	0-50
Extension	45-0	50-0
Ankle plantar flexion	0-50	0-50
Dorsiflexion	0-10	0-10

Comment [U2]: The table is split table and its contents are misleading. The table should be properly presented, and cited and discussed.

Rom assessment post physiotherapy rehabilitation

Home Program :

Active Range of motion exercises, bilateral upper limb strengthening, pursed lip breathing, static and dynamic hamstrings and quadriceps, ankle toe movements , walking with crutches was educated to the patient as well as to the family members.

DISCUSSION:

Avascular necrosis affects young people, most of them are males [3]. Joint or bone injuries (femoral neck fractures, hip dislocation), certain drugs and idiopathic symptoms (which account for 25% of cases) are the most prevalent causes of this condition [4]. Avascular necrosis after pertrochanteric fractures is a fairly uncommon complication that occurs in 0.3 percent to 0.5 percent of patients [5], [6]. In a thorough investigation, Barquet *et al.* discovered that this condition occurred in 1.37 percent in patients undergoing trochanteric fracture surgery within the first two years of injury [7]. A loss of blood flow in the metaphyseal cancellous bone causes intertrochanteric fractures [8]. As a result of a nail insertion, an adolescent with a femoral diaphyseal fracture developed avascular necrosis of the femoral head [9]. No investigations have indicated that mechanical failure may produce avascular necrosis, even if a brief ischemic episode occurs after surgery [10].

The femoral head avascular necrosis can be treated in a variety of methods. Weight-bearing on the afflicted hip joint may result in spontaneous remission of osteonecrosis if the condition is asymptomatic and the lesion is modest [11]. Accidents involving slips and falls are linked to 87 percent of hip fractures in the elderly. Falls in the elderly are connected with factors such as muscular weakening, decreased postural control, and balance(12). Piriformis stretching will help the patient **which** will allow him to reduce discomfort, **increase strength** and reintegrate into everyday activities (13). Weight-bearing exercise in quadruped posture was found to be beneficial for improving weight-bearing and proprioception, as well as for correct ambulation(14). Hamstring tightness is a rather frequent problem. Injuries are frequently related with poor hamstring flexibility. Both active release method and muscular energy technique assist patients improve their hamstring flexibility and discomfort (15). Early mobilisation and complete weight bearing in femur fracture patients often **result in rapid recovery of the patient.** A customizable programme to address her weaknesses while also increasing her strength and endurance was made (16).

Comment [U3]: The reference should be cited properly with date. It is not listed in the reference.

Formatted: Highlight

CONCLUSION

Avascular necrosis of the femoral head is an unusual condition that cannot be predicted or prevented following pertrochanteric fractures. Patients with risk factors should be closely monitored and treated as soon as possible if osteonecrosis advances. Uncemented total hip arthroplasty is the best surgical option in advanced stages, followed by physiotherapy rehabilitation.

ETHICAL APPROVAL

The **writers** have gathered and saved documented ethical approval in accordance with international or university standards.

Comment [U4]: Should be replaced with "authors"

CONSENT

The **writers** have obtained and saved written consent in accordance with international or university standards.

Comment [U5]: Should be replaced with "authors"

REFERENCES

Comment [U6]: The journal should be italicized
2. Some of your references are too old.

[1] R.P. Ficat. Idiopathic bone necrosis of the femoral head: early diagnosis and treatment; J. Bone Jt. Surg. Br., 67 (1985), pp. 3-9.

[2] E.M. Evans. The treatment of trochanteric fractures of the femur; J. Bone Jt. Surg. Br., 31B (1949), pp. 190-203.

[3] Takashi Atsumi, Yoshikatsu Kuroki. Role of impairment of blood supply of the femoral head in the pathogenesis of idiopathic osteonecrosis. Clin. Orthopaedics & Relat. Res., 277 (April 1992).

- [4] D. Kamal, R. Traistaru, D.O. Alexandru, D.C. Grecu, L. Mogoanta. Epidemiologic study of avascular necrosis of femoral head; *Curr. Health Sci. J.*, 39 (3) (2013).
- [5] E.J. Baixauli, F. Baixauli Jr., F. Baixauli, J.A. Lozano. Avascular necrosis of the femoral head after intertrochanteric fractures; *J. Orthop. Traum.*, 13 (1999), pp. 9-12.
- [6] L.Y. Shih, T.H. Chen, W.H. Lo. Avascular necrosis of the femoral head. An unusual complication of an intertrochanteric fracture; *J. Orthop. Traum.*, 6 (1992), pp. 382-385.
- [7] A. Barquet, G. Mayora, J.M. Guimaraes, R. Suárez. Avascular necrosis of the femoral head following trochanteric fractures in adults: a systematic review. *Injury*, 45 (12) (2014 Dec), pp. 1848-1858.
- [8] J.C. DeLee. Fractures and dislocations of the hip. Rockwood, Green, Bucholz (Eds.), *Fractures in Adults*, Lippincott Raven, Philadelphia (1996).
- [9] D.E. O'Malley, J.M. Mazur, R.J. Cummings. Femoral head avascular necrosis associated with intramedullary nailing in an adolescent. *J. Pediatr. Orthop.*, 15 (1995), pp. 21-23.
- [10] C. Vicario, F. Marco, L. Ortega, M. Alcobendas, I. Domínguez, L. López-Durán. Necrosis of the femoral head after fixation of trochanteric fractures with Gamma locking nail. A cause of late mechanical failure; *Injury*, 34 (2003), p. 129.
- [11] E.Y. Cheng, I. Thongtrangan, A. Laorr, K.J. Saleh. Spontaneous resolution of osteonecrosis of the femoral head; *J. Bone Jt. Surg. Am.*, 86 (2004), pp. 2594-2599.
- [12]. Revision of total hip replacement surgery in elderly patient and its recovery based on periprosthetic fracture rehabilitation [Internet]. [cited 2021 Dec 8]. Available from: http://www.discoveryjournals.org/medicalseience/current_issue/v24/n104/A114.htm
- [13]. Zade R, Deshmukh M. A Comparative Study Based On Two Stretching Protocol for Piriformis Tightness: A Research Protocol -. *Journal of Critical Reviews*. 2019;6(6):911-4.
- [14]. Dhankar. A case of fracture shaft femur in a patient with transtibial amputation [Internet]. [cited 2021 Dec 8]. Available from: <http://www.journaldmims.com/article.asp?issn=0974-3901;year=2019;volume=14;issue=4;spage=394;epage=396;aulast=Dhankar>
- [15]. Gaur VV, Kapoor AA, Phansopkar PA. Short Term Effects of Muscle Energy Technique vs. Active Release Technique in Improving Hamstring Flexibility and Pain in Patients with

Acute Anterior Cruciate Ligament (ACL) Tear - A Randomized Control Trial. jemds. 2021 Jan 18;10(3):137–42.

- [16]. Vaidya L, Naqvi W, Awasthi A, Kumar K, Phansopkar P. Achievement of Functional Independence in a Patient with Sickle Cell Disease with Autoimmune Hepatitis, Osteomyelitis, Wilson’s Disease, and Pathological Fracture Following Physiotherapy. jemds. 2020 Oct 26;9(43):3271–5.

UNDER PEER REVIEW