

Case study

Necrotizing fasciitis of the breast and Leukemoid reaction in an Immunocompetent Female: An unforeseen misadventure of LONG COVID syndrome?

Abstract

Necrotizing fasciitis are infrequently encountered but highly fatal group of infections. They are the infection of any of the three layers of soft tissue compartments which includes the dermis, subcutaneous tissue, superficial fascia, deep fascia or the muscle along with necrotising changes. During the initial stages it might be tricky to differentiate cellulitis and other infections of the superficial skin from necrotising fasciitis leading to an delay in the diagnosis. Prompt diagnosis and management can reduce mortality. This case report highlights a previously unreported presentation of necrotising fasciitis of breast in the form of leukemoid reaction encountered in the rural central India.

Keywords – Necrotising fasciitis, Leukemoid reaction, long covid syndrome

INTRODUCTION-

Necrotising fasciitis although being very uncommon presenting infective condition of fascia, muscle, subcutaneous tissue and overlying skin is associated with higher fatality. (1,2). Diagnostic delay is the reason behind its impending life threatening presentation because progression of infection causing bacteria is rapid which makes early detection of disease very important. Different varieties of NF are classified depending on the causative organism for ex. streptococcus, staphylococcus, MRSA and others. (1). Early presentation of necrotising fasciitis being pain and pyrexia makes it difficult to diagnose. Late course being development of purple coloured bullae, sloughing of skin and subsequent toxicity. (3)

Comment [BD1]: There are several grammatical mistakes in the paper. Please correct.

Comment [BD2]: grammar

Comment [BD3]: a

Comment [BD4]: grammar

Comment [BD5]: Why difficult? Please clarify more. I understand what you are trying to point out but you should be more clear

Comment [BD6]: Improve flow of the sentence

A leukemoid reaction is described as a white blood cell value more than 50,000 cells/mL associated with an increase in immature forms of neutrophils.(4).

The incidence rate of necrotising fasciitis per 100,000 population per year is 0.40 across the globe.(5)According to CDC, the mortality rate of necrotising fasciitis is 24 to 34 per 100 cases, while in India it is 7 to 76 per 100 cases. In leukemoid reaction the incidence is 59 per 10000 cases.(6)(7).

Comment [BD7]: Check statistics

One of the common factors associated with both leukemoid reaction and immunosuppression is COVID-19. Coronavirus infectious disease 2019 leads to suppression of immunity due to dysregulation of the immune system. Also, there have been reports of COVID-19 associated leukemoid reaction.(8)

Comment [BD8]: Improve flow of the sentence

Here we report a case of necrotizing fasciitis of left breast in an 57 year old lady presenting with leukemoid reaction as a result of long covid syndrome which was managed with surgical debridement and antibiotics successfully.

CASE REPORT-

A 57-year-old female patient presented to the emergency department, with chief complaint of fever and lesions over the breast since 10 days. The lesions were multiple fluid filled bullae which were associated with burning pain, itching sensation worsening over 6 days and spontaneous bursting. These lesions were not associated with active bleed or discharge or local rise of temperature.

Comment [BD9]: For 10 days

Comment [BD10]: Flow

She had a past history was covid 19 infection with a HRCT score of 10/25 four months back which was managed with remdesavir and intravenous steroids (injectable dexamethasone 6mg iv tds for 14 days). There was no history of any other co-morbidities.

Comment [BD11]: ?

On examination, she was well oriented to time place and person, her blood pressure was 110/70 mm Hg, pulse was 90 bpm, regular, normal volume, afebrile, chest was bilaterally

clear,normal heart sounds present,abdomen was soft and non tender and there was no focal neurodefecit.

On local examination, multiple fluid filled bullae were notedon medial aspect of left upper arm, along with granulation tissue and blackening of surrounding skin over the left breast (figure 1)

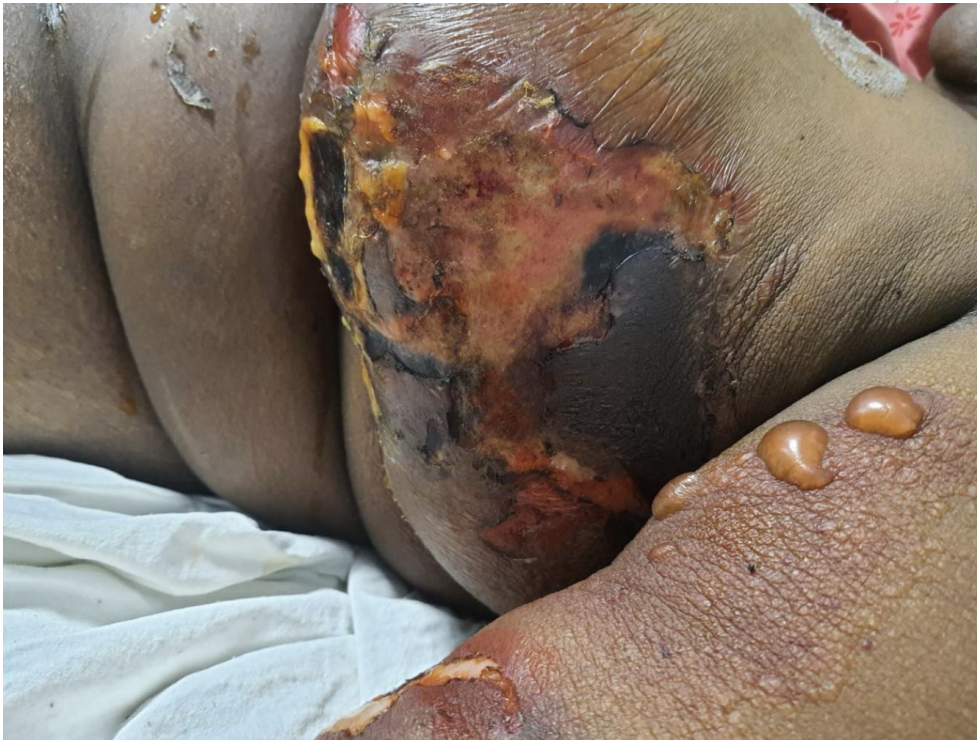

Figure 1:Showingmultiple fluid filled bullae along with granulation tissue and blackening of skin over the left side of chest

INVESTIGATIONS

Laboratory investigation	Measured Value
Complete Blood Count	Hamoglobin- 10.2 gm/dl
	Mean copurscular volume-78fl

	Total leukocyte count - 85,300/ μ L , with myeloblasts: 02 % , promyelocytes 05 % , myelocytes 18 % , metamyelocytes 17 % , band forms 15 % , neutrophils 28 % , eosinophils 06 % , basophils 02% , lymphocytes 05 % platelet count -1.36
Interleukin 6	112 pg/mL (normal range<7 pg/mL)
Renal function test	urea 127mg /dl (normal range 7-25), serum creatinine 2.2mg/dl (normal range 0.6 - 1.1)
Liver function test	Alkaline Phosphatase 176 IU/L (normal range 35-130), Alanine aminostransferaseT 32 IU/L (normal range 5-40), Aspartate aminotransferase-79 IU/L (normal range 5-40).

Table 1: showing laboratory investigations of the case .

Blood culture growth of coagulase negative staphylococci was noted.

On urine culture there was no growth

Wound culture showed growth of Acinetobacter species .

Antibiotic-sensitivity report for CONS showed resistance to antibiotics like Ciprofloxacin, clindamycin, Erythromycin and sensitivity to Linezolid, Vancomycin and

Tetracycline. Antibiotic-sensitivity report for Acinetobacter species showed resistance to Amikacin, Ceftazidime, Ciprofloxacin, Imipenem, Piperacillin_Tazobactam and sensitivity to Colistin.

Skin biopsy showed severe deep neutrophilic panniculitis and mild myositis with necrosis (**figure 2**). Cultures from the fat and muscle biopsy remained negative.

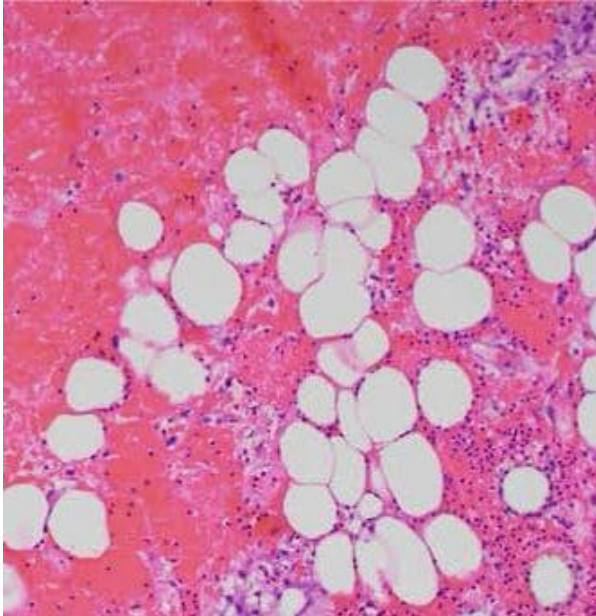


Figure 2: Histopathological examination of skin biopsy showing neutrophilic panniculitis and necrosis suggestive of necrotising fasciitis

Treatment –

The patient was admitted for suspected necrotising fasciitis and intravenous antibiotics were administered (injectable colistin 3 million international units thrice a day, piperacillin/tazobactam 4.45gm intravenous thrice a day and injectable metronidazole 100ml intravenous thrice a day)

Lab values after 5 days of admission showed Haemoglobin of 9.3 (normocytic anaemia), gradual improvement in leucocytosis TLC value 20200/ μ L (neutrophilic leucocytosis without toxic granules and cytoplasmic vacuolations) and thrombocytosis (platelet count >4.5 lakh/cumm). Surgical debridement was done for the necrotizing fasciitis along with other supportive measures.

Outcome-

Patient improved gradually and was discharged after day 23 of admission in satble condition and is presently doing well on follow up.

Discussion –

Necrotising fasciitis is most commonly associated with streptococcal and staphylococcal infection along with spectrum of other organisms. Etiology of necrotizing fasciitis is not fully understood making it difficult to treat resulting in high mortality. Although some etiological factors linked are penetrating or blunt trauma, surgery, soft tissue infections, IV drug abuse, childbirth, muscle injuries or burns. Predisposing factors such as trauma, insect bite, abrasions, etc. Disease can occur at any age and is most commonly seen in male population. Pre-existing conditions like immunocompromised state, steroid use, advanced age, malignancy, chronic kidney disease, obesity, vascular disease, diabetes mellitus make the patients susceptible to infection (1).

Most commonly affected parts are extremities, trunk, perineum but can involve any body part. Signs of inflammation are observed at the site of lesion. Extreme pain not related to local findings but in relation with toxicity of system is observed (2).

With the progression of infection, changes like erythematous, tense skin with not very well defined margins of lesion is seen. Sequential colour changes of lesion from redpurple to dusky blue which progresses to necrosis and bullae formation and eventually haemorrhagic sequelae. On palpation of affected area crepitus is noted and plain radiograph may also show soft tissue air (3). The period of symptom presentation varies from hours to several days.

Complications present with late stage systemic involvement, toxic shock and sepsis usually, and it imposes diagnostic challenges due to reduced GCS score.

Comment [BD12]: Please check all the references again and correct discrepancies.

Early clinical findings in necrotising fasciitis include loss of superficial skin sensations, pain, swelling, localized hardening of soft tissue, cellulitis, unknown origin of fever, increased heart rate.

Advanced stage features like extreme pain, skin colour changes, sequelae like haemorrhagic bullae, also crepitus can be palpated. Complications like severe sepsis or toxic systemic involvement like multiorgan failure have also been reported (3).

Investigations like FNAC and incisional biopsy can be performed. MRI and CT scan can be used to differentiate from equivocal findings. There is no lab parameter specific for necrotising fasciitis identified till date, but there has been a proposition of a Laboratory Risk Indicator for Necrotizing Fasciitis score (LRINEC) to categorise the risk of the same (3).

Treatment includes a course of IV antibiotics. Other controversial therapies suggested for treating are hyperbaric oxygen and intravenous immunoglobulin. Surgical debridement down to the fascia and muscle can be performed. Gram's staining and culture of the biopsy can be used in identifying the causative organism like GAS, mixed aerobic and anaerobic bacteria, MRSA, etc.

Risk factors of Type 1 NF include immunocompromised state, steroid use, advanced age, malignancy, chronic kidney disease, obesity, vascular disease, diabetes mellitus make the patients susceptible to infection. Risk factors for Type 2 NF are unknown, it can be seen in any age group and even in healthy patients. Pantone-Valentine leukocidin (PVL) toxin which reportedly causes necrotizing fasciitis is produced by MRSA strains. Early presentation of necrotising fasciitis being pain and pyrexia makes it difficult to diagnose. Late course being development of purple coloured bullae, sloughing of skin and subsequent toxicity. In advanced stages, extensive blood vessel thrombosis in the dermal papillae is observed. Advancement of infection down to the deep fascia gives the tissue a grayish brown appearance. Lymphatic and venous spread also occurs in advanced stages.

The term leukemoid reaction was coined by Krumbhaar for the conditions which were non-leukemic however mimicked leukaemia on the blood picture (4). It can be defined as a leukocyte count which is more than 50000/cumm along with increase in mature leukocytes as well as a differential count showing left shift (8). Drugs which can cause leukemoid reaction include steroids, minocycline and recombinant haematopoietic growth factors. Leukemoid reaction is commonly associated with infections such as bacterial diseases including disseminated tuberculosis, pneumonia, colostridium colitis and shigella dysentery. Viral infections such as human immune deficiency virus, cytomegalovirus and parvovirus B19 are also known to cause leukemoid reaction. Parasitic causes of leukemoid reactions include visceral leishmaniasis, malaria and trichinosis. Tumours of the gut, lung, pancreas and Hodgkin's lymphoma are also causative factors for leukemoid reaction. Our patient was not on steroid currently and had no history of any other drug intake. That makes viral infection the likely cause of leukemoid reaction.

In our case the patient was immunocompetent female with no history of diabetes mellitus with steroid use in the past of only fourteen days which was four months back making it unlikely the cause of immunosuppression.

Our patient had history of COVID-19 however developed leukemoid reaction and immunosuppression resulting in opportunistic infection resulting in necrotising fasciitis. A similar case of leukemoid reaction following remission of COVID-19 was reported by Nekooghadam et al (9). Long Covid syndrome is defined as persistence of inflammation in patients who recovered from COVID-19 for a period of more than three months.

In a study conducted by Zhou et al. it was reported that patients who were older and had chronic illness developed leucocytosis with COVID-19 (10). Also, patients who had COVID-19 and developed leucocytosis were found to have an increased level of interleukin 6 in the serum when compared to patients who did not have raised leukocyte counts. Interleukin 6

leads to Th17 cells differentiation from the native CD4 T cells and these Th17 cells in turn produce an inflammatory response by producing IL-17A and IL-17F which lead to migration of neutrophils, recruitment as well as activation. These recruited neutrophils cause cytokine storm as well as damage to the tissues and severe pneumonia. Therefore, neutrophilia can be a finding in patients who contract COVID-19 and require intensive care.

Also, COVID-19 can result in dysregulation of the immune system. There have been reports where COVID-19 has resulted in immune suppression leading to opportunistic infections as long COVID sequelae (11). Natural barriers which provides protection against opportunistic pathogens is disrupted by the severe acute respiratory syndrome coronavirus 2 as a result of down regulation of the proteins which form the tight junctions namely Occludin, Claudin 2,3,11 and 19, cingulin, Afadin, Rho GTPase-activating protein 17 and cAMP-dependent protein kinase catalytic subunit alpha (PRKACA). Hence, COVID-19 infection can alter the innate immune barriers causing superinfections from opportunistic pathogens. This might have been the cause of necrotising fasciitis in our patient who was otherwise immunocompetent before contracting COVID-19 infection.

Conclusion

Therefore we conclude that LONG COVID syndrome can in turn lead to varied presentations in the form of necrotizing fasciitis and leukemoid reaction even after the patient tests negative for COVID-19. Hence, there should be strict vigilance by the clinicians in order to detect these complications at the earliest and to prevent morbidity as well as mortality.

References

1. Dapunt U, Klingmann A, Schmidmaier G, Moghaddam A. Necrotising fasciitis. *BMJ Case Rep.* 2013 Dec 10;2013:bcr2013201906.
2. Hasham S, Matteucci P, Stanley PRW, Hart NB. Necrotising fasciitis. *BMJ.* 2005 Apr 9;330(7495):830–3.
3. Chen LL, Fasolka B, Treacy C. Necrotizing fasciitis: A comprehensive review. *Nursing.* 2020;50(9):34-40. doi:10.1097/01.NURSE.0000694752.85118.62

4. Ellison TA, Mandal K. Leukemoid reaction: Case report. *J Thorac Cardiovasc Surg*. 2018 Apr;155(4):e117–8.
5. Shimizu T, Tokuda Y. Necrotizing Fasciitis. *Intern Med*. 2010;49(12):1051–7.
6. Centers for Disease Control and Prevention [Internet]. [cited 2021 Oct 29]. Available from: <https://www.cdc.gov/>
7. K.C P, K.C P, H B. Evaluation of LRINEC Scoring System for Diagnosis of Necrotizing Fasciitis in Patients Presenting with Soft Tissue Infections. *J Evid Based Med Healthc*. 2020 Aug 31;7(35):1823–8.
8. Godhiwala P, Acharya S, Jagtap G, Bhake A, Shukla S. Leukemoid Reaction in a COVID-19 Patient. *J Evol Med Dent Sci*. 2021 Feb 8;10:399–400.
9. Nekooghadam S M, Moradi A, Karimi Toudeshki T, Pishgahi M. A Case of Acute Leukemia Following Remission of COVID-19 Infection; an Urge to Search for a Probable Association. *Arch Acad Emerg Med*. 2021; 9(1): e51, DOI: <https://doi.org/10.22037/aaem.v9i1.1338>.
10. Zhao, K., Li, R., Wu, X. *et al*. Clinical features in 52 patients with COVID-19 who have increased leukocyte count: a retrospective analysis. *Eur J Clin Microbiol Infect Dis* **39**, 2279–2287 (2020). <https://doi.org/10.1007/s10096-020-03976-8>
11. Talwar, D. ., Kumar, S. ., Acharya, S. ., Madaan, S. ., & Hulkoti, V. . (2021). COVID-19 Induced Immunosuppression resulting in Pulmonary Mucormycosis : A Long COVID sequelae. *Journal of Medicine*, 22(2), 150–154. <https://doi.org/10.3329/jom.v22i2.56707>