

Review Article

Placement of Implant with Allograft Vertical Ring- A Review

Comment [IRC1]: Please rewrite the article with importance to the grafting techniques, the procedures used and review prior publications. Then move into your choice of procedure.

Abstract:

Implant placement is getting space day by day. However, in every case, we never get the ideal condition of alveolar bone for implant placement. Alveolar bone loss is seen due to periodontitis, tooth loss, tooth extraction and periapical infection etc.

Resorption of alveolar bone varies among person to person and side to side. It has been noted that the size of the residual ridge shrinks more quickly within the first six months.

There is new demand for reconstruction of alveolar ridge for implant placement. Various techniques are available for increasing the ridge height and width by using bone graft, membrane etc., one of these is vertical ring procedure.

Bone ring technique (BRT) has been described as a one-stage approach to restore vertical ridge height defects, in which an autogenous or allogeneic bone block graft is used and implant is placed simultaneously.

The aim of this review is to focus on importance of the implant placement, consequences of complete edentulism, problem with removable partial denture (RPD) placement, as a result of bone loss in fully edentulism patient and use of vertical ring technique for the implant placement.

KEYWORDS- vertical ring, implant, periodontitis, allograft, implantology, bone grafts.

Introduction-

Dental implant is a material made up of alloplast, implanted into the oral tissues under the mucosal or/and periosteal layer, and on/or within the bony envelope to aid in retention and support to a fixed or removable dental prosthesis.¹

Types of Implant

Endosseous Implants

- 1)Bladelike
- 2)Pins
- 3)Cylindrical hollow and Cylindrical full
- 4)Disclike
- 5)Screw shaped
- 6)Tapered shaped

2) Subperiosteal frame like implants

3) Trans-mandibular implants²

Why Implant Placement Is Important?^{3,4,5,6}

The implant placement is important to preserve the alveolar bone, maintain the vertical dimension, occlusion, improves mastication. However, if early tooth loss occurs, partially or complete edentulism can lead to the consequences that are:

1. Continue loss of bone of jaws
2. Undesirable changes in the soft tissues of the jaws
3. Undesirable facial feature changes
4. Reduced masticatory process
5. Issues related to psychology
6. Decreased width and height of the supportive bone

7. Protruding mylohyoid as well as internal oblique ridges and amplified sore spots
8. Advanced loss of keratinized mucosa area
9. Protruding superior genial tubercles with sore spots and augmented denture movement
10. Muscle attachment neighbouring crest near the ridge
11. Raise of the prosthesis as well as the reduction of mylohyoid as well as buccinator helping in latter provision
12. Frontward elevation of the prosthesis from normal inclination
13. Thinning of mucosa which leads to the sensitivity from abrasion
14. Paraesthesia in mandibular neurovascular part
15. Increased role of tongue in mouth
16. Changes in esthetics of last third of face due to loss of bone
17. Maximum risk of mandible fracture of the body from accelerated bone loss.
18. Increased changes of denture and sore spots due to reduction of anterior ridge as well as nasal spine
19. Labiomental angle is loss
20. Skin of the lips and face are deepened.
21. Chin apparently moves forward and then face have a prognathic view
22. Horizontal angle of lip is decreased changing the rest expression of patient
23. Loss of tonicity in muscles responsible for facial expression
24. Advance columella-philtrum angle
25. Thinning of vermilion border as a result loss of muscle tone
26. Nasolabial groove appears deep
27. Dimension of maxillary lip is increased,

However, if some teeth are retained by doing the periodontal therapy or conservatively therapy and had a partial edentulism. For these we generally use removable partial denture (RPD) in those conditions where fixed partial denture (FPD) cannot be given. However, there are several problems related to RPD, they are as followed: ⁶

Comment [IRC2]: Please reformat the sentence.

1. Low rate of survival of more than 60% in 4 years.
2. 35% rate of survival in 10 years
3. Rate of restoration of abutment of at least 60% in 5 years as well as 80% in 10 years
4. Advance mobility as well as plaque accumulation, bleeding on probing, and caries in underlying supporting abutment teeth
5. 44% loss of underlying supporting abutment teeth in the span of 10 years
6. Faster loss of bones in edentulous area if the patient wears RPD

Advantages of Single Tooth Implant ⁷

1. Increased success rate (above 97% in span of 10 years)
2. Reduced chances of caries to the next teeth
3. Increased capability to clean the proximal areas of the adjacent tooth
4. Increased esthetics of next tooth
5. Increased lifespan of alveolar bone in the area where teeth are absent
6. Decreased cold as well as contact sensitivity to the adjacent tooth
7. Psychologically healthy patient
8. Decreased risk of loss of next tooth

Alveolar Bone Height

The height available is calculated by evaluating the radiograph in ideal edentulous area where placement of implant is intended. When one or couple of teeth is missing then periapical radiograph is of sufficient use to estimate the available alveolar bone height.

Generally, the anterior part of mandible has the highest bone height. The bone is dense in the mandible anterior area. Even when the resorption of the bone takes place after loss of tooth there is enough bone to have the implant. The areas with greater forces and where naturally wider teeth were present with 2 or 3 roots, also some shorter size implants, are generally used and are usually lesser in number because of the limited anatomy.

Oikarinen et al. had said that if there is more than a 6mm of height of bone is seen in as less as 50% of the posterior mandible and 40% in the posterior maxilla in partial edentulism patient. The available bone height is most critical criteria for implant placement because it has impact on both implant length and also height of the crown.⁸

Table 1: **TYPES OF BONE DENSITY IN MAXILLA AND MANDIBLE**

A)Misch's Bone Density Classification Scheme⁹

Density of the bone	Description	Physical Equivalent	Standard Anatomical Site
D1	Densely corticated	Oak, Maple wood	Anterior area of mandible
D2	Porous cortical and coarse trabecular	White pine as well as spruce wood	Anterior area of mandible Posterior area of mandible Anterior maxilla
D3	Porous cortical and fine trabecular	Balsa wood	Anterior area of maxilla area of
D4	Finely trabecular	Styrofoam	Posterior area of maxilla

Comment [IRC3]: Please reformat the sentence.

Table 2. GENERALIZED BONE DENSITY LOCATION ¹⁰

Anterior area of Mandible	D2
Posterior area of Mandible	D3
Anterior area of Maxilla	D3
Posterior area of Maxilla	D4

Table 3. COMPUTED TOMOGRAPHY DETERMINATION OF BONE DENSITY ¹¹

D1	>1250 Hounsfield units
D2	850-1250 Hounsfield units
D3	350-850 Hounsfield units
D4	150-350 Hounsfield units
D5	<150 Hounsfield units

Table 4. Initial Bone in Relation to Implant Contact Percent (BIC%) ¹²

DENSITY	BIC %
D1	85%
D2	65-75%
D3	40-50%
D4	30%

*: Bone To Implant Contact

Comment [IRC4]: How does it get affected by grafting procedure?

Table 2: BONE GRAFT-

a) **Types of bone graft** ¹³

Table 5. Various Graft Material

1) Autogenous Bone Grafts	
a) Bone - Intraoral Sites.	b) Bone - Extraoral Sites
1) Osseous coagulum	1) Iliac Autografts
2) Bone Blend	
3) Cancellous Bone Marrow Transplants	
4) Bone Swagging	

2)Allografts	3)Xenografts
Freeze Dried Bone Allograft (FDBA)	Calf bone
Demineralized Freeze Dried bone Allograft (DFDBA)	Bio-Oss
	Bio-Guide

Nonbone Graft Materials
Sclera from the eye
Cartilages
Plaster of Paris (pop)
Plastic Materials

Calcium Phosphate Biomaterials- Hydroxyapatite (HA) and Tricalcium phosphate (TCP)
Bioactive Glass
Coral- Derived Materials

Table 6. **Biologic requirement for bone regeneration** ¹⁴

Requirement	Surgical Procedures
Blood supply	Cortical perforations
Wound coverage	Flap management, tension- free suturing
Stabilization	Fixation screws membrane tacks
Osteoblasts	Autogenous
Space maintenance	bone graft materials
Confined space	Barrier membrane

Table 7. **Biologic Properties of Various Bone Graft Materials** ¹⁵

Sources	Osteo-inductive	Osteoconductive	Osteogenic
Alloplast	No	Yes	No
Xenograft	No	Yes	No
Autograft	Yes	Yes	Yes
Allograft	Yes/No	Yes	No

Bone Regeneration:

With increasing pace of development in dentistry, there is increase demand for reconstruction of bone prior or during implant therapy in partially or fully edentulous patients with deficient jawbone, especially when the main concern is aesthetics.

Advanced loss of alveolar bone prevents the proper placement of implant in a prosthetic position can be due to tooth extraction, periodontal bone loss, tooth and also long term use of removable and fixed appliances.

Recent advances in implantology sometimes contradict the original standard procedures by placement of implants in such areas where adequate volume of bone is absent, simultaneously augmentation of bone and placing and loading the implants after a short healing periods.

Restoration of periodontal osseous defects can be done by various therapeutic grafting modalities. Materials that can be used for grafting can be obtained from the same individual that is called as an autograft, materials that are derived from different individual of same class are known as allografts and the ones derived from a totally different class are called as xenografts.

Bone graft materials are usually graded according to their osteogenic, osteoconductive or osteoinductive properties.

Osteogenesis- development of new bone with the help of cells in the graft.

Osteoinduction- chemical procedure by which the molecules present inside graft also known as bone morphogenetic proteins changes the surrounding cells in osteoblasts which leads to the form the bone.

Osteoconduction- It is a physical effect in which the matrix molecules of the graft leads to the formation of a scaffold that aids the outside cells to enter the graft and form new bone.¹⁶

Bone Ring Technique.

Comment [IRC5]: Are there other techniques, sudden mention of the technique? Please give details.

Various treatment modalities are available to increase the vertical height and horizontal width for the alveolar ridge defect. Successful implant placement has been seen in the ridge defect having the vertical height and horizontal width defect by using ridge augmentation methods. One of the recent technique which is use to increase the vertical height is Bone ring technique (BRT).

BRT has been described as a one-stage approach to restore vertical ridge height defects, in which an autogenous or allogeneic bone block graft is used and implant is place simultaneously. Various studies in relation with vertical bone ring technique has been performed.

Comment [IRC6]: Reformat sentence

Comment [IRC7]: Reformat sentence

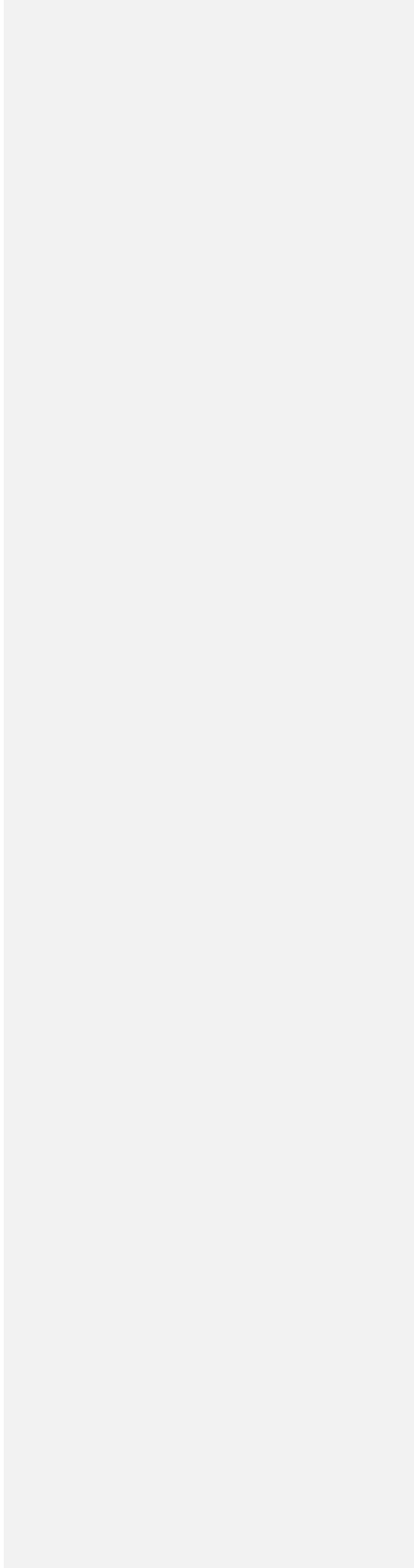
Table 8. Bone Ring Technique

Sr. no	Author (Year)	Title of study	Conclusion
1	Kerri Thomas Simpson et. al (2020) ¹⁷	Computer -Guided Surgery using the Allograft Ring Technique” with Simultaneous Implant Placement: a case report	The method of computer-guided technology for planning and placing of an allograft bone block and simultaneous insertion of implant aides for a prosthetically headed group approach to conciliated grafting

Comment [IRC8]:
Please remove table and write it along with the main text.

			at the site in addition to improve precision as well as accuracy as a comparison with no guided techniques.
2.	Robert J Miller et.al (2020) ¹⁸	Indications for Simultaneous Implantation and Bone Augmentation Using the Allograft Bone Ring Technique	The Allograft Ring Technique is utilised successfully to regenerate both the vertical and horizontal defects in the ridge following placement of implant . Many clinical situations occurs that can actually get the benefit from this technique ;however , case assessment is the key factor. Optimal three dimensional placing of implant is the ultimate guide to

			<p>surgical success and must be the prior analysed. The defect in the bone should be considered as the placement of the implant within the bone increases the chances of surgical success. An alternative that have two stage procedure should be considered when there is no possibility for restoratively driven placement. The standard factors that influence surgical success, including selection of the patient and the surgical judgement of</p>
--	--	--	--



			the dentist should not be overlooked. ¹⁹
3.	El Chaar E et al. (2021) ¹⁹	Bone Ring Allograft: Digitally Guided Placement in the Anterior Esthetic Area. A Retrospective Case Series	This case study shows a one-stage process in which a bone ring allograft as well as implant are placed for treating a severely damage ridge in the anterior region of maxilla. The technique is reliable to use in the esthetic zone, with minimal first-year loss of peri-implant bone

Comment [IRC9]: Is this a superscript to a reference , clarify?

CONCLUSION

Reconstruction of deficiencies in the alveolar bone , preservation of dimensions of alveolar bone, and replacement of loss teeth with dental implants in an aesthetic position with natural appearance, form can be achieved by bone augmentation and simultaneous implant surgery procedures. The desired outcome of this procedure also depends on various biologic principles

that should be taken in consideration. Diagnosis, treatment planning, clinical approach and treatment and also postoperative follow up, and appropriate implant loading are all deciding factors in achieving success.

References

1. Oral Implantology, V Rangrajan And Tv Padmanabhan, Textbook Of Prosthodontics, Second Edition, Elsevier, Pg. No. 726
2. Biological Aspects Of Oral Implants; Daniel Van Steenberghe, Marina Marechal, And Marc Quirynen, Carranza's Clinical Periodontology, Tenth Edition, Saunders Elsevier, 1073
3. Rationale For Dental Implants, Carl E. Misch , Dental Implant Prosthetics, Second Edition, Elsevier ,Pg No. 10
4. Rationale For Dental Implants, Carl E. Misch , Dental Implant Prosthetics, Second Edition, Elsevier , Pg No. 13

Comment [IRC10]: Formatting of all the references are not same.

5. Rationale For Dental Implants, Carl E. Misch , Dental Implant Prosthetics, Second Edition, Elsevier , Pg No. 16
6. Rationale For Dental Implants, Carl E. Misch , Dental Implant Prosthetics, Second Edition, Elsevier , Pg No. 8
7. Rationale For Dental Implants, Carl E. Misch , Dental Implant Prosthetics, Second Edition, Elsevier , Pg No. 7
8. Available Bone And Dental Implant Treatment Plans, Carl E. Misch , Dental Implant Prosthetics, Second Edition, Elsevier , Pg No. 318
9. Bone Density : A Key Determinant For Treatment Planning, Carl E. Misch , Dental Implant Prosthetics, Second Edition, Elsevier , Pg No. 242
10. Bone Density: A Key Determinant For Treatment Planning, Carl E. Misch , Dental Implant Prosthetics, Second Edition, Elsevier , Pg No. 244
11. Bone Density: A Key Determinant For Treatment Planning, Carl E. Misch , Dental Implant Prosthetics, Second Edition, Elsevier , Pg No. 245
12. Bone Density : A Key Determinant For Treatment Planning, Carl E. Misch , Dental Implant Prosthetics, Second Edition, Elsevier , Pg No. 247
13. Reconstructive Periodontal Surgery; Fermin A. Carranza, Henry H. Takei, And David L. Cochran, Carranza's Clinical Periodontology, Tenth Edition, Saunders Elsevier
14. Localized Bone Augmentation And Implant Site Development; Perry R. Klokkevold, Carranza's Clinical Periodontology, Tenth Edition, Saunders Elsevier, Pg No. 1134
15. Localized Bone Augmentation And Implant Site Development; Perry R. Klokkevold, Carranza's Clinical Periodontology, Tenth Edition, Saunders Elsevier, Pg No 1135

16. Localized Bone Augmentation And Implant Site Development; Perry R. Klokkevold, Carranza's Clinical Periodontology, Tenth Edition, Saunders Elsevier, Pg No 1133
17. Simpson Kt, Bryington M, Agosto M, Harper M, Salman A, Schincaglia Gp. Computer-Guided Surgery Using Human Allogenic Bone Ring With Simultaneous Implant Placement: A Case Report. Clin Adv Periodontics. 2020 Mar;10(1):16-22.
18. Miller RJ, Korn RJ, Miller RJ. Indications For Simultaneous Implantation And Bone Augmentation Using The Allograft Bone Ring Technique. Int J Periodontics Restorative Dent. 2020 May/Jun;40(3):345-352.
19. El Chaar E, Shi Y, Engebretson S, Zahedi D, Chang E. Bone Ring Allograft: Digitally Guided Placement In The Anterior Esthetic Area. A Retrospective Case Series. Int J Periodontics Restorative Dent. 2021 Nov-Dec;41(6):865-872.