

Case study

Ipsilateral neck/inter-trochanteric and mid-shaft femoral fractures treated with dual construct implants

Abstract

Background:

Various management protocols for ipsilateral neck/intertrochanteric and shaft fracture femur have been formulated, there have been many disagreements related to their ideal fixation plan. The aim of this study was to discuss the various type of fixation system available for such kind of complex injuries and the advantages of using dual construct fixation system.

Patient and methods:

In the present study we prospectively evaluated ipsilateral neck/intertrochanteric and shaft fracture femur in 7 cases -managed from January 2018 to December 2020. All the patients were managed with dual constructs fixation system using dynamic hip screw (DHS) and locking plate. The outcome was evaluated using Friedman and Wyman scoring system.

Results:

The average surgical time was 120.4 min (range 98–143 minutes) with a blood loss ranging from 290-565 mL (average 460 mL). In 6 patients follow-up was undertaken between 10- and 22-months after surgery, with a mean follow-up time of 16.2 months. 1 patient lost follow-up at 3-month. The neck/IT fractures achieved union in 6 patients at the final follow-up. 3-6 months was the duration for bone union, with an average of 4.1 months. The mid-shaft femur fractures achieved solid union in 6 cases at the most recent follow-up. 3 to 11 months was the duration of union, with a mean of 5.1 months. 1 patient went into non-union 11 months after the surgery. According to Friedman and Wyman scoring, 4 patients the functional outcome was good, in 2 patients the functional outcome was fair, and in 1 patient the functional outcome at the final follow-up was poor. The problems noted were surgical site infection in 1, Angulations (varus/valgus) of femoral neck in 1, non-union of neck femur fracture in 1, and avascular necrosis of femoral head in 1.

Conclusion: The management of ipsilateral neck/intertrochanteric and shaft fracture femur with dual construct implants dynamic hip screw for neck/IT fracture and locking plate for shaft femoral fractures yielded good union rates and good functional outcomes.

Keywords: Ipsilateral neck/intertrochanteric, shaft femoral fractures, Dual construct , fixation system

Introduction:

The index case literature of ipsilateral neck/inter-trochanteric and mid-shaft femoral fractures was noted in the year 1953 (1). From that point, orthopedic surgeons have concentrated their focus to this complex and multiple trauma pattern and gave guidelines related to its clinical diagnosis and management. ipsilateral neck/inter-trochanteric and mid-shaft femur fracture injury patterns are infrequent, amounts for an average 3.5–7% of femur fractures (2). Most presentations are caused by high-volume accidents, for example automobile road traffic accidents or falls, and are usually in associated with multiple systems such as head, chest, or abdominal associated injuries. 20-50% ~~percentage~~ cases also experience same side knee trauma (3).

Surgical fixation with various implant constructs for ipsilateral neck/inter-trochanteric and mid-shaft femoral fractures is advocated with many noteworthy literature, and numerous practices and choice of fixation device have been developed in management of such injuries (4). However, ideal management of such complicated fractures is still in discussion, with various surgical techniques and fixation device with variations in their own pros and cons.

Internal fixation device with clamp and rods CRIF (clamp and rod internal fixation) was discovered by the AO Development Institute based on biologic osteosynthesis concepts that emphasize the strength of the fracture site while retaining soft tissue integrity. However, bone-stabilizing strength is inadequate due to many lacunae in the locking construct between plate and screws; hence, CRIF (clamp and rod internal fixation) is not the best implant for osteosynthesis of these bones.(5) (6).

In this study we adopted a novel fixation device in the form of dual constructs containing a combination of dynamic hip screw and locking. The clinical and biomechanical studies analysis showcased acceptable results with this type of implant choice for fractures of the long bones (7). There are previous reports related to this type of management according to our research. According to the previous studies done and our knowledge related to the treatment of ipsilateral neck/inter-trochanteric & mid-shaft femoral fractures with dual construct implants (DHS and

locking plate), this prospective study was undertaken to evaluate this surgical technique and implant choice for the management ipsilateral neck/inter-trochanteric and mid-shaft femoral fractures

Clinical details

This study was a prospective analytical study with prior approval of the institutional ethics committee and board. 7 patients (5 mMale and 2 fFemale) were recruited in the study in the period of January 2018 till December 2020. Clinical parameters of patients have been given in detail in Table no. The average age of recruitment was 34.5 years (range: 27–45 years). Out of these 7 patient, 5 suffered through closed pattern of fracture and 2 suffered through open/compound pattern of injury (all were Gustilo I fractures). In these 7 patients the cause of injury/fracture was road traffic accidents in 6 patients and fall from a significant height in 1 patient. The fractures were also associated with some injuries like 1 patient had associated liver contusion and 1 patient had associated neurological trauma. In this study there were 4 intertrochanteric fractures and 3 neck of femur fractures. The inter-trochanteric fractures were classified using Boyd and Griffin classification system. According to which out of these 4 three were type I and one was type II and out of the 3-neck femur fracture which were classified based on gardens classification 2 were type I and 1 was type II There were 6 neck fractures, one trochanteric fracture. As per Garden’s classification, 1 femur neck fractures was type I, 4 type II, 2 were type III. Garden types I and II fractures are nondisplaced, but Garden types III and IV fractures are displaced (8). A subcapital fracture was one of the neck fractures, whereas the other two were basicervical fractures.. The shaft femur fractures were classified on the basis of Winquest and Hansen classification according to which 4 fractures were type I and 2 were of type II and 1 was of type III. In all the patients the diagnosis was done on the basis of clinical symptoms, X-ray, and computer tomography scan (CT). Clinical details mentioned in table no 1

Formatted: Highlight

Comment [PT1]: It lacked detailing criteria for the choice and exclusion of individuals used in these analyses.

No	Sex/age	MOI	Fracture shaft classification	Fracture neck /IT classification	Associated complication	Injury pattern
1	M/26	Road traffic	Winquist and	Boyd and griffin	-	Closed

		accident	Hansen type I	type I		
2	M/41	Road traffic accident	Winqvist and Hansen type I	Garden type II/Basicervical	-	Closed
3	M/29	Road traffic accident	Winqvist and Hansen type II	Boyd and griffin type II/Gustilo I	-	Open
4	F/35	Road traffic accident	Winqvist and Hansen type II	Garden type I/Basicervical	-	Closed
5	M/38	Road traffic accident	Winqvist and Hansen type I/Gustilo I	Garden type I/Subcapital	Brain injury	Open
6	F/48	Road traffic accident	Winqvist and Hansen type II	Boyd and griffin type I	-	Closed
7	M/28	Road traffic accident	Winqvist and Hansen type III	Boyd and griffin type I	Liver contusion	Closed

Table no 1 Clinical details

Formatted: Highlight

Comment [PT2]:

Pre-operative preparation

With the help of Steinman pin tibial skeletal traction was given immediately after to the patients immediately after admission to the hospital. Patients who had suffered an open/compound fracture in those patients through debridement, suturing and dressing was done, after which they were also given skeletal traction in tibia proximally. Additionally, cases having compound fractures were given IV (intra-venous) antibiotics 24 hours prior to surgery. Radiological examination in the form of X-ray and CT scans were done to identify fracture pattern and displacement to formulate a proper surgical plan. As soon as the patient obtained fitness for surgery from the concerned physician patient was undertaken for surgery.

Comment [PT3]: add information about the equipment used for these exams, manufacturer, model and others

Surgical procedure

The priority of fixation was given first to shaft femur fractures.

Patient was taken in lateral position on OT table, 8cm incision taken over the anterolateral aspect of left thigh over mid-shaft femur. Soft tissue dissection done and Fracture site exposed. Periosteum was elevated and fracture site was visualized. Under C-ARM guidance reduction achieved by traction manipulation. With the help of compression clamp the reduction of both fracture fragments was held and femur locking Plate was placed over

Comment [PT4]: ????

lateral surface of bone ~~Temporary~~ temporary fixation achieved by K-wire over the plate. After confirming the reduction and positioning of plate final fixation achieved by locking screws. Final rReduction was confirmed under fluoroscopic guidance and it was found satisfactory. Through lavage was done Drain was inserted and fixed and closure was done in layers.

After internal fixation of neck or IT fracture shaft femur was fixed.

Then the patient was made supine and again cleaning drawing and painting was done under all aseptic precaution to maintain the sterility.

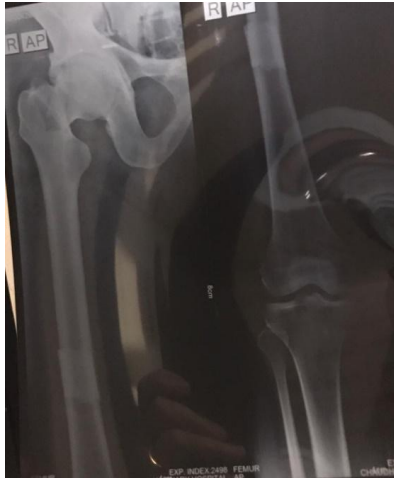Patient was taken into supine position over OT table. 10 cm horizontal incision was taken extending from greater trochanter distally along the anatomical femoral axis. Deep fascia was cut, ~~then~~ and then vastus lateralis was split. Guide wire was inserted in the femoral head centrally and postero-inferiorly and reaming was done using a triple reamer. Dynamic hip screw of particular size was inserted. Long barrel plate was fixed using bone holding forceps and fracture was stabilized. Top screw was inserted. Thorough wash given with normal saline. closure done in layers.

After internal fixation of neck or IT fracture shaft femur was fixed

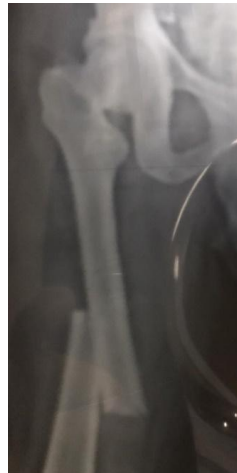Outcome assessment

To assess the outcome of this surgical exercise evaluation was done using Friedman and Wyman scoring system (9). A result was considered “good” if there was no limitation of movements or activities of patients daily living like going to bathroom taking shower etc, significant decrease in pain and the knee or hip movements are lost by less than 30%. A result was considered “fair” if there was mild limitation of movements or activities of patients daily living, mild to moderate decrease in pain and the knee or hip movements are lost between 30-50%. A result was considered “poor” if there was moderate to severe limitation of movements or activities of patients daily living, no decrease in pain and the knee or hip movements are lost between more than 50%. In rRadiological examination including X-rays and in some cases CT scans were carried out after an interval of 1 month post-surgery to visualise the union on bones until they show cased solid and organised callus formation. Depending on previous literature (10), the union at femoral neck and intertrochanteric fractures was said to be adequate if both antero-posterior and lateral X-rays show union in three to four cortices and had trabecular bridging present. When the patient can bear full ~~-~~body weight without any pain or radiological fusion of the fracture was noted, uUnion at mid-shaft femoral fracture was considered. If the radiological graphs showed consolidated callus around the fracture by 6 months post-surgically. When union at fracture site was not present by 12 months, the fracture was classified as non-union. Another parameter which was taken into consideration was if the patient was able to walk weight bearing. If the fractures didn't show above mentioned signs by six months it was considered delayed union and after 9 months was considered as non-union.

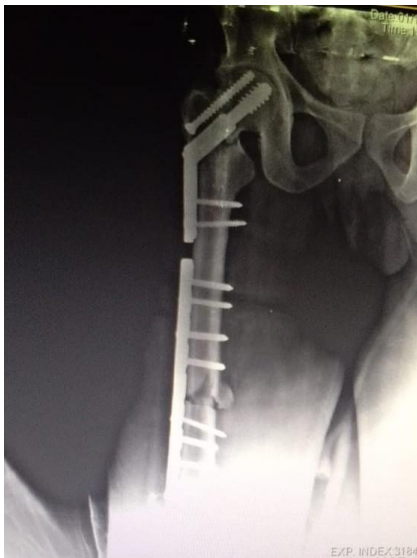
Comment [PT5]: was the treatment material the same for all patients?



Pre-operative Xray (fig 1)



(Fig 2)



Post-operative Xray (fig 3)

Comment [PT6]: Add infromations about figures 1, 2 and 3

Formatted: Highlight

Formatted: Highlight

Results

The average surgical time was 120.4 min (ranged 98–143 minutes) with a blood loss ranging from 290-565 mL (average 460 mL). In 6 patients follow-up was undertaken between 10- and 22-months after-surgery, with a mean follow-up time of 16.2 months. One patient lost follow-up at 3-month. The fractures of neck-IT achieved union in 6 patients at the final follow-up. 3-6 months was the duration for bone union, with an average of 4.1 months. The mid-shaft femur fractures achieved solid union in 6 cases at the most recent follow-up. 3 to 11 months was the duration of union, with a mean of 5.1 months. 1 patient went into nonunion 11 months after the surgery. According to Friedman and Wyman scoring, 4 patients the functional outcome was good, in 2 patients the functional outcome was fair, and in 1 patient the functional outcome was poor at the final follow-up. The problems noted were surgical site infection in 1, angulations (varus/valgus) of femoral neck in 1, femoral neck fracture landing in non-union in 1, and avascular necrosis of femoral head in 1 ([Table 2](#)). [Results mentioned in table no 2](#)

Comment [PT7]: Don't limit yourself in the results to presenting only the data related to what is already said in the table. verify the possibility of performing statistical tests to correlate the data.

No	Delayed diagnosis	Time to surgery	Operation time	Blood loss	Follow up (months)	Neck union (months)	Shaft union (months)	Outcomes	Complications
1	-	3	105	450	18	3	3	Good	-
2	5	11	98	506	22	3	6	fair	Surgical site infection
3	-	5	123	550	18	4	4	good	-
4	-	6	130	289	10	5	11	poor	Angulation at femoral neck
5	5	3	143	423	12	4	3	good	-
6	-	8	116	563	21	6	5	Poor	Osteonecrosis
7	-	11	128	444	lost	6	4	good	-

Table no 2: Results mentioned

Comment [PT8]: perform statistical tests on the data if possible. add caption, improve table title

Discussion

Although ipsilateral neck/inter-trochanteric and mid-shaft femoral fractures are not common, they are considered as challenging in terms of their diagnosis and management for orthopaedic surgeons. In this reported case series maximum of the patients were young male who suffered high volume trauma. As the prevalence of these kinds of injuries in road traffic accidents leading to vehicle crash and trauma is sustained by the passengers seated in the front and driver seat, ~~Typically~~ typically the mechanism of trauma is reported to be the result of a compressive force longitudinally on hip with flexion and abduction. The mid-shaft femoral fractures are mostly comminuted, diaphyseal in location and are compound/open in 20-30% patients. The neck of femur fractures are mostly basicervical in location with vertical orientation without displacement in 50% on patients (11).

The fractures of the proximal femur and usually missed or diagnosis is delayed in around 20-30% of patients, and the incidence of missed diagnosis may be 14–34% (12). The difficulty in early diagnosis of the disease is due to the basilar pattern of fracture in neck femur and the symptoms are generally mild in nature early on in this type of injury. Further adding to these surgeons tend to give more importance to the graver type of injuries mostly associated with neck femur fracture like in injuries around chest, head and abdominal (4). Therefore, it is mandatory to screen the pelvis in patients with mid shaft femur fractures. ~~In addition to that CT scans should be performed if it is~~ Additionally, CT scan examination can be done if needed.

However, CT scans are generally not ordered in cases suspected of femoral neck fractures pre-operatively (13). For screening of occult fractures around the hip joint sound waves via objective ultrasound can be used (14). However, recently a study has shown that rapid limited-sequence pelvis MRI for patients with femoral mid-shaft fractures could help in the diagnosis of neck/IT femur fractures that were missed on high-resolution CT scan with thin cuts (15). Conservative management of either the neck/inter-trochanteric femoral fractures or mid-shaft fracture is usually never planned except some exceptions like debilitated condition, very old age and unwillingness of the patient (16) (24). Many surgical management protocols have been formulated for this kind of injury pattern. Orthopedic surgeons need to take into consideration three issues which will help to come to an optimal surgical plan leading to successful management of these patients

Comment [PT9]: this non-request may be related to the higher cost of this clinical examination.

Comment [PT10]: ????

Comment [PT11]: ?????

- (1) The timing of the fracture fixation;
- (2) Which fracture fixation should be given priority;
- (3) The appropriate choice of implants to be used.

The whole logic behind the surgical management of ipsilateral neck/inter-trochanteric and mid-shaft femoral fracture is to attain anatomical reduction and rigid fixation of

both fractures. So as soon as the patient's general condition is stabilised and patient is fit to undergo surgery early fixation and reduction of this type of complex injury pattern are mandatory. There is no written rule or solid studies proving which fracture should be stabilised first. Some of the reports have recommended that the neck of femur fracture should mostly be fixed with priority, as these fractures are non-displaced or minimally displaced, to neglect displacement of a undisplaced or minutely displaced fracture and to make sure the anatomic reduction and stable fixation of the neck, preventing avascular necrosis and non-union.

Some of the reports have advocated that stabilisation of the femoral shaft fracture should be done first which allows good control of the leg when there is a more challenging and technically demanding femoral neck/inter-trochanteric reduction. In our study, we gave preference of fixation depending upon the femoral neck fracture pattern. The strategy of temporary fixation of non-displaced neck fracture in situ should be done first to prevent further displacement. Otherwise, the mid-shaft femoral fractures should be given priority in fixation for better control of the leg during the reduction of the displaced neck/inter-trochanteric fracture.

Many types of implant constructs and surgical procedures have been reported in the management of ipsilateral neck/inter-trochanteric and mid-shaft femoral fractures, which includes single and dual constructs for both the fracture patterns

Reconstruction intramedullary nails with interlocking screws for neck/inter-trochanteric fracture fixation, long proximal femoral nails (PFN-long) with De-rotation screws, long dynamic hip screws, and long proximal femoral locking plates are examples of single constructs. (17), (10), (11), 17 and (18),

Retrograde femoral intramedullary nails with cannulated cancellous screws (16); Antegrade femoral intramedullary nails with cannulated cancellous screws are examples of dual constructs implant (Parfenchuck, Carter and Young, 1993). In comparison to single construct implant, dual construct implants show many advantages, such as the immobilisation is easier and can achieve biomechanically superior fixation (17)-(19), their practical application is restricted by various complications related to the knee, non-union of fractures (particularly in retrograde nailing with DHS or lag screws), greater amount of reduction manipulative forces leading to greater intraoperative trauma, and expensive implant cost (20).

In the fractures of neck/inter-trochanteric and mid-shaft femur the incidence reported in numerous case studies is 1.5-6% (21). The ~~chances of non-union in this kind of fractures~~ is chances of non-union in this kind of fractures are also common. A similar study in which 95 cases were managed with screw fixation for femoral neck fracture and a intramedullary nail in retrograde manner for mid-shaft femur fracture the rate of non-union in this case study was 6% (22)-(23). In many of the published case reports the complications regarding the femoral mid-shaft fractures were more common than for the neck. In comparison to the isolated femoral mid-shaft fractures, have a high mean time for union (19.4-26.1 weeks) and high chances of non-union 2-24% and malunion 1.7-36% (24) (25). These variations in results occur due to the choice of different management protocols formulated for this type of injury pattern. In our study, only one case had avascular necrosis of the femoral head and only 1 case went into non-union and 1 in malunion respectively. All of the results were in relation to the previous reports.

In comparison to the other treatment protocols, the dual construct implant with DHS and locking plate was a relatively easy procedure. According to literature in a case study with 43 patients of ipsilateral neck/IT with mid-shaft femur fracture used four different surgical methods 1) aAntegrade intramedullary nailing with cancellous screw; 2) cancellous screw with low contact dynamic compression plating; 3) Hong proximal femoral nailing and 4) Hong barrel DHS; the

Formatted: Highlight

Formatted: Highlight

Comment [PT12]: ?????

average duration of surgical procedure was 285 mins and average intra-operative blood loss of 422.5 mL (26). The procedure we considered the average duration of surgical procedure was 120.4 mins and the mean blood loss was 460 mL, which showcases the advantages of this selection of implants. However, one important factor in favour of this study was that in these kinds of injuries the neck/IT fracture in basicervical in location, it is the region where in capsule of hip joint ends so basicervical neck femur fractures can be intra or extracapsular. Due to this anatomical relation sometimes, the capsule engages in between the two fracture fragments at neck femur and hampers union even if the fixation is solid so open reduction under vision mandates what we have done in this study. Furthermore, the curative effects, complications, and postoperative functional indexes, were similar to previous studies (26). Moreover, DHS with locking plate has a very vast scope of application, even in the treatment of ipsilateral neck/IT and mid shaft femoral fractures.

Conclusion

Here, in this case study we showed our results for the management of ipsilateral neck/inter-trochanteric and mid-shaft femoral fractures by dual construct implants including DHS for neck/IT fracture and locking plate for shaft femur fractures. The summary of our clinical efforts presents that this type of use of implants for complex fractures like these is a good alternative for complex fractures management with biologic internal fixation of both the fractures with convenient results. However, higher number of patients are still needed for longer duration results.

Comment [PT13]: present clearer conclusions related to the results obtained, so that the advantages or disadvantages of the techniques used here are made clear.

Informed consent:

Written and oral consents were obtained from cases before including in the study

References

1. Delaney WM, Street DM. Fracture of femoral shaft with fracture of neck of same femur; treatment with medullary nail for shaft and Knowles pins for neck. *J Int Coll Surg*. 1953 Mar;19(3):303–12.
2. Chen CM, Chiu FY, Lo WH, Chuang TY. Ipsilateral hip and distal femoral fractures. *Injury*. 2000 Apr;31(3):147–51.
3. Cannada LK, Viehe T, Cates CA, Norris RJ, Zura RD, Dedmond B, et al. A retrospective review of high-energy femoral neck-shaft fractures. *J Orthop Trauma*. 2009 Apr;23(4):254–60.
4. Alho A. Concurrent ipsilateral fractures of the hip and femoral shaft: a meta-analysis of 659 cases. *Acta Orthop Scand*. 1996 Feb;67(1):19–28.
5. Gamper S, Steiner A, Nuss K, Ohlerth S, Fürst A, Ferguson JG, et al. Clinical evaluation of the CRIF 4.5/5.5 system for long-bone fracture repair in cattle. *Vet Surg VS*. 2006 Jun;35(4):361–8.
6. Zahn K, Frei R, Wunderle D, Linke B, Schwieger K, Guerguiev B, et al. Mechanical properties of 18 different AO bone plates and the clamp-rod internal fixation system tested on a gap model construct. *Vet Comp Orthop Traumatol VCOT*. 2008;21(3):185–94.
7. Wang D, Xiong Y, Deng H, Jia F, Gu S, Liu B, et al. Biomechanical analysis and clinical effects of bridge combined fixation system for femoral fractures. *Proc Inst Mech Eng [H]*. 2014 Sep;228(9):899–907.
8. Garden RS. STABILITY AND UNION IN SUBCAPITAL FRACTURES OF THE FEMUR. *J Bone Joint Surg Br*. 1964 Nov;46:630–47.
9. Friedman RJ, Wyman ET. Ipsilateral hip and femoral shaft fractures. *Clin Orthop*. 1986 Jul;(208):188–94.
10. Wang W-Y, Liu L, Wang G-L, Fang Y, Yang T-F. Ipsilateral basicervical femoral neck and shaft fractures treated with long proximal femoral nail antirotation or various plate combinations: comparative study. *J Orthop Sci Off J Jpn Orthop Assoc*. 2010 May;15(3):323–30.
11. Jones CB, Walker JB. Diagnosis and Management of Ipsilateral Femoral Neck and Shaft Fractures. *J Am Acad Orthop Surg*. 2018 Nov 1;26(21):e448–54.
12. Wolinsky PR, Johnson KD. Ipsilateral femoral neck and shaft fractures. *Clin Orthop*. 1995 Sep;(318):81–90.
13. Heiney JP, Leeson MC, Vrabec GA. Delayed diagnosis of an ipsilateral femoral neck fracture with an associated femoral shaft fracture in light of a negative computed tomography scan. *J Trauma*. 2009 Oct;67(4):E129-131.

14. Jawad Z, Odumala A, Jones M. Objective sound wave amplitude measurement generated by a tuning fork. An analysis of its use as a diagnostic tool in suspected femoral neck fractures. *Injury*. 2012 Jun;43(6):835–7.
15. Rogers NB, Hartline BE, Achor TS, Kumaravel M, Gary JL, Choo AM, et al. Improving the Diagnosis of Ipsilateral Femoral Neck and Shaft Fractures: A New Imaging Protocol. *J Bone Joint Surg Am*. 2020 Feb 19;102(4):309–14.
16. Lawson E, Madougou S, Chigblo P, Quenum G, Ouangré A, Tidjani F, et al. Ipsilateral proximal and shaft femoral fractures. *Chin J Traumatol*. 2017 Jun;20(3):155–7.
17. Singh R, Rohilla R, Magu NK, Siwach R, Kadian V, Sangwan SS. Ipsilateral femoral neck and shaft fractures: a retrospective analysis of two treatment methods. *J Orthop Traumatol Off J Ital Soc Orthop Traumatol*. 2008 Sep;9(3):141–7.
18. Chaturvedi S, Sahu SC. Ipsilateral concomitant fractures of the femoral neck and shaft. *Injury*. 1993 Apr;24(4):243–6.
19. Oh C-W, Oh J-K, Park B-C, Jeon I-H, Kyung H-S, Kim S-Y, et al. Retrograde nailing with subsequent screw fixation for ipsilateral femoral shaft and neck fractures. *Arch Orthop Trauma Surg*. 2006 Sep;126(7):448–53.
20. Gadegone W, Lokhande V, Salphale Y, Ramteke A. Long proximal femoral nail in ipsilateral fractures proximal femur and shaft of femur. *Indian J Orthop*. 2013 May;47(3):272–7.
21. Hak DJ, Mauffrey C, Hake M, Hammerberg EM, Stahel PF. Ipsilateral femoral neck and shaft fractures: current diagnostic and treatment strategies. *Orthopedics*. 2015 Apr;38(4):247–51.
22. Strauss E, Frank J, Lee J, Kummer FJ, Tejwani N. Helical blade versus sliding hip screw for treatment of unstable intertrochanteric hip fractures: a biomechanical evaluation. *Injury*. 2006 Oct;37(10):984–9.
23. Ostrum RF, Tornetta P, Watson JT, Christiano A, Vafek E. Ipsilateral proximal femur and shaft fractures treated with hip screws and a reamed retrograde intramedullary nail. *Clin Orthop*. 2014 Sep;472(9):2751–8.
24. Randelli P, Landi S, Fanton F, Hoover GK, Morandi M. Treatment of ipsilateral femoral neck and shaft fractures with the Russell-Taylor reconstructive nail. *Orthopedics*. 1999 Jul;22(7):673–6.
25. Vidyadhara S, Rao SK. Cephalomedullary nails in the management of ipsilateral neck and shaft fractures of the femur—one or two femoral neck screws? *Injury*. 2009 Mar;40(3):296–303.
26. Tsai C-H, Hsu H-C, Fong Y-C, Lin C-J, Chen Y-H, Hsu C-J. Treatment for ipsilateral fractures of femoral neck and shaft. *Injury*. 2009 Jul;40(7):778–82.