

Original Research Article

Location of mental foramen among South Indian populations - a retrospective radiography study

ABSTRACT :

Background :

The mental foramen (MF) is located in an antero-lateral aspect of the body of the mandible. It is present between the upper and lower mandibular border. It transmits mental nerve and blood vessels. Variations within the position of the MF are reported by many authors in several ethnic groups and various shapes have also been noticed. It's usually located below the 1st premolar teeth. This mental foramen may transmit the branches of the mental nerve and vessels. The aim of the study is to analyse the location of mental foramen in the South Indian population.

Materials and methods :

The study was conducted using 100 different OPG's of the South Indian population. The location of mental foramen for different mandibles is studied visually from OPG's and data collected was tabulated and analysed using SPSS for statistical analysis.

Results :

From the results it is suggested that the maximum frequency for the right side is at location 2 which is in the longitudinal axis of 1st premolar. 14.0% at location 1, 31.6% at location 2, 21.1% at location 3. 17.3% at location 4. 10% at location 5, 6% at location 6. The location of mental foramen at the axis of 1st premolar was observed to have a high frequency of occurrence in the age group of 26-35.

Conclusion :

The Mental foramen in South Indian population is mostly found in the longitudinal axis of 1st premolar. The clinical students and surgeons should know the existence of mental foramen at surgical procedures using mandibular premolar and molar regions. Future studies with large sample sizes should be conducted to make the results conclusive.

Keywords :

Mental foramen; OPG; mandible; Radiography; Innovative technique

Running Title: Location of mental foramen in the south indian population.

INTRODUCTION :

The Mental Foramen(MF) is found within the body of the mandible, midway between the inferior and therefore the alveolar margins of the body it's present between the premolars, during a vertical line with the supraorbital notch. It provides a passage for the exit of the mental nerve and therefore the vessels.(1). Using an orthopantomogram (OPG) we can find the location. Most of the mental foramina are oriented postero-superiorly. Variations within the position of the MF are reported by many authors in several ethnic groups and various shapes have also been noticed. it's usually located below the 1st premolar teeth. This mental foramen may transmit the branches of the mental nerve and vessels. The precise knowledge on the variations within the position, shape, and the size of the mental foramen and therefore the presence of the accessory mental foramen would be of much use for dental surgeons while they do surgical procedures on the mandible, like the Curettage of the premolars,(2) Filling procedures, Dental implants, passage Treatments (RCT), Orthognatic surgeries, etc. Its also essential to have an efficient and a successful anaesthesia during nerve blocks, prior to the surgery . Many studies reported by various authors within the South Indian population are sparse. Hence, an attempt was made in our present study, to work out the foremost common position and size of the mental foramen in adult South Indian mandibles, which can be useful for the longer term implications in our South Indian population.(3) **The experience from our previous studies (4) (5,6) (5)(7)(8)(9)(10)(8,10)(11)(12) (13) have led us to focus on the current topic.**

Kindly mention in detail the experience from your previous studies. References cannot be quoted without any text/published material being used in the present paper.

The MF provides a passage for the mental nerve and vessels. MF is usually single in human beings; If Accessory mental foramen is present, MF transmit either the accessory mental nerve, which itself may be a branch of inferior alveolar nerve, or one among the branches of mental nerve.(14) These accessory mental foramen (AMFs) are usually smaller as compared to the MF and are located on the perimandibular surface surrounding the MF. Failure to spot and protect MF and structures traversing it'd be the rationale for failure to realize an adequate level of mental nerve anesthesia. It may lead to accidental damage to the accessory nerves with

neurosensory disturbances or rarely traumatic neuroma. **Our team has extensive knowledge and research experience that has translated into high quality publications (15–34).** The aim of the study is to analyse the location of mental foramen in the South Indian population.

Kindly mention in detail the experience from your previous studies. References cannot be quoted without any text/published material being used in the present paper.

MATERIALS AND METHODS :

This is a retrospective study conducted in a private dental college and hospital in Chennai using 100 OPG's. **Patients aged 1 year and above** and High quality OPG's with respect to coloration and angulation were included. Exclusion criteria-Patients affected with dental and maxillofacial fractures, joint disjunction, traumas, pathological lesions around mental foramen were excluded and Patients undergoing diagnosis surgery or orthodontic purposes were excluded from the study. Data were analyzed statistically by SPSS 2.3. Data was set and analysed by chi square test with bar charts and cross tabs. The study was approved by the institutional review board. The OPG'S of the South Indian population were taken and the location of the mental foramen is located and the data were added in sheets and statistically analysed in SPSS. The locations were classified by 6 different locations (Table 1) The locations were entered and statistically analysed by SPSS.

Please mention exact age of patients. In the error bar the age group starts from 19 years

Table 1- Representing different locations of mental foramen based on its position

Locations	Positions
1	Between canine and 1st premolar
2	Axis of 1st premolar
3	Between 1st and 2nd premolar
4	Axis of 2nd premolar,
5	Between 2nd premolar and 1st molar

6	Axis of 1st molar.
---	--------------------

RESULT :

From the results it is suggested that the maximum frequency for the right side is at location 2 which is in the longitudinal axis of 1st premolar. 14.0% at location 1, 31.6% at location 2, 21.1% at location 3. 17.3% at location 4. 10% at location 5, 6% at location 6. The location of mental foramen at the axis of 1st premolar was observed to have a high frequency of occurrence in the age group of 26-35.(figure 1,2)

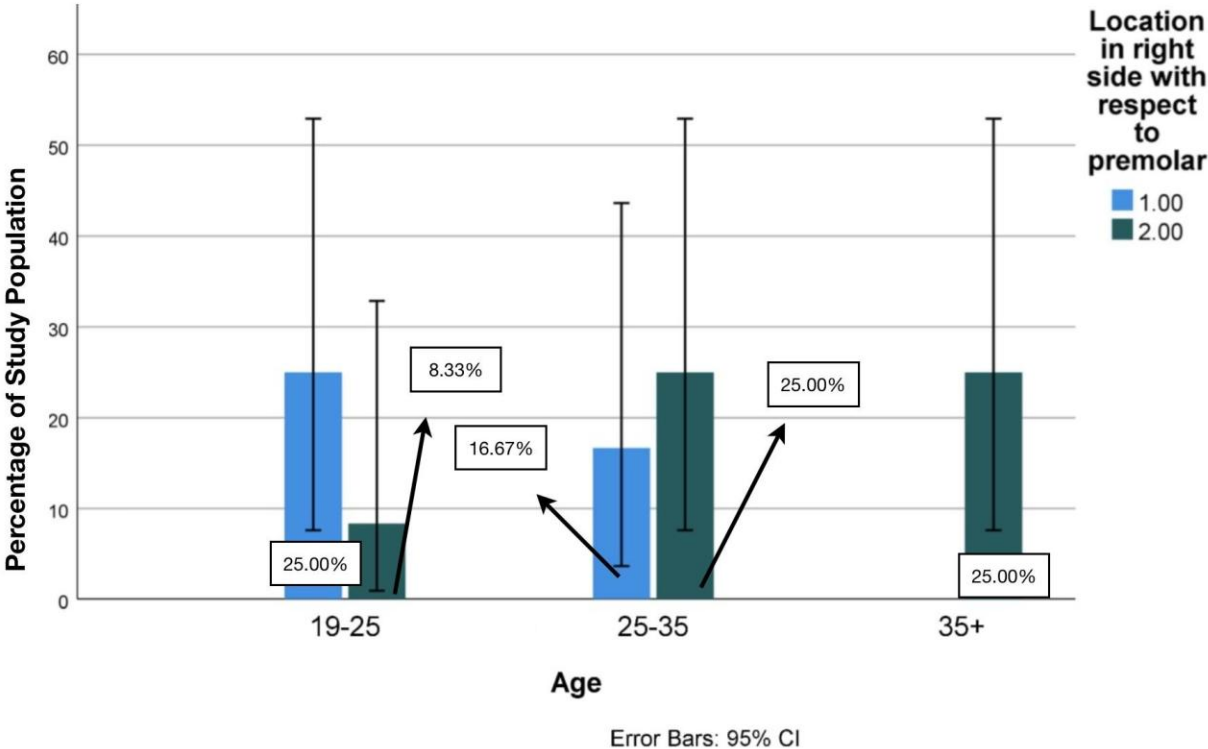


Figure : 1 This graph represents the comparison analysis of the different location of mental foramen in the right side with respect to age groups. X-axis represents locations of mental foramen The y axis represents the number of the samples. **Blue represents the age of 1-15, green represents 16-25, brown represents 26-35, violet represents 36-50, yellow represents 50+. The maximum frequency is at location 2 in 26-35yrs.**

The colour coding given in the error bar & that mentioned in the text below DO NOT correlate. There are only blue, grey & black colours in the graph. The text also mentions green, brown, violet & yellow colours

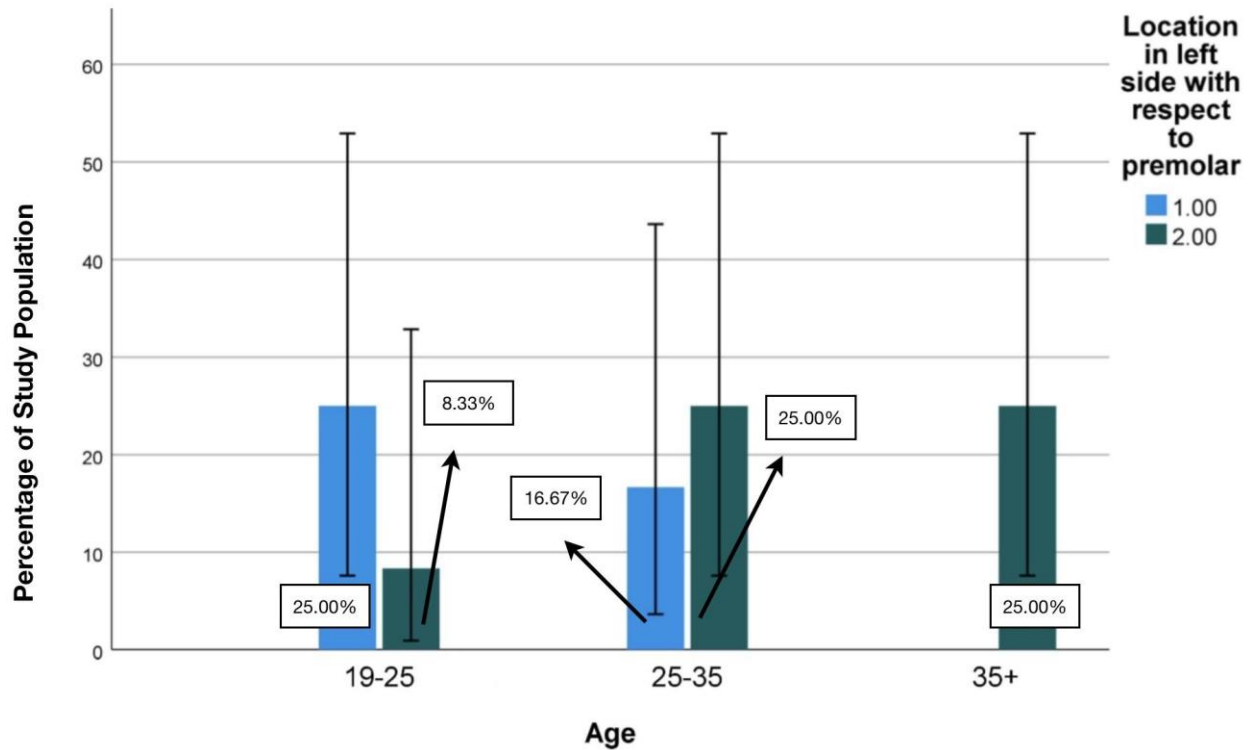


Figure :2 This graph represents the comparison analysis of the mean location of mental foramen in the left side between age groups. X axis represents the different locations of mental foramen. Y axis represents the count of population with respect to the location. **Blue** represents the age 1-15, green represents 16-25, brown represents 26-35, violet represents 36-50, yellow represents 50+.The maximum frequency is at location 2 which is in the longitudinal axis of the 1st premolar in 16-25yrs.

The colour coding given in the error bar & that mentioned in the text below DO NOT correlate. There are only blue, grey & black colours in the graph. The text also mentions green, brown, violet & yellow colours

DISCUSSION :

The location of the longitudinal axis of the 1st premolar has the maximum frequency among the 100 OPG's in the South Indian population. The Most frequent frequency was 14.0% at location 1, 31.6% at location 2, 21.1% at location 3. This study can have its own relevance and has forensic importance. The MF is typically directed posterosuperiorly and is situated on the anterolateral aspect of the body of the mandible. It's usually located below the interval between the premolars, midway between the inferior and therefore the alveolar margins of the body, and approximately 13–15 mm superior to the inferior border of the mandibular body. Variations are observed in its location, which may be more anterior, below the canine or posterior, and shut to the second molar.(35)

Previous studies have reported that MFs are commonly located below the primary molar tooth. Within the present study, though it's present in various locations, in 48%, it had been present below the second premolar. It's been reported earlier that the majority of the MF were located within the distal region of MF and really few within the mesial region.

(36). The MF is typically directed posterosuperiorly and is situated on the anterolateral aspect of the body of the mandible. It's usually located below the interval between the premolars, midway between the inferior and **therefore** the alveolar margins of the body, and approximately 13–15 mm superior to the inferior border of the mandibular body. Variations are observed in its location, which may be more anterior, below the canine or posterior, and close to the second molar(37).

Previous studies have reported that MFs are commonly located below the primary molar and premolar tooth. Within the present study, though it's present in various locations, in 48%, it had been present below the second premolar.(38) It's been reported earlier that the majority of the MF were located within the distal region of MF and really few within the mesial region. Mostly, **MF were found to be located inferior to the MF.** AMF were located posterior to MF.(39)

The situation of AMF in reference to MF might influence the planning of rehabilitating treatment since its presence would interfere with the implant procedures. Within the present study, most of the **MF** were either inferolateral (25.9%) or superomedial (25.9%) to MF.(40)

The first three lines in the above two paragraphs have been repeated. The reference numbers also do not match.

In the above paragraph it is mentioned that "**MF were found to be located inferior to the MF.**" Does the author mean to use some other terminology?

In the anterior-posterior position, the foremost frequent MF location no matter gender of the themes was an edge between the primary and second premolars of the mandible characteristic for older patients and, next, a location within the long axis of the second premolars of a mandible, typical for the youngest patients on the proper side.(41) Our studies correspond with the results of the research administered in every case using CT methods. the dimensions of MF no differences with reference to the age of the themes were observed. On the opposite hand, statistically significant differences were observed within the size of MF in reference to the sex of the patients. In men, vertical diameter on each side of the mandible and horizontal diameter on the proper side were higher as compared to the values observed in women.(42)

Dental implants and other surgery can be easily done by the identification of the mental foramen and its location, preparation for the surgery can be easily made according to the requirements.

MF are a rare anatomical variation and reported to possess a prevalence starting from 1.4% to 10%. (43) The presence of MF has been reported by investigations on dry human skulls, cadaveric dissections, and radiological studies. In a previous study, the incidence in the South Indian population was found to be 8.85%. In the present study, MF were located more on the left side than on the proper side. This is often in accordance with previous studies that have found 8% MFs on the left side and 5% on the proper side; found 3.33% MFs on the left side and a couple of .22% on the right side. (44) reported the presence of 4 MF, all of which were situated on the right side of the mandible. Previous studies have shown that bilateral MF is a particularly rare finding and has been reported only in 0.53% of total population. (45) Contrary to that, bilateral occurrence of MF has been reported in 2% of the South Indian population.

MF are a rare anatomical variation – Kindly clarify

A study revealed 1.6% bilateral MF, indicating that bilateral MF occurrence is more in Indian population. The site and size of the MF are thought to be influenced by the nerve passing through it. described four terminal branches of the mental nerve as angular, medial inferior labial, lateral inferior labial, and mental branches.(46) The nerve emerging from MF has been described as either being one among the terminal branches of mental nerve given off within the mandibular canal or the presence of a further branch, called accessory mental nerve which is taken into account to be a branch of the inferior alveolar nerve which could have separated earlier than formation of mental foramina. Limitations of this study are limited sample size, random sampling, ethical issues in identifying opg's and names that can't be revealed and the

data collected are highly confidential. Future studies should be conducted with a huge sample size to make the context evident and it may have forensic and surgical implications.

CONCLUSION :

The Mental foramen in South Indian population is mostly found in the longitudinal axis of 1st premolar. The clinical students and surgeons should know the existence of mental foramen at surgical procedures using mandibular premolar and molar regions. Future studies with large sample sizes should be conducted to make the results conclusive.

REFERENCES :

1. von Arx T, Friedli M, Sendi P, Lozanoff S, Bornstein MM. Location and dimensions of the mental foramen: a radiographic analysis by using cone-beam computed tomography. *J Endod.* 2013 Dec;39(12):1522–8.
2. Muínelo-Lorenzo J, Fernández-Alonso A, Smyth-Chamosa E, Suárez-Quintanilla JA, Varela-Mallou J, Suárez-Cunqueiro MM. Predictive factors of the dimensions and location of mental foramen using cone beam computed tomography [Internet]. Vol. 12, *PLOS ONE*. 2017. p. e0179704. Available from: <http://dx.doi.org/10.1371/journal.pone.0179704>
3. Chikkanarasaiah N, Krishnamurthy NH, Vathariparambath N. Morphological Location of Mandibular and Mental Foramen in Teenagers: A Cone-beam Computed Tomography Study [Internet]. Vol. 11, *Journal of Health Sciences & Research*. 2020. p. 1–5. Available from: <http://dx.doi.org/10.5005/jp-journals-10042-1088>
4. **Shruthi M, Preetha S. Effect of Simple Tongue Exercises in Habitual Snorers [Internet]. Vol. 11, *Research Journal of Pharmacy and Technology*. 2018. p. 3614. Available from: <http://dx.doi.org/10.5958/0974-360x.2018.00665.0>**
5. **Preetha S, Packyanathan J. Comparison of the effect of Yoga, Zumba and Aerobics in controlling blood pressure in the Indian population [Internet]. Vol. 9, *Journal of Family Medicine and Primary Care*. 2020. p. 547. Available from: http://dx.doi.org/10.4103/jfmpc.jfmpc_607_19**
6. **J SK, Saveetha Dental College and Hospitals, Road PH, Chennai, Tamilnadu, Preetha S, et al. Effect of aerobics exercise and yoga on blood pressure in hypertensives**

- [Internet]. Vol. 6, International Journal of Current Advanced Research. 2017. p. 3124–6. Available from: <http://dx.doi.org/10.24327/ijcar.2017.3126.0200>
7. Prathap L, Suganthirababu P, Ganesan D. Fluctuating Asymmetry of Dermatoglyphics and DNA Polymorphism in Breast Cancer Population [Internet]. Vol. 10, Indian Journal of Public Health Research & Development. 2019. p. 3574. Available from: <http://dx.doi.org/10.5958/0976-5506.2019.04141.x>
 8. Lavanya J, Prathap S, Alagesan J. Digital and palmar dermal ridge patterns in population with breast carcinoma. Biomedicine. 2014 Jul 1;34(3):315–21.
 9. Prathap L, Jagadeesan V. Association of quantitative and qualitative dermatoglyphic variable and DNA polymorphism in female breast cancer population. Online J Health [Internet]. 2017; Available from: https://www.researchgate.net/profile/Prathap_Suganthirababu/publication/321606278_Association_of_Quantitative_and_Qualitative_Dermatoglyphic_Variable_and_DNA_Polymorphism_in_Female_Breast_Cancer_Population/links/5a28c8f1a6fdcc8e8671c0cd/Association-of-Quantitative-and-Qualitative-Dermatoglyphic-Variable-and-DNA-Polymorphism-in-Female-Breast-Cancer-Population.pdf
 10. Lavanya J, Kumar VJ, Sudhakar N, Prathap S. Analysis of DNA repair genetic polymorphism in breast cancer population. Int J Pharma Bio Sci [Internet]. 2015; Available from: https://scholar.google.ca/scholar?cluster=8949053652564257518&hl=en&as_sdt=0,5&scioldt=0,5
 11. Prathap L, Suganthirababu P. Estrogen Exposure and its Influence in DNA Repair Genetic Variants in Breast Cancer Population [Internet]. Vol. 13, Biomedical and Pharmacology Journal. 2020. p. 1321–7. Available from: <http://dx.doi.org/10.13005/bpj/2001>
 12. Ravikumar H, Prathap L, Preetha S. ANALYSIS OF PALMAR ATD ANGLE IN POPULATION WITH MALOCCLUSION. 2020 Jan 1;1174–82.
 13. Prathap L. INTERPLAY OF OXIDATIVE STRESS AND LIPOPROTEINS IN BREAST CARCINOMA INITIATION, PROMOTION AND PROGRESSION -A SYSTEMATIC REVIEW. PalArch's Journal of Archaeology of Egypt/ Egyptology [Internet]. 2021 Jan 7 [cited 2021 Mar 9];17(7). Available from: <http://dx.doi.org/>
 14. Zhang L, Zheng Q. Anatomic Relationship between Mental Foramen and Peripheral Structures Observed By Cone-Beam Computed Tomography [Internet]. Vol. 05, Anatomy & Physiology. 2015. Available from: <http://dx.doi.org/10.4172/2161-0940.1000182>
 15. Sekar D, Lakshmanan G, Mani P, Biruntha M. Methylation-dependent circulating microRNA 510 in preeclampsia patients. Hypertens Res. 2019 Oct;42(10):1647–8.
 16. Princeton B, Santhakumar P, Prathap L. Awareness on Preventive Measures taken by Health Care Professionals Attending COVID-19 Patients among Dental Students. Eur J Dent. 2020 Dec;14(S 01):S105–9.
 17. Logeshwari R, Rama Parvathy L. Generating logistic chaotic sequence using geometric pattern to decompose and recombine the pixel values. Multimed Tools

Appl. 2020 Aug;79(31-32):22375–88.

18. Johnson J, Lakshmanan G, M B, R M V, Kalimuthu K, Sekar D. Computational identification of MiRNA-7110 from pulmonary arterial hypertension (PAH) ESTs: a new microRNA that links diabetes and PAH. *Hypertens Res.* 2020 Apr;43(4):360–2.
19. Paramasivam A, Priyadharsini JV, Raghunandhakumar S, Elumalai P. A novel COVID-19 and its effects on cardiovascular disease. *Hypertens Res.* 2020 Jul;43(7):729–30.
20. Pujari GRS, Subramanian V, Rao SR. Effects of *Celastrus paniculatus* Willd. and *Sida cordifolia* Linn. in Kainic Acid Induced Hippocampus Damage in Rats. *Ind J Pharm Educ.* 2019 Jul 3;53(3):537–44.
21. Rajkumar KV, Lakshmanan G, Sekar D. Identification of miR-802-5p and its involvement in type 2 diabetes mellitus. *World J Diabetes.* 2020 Dec 15;11(12):567–71.
22. Ravisankar R, Jayaprakash P, Eswaran P, Mohanraj K, Vinitha G, Pichumani M. Synthesis, growth, optical and third-order nonlinear optical properties of glycine sodium nitrate single crystal for photonic device applications. *J Mater Sci: Mater Electron.* 2020 Oct;31(20):17320–31.
23. Wu S, Rajeshkumar S, Madasamy M, Mahendran V. Green synthesis of copper nanoparticles using *Cissus vitiginea* and its antioxidant and antibacterial activity against urinary tract infection pathogens. *Artif Cells Nanomed Biotechnol.* 2020 Dec;48(1):1153–8.
24. Vikneshan M, Saravanakumar R, Mangaiyarkarasi R, Rajeshkumar S, Samuel SR, Suganya M, et al. Algal biomass as a source for novel oral nano-antimicrobial agent. *Saudi J Biol Sci.* 2020 Dec;27(12):3753–8.
25. Alharbi KS, Fuloria NK, Fuloria S, Rahman SB, Al-Malki WH, Javed Shaikh MA, et al. Nuclear factor-kappa B and its role in inflammatory lung disease. *Chem Biol Interact.* 2021 Aug 25;345:109568.
26. Rao SK, Kalai Priya A, Manjunath Kamath S, Karthick P, Renganathan B, Anuraj S, et al. Unequivocal evidence of enhanced room temperature sensing properties of clad modified Nd doped mullite Bi₂Fe₄O₉ in fiber optic gas sensor [Internet]. Vol. 838, *Journal of Alloys and Compounds.* 2020. p. 155603. Available from: <http://dx.doi.org/10.1016/j.jallcom.2020.155603>
27. Bhavikatti SK, Karobari MI, Zainuddin SLA, Marya A, Nadaf SJ, Sawant VJ, et al. Investigating the Antioxidant and Cytocompatibility of *Mimusops elengi* Linn Extract over Human Gingival Fibroblast Cells. *Int J Environ Res Public Health* [Internet]. 2021 Jul 4;18(13). Available from: <http://dx.doi.org/10.3390/ijerph18137162>
28. Marya A, Karobari MI, Selvaraj S, Adil AH, Assiry AA, Rabaan AA, et al. Risk Perception of SARS-CoV-2 Infection and Implementation of Various Protective Measures by Dentists Across Various Countries. *Int J Environ Res Public Health* [Internet]. 2021 May 29;18(11). Available from: <http://dx.doi.org/10.3390/ijerph18115848>

29. **Barma MD, Muthupandiyam I, Samuel SR, Amaechi BT. Inhibition of Streptococcus mutans, antioxidant property and cytotoxicity of novel nano-zinc oxide varnish. Arch Oral Biol. 2021 Jun;126:105132.**
30. **Vijayashree Priyadharsini J. In silico validation of the non-antibiotic drugs acetaminophen and ibuprofen as antibacterial agents against red complex pathogens. J Periodontol. 2019 Dec;90(12):1441–8.**
31. **Priyadharsini JV, Vijayashree Priyadharsini J, Smiline Girija AS, Paramasivam A. In silico analysis of virulence genes in an emerging dental pathogen A. baumannii and related species [Internet]. Vol. 94, Archives of Oral Biology. 2018. p. 93–8. Available from: <http://dx.doi.org/10.1016/j.archoralbio.2018.07.001>**
32. **Uma Maheswari TN, Nivedhitha MS, Ramani P. Expression profile of salivary micro RNA-21 and 31 in oral potentially malignant disorders. Braz Oral Res. 2020 Feb 10;34:e002.**
33. Gudipaneni RK, Alam MK, Patil SR, Karobari MI. Measurement of the Maximum Occlusal Bite Force and its Relation to the Caries Spectrum of First Permanent Molars in Early Permanent Dentition. J Clin Pediatr Dent. 2020 Dec 1;44(6):423–8.
34. Chaturvedula BB, Muthukrishnan A, Bhuvanaraghan A, Sandler J, Thiruvengkatachari B. Dens invaginatus: a review and orthodontic implications. Br Dent J. 2021 Mar;230(6):345–50.
35. Rajkohila J, Daniel P, Ambikaipakan S, Rabi S. Morphological and morphometric analysis of accessory mental foramen in dry human mandibles of south indian population. Indian J Dent Res. 2018 Jan;29(1):56–60.
36. Daniel P, Rajkohila J, Ambikaipakan S, Rabi S. Morphological and morphometric analysis of accessory mental foramen in dry human mandibles of south indian population [Internet]. Vol. 29, Indian Journal of Dental Research. 2018. p. 56. Available from: http://dx.doi.org/10.4103/ijdr.ijdr_146_17
37. Suman P, Singh S, Mahato RK. Mental foramen and accessory mental foramen: a dry human mandibles study in South Indian population [Internet]. Vol. 7, National Journal of Clinical Anatomy. 2018. p. 182–91. Available from: <http://dx.doi.org/10.1055/s-0040-1701734>
38. Pyun J-H, Lim Y-J, Kim M-J, Ahn S-J, Kim J. Position of the mental foramen on panoramic radiographs and its relation to the horizontal course of the mandibular canal: a computed tomographic analysis [Internet]. Vol. 24, Clinical Oral Implants Research. 2013. p. 890–5. Available from: <http://dx.doi.org/10.1111/j.1600-0501.2011.02400.x>
39. Laher AE. The Ultrasonographic Determination of the Position of the Mental Foramen and its Relation to the Mandibular Premolar Teeth [Internet]. JOURNAL OF CLINICAL AND DIAGNOSTIC RESEARCH. 2016. Available from: <http://dx.doi.org/10.7860/jcdr/2016/18808.7992>
40. Sultana Z, Professor A, Department of Anatomy, Shadan institute of medical sciences, Hyderabad, Telangana, et al. A MORPHOMETRIC STUDY OF MANDIBULAR FORAMEN

IN DRY ADULT HUMAN MANDIBLES OF INDIAN POPULATION IN TELANGANA STATE [Internet]. Vol. 7, International Journal of Anatomy and Research. 2019. p. 7080–5. Available from: <http://dx.doi.org/10.16965/ijar.2019.308>

41. Aminoshariae A, Su A, Kulild JC. Determination of the location of the mental foramen: a critical review. *J Endod.* 2014 Apr;40(4):471–5.
42. Zmyslowska-Polakowska E, Radwanski M, Ledzion S, Leski M, Zmyslowska A, Lukomska-Szymanska M. Evaluation of Size and Location of a Mental Foramen in the Polish Population Using Cone-Beam Computed Tomography. *Biomed Res Int.* 2019 Jan 2;2019:1659476.
43. Guo JL, Su L, Zhao JL, Yang L, Lv DL, Li YQ, et al. Location of Mental Foramen Based on Soft- and Hard-Tissue Landmarks in a Chinese Population [Internet]. Vol. 20, *Journal of Craniofacial Surgery.* 2009. p. 2235–7. Available from: <http://dx.doi.org/10.1097/scs.0b013e3181bf85f4>
44. Voljevica A, Talović E, Hasanović A. Morphological and morphometric analysis of the shape, position, number and size of mental foramen on human mandibles. *Acta Med Acad.* 2015;44(1):31–8.
45. **Ghaffari R, Afghari P, Sohilipour S. Anatomical assessment of foramen tympanicum using cone beam computed tomography images [Internet]. Vol. 7, *Dental Hypotheses.* 2016. p. 107. Available from: <http://dx.doi.org/10.4103/2155-8213.190486>**
46. Ajmal M. Evaluation of Mental Foramen Position from Panoramic Dental Radiographs [Internet]. Vol. 15, *The Journal of Contemporary Dental Practice.* 2014. p. 399–402. Available from: <http://dx.doi.org/10.5005/jp-journals-10024-1551>