

Original Research Article

EVALUATION OF INTERMENTAL FORAMINA DISTANCE AMONG SOUTH INDIAN POPULATION

ABSTRACT:

Background:

OPG (orthopantomogram) is a cephalogram, a type of a dental x-ray, and has been found that the intermental foramina distance varies at different ethnicities. It has been noted that the commonly seen part is below the 2nd premolar where mandibular foramen has a bony canal formed in the mandible at the two distinct anatomies and its rim is 'v' shaped, that was its common form where the groove separating the anterior and posterior parts are horizontally oriented rim which is an oval shaped rim. The mandibular foramen's location also varies at different ethnicities; the intermental foramina distance is recorded always from the mandibles mid-line.

Comment [S1]: Grammatical correction

Comment [S2]: What part?

Comment [S3]: Rephrase the sentence, it's quite confusing.

Comment [S4]: Grammatical correction

Comment [S5]: Grammatical correction.

Materials & Methods:

The OPGs are collected from the private dental college and hospital in Chennai. The location of mental foramen is identified and the intermental foramina distance is calculated by Adobe Photoshop. The collected data is analysed using SPSS software.

Comment [S6]: SPSS full form, version and company name. Grammatical correction.

Results:

Among the South Indian population, the average distance of the intermental foramen is 4.93 cm. The average intermental foramina distance however is 4.93 cm. The average distance of the intermental foramen among the Males is 5.14 cm and in females it is 4.76 cm. There is a significant difference in the intermental foramina distance between the gender among the South Indian population with p value 0.001.

Comment [S7]: Please be specific its intermental foramen or foramina. Repeated sentence be removed. Please use past tense in this section.

Comment [S8]: This sentence is confusing please be specific.

Conclusion:

From the results of the study within the limitations it can be concluded that there is a significant difference in the intermental foramina distance between the gender among the South Indian population with p value 0.001. The knowledge on the intermental foramina difference is the

important measure for the dentist while performing the implants, orthodontic surgery, and periodontal surgery. It helps the dentist to make the planning for drilling the lower jaw bone

Comment [S9]: Make it short and specific.

KEYWORDS: Mental foramen; Mandible; South Indian population; intermental foramina distance; OPG; Innovative technique.

Comment [S10]: Alphabetical order and please use capital and small letter where its appropriate.

Running Title: Intermental foramina distance using OPG

INTRODUCTION:

OPG (Orthopantomogram) is a cephalogram of the type of a dental x-ray that has been found that the intermental foramen varies at different ethnicities. It has been noted that the commonly seen part is below the 2nd premolar. (1) Mandibular foramen has a bony canal formed in the mandible at the two distinct anatomies and its rim is 'V' Shaped. It has been found that the situation of the mental foramen varies in several ethnicities. (2) Mental foramen position is usually seen below the second premolar. However, individual variation exists whereby it is often placed anywhere in between the primary premolar to the mesial different planes, which are the horizontal and therefore the vertical planes. (3) The horizontal position of mental foramen was recorded as either in line with the longitudinal axis of the tooth or lying in between two teeth. (4) The vertical position of the mental foramen to be either situated coronal to the apex, at the apex, or apical to the apex. (5)

Comment [S11]: Repeated section from background.

Comment [S12]: Primary premolar tooth does not exist

Some studies measured the situation of the mental foramen from various landmarks of the mandible. As an example, the foremost commonly used landmarks are symphysis menti, 6 posterior borders of the ramus of the mandible (in horizontal plane), and therefore the lower border of the body of the mandible (in vertical plane). (6) To estimate the space of the interforamina, various studies are done by using the midline of the mandible as an anatomical landmark. consistent with Shank-land the mandibular foramen is found 28 mm from the midline of the mandible and 14–15 mm from the inferior border of the mandible. (7). The experience from our previous studies (8) (9,10) (9)(11)(12)(13)(14)(12,14)(15)(16) (17) have led us to focus on the current topic.

Comment [S13]: What is situation here please specify.

Comment [S14]: This study is about distance between intermental foramina and why are you talking about volume?

Comment [S15]: Please specify your studies and reference

In between the inferior and the alveolar margins of the body it is present in the premolars. It also provides the passage for the exit of the mental nerves and vessels, most of them oriented postero-superiorly. Any foramina which is in the addition or extra to the mental foramen (MF) is considered as an accessory mental foramen (AMF) present below the 1st molar of teeth. The branches of the mental nerves are transmitted by the AMF. (18) The position of the mental foramen are often seen in two midlines of the mandible. For the aim of implant placement within the interforaminal area of a complete edentulous patient, interforaminal distance is crucial in determining the situation and therefore the number of implant placement. (18,19) Our team has extensive knowledge and research experience that has translate into high quality publications. (20–27),(28),(29),(30),(31,32),(33),(34),(35–39) The aim of this study is to evaluate and explore the intermental foramina distance among the south indian population.

Comment [S16]: What is present?

Comment [S17]: Confusing sentence

Comment [S18]: Please use one font and size of word.

Comment [S19]: Capitalize I

MATERIALS AND METHOD:

This is a retrospective panoramic radiography study conducted in a private dental college and hospital in Chennai and the study was approved by the institutional review board. Random sampling was done to select the participants for this study. A total of 100 panoramic radiographs orthopantomogram (OPG) of South Indian population of both sexes having visible mental foramina were collected. All panoramic radiographs were taken using Siemens Orthophos (Sirona) with magnification of 1.2. The radiographs were chosen consistent with the following inclusion and exclusion criteria. South Indian ethnicity, High quality with reference to geometric accuracy and contrast of the image, Panoramic radiographs having bilaterally visible mental foramina are taken as the inclusion criteria. poor quality of OPG, Radiopaque or radiolucent lesion within the lower arch, fractured mental foramen region, Fractured Lower jaw was removed are the exclusion criteria followed in making this study. Presence of supernumerary or unerupted teeth because the unerupted teeth might obscure the appearance of the mental foramen.

Comment [S20]: In abstract it is materials and methods ?

Comment [S21]: IRB reference number is missing.

Comment [S22]: Specification of the OPG machine should be included .

Comment [S23]: Reformat this section with clear and specific to what you have done.

Any radiographic exposure or processing artifacts. Adobe photoshop was used to view the x-ray, the magnification was 1.2, to calculate the intermental foramen the ruler option is selected on adobe photoshop and the vertical and horizontal markings have to be done and the distance should be measured on each side of the mental foramen region. A vertical line marking the midline was drawn passing between the maxillary central incisors (as first preference), the

Comment [S24]: Software version

mandibular central incisors, or the septum (if the maxillary and mandibular central incisors were missing) by employing a ruler. The Collection of OPG's of mandibles is done, identifying the location of mental foramen in it and evaluating the intermental foramina distance and then entering the collected data into microsoft excel and analysing the data using the IBM SPSS software.

RESULTS:

As many as 100 OPGs were selected out of 126 OPGs based on the exclusion criteria. Of these, 47% were males and 53% were females. (figure 1) The youngest patient was 11 years old and the oldest was 87 years old. Gender analysis showed a higher female percentage (53%). the age group distribution of the people who are participated in this study age group of 1-15 belongs to category 1 for 14%; age group of 16-30 belongs to category 2 for 29%; age group of 31 to 45 belongs to category 3 for 21%; age group of 46 to 60 belongs to category 4 for 25%; people who were aged 65 & 65+ belongs to category 5 for 11%. It is clear that the age group of 16 to 30 present more on this study. (figure 2) Among the South Indian population, the average distance of the inter-mental foramen is 49.93 ± 2.79 mm. (Figure 3) The average distance of the inter mental foramen among the Males is 5.14 cm and in females it is 4.76 cm. There is a significant difference in the intermental foramina distance between the gender among the south Indian population with p value 0.001.

Comment [S25]: The sentences are not clear. How did you manage the magnification is not included. Remove repeated sentences and be specific. Please specify the software version where ever applicable. The ststistical analysis you have used, the test that were applied is not included please include.

Comment [S26]: This should be in materials and method section. How do you randomly selected 100 samples from 126 sammplinf frame is not clear/.

Comment [S27]: What about growth consideration if sample is between 11 and 87 years old.

Comment [S28]: In result section in abstract the measurements are in cm and here it is mm?

Comment [S29]: Please use either mm or cm

Comment [S30]: The grammatical portion is confusing and use of capital and small letter is not appropriate. The use of full stop is not proper. Please write about significant result only in this section as you have pie chart and bar diagram in the result section repeated presentation should be avoided.

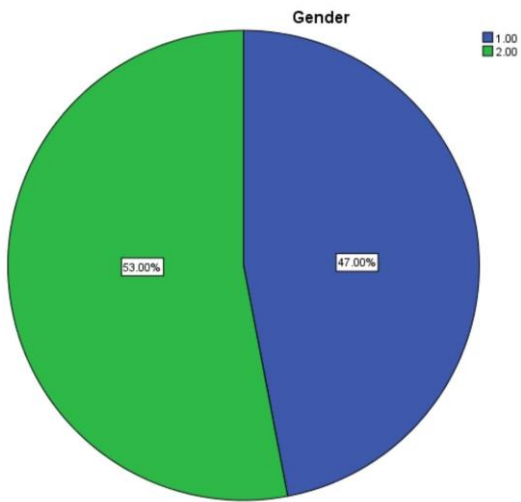


Fig 1: This pie chart represents the distribution of males and females who participated in this survey. Blue denotes male (1) for 47% and green denotes female (2) for 53% and Females participated more in this study.

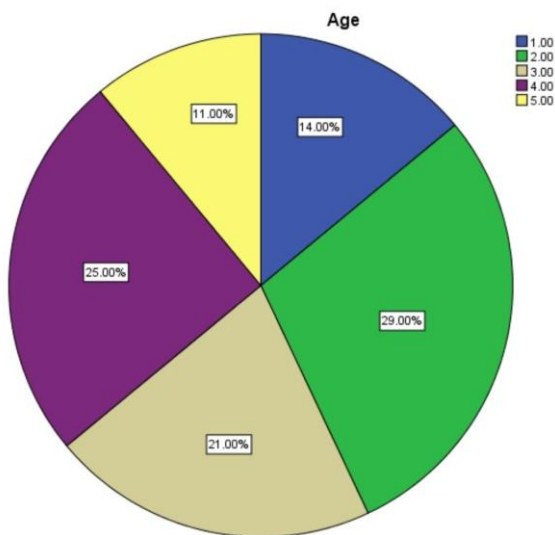


Fig 2: This pie chart represents the age group distribution of the people who are participated in this study age group of 1-15 belongs to category 1, blue denotes 1 for 14%; age group of 16-30 belongs to category 2, green denotes 2 for 29%; age group of 31 to 45 belongs to category 3, sandal colour denotes 3 for 21%; age group of 46 to 60 belongs to category 4, violet colour denotes 4 for 25%; people who were aged 65 & 65+ belongs to category 5, yellow colour denotes 5 for 11%. It is clear that the age group of 16 to 30 present more on this study.

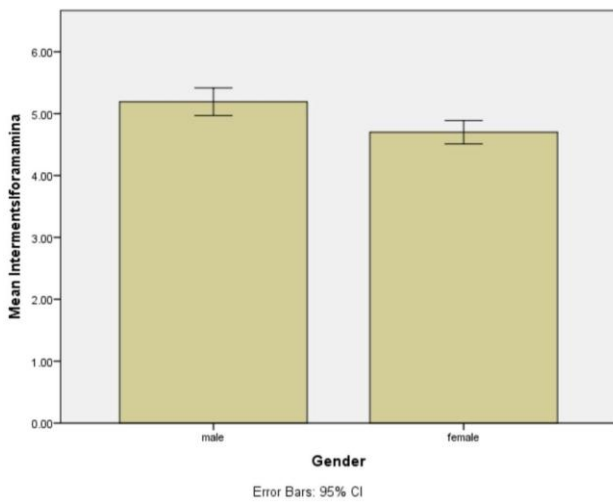


Fig 3: This bar chart represents the association between the gender and their intermental foramina distance. X axis represents gender and Y axis represents the mean intermental foramina distance. There is a significant difference in the intermental foramina distance between the gender with Males 5.14 cm and females it is 4.76 cm. with p value 0.001.

DISCUSSION:

This study has shown that the evaluation of the intermental foramina distance among the South Indian population has some little variations but it is statistically significant. The intermental

Comment [S31]: This is not clear

foramina distance among the south Indian population varies from person to person and also has a huge difference between the geographical population when compared.

Comment [S32]: What is huge difference?

The determination of the intermental foramina distance among the various population has an important landmark for anatomical intrusions, there are little variations in different populations are proven by the failures of the anaesthesia in the mental foramen region, our study has demonstrated the most common position, which was similar to the North Americans, North Indians and Zimbabweans. (7,40,41)

Comment [S33]: Not compared to other population so how can you justify this.

Our study findings have coincided with those of Mohammed Jasim Al-Juboori and K.Udhaya., et al in different populations. These findings were significant with the higher prevalence of the position. The Nigerians and Kenyans have shown us the most common position followed by the Malays and Srilankan populations. They have shared the most similar intermental foramina distance. (42). The distance between the intermental foramina distance among south Indian population in males showed us 5.3 cm and in females it is 4.4 cm as the average distance and it is not significant for the both genders. (43)

Comment [S34]: Compare with relevant study only

In the previous study, 3.33% of the mandible showed accessory mental foramen on the left side and 2.22% showed accessory mental foramen on the other side. Our results were in contrast with those of Singh and Srivastava, where they found 8% AMFs on the left side and 5% on the proper side. (43,44) Cag Irankaya and Kansu, Singh et al., reported AMFs below the first molar.

Comment [S35]: Which study please specify or cite?

But in our study, each AMF showed a variable position viz., between the 2nd premolar and the 1st molar, followed by between the first molar and therefore the 2nd premolar (left side); between the 2nd premolar and the first molar then between the first premolar and the 2nd premolar (right side). The literature on this is very sparse in Indian studies. The literature on the dimensions of the AMF is hardly available, to match with ours. Singh et al., recorded a mean diameter of 1mm, but our study recorded a vertical diameter 2.26 mm with an HD of 1.58 mm on the left side. The data collected were divided based on the ethnicity for each sex. Fishel et al and Greenstein et al have proposed the foremost popular method for the identification of mental foramen. (45)

Comment [S36]: What is proper side?

Comment [S37]: This sentence is not clear please reformat.

Comment [S38]: What is HD?

Neiva et al has also studied the intermental foramina distance and found that the space between the left and right foramen was 55.23 ± 5.34 mm. Another study that was done by Apinhasmit et al⁸ found that the mental foramen was a mean of 28.52 ± 2.15 mm from the root

Comment [S39]: Space or distance?

of the primary molar. (46) The clinician should always take this into the consideration that the IMF distance must not be determined based upon their ethnicity / independent variables.

Comment [S40]: What is IMF here its not clear.

Limitations of this study are low case study, random sampling, lesser time limit, ethical issues in identifying opg's and names that can't be revealed. The data collected are highly confidential. Dental implants and other major/minor surgery can be easily done with the identification of the intermental foramina distance, preparation for the surgery can be easily made according to the requirements. Future studies with large sample size should be conducted for more reliable results and to make the context evident.

Comment [S41]: The limitation are vague?

CONCLUSION:

From the results of the study within the limitations it can be concluded that there is a significant difference in the intermental foramina distance between the gender among the south Indian population with p value 0.001. The knowledge on the intermental foramina difference is the important measure for the dentist while performing the implants, orthodontic surgery, and periodontal surgery. It helps the dentist to make the planning for drilling the lower jaw bone

Comment [S42]: This section is in abstract and please be specific. The consideration of P value is not shown anywhere in the article .

• **COMPETING INTERESTS DISCLAIMER:**

-
- Authors have declared that no competing interests exist. The products used for this research are commonly and predominantly use products in our area of research and country. There is absolutely no conflict of interest between the authors and producers of the products because we do not intend to use these products as an avenue for any litigation but for the advancement of knowledge. Also, the research was not funded by the producing company rather it was funded by personal efforts of the authors.

Comment [S43]: Please specify about what product you are talking. Be realistic in this section.

REFERENCES:

1. Al-Juboori MJ, Department of Periodontology, Al-Rafidain University College, Baghdad, Iraq, Al-Juboori AJ, et al. The Relationship between the Lip Length and Smile Line in a Malaysian Population: A Cross-Sectional Study [Internet]. Vol. 3, Journal of Dentistry and Oral Care. 2017. p. 1–5. Available from: <http://dx.doi.org/10.15436/2379-1705.17.1385>
2. Al-Juboori MJ. The Importance of the Mental Foramen Location Detection by Using Different Radiographic Technique: Mini Review [Internet]. Vol. 2, International Journal of Medical Imaging. 2014. p. 63. Available from: <http://dx.doi.org/10.11648/j.ijmi.20140203.14>
3. Singh S, Suman P, Mahato R. Mental foramen and accessory mental foramen: a dry

human mandibles study in South Indian population [Internet]. Vol. 7, National Journal of Clinical Anatomy. 2018. p. 182. Available from: <http://dx.doi.org/10.4103/2277-4025.294770>

4. Musrati A, Elhassan A, Ehtiwash N, Peeran S, Alzahrani F. Location of mental foramen in a group of Libyan patients: An orthopantomographic study [Internet]. Vol. 7, Dentistry and Medical Research. 2019. p. 45. Available from: http://dx.doi.org/10.4103/dmr.dmr_21_19
5. Singh R, Srivastav AK. Study of Position, Shape, Size and Incidence of Mental Foramen and Accessory Mental Foramen in Indian Adult Human Skulls [Internet]. Vol. 28, International Journal of Morphology. 2010. p. 1141–6. Available from: <http://dx.doi.org/10.4067/s0717-95022010000400025>
6. Singh R. Evaluation of position, shape, size and incidence of mental foramen and accessory mental foramen in Indian adult human skulls [Internet]. Vol. 5, Anatomy (International Journal of Experimental and Clinical Anatomy). 2011. p. 23–9. Available from: <http://dx.doi.org/10.2399/ana.10.004>
7. Shah DMP, Shah MP, Associate professor: Dept. of Anatomy, AMC Met Medical College, Ahmedabad. A Study of position of mental foramen and accessory mental foramen in 300 mandibles of Gujarat population [Internet]. Vol. 2, International Journal of Scientific Research. 2012. p. 412–3. Available from: <http://dx.doi.org/10.15373/22778179/july2013/140>
8. Shruthi M, Preetha S. Effect of Simple Tongue Exercises in Habitual Snorers [Internet]. Vol. 11, Research Journal of Pharmacy and Technology. 2018. p. 3614. Available from: <http://dx.doi.org/10.5958/0974-360x.2018.00665.0>
9. Preetha S, Packyanathan J. Comparison of the effect of Yoga, Zumba and Aerobics in controlling blood pressure in the Indian population [Internet]. Vol. 9, Journal of Family Medicine and Primary Care. 2020. p. 547. Available from: http://dx.doi.org/10.4103/jfmpc.jfmpc_607_19
10. J SK, Saveetha Dental College and Hospitals, Road PH, Chennai, Tamilnadu, Preetha S, et al. Effect of aerobics exercise and yoga on blood pressure in hypertensives [Internet]. Vol. 6, International Journal of Current Advanced Research. 2017. p. 3124–6. Available from: <http://dx.doi.org/10.24327/ijcar.2017.3126.0200>
11. Prathap L, Suganthirababu P, Ganesan D. Fluctuating Asymmetry of Dermatoglyphics and DNA Polymorphism in Breast Cancer Population [Internet]. Vol. 10, Indian Journal of Public Health Research & Development. 2019. p. 3574. Available from: <http://dx.doi.org/10.5958/0976-5506.2019.04141.x>
12. Lavanya J, Prathap S, Alagesan J. Digital and palmar dermal ridge patterns in population with breast carcinoma. Biomedicine. 2014 Jul 1;34(3):315–21.
13. Prathap L, Jagadeesan V. Association of quantitative and qualitative dermatoglyphic variable and DNA polymorphism in female breast cancer population. Online J Health [Internet]. 2017; Available from: https://www.researchgate.net/profile/Prathap_Suganthirababu/publication/321606278_Association_of_Quantitative_and_Qualitative_Dermatoglyphic_Variable_and_DNA_Polymorphism_in_Female_Breast_Cancer_Population/links/5a28c8f1a6fdcc8e8671c0cd/Association-of-Quantitative-and-Qualitative-Dermatoglyphic-Variable-and-DNA-Polymorphism-in-Female-

Breast-Cancer-Population.pdf

14. Lavanya J, Kumar VJ, Sudhakar N, Prathap S. Analysis of DNA repair genetic polymorphism in breast cancer population. *Int J Pharma Bio Sci* [Internet]. 2015; Available from: https://scholar.google.ca/scholar?cluster=8949053652564257518&hl=en&as_sdt=0,5&scio dt=0,5
15. Prathap L, Suganthirababu P. Estrogen Exposure and its Influence in DNA Repair Genetic Variants in Breast Cancer Population [Internet]. Vol. 13, *Biomedical and Pharmacology Journal*. 2020. p. 1321–7. Available from: <http://dx.doi.org/10.13005/bpj/2001>
16. Ravikumar H, Prathap L, Preetha S. ANALYSIS OF PALMAR ATD ANGLE IN POPULATION WITH MALOCCLUSION. 2020 Jan 1;1174–82.
17. Prathap L. INTERPLAY OF OXIDATIVE STRESS AND LIPOPROTEINS IN BREAST CARCINOMA INITIATION, PROMOTION AND PROGRESSION -A SYSTEMATIC REVIEW. *PalArch's Journal of Archaeology of Egypt/ Egyptology* [Internet]. 2021 Jan 7 [cited 2021 Mar 9];17(7). Available from: <http://dx.doi.org/>
18. Samanta PP, Kharb P. MORPHOMETRIC ANALYSIS OF MANDIBULAR FORAMEN AND INCIDENCE OF ACCESSORY MANDIBULAR FORAMINA IN ADULT HUMAN MANDIBLES OF AN INDIAN POPULATION. Análisis morfológico del foramen mandibular e incidencia de la foramina mandibular accesoria en mandíbulas adult [Internet]. Vol. 5, *Revista Argentina de Anatomía Clínica*. 2016. p. 60–6. Available from: <http://dx.doi.org/10.31051/1852.8023.v5.n2.14059>
19. Seema, Seema, Verma P. Morphology and morphometry of mental foramen in adult human mandibles of North Indian population [Internet]. Vol. 4, *National Journal of Clinical Anatomy*. 2015. p. 76. Available from: <http://dx.doi.org/10.4103/2277-4025.297305>
20. Sekar D, Lakshmanan G, Mani P, Biruntha M. Methylation-dependent circulating microRNA 510 in preeclampsia patients. *Hypertens Res*. 2019 Oct;42(10):1647–8.
21. Princeton B, Santhakumar P, Prathap L. Awareness on Preventive Measures taken by Health Care Professionals Attending COVID-19 Patients among Dental Students. *Eur J Dent*. 2020 Dec;14(S 01):S105–9.
22. Logeshwari R, Rama Parvathy L. Generating logistic chaotic sequence using geometric pattern to decompose and recombine the pixel values. *Multimed Tools Appl*. 2020 Aug;79(31-32):22375–88.
23. Johnson J, Lakshmanan G, M B, R M V, Kalimuthu K, Sekar D. Computational identification of MiRNA-7110 from pulmonary arterial hypertension (PAH) ESTs: a new microRNA that links diabetes and PAH. *Hypertens Res*. 2020 Apr;43(4):360–2.
24. Paramasivam A, Priyadharsini JV, Raghunandhakumar S, Elumalai P. A novel COVID-19 and its effects on cardiovascular disease. *Hypertens Res*. 2020 Jul;43(7):729–30.
25. Pujari GRS, Subramanian V, Rao SR. Effects of *Celastrus paniculatus* Willd. and *Sida cordifolia* Linn. in Kainic Acid Induced Hippocampus Damage in Rats. *Ind J Pharm Educ*. 2019 Jul 3;53(3):537–44.

Comment [S44]: Use one format of word.

26. Rajkumar KV, Lakshmanan G, Sekar D. Identification of miR-802-5p and its involvement in type 2 diabetes mellitus. *World J Diabetes*. 2020 Dec 15;11(12):567–71.
27. Ravisankar R, Jayaprakash P, Eswaran P, Mohanraj K, Vinitha G, Pichumani M. Synthesis, growth, optical and third-order nonlinear optical properties of glycine sodium nitrate single crystal for photonic device applications. *J Mater Sci: Mater Electron*. 2020 Oct;31(20):17320–31.
28. Wu S, Rajeshkumar S, Madasamy M, Mahendran V. Green synthesis of copper nanoparticles using *Cissus vitifolia* and its antioxidant and antibacterial activity against urinary tract infection pathogens. *Artif Cells Nanomed Biotechnol*. 2020 Dec;48(1):1153–8.
29. Vikneshan M, Saravanakumar R, Mangaiyarkarasi R, Rajeshkumar S, Samuel SR, Suganya M, et al. Algal biomass as a source for novel oral nano-antimicrobial agent. *Saudi J Biol Sci*. 2020 Dec;27(12):3753–8.
30. Alharbi KS, Fuloria NK, Fuloria S, Rahman SB, Al-Malki WH, Javed Shaikh MA, et al. Nuclear factor-kappa B and its role in inflammatory lung disease. *Chem Biol Interact*. 2021 Aug 25;345:109568.
31. Rao SK, Kalai Priya A, Manjunath Kamath S, Karthick P, Renganathan B, Anuraj S, et al. Unequivocal evidence of enhanced room temperature sensing properties of clad modified Nd doped mullite Bi₂Fe₄O₉ in fiber optic gas sensor [Internet]. Vol. 838, *Journal of Alloys and Compounds*. 2020. p. 155603. Available from: <http://dx.doi.org/10.1016/j.jallcom.2020.155603>
32. Bhavikatti SK, Karobari MI, Zainuddin SLA, Marya A, Nadaf SJ, Sawant VJ, et al. Investigating the Antioxidant and Cytocompatibility of *Mimusops elengi* Linn Extract over Human Gingival Fibroblast Cells. *Int J Environ Res Public Health* [Internet]. 2021 Jul 4;18(13). Available from: <http://dx.doi.org/10.3390/ijerph18137162>
33. Marya A, Karobari MI, Selvaraj S, Adil AH, Assiry AA, Rabaan AA, et al. Risk Perception of SARS-CoV-2 Infection and Implementation of Various Protective Measures by Dentists Across Various Countries. *Int J Environ Res Public Health* [Internet]. 2021 May 29;18(11). Available from: <http://dx.doi.org/10.3390/ijerph18115848>
34. Barma MD, Muthupandiyani I, Samuel SR, Amaechi BT. Inhibition of *Streptococcus mutans*, antioxidant property and cytotoxicity of novel nano-zinc oxide varnish. *Arch Oral Biol*. 2021 Jun;126:105132.
35. Vijayashree Priyadharsini J. In silico validation of the non-antibiotic drugs acetaminophen and ibuprofen as antibacterial agents against red complex pathogens. *J Periodontol*. 2019 Dec;90(12):1441–8.
36. Priyadharsini JV, Vijayashree Priyadharsini J, Smiline Girija AS, Paramasivam A. In silico analysis of virulence genes in an emerging dental pathogen *A. baumannii* and related species [Internet]. Vol. 94, *Archives of Oral Biology*. 2018. p. 93–8. Available from: <http://dx.doi.org/10.1016/j.archoralbio.2018.07.001>
37. Uma Maheswari TN, Nivedhitha MS, Ramani P. Expression profile of salivary micro RNA-21 and 31 in oral potentially malignant disorders. *Braz Oral Res*. 2020 Feb 10;34:e002.

38. Gudipani RK, Alam MK, Patil SR, Karobari MI. Measurement of the Maximum Occlusal Bite Force and its Relation to the Caries Spectrum of First Permanent Molars in Early Permanent Dentition. *J Clin Pediatr Dent*. 2020 Dec 1;44(6):423–8.
39. Chaturvedula BB, Muthukrishnan A, Bhuvaraghan A, Sandler J, Thiruvengkatachari B. Dens invaginatus: a review and orthodontic implications. *Br Dent J*. 2021 Mar;230(6):345–50.
40. The Morphometric Analysis of the Mental Foramen in Adult Dry Human Mandibles : A Study on the South Indian Population [Internet]. *JOURNAL OF CLINICAL AND DIAGNOSTIC RESEARCH*. 2013. Available from: <http://dx.doi.org/10.7860/jcdr/2013/6060.3207>
41. Mohammad ZK, Shadid R, Kaadna M, Qabaha A, Muhamad AH. Position of the Mental Foramen in a Northern Regional Palestinian Population [Internet]. Vol. 2, *International Journal of Oral and Craniofacial Science*. 2016. p. 057–64. Available from: <http://dx.doi.org/10.17352/2455-4634.000020>
42. Ilayperuma I, Nanayakkara G, Palahepitiya N. Morphometric Analysis of the Mental Foramen in Adult Sri Lankan Mandibles [Internet]. Vol. 27, *International Journal of Morphology*. 2009. Available from: <http://dx.doi.org/10.4067/s0717-95022009000400010>
43. Alrahabi M, Zafar M. Anatomical Variations of Mental Foramen: A Retrospective Cross-Sectional Study [Internet]. Vol. 36, *International Journal of Morphology*. 2018. p. 1124–9. Available from: <http://dx.doi.org/10.4067/s0717-95022018000301124>
44. Kim I-S, Kim S-G, Kim Y-K, Kim J-D. Position of the Mental Foramen in a Korean Population: A Clinical and Radiographic Study [Internet]. Vol. 15, *Implant Dentistry*. 2006. p. 404–11. Available from: <http://dx.doi.org/10.1097/01.id.0000243319.66845.15>
45. Chandramohan RV, Ramanathan S, Rethinasamy M, Muthulingam V. A COMPARATIVE STUDY OF MORPHOLOGICAL AND MORPHOMETRIC ANALYSIS OF MENTAL FORAMEN AND ITS CLINICAL IMPORTANCE ON HUMAN DRY MANDIBLES OF SOUTH INDIAN POPULATION [Internet]. Vol. 5, *Journal of Evolution of Medical and Dental Sciences*. 2016. p. 5439–44. Available from: <http://dx.doi.org/10.14260/jemds/2016/1232>
46. Suman P, Singh S, Mahato RK. Mental foramen and accessory mental foramen: a dry human mandibles study in South Indian population [Internet]. Vol. 7, *National Journal of Clinical Anatomy*. 2018. p. 182–91. Available from: <http://dx.doi.org/10.1055/s-0040-1701734>