

Review Article

Lumbar stenosis with necrosis of foot a diagnostic approach

Abstract

Lumbar stenosis is characterised by decrease in spinal canal, neural foramina, lateral nerve .with the narrowing or compression which results in pain and progressive loss. The main objective of the review was to present etiology, pathogenesis and most importantly its clinical presentation along with the necrosis of foot . Study shows that lumbar stenosis can show its improvement by surgical Lumbar decompression and endoscopy.

List of keywords used

BMP - bone morphogenetic protein

TGF - transforming growth factor

CSF – cerebrospinal fluid

Introduction

Lumbar stenosis is known for the reduction in the diameter of the spinal canal , lateral nerve canals, or neural foramina or its narrowing . The nerve that passes through the spine and the pressure created on the spinal cord may be created by lumbar spinal stenosis. The stenosis may arise part of a general disorder process and involve more than one region of the canal and more than one ranges or, oppositely can be segmental. The decrease in the vertebral column diameter or neural tube may be because of the bone enlargement , ligament enlargement ,sleep disc, or any other compound of these . necrosis of foot is an uncommon condition which mainly affects the bones of foot. Which is due to loss of blood supply to the bone or that portion , which causes death of bone cells .it mainly occurs in diabetic patients which is known as diabetic necrotic foot. Necrotic foot looks like a dry ,thick ,leathery tissue which usually look tan , black or brown in colour (fig 2) . their is redness and swelling in the affected area. Diabetic foot lesion leads to lower limb amputations. Which has sensory loss. As Wiltse [1] noted that the first decompressive of laminectomy was carry out for cauda equina syndrome was accomplished by Lane in 1893. In 1900, Sachs and Fraenkel,[2] ,baly and Casamajor reported changes in lumbar spine which bring out compression of nerve root and, spinal stenosis , hypertrophic facet joints and a thickened yellow ligament. Later describe from Elsberg and from Kennedy [3] granted an credit to those clinical being. Schlesinger and Taveras [4] describe the importance of lumbar canal stenosis in patients with a herniated disc and an uncommon portrait of compression of several nerve roots or the cauda equina. The following authors were the first to notice the size of the spinal canal was more applicable than the size of the disc protrusion on producing symptoms .Most of the patients with typical lumbar stenosis present with neurogenic spasmodic lameness with risk of falling . Although the physical symptoms and clinical feature of lumbar stenosis are not acute, the radiographic signs are somewhat severe.

Comment [S1]: Reference?

Comment [S2]: Reference?

Comment [S3]: The purpose of review, gap in current knowledge is missing.

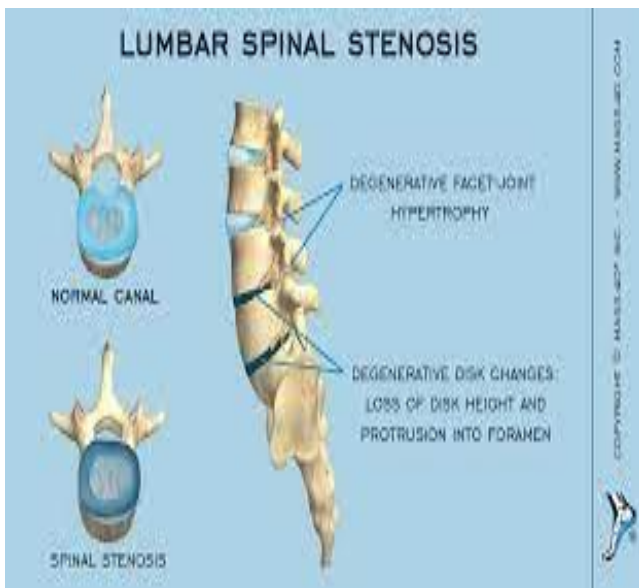


Fig 1. lumbar spinal stenosis

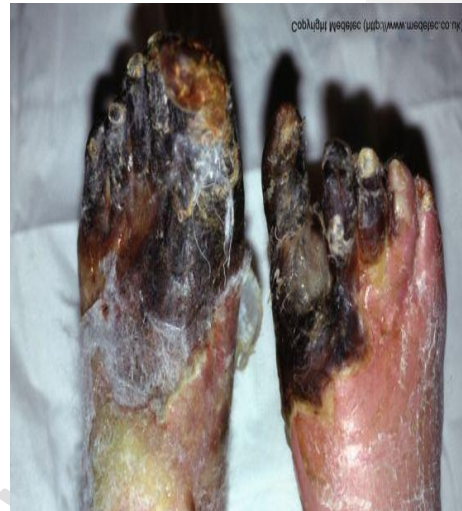

Fig 2. Necrosis of foot

Etiology

In spinal stenosis the basic mechanism is behind bone alteration and proliferation along the osteophyte formation. Bone Excessive growth is determined by the degenerative process which acts on the 3 joint compound consisting the adjacent sides and two zygapophysial joints. In joint complex the three parts are ultimately relatable and the damage caused to it depresses one part which ultimately have an impact on the other two part. Along with that foot necrosis occurs which has different etiologies which include embolus , ischemia and others . the most common is ischemia .it occurs because of the decrease in the blood supply to tissue that may lead to tissue death and infection or injury . intermittent claudication caused by reduction or obstruction of blood supply to the muscle will cause a pain . before any surgical approach of foot necrosis an etiology must be noticed. As the most common cause is ischemia so the lower limb gangrene could be secondary to mechanical trauma , pharmacological sensitivity , infections and granulomatous tissue . Any tissue loss such as massage of the articular cartilage, results in relation of ligament laxity and joint degradation. Bone alteration is a result of excessive joint movement or a physiological attack at arthrodesis. The end result, caused is a decreased in segmental strength. The distruction of strength in one segment develop an irregular stress and force to the contiguous spinal part, which degenerate at a very fast speed. It is said that the relation between the degraded process and mobility creates two lower motion segments (L3L4, L4L5) which are more frequently afflicted by degraded narrowing. The two lower segments are in a moving area starting with the stiff sacrum to the moving lumbar spine. however, their posterior joints have a lesser sagittal inclination which handle many rotations and is the most danger revolving tension. In most of the cases or individuals, the L5S1 segment is rescued from degradation and injury

Comment [S4]: Vs of pathogenesis. Kindly check

by its given location which is given just beneath the intercrestal line and its related large transverse L5 processes . The accepted material for bone regrowth by chondroid metaplasia and in the consecutive outgrowth remains volatile. Developmental cytokines and bone proteins of the TGF family have exist compressive within operation of disc declination [5,6]. Bone morphogenetic proteins is strong and stiffened (hardened) proteins that adjust its growth, demarcation, and apoptosis of numerous types of cell and are mostly established in profusion of bone and cartilage. Among the improvement of disc degradation. In cellular apoptosis it is said that BMP , moderate has its reaction . which measure to the degenerative process because the programmed cell death had directly appear and had played an important role in disc degradation.[7]

Pathogenesis

Depressive stenosis of the lumbar spine develops from degradation of the facet joints, herniated disc, spondylosis , hypertrophy of the yellow ligament. Degenerative variations in the joint complex (the intervertebral disc and the two facet joints) explain about the variable changes at the clinical feature of modification in load ,posture and time of load.[8]. Lumbar disc degeneration shows a force of occurrence which involves herniated disc, swelling of the disc and yellow ligament at the duct and consequent chronic facet osteoarthritis. In the progression of spinal narrowing the Yellow ligament hypertrophy plays an major role. Lumbar spine drop creates hypertrophy of the yellow ligament which further leads to stenosis. Nerve root and spinal disease, however, does not directly result from nerve contraction. As compared to, the resulting stenosis causes a decline in CSF flow, resulting for the increase in venous pressure and 60 percent of the nutrient distribution to the cauda equina. Any other spinal deformities in this kind of bodywork may severly consist of the nerve roots and cord, in addition to intensified neurological indication of lumbar stenosis.

Spondylolisthesis can be produce by hereditary or inborn ,developmental, traumatic, neoplastic, or degenerative conditions. With lumbar stenosis the most familiar type seen is foot necrosis with serious complication of diabetes mellitus causing morbidity and mortality and disability in diabetic patient . this factors contribute to the diabetic foot this causes peripheral vascular disease causing poor circulation in legs and foot and neuropathy , a condition where the nerve damage from diabetes results in decreased sensation in the upper and lower extremities . this condition can speed up , if proper treatment is not given . complications of this condition increase the risk of amputations in diabetic patient .further this can result in gangrene and thrombosis .In most of the cases the diabetic foot are polymicrobial in nature .the fungi scattered from diabetic foot are almost pathogenic when found in nails or skin , this infections are caused by Trichophyton rubrum , trichophyton metagrophytes , candida and Fusarium . In degenerative spondylolisthesis the anterior or posterior rearrangement of vertebral body results from destruction and depletion of the facet joints of muscle, capsular and ligament structures. It is more familiar in women than in men. , depressive spondylolisthesis comes up with repeated time mostly at L4-5 and L5-S1[9] segments. Spondylolisthesis is caused by disc degeneration which further results in divisional hypermobility ,aggravated by arthritis of the sagittal facets .These facet joints, which comes up to a third spinal compressive load and axial loads , and drop their opposition in regards towards its pressure in the sagittal plain .Degenerative vertebral anterior contracture, which does not usually increased its 30% of the wideness of the vertebral body , and uncertainty in vertebral column may come up with the neurogenic claudication of lumbar stenosis Extension of the central canal comes up when the Vertebral body moves in the forward direction whereas the other posterior arch of the cephalic vertebrae leaves at one place . Although this shows a straight aggravation of the vertebral canal, Around the pars conformation of calluses which can decrease the entire narrowing of the canal. Spondylolisthesis is mostly related of

Comment [S5]: I think the major etiology part is written under the subheading. Please check

back pain, that ultimately affects the methods of treatment. Scoliosis [curved spine] can disjoin lumbar spinal stenosis. And Mostly the cases could be classified under degenerative, idiopathic, or post-surgical. Idiopathic curvature of spine is present their when the changes results in pre-existing idiopathic scoliosis.. The another spinal abnormality that may combine the treatment and presentation of lumbar spinal stenosis is rising the post-surgical flat back syndrome. The purpose of this review is considering the most common post-surgical type. Flat back deformity is an relative decrease in the normal lumbar lordosis which can lead to a fixed sagittal variation. Since flatback generally develops against location of posterior spinal junction where the distraction has been placed ,and usually it is being followed by union degeneration, and stenosis .The remaining causes include spinal cord deformity and extensive rheumatologic disorders like ankylosing spondylitis[11]. Thus, causing sagittal deformity which increases its neurophysiologic demands on the other related muscles, ligaments, and intervertebral discs, which may further causes a back pain and endless degeneration. Therefore, the treatment of lumbar stenosis or narrowing against the scenario of flat back deformity must have looked but not only the relaxation of neuronal elements, but also sagittal adjustment and back pain. The fixed spine of sagittal deformity can be shown their to increased the back pain, improper walking ability, and with the problem like unable to stand with the hips and knees extended. the fixed deformities occur at the same time as with spinal stenosis. The specific organ of these abnormality may have an non-structural and structural causes. Non-structural causes has its own psychopathological factors such as depression, neuromuscular disease, poor posture, and disturbing injury along with those in metastatic disease. Systemic causes can be degenerative, congenital, and balancing along with the other lesions of the spine. Degenerative causes include lumbar stenosis, arthritis of the facet joints, and disc disease. Sagittal malformation which may represent a injury for thoraco-lumbar kyphosis which is greater than 15 °, thoracic lordosis or lumbar kyphosis. Noxious vertebral processes has the following tumors (primary or metastatic), infections (eg, discitis), trauma, and nerve pain. Inflammatory diseases can include ankylosing spondylitis and scatter idiopathic skeletal hyperostosis. iatrogenic causes include post-laminectomy deformities, misaligned fusion.

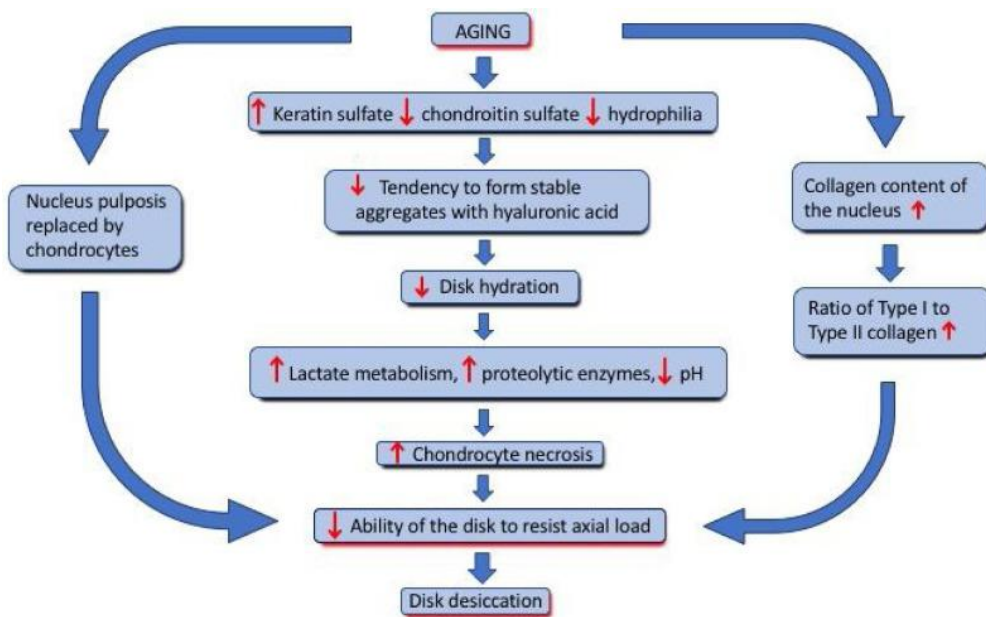


Fig. 3. Pathogenesis

Clinical presentation

Generally, lumbar spinal stenosis or the narrowing represents as a pain intensified by long walking, standing etc and is further alleviated by bending over and resting. Along with that in foot necrosis we have seen that due to obstruction of blood supply to the muscle it causes pain. Both the pain will ultimately lead to tingling sensation in leg. We can also experience sensory loss in both the conditions. Lumbar spinal stenosis has neurogenic claudication as an important feature. Clinical features are generally two ways, but also asymmetric.

- Lower back pain, numbness in leg while walking and tingling sensation are seen in most of the patients.
- In tingling sensation it involves the full leg and sometimes affects only a single nerve root.
- About 43% of patients face weakness.
- The patients may also report that it is easier to go up with the stairs than to go down because the back is bent forward when we climb the stairs.
- If patients experience bowel or bladder condition, bilateral lower limb weakness, or lower limb extension, the patient can have the developed cauda equina.
- At different regions removal can occur. The anatomical / radiographic classification could be appealing by distinguishing between: [12,13,14]

-narrowing of the spinal canal

-constriction of the lateral recess (area under the facet joint)

-constriction of the intervertebral foramen.

- One or a compound of anatomical changes may occur.[14]
stenosis is mostly found in facet joints. At this level, the pathological changes of

Comment [S6]: Please support each feature with reference, if possible. Some other diagnostic features like patho/biochem/ imaging studies may be added

the disc and facets and the hypertrophy of the ligamentum luteum cause the greatest narrowing .Narrowing is somewhat rare and shows an inborn stenosis underlying the development of the bone canal.

- Degeneration of the spinal disc further leads to Central stenosis. So this can lead to a narrowing of the spinal canal around the Symptoms which are mainly concern with the buttocks and the posterior thighs in a non-dermatological parts .
- At rest Patients may experience more pain at night time, but can highly tolerate while walking .
- In foot necrosis there is skin discoloration which is blue , black , purple or bronze and red in colour . which depend on type of gangrene.
- Their will be swelling and sudden rising pain followed by feeling of numbness.
- A bad smelling from the leaking sore.
- Skin that feels cool or cold to the touch.

So we have seen that both the condition experience somewhat same clinical features like pain in leg and mainly it feels tingling sensation , and sensory loss .

Comment [S7]: Discussion missing. The manuscript not presented in a review article format. Methodology not followed/mentioned. Manuscript needed more clarity.

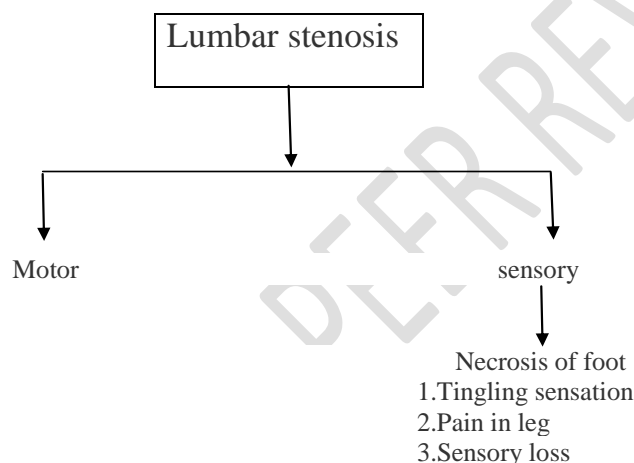


Fig. 3. Details of Lumbar stenosis

Conclusion

Lumbar canal stenosis is a compound syndrome, which consist of degenerative processes in the lumbar spine.. And in necrotic foot it can be treated by bone transplant , core decompression in which the surgeon removes part of the inner layer of the infected bone . Most of the patient of lumbar stenosis will show improvement after surgical decompression.

References

1. Wilste LL: History of Spinal Disorders.InFrymoyer JW (a cura di).AdultSpine.New York, Raven Press
2. SACHS B, Fraenkel J: Progressive Ankylosis of TheSpine.jDish 27: 1-15, 1900

3. Kennedy F, Elsberg CA, Lambert CI: A **particular** undescribed disease of the nerves of the cauda equina. *Am J Med Sci* 147: **645-667**, 1914.
4. Schlesinger EB, Taveras JM: Factors on the production of cauda equina syndromes in **the lumbar** discs. *Trans Am Neurol Assoc* 78: **263-265**, 1953
5. Hayashi K, Ishidou Y, Yonemori K, et al: **expression and** localization of **bone** morphogenetic proteins (BMP) and BMP **receptors** in **the ossification** of the ligamentum **luteum**. *Os* 21: **23-30**, 1999
6. Takae R, Matsunaga S, Origuchi N, et al: **Immunolocalisation** of bone morphogenetic protein and its receptors in intervertebral disc **degeneration**. *Spine* 24: **1397-1401**, 1999.
7. Gruber HE, Hanley EN: Analysis of aging and degeneration of the human intervertebral disc. **Comparison** of surgical specimens with normal controls. *Return* 23: **751-757**, 1998.
8. Schonstrom N, Willen J: Imaging **of lumbar** spinal stenosis. *Radiol Clin North Am* 39: **31-53**, 2001
9. Cauchoix J, Benoist M, Chassaing V: **Spondilolistesidegenerativa**. *ClinOrthop* **115:122-129**, 1976
10. Postacchini F: Surgical **treatment** of lumbar spinal stenosis. *Spine* 24: **1043-1047**, 1999
11. Bridwell KH, Lenke LG, Lewis SJ: Treatment of spinal stenosis and fixed sagittal imbalance. *ClinOrthop* 384: **35-44**, 2001.
12. Gallucci M, Puglielli E, Splendiani A, Pistoia F, Spacca G. **Degenerative diseases** of the spine. *EurRadiol*. **March 15, 2005** (3): **5918**. [NdP: 2C]
13. Skinner HB, McMahon PJ. **Current diagnosis and treatment in orthopedics**. 5th U.S.A. **Edition**: Mc Graw Hill Education; 2014.
14. De Graaf I, Prak A, BiermaZeinstra S, Thoma S, Peul W, Koes B. **Diagnosis** of lumbar spinal stenosis: a systematic review of the accuracy of diagnostic tests. *May* 2006; **31 (10): 1168-1176**. [LoE: 3A]

15. Siebert E, Prüss H, Klingebiel R, Failli V, Einhäupl KM, Schwab JM. Lumbar spinal stenosis: syndrome, diagnostics and treatment. *Neurology* 2009 Jul; 5(7):392403. [LoE: 1A].

UNDER PEER REVIEW