

Arthroscopic Management and Treatment of Synovial Chondromatosis with loose bodies in of the knee joint

Comment [A1]: Arthroscopic management includes treatment. The title should be simple, direct, precise and concise.

Comment [A2]: In synovial chondromatosis, the synovium produces obviously cartilaginous loose bodies. The title should be simple, direct, precise and concise.

Comment [A3]: Redundance. The subtitle should be short.

Running title : Arthroscopic Management and Treatment of Synovial Chondromatosis

Abstract

Synovial chondromatosis, is a rare and ~~it is a~~ benign condition characterized by multiple cartilaginous nodules in ~~synovial facet spaces~~. Synovial chondromatosis affects joints, the most common being ~~most commonly the~~ knee. This report examined a 30-year-old male ~~patient with chief complaints of who presented with~~ pain in the left knee joint. Investigations were done and MRI showed loose ~~body bodies~~, for which he underwent, arthroscopic exploration. Viscous fluid and loose bodies were identified and showed synovial hyperemia. Synovial debridement ~~was done and loose body was bodies were~~ removed and sent to histopathological examination. The results of the current report signify that arthroscopy is efficient method both in diagnostic as well as therapeutic management of synovial chondromatosis.

Comment [A4]: The expression "in joint cavities" may be better.

Keywords:

Synovial chondromatosis, knee joint, arthroscopy, loose bodies.

Introduction

Synovial chondromatosis furthermore called as synovial Osteo-Chondromatosis, is ~~in fact~~ a rare and benign disorder characterized ~~by~~ multiple cartilaginous nodules deemed to be loose bodies within the synovium of joints^{1,2}. Synovial chondromatosis affects single large joints, knee being more common, affections in hip, elbow, shoulder and ankle³ are also reported. But affections are reported in smaller joints as well, especially in distal radio-ulnar, tibio-fibular, metacarpo-phalangeal and metatarso-phalangeal joints⁽⁴⁻⁷⁾. Clinical features may vary from being completely asymptomatic or may present with subtle history of pain, associated with swelling, joint crepitus or may present with typical history of locking of the knee joint⁽⁸⁾. Diagnosis ~~is~~ mainly based on radiological investigations ~~such as~~ x-ray, computed tomography (CT) scans ~~that identifies mineralized / calcified nodules or~~ ~~and~~ magnetic resonance imaging (MRI). Investigations not only help as a diagnostic tool, but also ~~aid~~ ~~aid~~ in surgical management ~~as well~~. However definitive diagnosis is based on histopathological examination. Clinically management involves excision of loose bodies using arthroscopic technique⁹ to eliminate symptoms and to avoid further joint destruction⁽¹⁰⁾. ~~This current reports~~ ~~We report~~ a case of synovial chondromatosis of the knee in a young patient with pain in knee joint since 1 year.

Case report

A 30-year-old male patient with past history of trauma 1 year back previously presented with pain in the left knee since 1 month. Following which patient was admitted to Sree Balaji medical college for further examination and treatment. Pain was insidious at onset, intermittent (initially) and progressive and severe since 1 month. Symptoms exacerbated after a history of climbing stairs associated with swelling and pain of the left knee and the patient experienced difficulties in activities of daily living like squatting, walking and gives a history several episodes of locking of the knees. On clinical examination, there was a swelling associated with a local tenderness at the front and back of the left knee. The range of movements motion was not restricted but terminally painful. MRI scans identified loose bodies in anterior inter-condylar region.

Comment [a5]: Grammar issues. The whole sentence should be revised.

Comment [a6]: Grammar issues. The whole sentence should be revised.

Comment [a7]: Xray findings haven't been mentioned. The Figure 1 haven't been referred to.

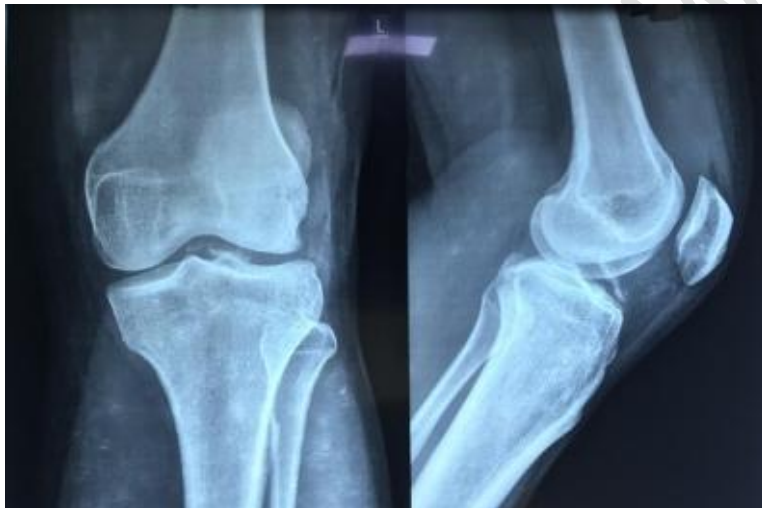
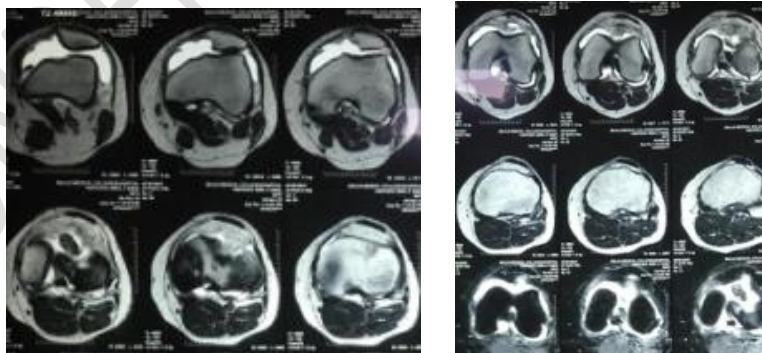


Fig 1. X-Ray image of knee



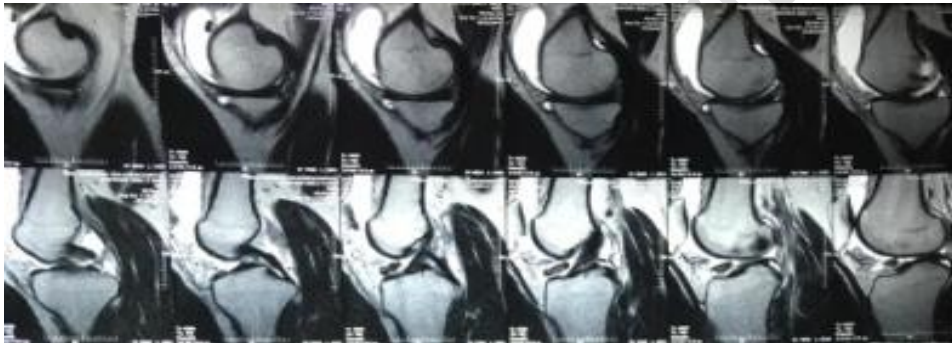
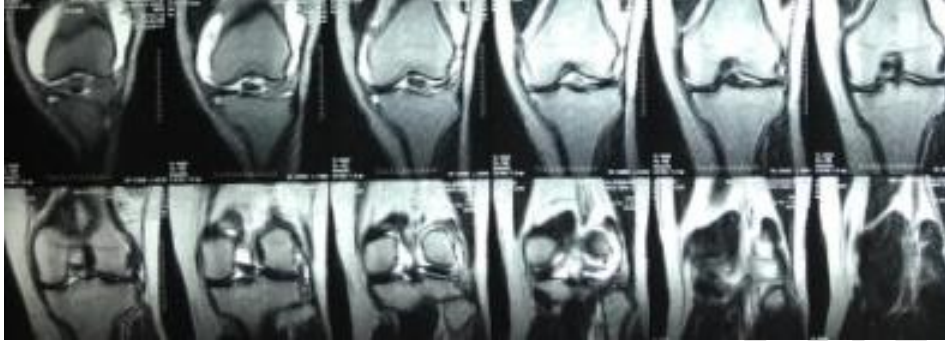
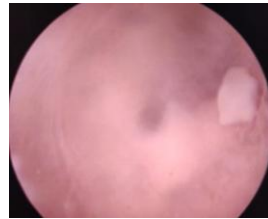
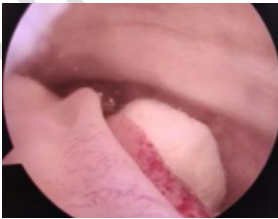

Fig 2. MRI scans

The Patient was posted for Arthroscopic removal of loose bodies. Under Spinal anesthesia, under tourniquet control standard medial and lateral portals were used. With the help of Using Probe hooks, joint spaces and structures were initially assessed in all directions. Articular cartilages were cartilage was examined as well. Intra operatively it was observed that there was hyperemia and edema in the medial and lateral recesses. Partial synovectomy was performed. Irregular cartilage-like bodies of ~16x7 mm, were identified and subsequently removed with forceps. Synovial membrane and the loose bodies were sent to Histopathological analysis.

Comment [a8]: Only informative MRI images should be preserved

Comment [a9]: The whole sentence should be revised.




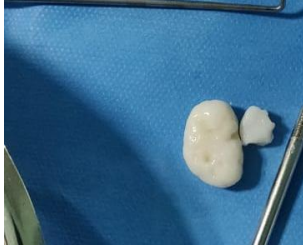


Fig 3. Histopathological analysis

Pathological gross specimen showed multiple white loose bodies and were reported as synovial hyperplasia with cartilage island, that was . These findings were consistent with the diagnosis of synovial chondromatosis.

The Patient underwent standard post operative protocol with antibiotics, analgesics and physical therapy. The Post operative period was uneventful. The Patient improved symptomatically and terminal pain was relieved. The Patient could sit crossed legs and squat without pain.

Comment [a10]: Every image should have a single legend. For example Fig 3a, 3b, 3c...

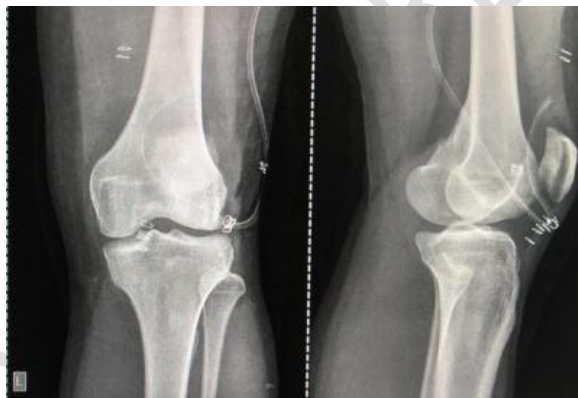

Fig 4. Post operative X-ray image

Comment [a11]: Every figure should be referred to in the main text

Discussion

Synovial chondromatosis is a condition that has an etiology pertaining to synovial metaplasia⁽¹⁹⁾. The cartilaginous nodules in the synovium or in joints leads to formation of sub-intimal fibroblasts in tendons and bursae⁽²⁰⁾. These extrudes from synovium to become loose bodies found to be floating in the synovial spaces or extend to the extra articular soft tissue⁽²¹⁾.

Milgram's classified, synovial osteochondromatosis in three stages based on gross and pathological findings. The Stage I, referred to active lesions of the synovium, without loose bodies and synovial cartilage metaplasia. The Stage II, referred to transitional lesions with active intra-synovial proliferation with free loose bodies. The Loose bodies may remain within proliferated membrane. The Stage III,

referred to multiple loose bodies in joint space and synovitis subsides⁽²⁾. Partial or total synovectomy was proposed done during stages I and II and stage III while free body removal is necessary in the stage III. This patient was found to be in stage III.

Comment [a12]: This information is not necessary.

Synovial chondromatosis is mostly seen in patients aged between 30 and 50 years⁽²²⁾. Routine examinations, including AP and lateral X-ray, CT and MRI scans are mandatory for diagnosis. Multiple irregular loose bodies⁽²⁴⁾. In the present report, loose bodies were identified in x-ray and MRI, with minimal effusion. Arthroscopy has replaced arthrotomy, in view of post-operative early recovery, less operative time period, minimal incision and complete instrumentation and arthroscopy is a more effective treatment than loose body removal alone^(27,28). According to Urbach et al⁽²⁹⁾ loose body removal with local synovectomy, eliminates abnormal synovial tissue and prevent recurrence. This concludes that arthroscopic technique is safe and effective method in the treatment of synovial chondromatosis.

Comment [a13]: anteroposterior

Comment [a14]: The sentence should be revised.

References

1. Chiba S, Koge N, Oda M, Yamauchi R, Imai T, Matsumoto H and Yokogushi K: Synovial chondromatosis presenting with cervical radiculopathy: A case report. *Spine (Phila Pa 1976)* 28: E396-E400, 2003.
2. Milgram JW: Synovial osteochondromatosis: A histopathological study of thirty cases. *J Bone Joint Surg Am* 59: 792-801, 1977.
3. Roberts D, Miller TT and Erlanger SM: Sonographic appearance of primary synovial chondromatosis of the knee. *J Ultrasound Med* 23: 707-709, 2004.
4. von Schroeder HP and Axelrod TS: Synovial osteochondromatosis of the distal radio-ulnar joint. *J Hand Surg Br* 21: 30-32, 1996.
5. Batheja NO, Wang BY, Springfield D, Hermann G, Lee G, Burstein DE and Klein MJ: Fine-needle aspiration diagnosis of synovial chondromatosis of the tibiofibular joint. *Ann Diagn Pathol* 4: 77-80, 2000.
6. Warne BA, Tigrani DY and Ward CM: Metacarpophalangeal joint synovial osteochondromatosis: A case report. *Iowa Orthop J* 28: 91-93, 2008.
7. Tagliavero G, Moro S, Stecco C and Pennelli N: Bilateral synovial chondromatosis of the first metatarsophalangeal joint: A report case. *Reumatismo* 55: 263-266, 2011 (In Italian).
8. Evans S, Boffano M, Chaudhry S, Jeys L and Grimer R: Synovial chondrosarcoma arising in synovial chondromatosis. *Sarcoma* 2014: 647939, 2014.
9. Yu GV, Zema RL and Johnson RW: Synovial osteochondromatosis. A case report and review of the literature. *J Am Podiatr Med Assoc* 92: 247-254, 2002.
10. Neumann JA, Garrigues GE, Brigman BE and Eward WC: Synovial Chondromatosis. *JBSJ Rev* 4: pii: 01874474-201605000-00005, 2016.

11. Varol A, Sencimen M, Gulses A, Altug HA, Dumlu A and Kurt B: Diagnostic importance of MRI and CT scans for synovial osteochondromatosis of the temporomandibular joint. *Cranio* 29: 313-317, 2011.
12. Xie S, Nevis J and Lezmi S: Pathology in practice. Chondro-osseous metaplasia consistent with synovial chondromatosis in a great horned owl. *J Am Vet Med Assoc* 245: 767-769, 2014.
13. Jiang W: Clinical observation of combined treatment of traditional chinese medicine and western medicine in 35 cases with traumatic synovitis of knee joint. *World Health Digest* 433-433, 2012
14. McQueen FM: The MRI view of synovitis and tenosynovitis in inflammatory arthritis: Implications for diagnosis and management. *Ann N Y Acad Sci* 1154: 21-34, 2009.
15. Mannami K: Influence of intraarticular continuous perfusion of physiological saline on chondrocytes. *Nihon Seikeigeka Gakkai Zasshi* 59: 573-580, 1985 (In Japanese).
16. Outerbridge RE: The etiology of chondromalacia patellae. *J Bone Joint Surg Br* 43-B: 752-757, 1961.
17. Parvizi J, Azzam K and Rothman RH: Deep venous thrombosis prophylaxis for total joint arthroplasty: American Academy of Orthopaedic Surgeons guidelines. *J Arthroplasty* 23 (7 Suppl): S2-S5, 2008.
18. Collins NJ, Misra D, Felson DT, Crossley KM and Roos EM: Measures of knee function: International knee documentation committee (IKDC) subjective knee evaluation form, knee injury and osteoarthritis outcome score (KOOS), knee injury and osteoarthritis outcome score physical function short form (KOOS-PS), knee outcome survey activities of daily living scale (KOS-ADL), lysholm knee scoring scale, oxford knee score (OKS), western ontario and McMaster universities osteoarthritis index (WOMAC), activity rating scale (ARS), and tegner activity score (TAS). *Arthritis Care Res (Hoboken)* 63 (Suppl 11): S208-S228, 2011.
19. Narasimhan R, Kennedy S, Tewari S, Dhingra D and Zardawi I: Synovial chondromatosis of the elbow in a child. *Indian J Orthop* 45: 181-184, 2011.
20. Surwade A, Chaudhary A and Mahale Y: Synovial chondromatosis of the knee: Management with arthroscope-assisted synovectomy and removal of loose bodies: A case report *IJHSR*: 6: 388-391, 2016.
21. Birchall D, Khangure MS and Spagnolo DV: Vertebral synovial osteochondromatosis with compressive myelopathy. *Spine (Phila Pa 1976)* 24: 921-923, 1999.
22. Jesalpura JP, Chung HW, Patnaik S, Choi HW, Kim JI and Nha KW: Arthroscopic treatment of localized synovial chondromatosis of the posterior knee joint. *Orthopedics* 33: 49, 2010.
23. Kistler W: Synovial chondromatosis of the knee joint: A rarity during childhood. *Eur J Pediatr Surg* 1: 237-239, 1991.
24. Sato J, Notani KI, Goto J, Shindoh M and Kitagawa Y: Synovial chondromatosis of the temporomandibular joint accompanied by loose bodies in both the superior and inferior joint compartments: Case report. *Int J Oral Maxillofac Surg* 39: 86-88, 2010.

25. Frick MA, Wenger DE and Adkins M: MR imaging of synovial disorders of the knee: An update. *Radiol Clin North Am* 45: 1017-1031, 2007.
26. Rehm J, Zeifang F and Weber MA: Imaging of the elbow joint with focus MRI. Part 2: Muscles, nerves and synovial membranes. *Radiologe* 54: 279-294, 2014.
27. Samson L, Mazurkiewicz S, Treder M and Wiśniewski P: Outcome in the arthroscopic treatment of synovial chondromatosis of the knee. *Ortop Traumatol Rehabil* 7: 391-396, 2005.
28. Ogilvie-Harris DJ and Saleh K: Generalized synovial chondromatosis of the knee: A comparison of removal of the loose bodies alone with arthroscopic synovectomy. *Arthroscopy* 10: 166-170, 1994.
29. Urbach D, McGuigan FX, John M, Neumann W and Ender SA: Long-term results after arthroscopic treatment of synovial chondromatosis of the shoulder. *Arthroscopy* 24: 318-323, 2008

UNDER PEER REVIEW